

Enhanced-depth optical coherence tomography for imaging horizontal rectus muscles in Graves' orbitopathy

Nathanael U. Häner¹ · Muriel Dysli^{1,2} · Mathias Abegg¹ ·
Martin S. Zinkernagel^{1,2}

Received: 30 October 2014 / Revised: 12 May 2015 / Accepted: 14 May 2015 / Published online: 7 June 2015
© Springer-Verlag Berlin Heidelberg 2015

Abstract

Purpose Graves' orbitopathy (GO) is an extraocular eye disease with symptoms ranging from minor discomfort from dry eyes to strabismus and visual loss. One of the hallmarks of active GO is visible hyperemia at the insertion of the extraocular muscles. The aim of the present study was to evaluate the use of enhanced-depth imaging spectral domain anterior segment optical coherence tomography (EDI SD AS-OCT) for detecting pathological changes in horizontal recti muscles of patients with GO.

Methods Prospective cross sectional study of 27 eyes. Only women were included. EDI AS-OCT was used to measure the thickness of the tendons of the horizontal recti muscles in a predefined area in patients with GO and healthy controls.

Results EDI AS-OCT was able to image the tendons of the horizontal recti muscles in both healthy controls and patients suffering from GO. The mean thickness of the medial rectus muscle (MR) tendon was 256.4 μm [± 17.13 μm standard deviation (SD)] in the GO group and, therefore, significantly thicker ($p=0.046$) than in the healthy group which had a mean thickness of 214.7 μm (± 5.516 μm SD). There was no significant difference in the mean thickness of the tendon of the lateral recti muscles (LRs) between these groups.

Conclusion This is the first report showing that EDI AS-OCT is suitable to detect swelling at the insertion site of the MR muscle in GO. MR tendon thickness may be a useful parameter to monitor activity in these patients.

Keywords Extraocular eye muscles · Myopathy · Anterior segment OCT · Graves' orbitopathy

Introduction

Graves' disease represents the most common cause of hyperthyroidism in adults [1]. In addition to the thyroid, the skin and the eyes may be involved as well [1]. Orbital involvement is known as Graves' orbitopathy or ophthalmopathy (GO) or as thyroid eye disease (TED) [2]. Rarely, GO is associated with Hashimoto thyroiditis, euthyroid or hypothyroid patients [1].

The pathogenetic mechanisms of GO have not yet been fully resolved. It is known that antibodies against the thyroid stimulating hormone (TSH) receptors play an important role. TSH receptors can not only be found in the thyroid, but also in the extraocular eye muscles and retrobulbar fat tissue. It is thought that circulating TSH-receptor autoantibodies (TRAbs) trigger inflammation and activation of orbital fibroblasts leading to intraorbital swelling and, subsequently, to fibrosis at a later stage. Accordingly, circulating TRAbs can be detected in the blood and are detected in most GO patients [3].

Active GO is characterized by an inflammatory response which may involve the ocular surface, extraocular muscles and other orbital tissue. Depending on the site of inflammation, the disease may cause dry eye symptoms or conjunctival chemosis, while the increased orbital volume may cause proptosis and eye movement disorders. The inferior rectus muscle and the MR muscle are primarily affected [4]. Due to potential

✉ Martin S. Zinkernagel
m.zinkernagel@gmail.com

¹ Department of Ophthalmology, Inselspital, Bern University Hospital, and University of Bern, Bern, Switzerland

² Department of Clinical Research, University Hospital Bern, Bern, Switzerland

severe GO morbidity, patients with a moderate-to-severe degree require treatment ranging from nonsteroidal anti-inflammatory drugs (NSAIDs) to orbital irradiation and surgical decompression [5]. However, the mainstay treatment is steroids, which may cause significant side effects. For efficient treatment, an effective treatment monitoring is important.

Clinical assessment is the foundation for the diagnosis of GO and the clinical activity score (CAS) has emerged as a useful tool for assessing GO activity [6, 7].

In order to quantify disease activity, several imaging modalities have been described in the literature; sonography of the orbita is a fast and a non-invasive imaging method to determine the stage of GO on the basis of muscle thickness and reflectivity. However, sonography of the extraocular muscles has a long learning curve and the quality of this method is strongly dependent on the examiner's experience [4].

Magnetic resonance imaging (MRI) [8, 9] and computed tomography (CT) have been used to determine the degree of proptosis, mainly for surgical planning of elective orbital decompression. However, they are not useful for repetitive monitoring of disease activity [10].

In this study, we assess the usefulness of optical coherence tomography (OCT) to image the extraocular muscles in GO and whether it may serve as a tool to detect active GO.

Materials and methods

This study was approved by the local ethics commission (KEK 178/12) and conformed to the provisions of the Declaration of Helsinki. Informed consent was obtained in written form from each individual. The patients and subjects were recruited from the outpatient clinic of the Department of Ophthalmology at the University Hospital Bern, Switzerland. For each patient with GO, a questionnaire according to the guidelines of EUGOGO (European Group of Graves' Orbitopathy) was completed and the CAS was calculated by screening the patient for the following seven signs of activity: 1. moderate to severe active lid swelling, 2. eyelid erythema, 3. definite conjunctival redness, 4. chemosis, 5. caruncle or plical inflammation, 6. spontaneous orbital pain, 7. gaze-evoked orbital pain [6, 7].

To image the anterior segment of the eye, the 'anterior segment module' of a spectral domain OCT (SD OCT; Heidelberg Engineering GmbH, Heidelberg, Germany) was used. The zoom was set to zero and the program was changed to 'sclera mode' with enhanced depth imaging (EDI). Ambient light was reduced to nearly zero lux for noise reduction. The patient was asked to focus his eyes on the external fixation light which was mounted at an angle of 45° to the left and to the right, consecutively (see Fig. 1). The images were taken in 'grid mode' at high resolution. The grid was 30° wide and 5° high, resulting in 11 sections (278 μm between the sections; see Fig. 2a). Depending on the compliance of the patient, 9 or 16 frames were chosen. For the lateral rectus muscle, the grid was rotated by +5.5°, for the medial rectus (MR) muscle by -5.5°. These settings delivered high resolution images (1536 x 496 pixels) with a wide viewing angle and sections running parallel to the tendon. Infrared (IR) images were obtained at a resolution of 1536 x 1536 pixels.

Measurement sites were chosen at 8.7 mm from the limbus for the MR muscles and at 9.8 mm from the limbus for the LR muscles, according to the insertion site of the horizontal muscles. At these predefined sites, the thickness of three OCT scans were averaged. Care was given to not include the episclera and the conjunctiva in the muscle thickness measurements (Fig. 2a).

Statistically significant differences were determined using an unpaired two-tailed Student's test, and linear regression analysis was performed to correlate CAS with muscle thickness measurements. P values less than 0.05 were defined as statistically significant. GraphPad Prism version 5 for Windows (GraphPad Software Inc. La Jolla, California, U.S.A) was used to perform statistical data analysis.

Results

All study participants were female. The patient group included 15 women with a mean age of 48 years (± 15 years standard deviation [SD]), a mean weight of 69 kg (± 13.56 kg SD) and a mean height of 164 cm (± 7.6 cm SD). Of these 15 patients, 10 smoked or had stopped smoking recently.

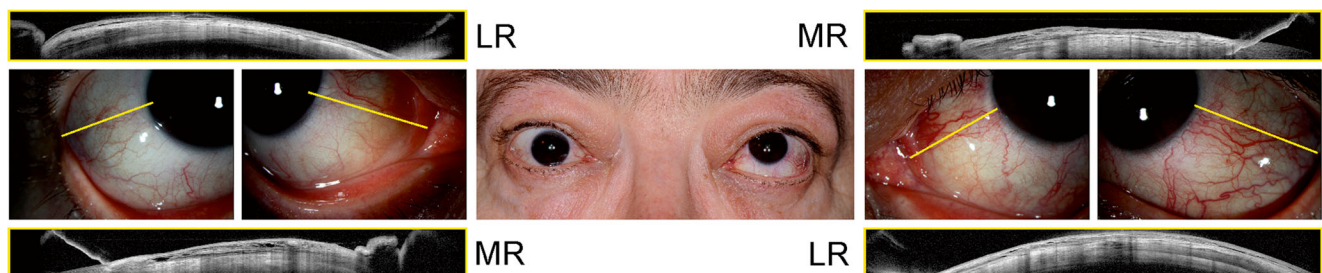

Fig. 1 Representative patient with graves orbitopathy. Both horizontal extraocular eye muscle insertions (LR=lateral rectus, MR=medial rectus) of both eyes (RE=right eye, LE=left eye) were imaged. OCT of LR (top) and MR (bottom)

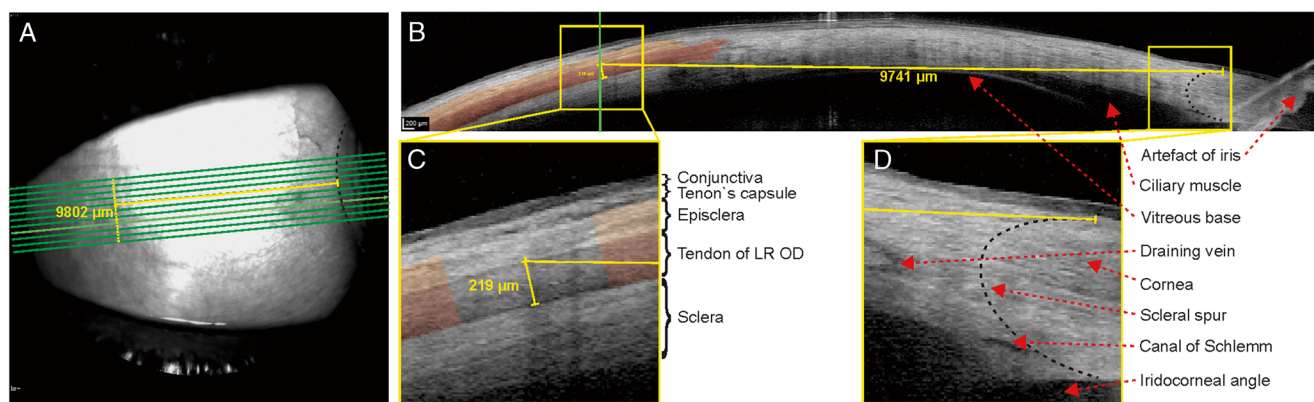


Fig. 2 EDI anterior segment imaging of the LR muscle. **a)** IR image of the LR eye muscle insertion of a healthy RE. Green lines correspond to the 11 OCT scans. The yellow dashed line marks the locations where tendon thickness was measured on the OCT scans, 9.8 mm (yellow solid line) from the limbus (black dashed line). **b)** AS-OCT scan

correlating to the bright green line on the IR image. Black dashed line marks the scleral spur. The reddish area highlights the muscle insertion while the orange area corresponds to the episclera on it. **c)** Enlarged illustration of the area 9.8 mm from the scleral spur. **d)** Enlarged area of the scleral spur

The control group of healthy volunteers included 12 women with a mean age of 56 years (± 16.0 years SD), a mean weight of 71 kg (± 17.4 kg SD) and a mean height of 166 cm (± 6.7 cm SD). Seven women smoked.

The CAS of all controls was 0 with no history of thyroid disease. In the patient group, three patients had a CAS of zero, four patients had a CAS of 1, three patients had a CAS of 2, one patient each had a CAS of 3 and 4, and three patients had a CAS of 6.

The mean thickness of the tendon of the MR muscle in the GO group was $256.4 \mu\text{m}$ ($\pm 17.13 \mu\text{m}$ SD), significantly thicker than the same region of the MR in the healthy group with a mean value of $214.7 \mu\text{m}$ ($\pm 5.52 \mu\text{m}$ SD) ($p=0.0$; Fig. 3). Correlation of the CAS with the thickness of the MR at the area of insertion was significant (see Fig. 4, $R^2=0.5$, $p=0.0027$). The thickness at the insertion site of the LR (mean of LR OD and LR OS) on the other hand was not significantly different between the GO group ($263.8 \mu\text{m} \pm 57.69 \mu\text{m}$ SD) and the healthy group ($254.9 \mu\text{m} \pm 8.59 \mu\text{m}$ SD; $p=0.6$).

Discussion

In this study, we found that the tendons of the horizontal recti muscles can be readily imaged with AS-OCT. We show that the MR muscle insertion area shows significant thickening in patients with GO. To the best of our knowledge, this is the first paper to provide evidence about the use of AS-OCT in GO.

A myriad of clinical signs have been described to assess the activity of GO in patients. Vascular injection around the insertion sites of the extraocular muscles has been described as the Topolanski’s sign. Swelling of the extraocular muscles has proven as a valuable tool to distinguish an acute inflammatory active disease from an inactive disease by demonstrating interstitial oedema within the extraocular muscles. Several imaging modalities have been proposed to monitor muscle swelling, including ultrasonography.

Ultrasound uses high frequencies of up to 8 MHz and, therefore, offers excellent penetration into the orbit. However, orbital ultrasound is not widely available and has

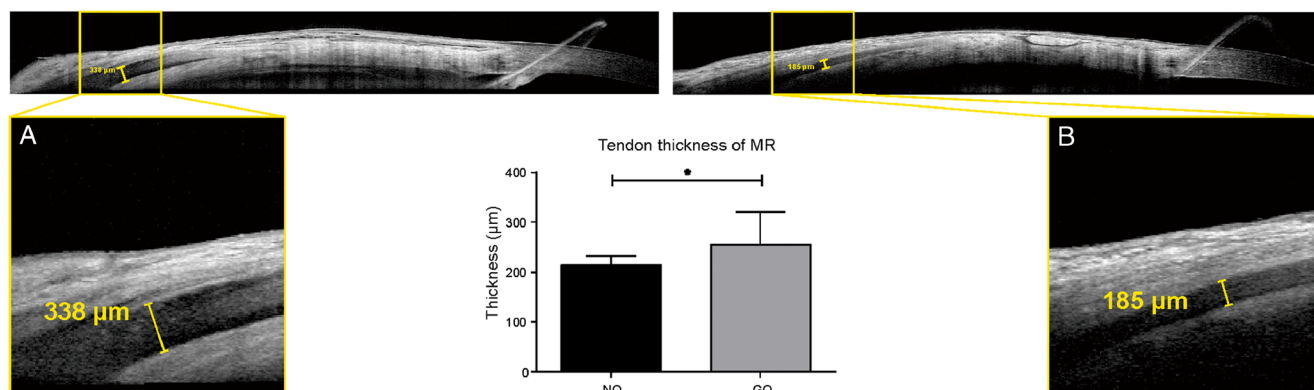


Fig. 3 Thickness of the horizontal muscle at the insertion site measured by EDI AS-OCT. **a)** Measurement of MR of the RE of a GO patient. **b)** Measurement of MR of the RE of a healthy subject (NO). The graph

shows the mean tendon thickness measured in the patient group (GO, $n=15$) and subject group (NO, $n=12$). $*p < 0.05$

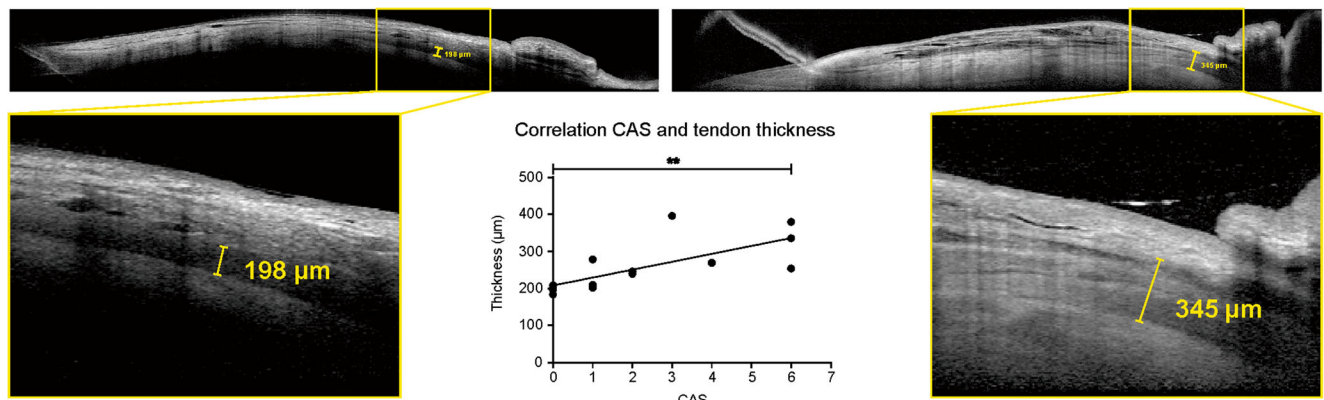


Fig. 4 Correlation between the CAS and thickness of horizontal muscle at the insertion site in GO patients measured with EDI AS-OCT. A) OCT scan of a GO patient with CAS 1. B) OCT scan of a GO patient with CAS 6 (n=15, p=0.0027)

a high intra- and interobserver variability in the measurements of muscle thickness [4]. With the increasing popularity of OCT for retinal diseases, OCT has become a widely available tool for ophthalmologist. The noninvasive, noncontact imaging modality of OCT can acquire cross-sectional scans of the anterior segment and has been used to image the anterior chamber angle as an adjunct diagnostic tool for glaucoma specialists [11, 12] and has become an increasingly popular tool for imaging the cornea [13, 14]. EDI OCT uses the same wavelength of light as conventional retinal OCT, namely 830 nm, and, therefore, only offers limited penetration of the sclera. Using EDI, the OCT probe is placed closer to the eye than normal, resulting in an inverted image with the most tightly focused illumination at the level of the sclera, allowing for better penetration of the scleral tissue. Using EDI OCT we were able to identify the lower end of the horizontal recti muscle tendon as a sharply defined border to the sclera. However the border between the tendon and episclera was sometimes difficult to determine, especially at the muscle insertion into the sclera. A recent report [15] using AS-OCT, showed the mean limbus-insertion distance to be about

5.7 mm for the MR muscles and 6.8 mm for the LR muscles. Adding 3 mm to these distances provided us with a clearly defined measuring point in the muscle insertion area. Consequently, we determined the thickness of the horizontal eye muscle insertions. In order to perform reliable thickness measurements, we measured the muscle 3 mm posterior to the insertion site.

Our study has several limitations, including the small number of and the low clinical activity score in our patients. Nevertheless, even with this small study group, we could find significant differences in thickness of the distal end of the MR muscle between the GO group and the healthy controls. The preponderance for the involvement of the MR muscle in GO is in keeping with previously published data [4]. However, we are not aware of any previous report using OCT showing that the tendinous area of the insertion site is affected in GO. In fact, radiological studies based on CT found that swelling of the extraocular muscles generally occurs within their bellies with sparing of the tendons [16]. This is not contradictory to our findings, as our finding of a greater thickness of about 60 microns is far beyond the detection level of conventional

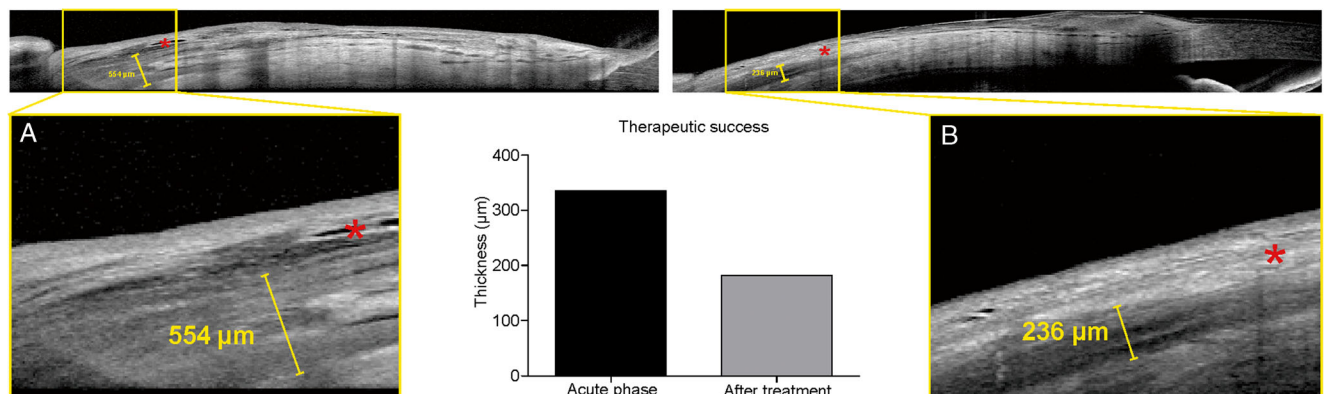


Fig. 5 Response to treatment in a patient with active GO using EDI AS-OCT. A) OCT scan before therapy start. Mean tendon thickness of both MR muscles was 336 μm. B) OCT scan two months after therapy start.

Mean tendon thickness of both MR muscles was 182 μm. The red asterisk in A marks chemosis which showed resolution after therapy

MRI. In one patient, we were able to obtain longitudinal EDI OCT before and after therapy with corticosteroids. Here, the OCT images showed a dramatic reduction of thickness of the MR muscle over the course of two months (see Fig. 5).

This suggests that AS-OCT may not only be used for diagnosis of GO but can be used to monitor the therapeutic response as well.

Conflict of interest The authors acknowledge the use of the facilities and scientific and technical assistance of the Department for Clinical Research (DCR) of the University of Bern. These studies were supported by grants from the Inselspital Bern and the OPOS Foundation. Dr. Zinkernagel has served as a speaker for and has received funding from Heidelberg Engineering GmbH, Germany

References

- Piantanida E, Tanda ML, Lai A, Sassi L, Bartalena L (2013) Prevalence and natural history of Graves' orbitopathy in the XXI century. *J Endocrinol Invest* 36:444–449
- Verity DH, Rose GE (2013) Acute thyroid eye disease (TED): principles of medical and surgical management. *Eye (Lond)* 27:308–319
- Eckstein A, Esser J (2011) Graves' orbitopathy. *Klin Monbl Augenheilkd* 228:432–438
- Daubner D, Spieth S, Engellandt K, von Kummer R (2012) Diagnosis and differential diagnosis of Graves' orbitopathy in MRI. *Radiologie* 52:550–559
- Johnson KT, Wittig A, Loesch C, Esser J, Sauerwein W, Eckstein AK (2010) A retrospective study on the efficacy of total absorbed orbital doses of 12, 16 and 20 Gy combined with systemic steroid treatment in patients with Graves' orbitopathy. *Graefes archive for clinical and experimental ophthalmology = Albrecht von Graefes Archiv fur klinische und experimentelle. Ophthalmologie* 248:103–109
- Bartalena L, Baldeschi L, Dickinson A, Eckstein A, Kendall-Taylor P, Marcocci C, Mourits M, Perros P, Boboridis K, Boschi A, Curro N, Daumerie C, Kahaly GJ, Krassas GE, Lane CM, Lazarus JH, Marino M, Nardi M, Neoh C, Orgiazzi J, Pearce S, Pinchera A, Pitz S, Salvi M, Sivelli P, Stahl M, von Arx G, Wiersinga WM (2008) Consensus statement of the European Group on Graves' orbitopathy (EUGOGO) on management of GO. *Eur J Endocrinol* 158:273–285
- Mourits MP, Prummel MF, Wiersinga WM, Koornneef L (1997) Clinical activity score as a guide in the management of patients with Graves' ophthalmopathy. *Clin Endocrinol (Oxf)* 47:9–14
- Kvetny J, Puhakka KB, Rohl L (2006) Magnetic resonance imaging determination of extraocular eye muscle volume in patients with thyroid-associated ophthalmopathy and proptosis. *Acta Ophthalmol Scand* 84:419–423
- Nishida Y, Tian S, Isberg B, Hayashi O, Tallstedt L, Lennerstrand G (2002) Significance of orbital fatty tissue for exophthalmos in thyroid-associated ophthalmopathy. *Graefes archive for clinical and experimental ophthalmology = Albrecht von Graefes Archiv fur klinische und experimentelle. Ophthalmologie* 240:515–520
- Campi I, Vannucchi GM, Minetti AM, Dazzi D, Avignone S, Covelli D, Curro N, Ratiglia R, Guastella C, Pignataro L, Beck-Peccoz P, Salvi M (2013) A quantitative method for assessing the degree of axial proptosis in relation to orbital tissue involvement in Graves' orbitopathy. *Ophthalmology* 120:1092–1098
- Wang J, Abou Shousha M, Perez VL, Karp CL, Yoo SH, Shen M, Cui L, Hurmeric V, Du C, Zhu D, Chen Q, Li M (2011) Ultra-high resolution optical coherence tomography for imaging the anterior segment of the eye. *Ophthalmic Surg Lasers Imaging* 42(Suppl): S15–27
- Nolan WP, See JL, Chew PT, Friedman DS, Smith SD, Radhakrishnan S, Zheng C, Foster PJ, Aung T (2007) Detection of primary angle closure using anterior segment optical coherence tomography in Asian eyes. *Ophthalmology* 114:33–39
- Sayegh RR, Pineda R 2nd (2012) Practical applications of anterior segment optical coherence tomography imaging following corneal surgery. *Semin Ophthalmol* 27:125–132
- Ramos JL, Li Y, Huang D (2009) Clinical and research applications of anterior segment optical coherence tomography - a review. *Clin Exp Ophthalmol* 37:81–89
- Liu X, Wang F, Xiao Y, Ye X, Hou L (2011) Measurement of the limbus-insertion distance in adult strabismus patients with anterior segment optical coherence tomography. *Invest Ophthalmol Vis Sci* 52:8370–8373
- Trokel SL, Jakobiec FA (1981) Correlation of CT scanning and pathologic features of ophthalmic Graves' disease. *Ophthalmology* 88:553–564