


The effect of pregnancy on endometriosis—facts or fiction?

Brigitte Leeners ^{1,*}, Fabia Damaso¹, Nicole Ochsenbein-Kölble², and Cindy Farquhar³

¹Department of Reproductive Endocrinology, University Hospital Zurich, 8091 Zurich, Switzerland ²Department of Obstetrics, University Hospital Zurich, 8091 Zurich, Switzerland ³Department of Gynaecology and Obstetrics, University Hospital Auckland, Park Road, 1023 Auckland, New Zealand

*Correspondence address. Department of Reproductive Endocrinology, University Hospital Zurich, Frauenklinikstr. 10, CH 8091 Zurich, Switzerland. Tel: +41-44-255-5009; Fax: +41-44-255-4376; E-mail: Brigitte.Leeners@usz.ch  orcid.org/0000-0003-4027-6151

Submitted on September 15, 2017; resubmitted on December 9, 2017; editorial decision on January 17, 2018; accepted on February 3, 2018

TABLE OF CONTENTS

- Introduction
- Methods
- Results
 - Studies in pregnant women that report endometriosis before, during and/or after pregnancy
 - Factors influencing the development of endometriosis in pregnancy
 - Morphological changes of endometriotic lesions in pregnancy
 - Effect of pregnancy on endometriosis-associated pain
 - Endometriosis-related pregnancy complications
 - Histology of endometriotic lesions in pregnancy
 - Long-term effects of pregnancy on endometriosis and disease recurrence after delivery and lactation
- Discussion
- Conclusion

BACKGROUND: It is not uncommon for women with endometriosis to be advised that becoming pregnant might be a useful strategy to manage their symptoms and reduce disease progression. Consequently, many women diagnosed with endometriosis and motivated to become pregnant, may also have expectations regarding improvement of symptoms and the disease. However, study results on the effect of pregnancy on endometriosis are controversial and pregnancy in women with endometriosis is not always associated with improved symptoms. Moreover, there is increasing evidence that endometriosis may interfere with a successful pregnancy outcome.

OBJECTIVE AND RATIONALE: The objective was to evaluate the evidence on whether pregnancy and lactation has a beneficiary effect on growth characteristics and symptoms of endometriosis diagnosed prior to pregnancy.

SEARCH METHODS: A search for articles containing keywords related to pregnancy and endometriosis was performed via PubMed. Manuscripts dealing with a potential effect of pregnancy on endometriosis were systematically reviewed. We included English, French and German language publications on human studies from 1966 to May 2017. Bibliographies of these manuscripts were searched for further relevant literature.

OUTCOMES: Five small observational studies were identified concerning the longitudinal development of endometriotic lesions during and after pregnancy, four of medium and one of low quality. Eleven publications reported measurements of endometriomas during pregnancy and the postpartum period (the five studies just mentioned and six case reports). Another 22 case reports/small case series (maximum of five cases), six studies on histology of endometriotic lesions in pregnancy, plus eight studies on the role of pregnancy in initial

development and recurrence of endometriosis were included. Few studies of very limited quality are available to evaluate the effect of pregnancy and the postnatal period on the development of endometriosis. The development of endometriosis is variable and there is no evidence that pregnancy can be expected to generally reduce the size and number of endometriotic lesions. Growth and structural changes of lesions during pregnancy may occur with decidualization. Results on the association between pregnancy and symptoms of endometriosis are controversial and strongly biased.

WIDER IMPLICATIONS: Available data on the development of endometriosis during and after pregnancy show fewer beneficial effects than previously reported. Therefore, women aiming for pregnancy on the background of endometriosis should not be told that pregnancy may be a strategy for managing symptoms and reducing progression of the disease.

Key words: pregnancy / endometriosis / pain / decidualization / recurrence / pathophysiology

Introduction

For over a century, pregnancy has been considered to have beneficial effects on endometriosis, and 'pseudopregnancy' induced through hormonal therapies has been recommended as a way to manage symptoms. The coexistence of endometriosis and pregnancy was first described in 1904–1905 (Olshausen, 1904; Amos, 1905). In the early 1920s, regression of endometriosis cysts during pregnancy (Sampson, 1922, 1924) or during lactation (Meigs, 1922) was observed in small case series. Beecham (1949) declared pregnancy as an efficient prophylactic and curative measure against endometriosis. The increased prevalence of endometriotic lesions in women with few children compared to women with many children supported this theory (Meigs, 1922). These observations were the basis of the 'pseudopregnancy' approach with progesterone as a treatment for endometriosis in the late 1950s (Kistner, 1959a,b). Even now, progestogens are an important treatment to manage endometriosis (Dunselman et al., 2014). The occurrence of endometriosis-related symptoms only after menarche, when the menstrual cycle had commenced, and the regression of symptoms after menopause were used as further arguments for a beneficial effect of pregnancy (Bulun, 2009).

Regression of endometriosis in pregnancy has been attributed to pregnancy-related hormonal changes (diZerega et al., 1980; Cummings and Metcalf, 1996; Porpora et al., 2010; Coccia et al., 2012; Benaglia et al., 2013; Bilotas et al., 2015), and consequently led to recommending pregnancy as a therapeutic strategy (Meigs, 1953; Rubegni et al., 2003; Benagiano et al., 2014; Brosens et al., 2016). Assuming the development of endometriosis through 'transplantation' of endometrium fragments, the interruption of the menstrual cycles has been considered as a mechanism to explain an eventual beneficial effect of pregnancy on endometriosis (Eskenza and Warner, 1997; Missmer et al., 2004).

The estimated prevalence of ovarian endometriomas among women diagnosed with endometriosis is 17–20% (Redwine, 1999), and endometriomas account for 4–5% of ovarian tumours detected in early pregnancy (Condous et al., 2004) resulting in an overall frequency of endometriomas in pregnancy of 0.05–0.5% (Bromley and Benacerraf, 1997; Sherard et al., 2003; Zanetta et al., 2003; Condous et al., 2004; Yazbek et al., 2007; Ueda et al., 2010). The increasing use of first trimester transvaginal ultrasound has recently led to higher detection rates of endometriomas in pregnancy (Fruscella et al., 2004; Pateman et al., 2014; Bailleux et al., 2015). In one study (Ueda et al., 2010), ovarian endometriomas were the most common adnexal mass detected during

pregnancy with a strong increase in detection rates during the most recent study period. However, the prevalence of endometriosis in pregnancy might be far higher and in a series of 208 unselected women undergoing tubal sterilization (101 in combination with termination of an unwanted pregnancy), endometriosis was detected in 16% of the pregnant and 22% of the non-pregnant women (Moen and Muus, 1991). Taken together, the available studies on the prevalence of endometriosis are limited by detection and selection biases, as symptomatic women are more likely to present for assessment, and not all women will have the same access to surgery, which remains the gold standard for confirmation of endometriosis (Dunselman et al., 2014). The growing success rates of ART in women with endometriosis (Ueda et al., 2010; Dunselman et al., 2014), will undoubtedly increase the co-occurrence of pregnancy and endometriosis. With this in mind, we need to report the impact of pregnancy on the development of endometriosis in order to inform women with endometriosis of the likely benefits and harms of a pregnancy.

Despite intensive research and promising new strategies to improve treatment options, treatment success in endometriosis is still rather limited. Following laparoscopic surgery, recurrence has been observed in 7–30% of patients within 3 years, and 40–50% after 5 years (Seracchioli et al., 2010). Recurrence in endometriosis only treated by medications reaches up to 50% within the first 2 years following treatment (Nisolle-Pochet et al., 1988; D'Hooghe et al., 2004). Endometrioma recurrence affects between 12 and 32% of women, and pain reappears in 34–73% (Busacca et al., 1999, 2006; Koga et al., 2006; Liu et al., 2007). As current long-term treatment success rates are rather frustrating, it is important to consider future areas of research. Pregnancy represents a unique *in vivo* model to investigate the growth dynamics of endometriotic lesions in a specific hormonal, immunological and metabolic environment.

Although women with endometriosis may have been encouraged to consider pregnancy as part of their efforts to reduce endometriosis and its symptoms, a recent review (Leone Roberti Maggiore et al., 2016) reported that endometriotic lesions in pregnancy are associated with a range of obstetric problems.

The objective of our review is to summarize all the available epidemiological studies on the effect of pregnancy and lactation on endometriosis. Findings are here presented on disease progression during and after pregnancy as well as the effect of pregnancy on symptom remediation.

Methods

A literature search of the PubMed database was performed including studies from 1966 until May 2017 in English, German and French. To investigate the effect of pregnancy on the development of endometriosis, the search terms were the following: 'endometriosis' or 'endometrioma' or 'endometriotic'; 'pregnancy'; 'other': cyst, decidualized, decidualization, postpartum, prevalence, sono-morphology, sonography, pain, lactation, breast-feeding and amenorrhoea. An 'endometriosis' set element AND a 'pregnancy' set element were always included in title, abstract or all fields, where capital letters indicate Boolean connectors. We searched for either these two terms alone or together with one of the remaining set elements ('other') in the title. All studies were screened by the abstract and title. Eligible articles were read and the relevant information was extracted. References of these articles were also screened, to identify relevant secondary literature. The main inclusion criterion for clinical results was relevant information about the impact of pregnancy on the development of endometriosis. Studies on the reverse question (i.e. the effect of endometriosis upon pregnancy and pregnancy complications) were not part of the present review (Leone Roberti Maggiore et al., 2016). However, to present our findings in the context of counselling women who consider a pregnancy in the context of endometriosis, we also include some key findings on endometriosis-related pregnancy complications in the discussion. We included observational studies irrespective of the number of included cases.

We used a quality assessment tool for non-randomized studies (the Strengthening the Reporting of Observational Studies in Epidemiology—STROBE) (von Elm et al., 2007), which we applied to the observational studies with the exception of case reports of small series. This tool was applied by one of the authors (B.L.).

Results

Five observational studies that included a total of 141 study participants were identified (McArthur and Ulfelder, 1965; Ueda et al., 2010; Benaglia et al., 2013; Pateman et al., 2014; Bailleux et al., 2015) and four were of medium and one of low quality according to the STROBE criteria (von Elm et al., 2007) (Table I). We also included 28 case reports or small case series and six studies on decidualization and histology of endometriotic lesions in pregnancy, as well as eight

studies on the role of pregnancy in the initial development and recurrence of endometriosis.

Studies in pregnant women that report endometriosis before, during and/or after pregnancy

Regression and disappearance

There were five studies on growth characteristics of endometriotic lesions during pregnancy and the postpartum period (Table I). A summary of all findings on the development of endometrioma (e.g. lesions for which exact sonographic measurements were available) from both cohort studies and case reports is presented in Table II. Some of the lesions regressed or even disappeared completely, while others remained stable or increased during pregnancy. Altogether, 15–50% of the lesions disappeared completely (Ueda et al., 2010; Benaglia et al., 2013; Bailleux et al., 2015) and 34–64.7% regressed in pregnancy (Pateman et al., 2014; Bailleux et al., 2015). Several case reports also report regression of endometrioma in pregnancy (Gregora and Higgs, 1998; Guerriero et al., 2005). A reduction in lesion size has also been reported in non-ovarian lesions such as the bladder or the umbilicus (Müller, 1939; Rubegni et al., 2003; Razzi et al., 2004).

Several early case reports describe regression of endometriotic lesions during the early puerperium (Hay, 1939; Portes and Varangot, 1939; Portes et al., 1939; Mocquot and Musset, 1949). Gainey (Gainey et al., 1952) recorded a marked involution of endometriosis 8 months postpartum in a non-breast feeding woman. A recent study demonstrated reduction of lesion sizes of between 45.9 and 88.5% in 16% of the women who attended for postnatal scans, i.e. in 84% of the women lesions did not regress (Pateman et al., 2014). Also, lesions gradually decreased and/or disappeared after delivery in four cases managed expectantly with follow-up by MRI for 1 year or more (Takeuchi et al., 2008). In agreement with these findings, 40% of the suspected endometriomas visualized prior to successful IVF could not be detected 12–18 months after pregnancy (Benaglia et al., 2013). In the same study the number of ovarian cysts was reduced in three cases (13%), but 8% of the women developed additional lesions up until 12–18 months after delivery. Unfortunately, there is no information on whether these lesions developed during or after pregnancy. Altogether, the few

Table I Studies on the longitudinal development of endometriotic lesions during pregnancy and the postnatal period.

Study	N pregnant women	N endometriotic lesions	Type of lesion	Focus on development of endometriosis in pregnancy	Time of investigation	Type of study	Study quality ^a
Bailleux et al. (2015)	46	53	Ovarian endometriosis	Yes	2004–2013	Retrospective cohort study	Medium
Benaglia et al. (2013)	24	40	Ovarian endometriosis	No: one measurement in and one measurement 3–9 months after pregnancy	2006–2008	Prospective cohort study	Medium
McArthur and Ulfelder (1965)	23	25	Any type of lesion	Yes	1913–1965	Review	Low
Pateman et al. (2014)	24	34	Ovarian endometriosis	Yes	2009–2013	Retrospective cohort study	Medium
Ueda et al. (2010)	24	25	Ovarian endometriosis	Yes	1996–2007	Retrospective cohort study	Medium

^aQuality was assessed using the Strengthening the Reporting of Observational Studies in Epidemiology (STROBE) criteria (von Elm et al., 2007).

Table II Summary of findings on the development of endometrioma.

Study	N	Time of investigation	Increase n (%)	No change n (%)	Decrease, n (%)	Disappearance n (%)	Study quality
Bailleux <i>et al.</i> (2015)	33	Second trimester	8 (24)	9 (27)	11 (34)	5 (15)	Medium
	13	Third trimester	5 (39)	1 (17)	5 (39)	2 (15)	
	15	Postpartum	1 (7)	5 (33)		9 (60)	
Gregora and Higgs (1998)	2	Second trimester	2 (100)				Low
Pateman <i>et al.</i> (2014)	34	Whole pregnancy	3 (8)	9 (27)	22 (65)		Medium
Ueda <i>et al.</i> (2010)	25	Every 4–8 weeks from prior to pregnancy/first trimester till surgery (N = 3) or postpartum period (N = 22)	5 (20)	7 (28)	13 (52)		Medium
Benaglia <i>et al.</i> (2013)	24	Postpartum	2 (8) ^a	8 (33) ^a	3 (13) ^a	11 (46) ^a	Medium
Phupong <i>et al.</i> (2004)	1	Second and third trimester				1 (100)	Low
Iwamoto <i>et al.</i> (2006)	1	Second trimester	1 (100)				Low
McArthur and Ulfelder (1965)	16	First trimester	12 (75)	0 (0)	4 (25)		Low
	14	Second trimester	5 (36)	1 (7)	8 (57)		
	11	Third trimester	2 (18)	0 (0)	9 (82)		
	15	Postpartum	6 (40)	1 (7)	8 (53)		
Fruscella <i>et al.</i> (2004)	2	Second trimester	2 (100)				Low
Guerrero <i>et al.</i> (2005)	2	Whole pregnancy	1 (50)	1 (50)			Low
Miyakoshi <i>et al.</i> (1998)	1	Second trimester	1 (100)				Low
Sammour <i>et al.</i> (2005)	2	Second trimester	1 (50)	1 (50)			Low
Garcia-Velasco <i>et al.</i> (1998)	1	First trimester	1 (100)				Low
Coccia <i>et al.</i> (2012)	3	First, second and third trimester	1 (33)		2 (67)		Low

^aReduction in number of cysts (not size).

available, and methodologically very different, studies on the development of endometriotic lesions in the lactation period allow no final conclusion to be reached on the effect of breast feeding on the biological behaviour of endometriosis.

Progression

Between 8.8 and 39% (Ueda *et al.*, 2010; Bailleux *et al.*, 2015; Pateman *et al.*, 2014) of endometriomas increase during pregnancy. Different case reports describe growth of endometriotic lesions with subsequent surgical interventions during pregnancy (Garcia-Velasco *et al.*, 1998; Fruscella *et al.*, 2004; Gregora and Higgs, 1998; Miyakoshi *et al.*, 1998; Phupong *et al.*, 2004; Sammour *et al.*, 2005; Ueda *et al.*, 2010). Lesions ultimately resulting in haemorrhage seem to be able to develop during pregnancy even without any prior evidence of endometriosis (Bashir *et al.*, 1995). Growth of non-ovarian lesions during pregnancy may occur in the abdominal cavity, the bladder and the umbilicus (McArthur and Ulfelder, 1965; Chertin *et al.*, 2007; Wiegratz *et al.*, 2008). However, pregnancy-related abdominal distension might facilitate diagnosis of otherwise asymptomatic umbilical nodules (Rubegni *et al.*, 2003). Lesions may also increase initially and regress later (Ueda *et al.*, 2010). Endometriosis seems to be capable of lymphatic spread, even during pregnancy (Beavis *et al.*, 2011).

Stability

Just over 25% of endometriomas are reported to be unchanged during pregnancy (Ueda *et al.*, 2010; Pateman *et al.*, 2014; Bailleux *et al.*,

2015). Case reports of pregnant women with deep infiltrating lesions in the retroperitoneal space, or endometriomas, similarly reported a lack of clinical or morphological changes in pregnancy (Skidmore *et al.*, 1996; Guerrero *et al.*, 2005; Coccia *et al.*, 2012).

Factors influencing the development of endometriosis in pregnancy

While demographic factors, such as patients' age, have no influence on the development of endometriotic lesions during pregnancy (Ueda *et al.*, 2010), a variety of pregnancy- and endometriosis-associated factors seem to be involved.

Gestational age

Regression of endometriotic lesions has been reported to occur in all trimesters (Bailleux *et al.*, 2015). In the few available human studies, the identification of significant regression of endometriotic lesions in the first trimester was rare but more likely in the second/third trimester or even in the lactation period (Gainey *et al.*, 1952; McArthur and Ulfelder, 1965; Ueda *et al.*, 2010; Bailleux *et al.*, 2015).

Disease stage

Moen and Muus (1991) found an earlier stage of endometriosis in women with an unwanted pregnancy than in non-pregnant women, when performing laparoscopic sterilization. As it seems unlikely that fibrosis and pigmentation disappear in the first 3 months of gestation, the authors assume that differences in endometriosis stages are likely

a result of advanced endometriosis causing infertility. For the interpretation of these results, we note that women undergoing sterilization are almost always multiparous.

Initial size of lesion

The initial size of an endometriotic lesion seems to be unrelated to future development throughout pregnancy (Ueda et al., 2010). Cysts reported to have vanished during pregnancy were rather small (15 ± 5 mm) in one study (Benaglia et al., 2013), but another study reported a decrease in 34%, or disappearance in 15% out of 46 ovarian cysts, with 98% of them being <100 mm (Bailleux et al., 2015). Unfortunately, the authors did not reveal more detailed information on differences in initial size between lesions which regressed and those which remained stable or increased.

Histological characteristics

Specific histological characteristics might explain variability in the development of endometriotic lesions during pregnancy (Barbieri et al., 2009; Ueda et al., 2010; Benaglia et al., 2013). For example, only lesions prone to decidualization or possessing a certain quantity of mucosa may shrink and vanish (Brosens et al., 2009a; Ueda et al., 2010; Benaglia et al., 2013). This is in accordance with endometriosis in some cases not responding to either normal cyclic variations in hormones (Bergqvist et al., 1984; Brosens et al., 1987; Metzger and Haney, 1988) or to exogenous hormonal therapy (Yap et al., 2004; Dunselman et al., 2014).

Morphological changes of endometriotic lesions in pregnancy

In pregnancy, endometriotic lesions may undergo extensive changes in dimension, structure and vascularization, which hamper their differentiation from malignant ovarian tumours (Barbieri et al., 2009; Pateman et al., 2014; Leone Roberti Maggiore et al., 2016). Lesions may become more homogeneous and less fibrotic-like with less evident limits of nodules and band-like echoes (Coccia et al., 2012). Sono-morphological changes may be reversible (Barbieri et al., 2009). The frequency of sono-morphological changes seems to vary between 0 and 12% (Ueda et al., 2010; Benaglia et al., 2013). In addition, the type of lesions seems to be associated with pregnancy. Women presenting for sterilization in combination with termination of an unwanted pregnancy presented with more superficial, non-pigmented, gland-like lesions than a non-pregnant comparison group (Moen and Muus, 1991).

Effect of pregnancy on endometriosis-associated pain

Pregnancy has been reported to relieve endometriosis-related pain (Missmer et al., 2004; Koga et al., 2006; Barbieri et al., 2009; Porpora et al., 2010; Coccia et al., 2012). Small series and case reports support the resolution of symptoms, e.g. in deep infiltrating endometriosis or cervical endometriosis during and after pregnancy (Ganesh and Chakravarty, 2007; Coccia et al., 2012). However, it remains an open question as to the association between endometriosis and pain during pregnancy, and subfertility biases this effect. Pregnancy following endometriosis surgery is also associated with a reduction of pain (Porpora et al., 2010). A long-term study on risk factors for the recurrence of endometriosis-associated pain after

surgery showed no differences in pregnancy rates between women developing recurrence of pain symptoms and those who remained pain-free (Coccia et al., 2011). While Müller (1939) describes a case with regression of endometriosis-associated dysuria in pregnancy, Chertin et al. (2007) presents a case of increasing dysuria during pregnancy as a result of a growing decidualized endometriotic lesion in the bladder. Rectal and umbilical endometriosis appears to be associated with increased pain during pregnancy (Ganesh and Chakravarty, 2007; Wiegratz et al., 2008). Of 14 pregnant women with endometriosis-associated pain, but without either endometriomas or adenomyosis, three women described a loss or decrease of pain and two women an increase of pain in association with pregnancy (McArthur and Ulfelder, 1965). In 7–33% of women diagnosed with endometriosis, endometriosis-associated pain was the reason for evaluation of the ovaries in pregnancy (Pateman et al., 2014; Bailleux et al., 2015). Available studies lack information on the chronological development of endometriosis-related pain and the duration of symptom remediation during pregnancy and following delivery, which limits our understanding of the possible effect of pregnancy on endometriosis-related pain. Altogether, the results on the correlation between pregnancy and endometriosis-associated pain are controversial and there is no evidence that pregnancy will generally help to reduce endometriosis-associated pain.

Endometriosis-related pregnancy complications

Pregnancy complications caused by endometriosis have recently been reviewed by Leone Roberti Maggiore et al. (2016). The most frequent complications were:

- rupture of endometriomas
- intestinal perforation (colon, appendix, sigmoid)
- spontaneous hemoperitoneum/rupture of uterine and non-uterine blood vessels
- infection of endometrioma/development of (ovarian) abscess/appendicitis
- uterine haemorrhage
- spontaneous pneumothorax
- uroperitoneum
- rupture of fallopian tubes.

Enlargement of endometrioma and changes of sonographic morphology are the most frequent reasons for surgical interventions during pregnancy. The risk for placenta praevia is increased by a factor of nine, especially in case of rectovaginal endometriosis. With regard to perinatal outcome, some studies support the association between endometriosis and an increased risk for spontaneous miscarriage (Corson, 1986), preterm birth, small for gestational age babies, uterine rupture and the necessity of a caesarean section (Leone Roberti Maggiore et al., 2016). Also, subfertility has been associated with adverse pregnancy outcome (Luke et al., 2017).

Histology of endometriotic lesions in pregnancy

Decidualization

Decidualization includes the increase of glandular epithelial secretion, vascular remodelling, accumulation and adaptation of immune cells, as

well as the differentiation of stromal fibroblasts into large, round secreting epitheloid decidual cells (Gellersen *et al.*, 2007; Barbieri *et al.*, 2009; Brosens *et al.*, 2009b; Canlorbe *et al.*, 2012). Molecular alterations involve adhesion, angiogenesis, steroid receptor expression, steroid metabolism, cell cycle regulation, changes in extracellular matrix, and expression of growth factors, cytokines and their receptors (Gellersen and Brosens, 2003; Kobayashi *et al.*, 2014). Interestingly, the expression patterns of the endometriosis-associated genes resemble those of the decidualization process (Kobayashi *et al.*, 2014). However, more than half of the steroid hormone-regulated genes overexpressed in decidualization are prominently down-regulated in endometriosis. In contrast, a majority of adhesion molecules involved in decidualization to prepare for implantation of a blastocyst are also elevated in endometriosis.

An early literature review reported decidual formation in 40–100% of ovarian biopsies, and 65% of examinations from the posterior uterine serosa in pregnancy (Scott, 1944). A more recent study depicted a decidual reaction in 31% of peritoneal biopsies from pregnant women without verified endometriosis (Moen and Muus, 1991). Decidualization is often associated with an increase in size of endometriotic lesions (Fruscella *et al.*, 2004; Pateman *et al.*, 2014). It may lead to sono-morphological changes, which are difficult to distinguish from the characteristics of malignant lesions, e.g. thick and irregular inner walls, papillary projections and high vascularity on Doppler examination (Pateman *et al.*, 2014) (Fig. 1).

Although endometriotic lesions in pregnancy may present a decidual reaction similar to changes in the eutopic endometrium (Flieder *et al.*, 1998; Fair *et al.*, 2000; Beavis *et al.*, 2011; Leone Roberti Maggiore *et al.*, 2016), not all endometriotic lesions seem to decidualize during pregnancy (Moen and Muus, 1991; Setúbal *et al.*, 2014; Leone Roberti Maggiore *et al.*, 2016). Depending on the diagnostic criteria applied, decidualization can be demonstrated in up to 77% of endometriomas, with a broad range between 0 and 77%, and also in peritoneal, cutaneous, vesical and pulmonary endometriotic lesions (Moen and Muus, 1991; Ueda *et al.*, 2010; Pateman *et al.*, 2014; Bailleux *et al.*, 2015; Leone Roberti Maggiore *et al.*, 2016; Lier *et al.*, 2017).

Some authors assume that initial enlargement of endometriotic lesions as a consequence of decidualization and infiltration with immune cells is the first step towards ultimate regression (Takeuchi *et al.*, 2008; Barbieri *et al.*, 2009; Ueda *et al.*, 2010; Benaglia *et al.*, 2013). The strongly decreased ability of decidualized tissue to transplant with ongoing gestation (Scott and Te Linde, 1954) will likely reduce the risk of developing new lesions.

Atrophy and necrosis

Histopathological studies of endometriotic lesions during human pregnancy show an atrophic epithelial lining (Clement, 1977; Nakatani *et al.*, 1987; Razzi *et al.*, 2004), which is surrounded by nodules of strongly decidualized endometrial stroma, oedema and haemorrhagic changes from the mucosal lining to the serosal surface of the lesion (Schweitzer *et al.*, 2006). A tendency towards fibrosis has been described (McArthur and Ulfelder, 1965; Schenken *et al.*, 1987). Clement (2007) emphasizes that diagnosis of endometriosis in pregnant women may be missed on microscopic examination because the flattened epithelial cells can be mistaken for endothelial or mesothelial cells, leading to a diagnosis of ectopic decidual rather than endometriosis. However, other studies have also found pregnancy to be associated with increased cell proliferation in both stromal and glandular tissue (Cohen *et al.*, 2014).

Altogether, although some of the data support an atrophic effect of pregnancy-associated changes on endometriotic lesions, not all lesions show this effect.

According to McArthur and Ulfelder (1965) endometriotic lesions shrink by means of necrosis, with contraction in the third trimester and postpartum. Other authors have confirmed necrosis of decidual cells in pregnancy (Clement, 2007). However, histological evaluation of endometriotic lesions of other cases (rectovaginal septum) (Hay, 1939; Mocquot and Musset, 1949), the right lateral cul-de-sac (Portes and Varangot, 1939; Portes *et al.*, 1939) and the lung (Mobbs and Pfanner, 1963) showed no necrosis in any of the lesions except for one pulmonary endometriotic lesion resected at 30 weeks gestation. Consequently, data on the effect of pregnancy on necrosis of endometriotic lesions are currently controversial.

Long-term effects of pregnancy on endometriosis and disease recurrence after delivery and lactation

Only a few studies have addressed long-term recurrence rates of endometriosis following pregnancy. Evaluation of causal effects is hampered by the fact that initial endometriosis stage strongly influences the likelihood of pregnancy (Dunselman *et al.*, 2014). Recurrence of surgically confirmed endometriosis is reported to be significantly lower in women becoming pregnant than for women with no pregnancy in a 2- (Koga *et al.*, 2006), 4- (Busacca *et al.*, 2006) or 6-year (Coccia *et al.*, 2011) observation period. None of 28 women spontaneously conceiving within 2 years of endometriosis surgery had sonographically visible recurrences of ovarian endometrioma after delivery, but unfortunately comparable data for the 24 women not achieving the desired pregnancy are not reported (Porpora *et al.*, 2010). Also, an increasing number of births seems to be associated with a lower risk for the development of endometriosis (Parazzini *et al.*, 1995; Sangi-Haghpeykar and Poindexter, 1995; Missmer *et al.*, 2004). Interestingly, the recurrence rate of endometriosis after vaginal delivery is significantly lower than after caesarean section or in nulliparous women (Bulletti *et al.*, 2010). A possible explanation could be that a larger opening of the cervix allows facilitated menstrual flow and consequently a reduction of endometrial fragments reaching the abdominal cavity (Bulletti *et al.*, 2010).

Few authors (Hay, 1939; Mocquot and Musset, 1949; Barbieri *et al.*, 2009) have followed women with endometriosis through successive pregnancies: with one patient showing no differences in disease symptoms and another woman presenting regression of large lesions in a second pregnancy, the development of endometriotic lesions seems to be rather individual. In the third case presented, a pre-existing endometrioma could be observed through a first pregnancy ending in a spontaneous miscarriage at 10 weeks of gestation and a following ongoing pregnancy 9 months later (Barbieri *et al.*, 2009). While the endometrioma showed rapid growth of richly vascularized intracystic excrescences in the first pregnancy, it resumed the typical appearance of an ovarian endometrioma until 6 weeks after curettage, remained unmodified during the following 6 months and presented regression in size as well as lack of intracystic excrescences until 15 weeks of gestation of the following pregnancy, when the latest ultrasound was performed (Barbieri *et al.*, 2009). This shows that even the same endometrioma can show different growth dynamics in comparable conditions. Interestingly, in the same woman

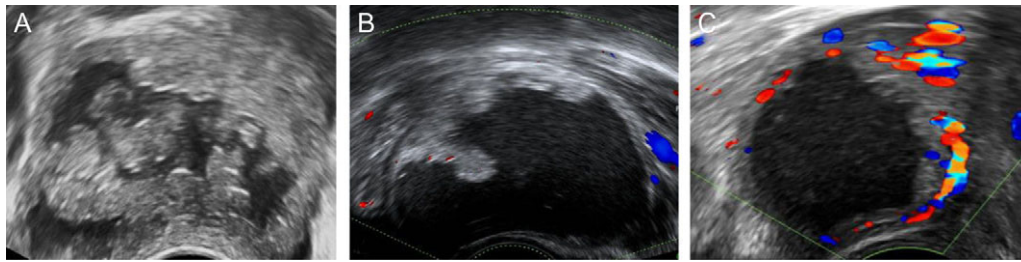


Figure 1 Sonographic appearances of decidualized endometrioma. Unilocular cysts containing hyperechoic fluid and an irregular internal wall with prominent echogenic rounded papillary projections (**A**). The papillary projections were typically highly vascular on Doppler examination (**B** and **C**). Reprinted with permissions from Pateman et al. (2014).

different endometriomas may also show different developmental characteristics in pregnancy: one case report (Guerrero et al., 2005) presented an endometrioma in one ovary whose sonographic appearance was typical and did not change, while the other ovary showed an endometrioma with extensive changes during pregnancy. Another case report described moderate growth of endometriomas on both ovaries (Fruscella et al., 2004).

Discussion

Although gynaecologists often advise women that pregnancy has a beneficial effect on endometriosis, few studies confirm this association. Owing to the paucity and limited quality of the data, we can conclude that the behaviour of endometriotic lesions during pregnancy seems to be variable, ranging from complete disappearance to increased growth. Despite some of the early authors questioning a positive effect (McArthur and Ulfelder, 1965; Schenken et al., 1987), the idea to recommend pregnancy as part of the treatment strategy for endometriosis persists to this day (Rubegni et al., 2003; Coccia et al., 2012; Benaglia et al., 2013). The few favourable early observations and very limited options to treat endometriosis seem to have generated the myth of a beneficial effect of pregnancy and initiation of the so-called ‘pseudopregnancy’ therapy. Endometriosis is associated with infertility, and a lower prevalence of endometriosis in pregnant than in non-pregnant women may have led clinicians and scientists to the view that pregnancy has a positive effect against the disease.

Available studies on the association between pregnancy and endometriosis are very heterogeneous and are often isolated cases or small case series. They focus on associations between pregnancy and growth of endometriosis, and only a few studies evaluate pregnancy and endometriosis-related pain, which is only weakly correlated with lesion size. Most studies concentrate on endometriomas and do not provide information on non-ovarian lesions. Systematic studies on the effect of first versus subsequent pregnancies or specific characteristics of lesions are lacking completely and the influence of endometriosis on the chance to conceive is only rarely taken into consideration. Studies vary widely with regard to size and type of study group, disease phenotypes, choice and definitions of parameters, analytic approaches, and natural or ART conception as well as the choice of controls, which strongly hampers the comparison of different study results. The necessity of surgical confirmation of endometriosis for a reliable diagnosis means

that detection and selection bias are likely. The time intervals between surgery and conception and whether endometriotic lesions were only diagnosed or (partly) excised are rarely reported, which impedes a differentiation between effects of surgery and of pregnancy. Generally, symptoms are not evaluated systematically and/or by validated instruments, e.g. information on changes in symptoms during and after pregnancy is not very reliable. Additionally, findings were often collected when the diagnostic options were limited, e.g. no or very low-quality ultrasound and no MRI to conduct reliable long-term observations of endometriotic lesions throughout and after pregnancy were available. The investigation of adnexal tumours was, and still is, not a routine element of the first and later ultrasounds in pre-natal care (Barbieri et al., 2009; Leone Roberti Maggiore et al., 2016). Very likely larger tumours, especially when showing signs of decidualization mimicking malignancy, will be referred more often for specialized gynaecology examination (Barbieri et al., 2009; Pateman et al., 2014; Leone Roberti Maggiore et al., 2016). Such tumours and those resulting in pain or obstetrical complication will therefore appear more often in retrospective analysis and add to bias.

The first trimester visualization of endometrioma is challenging. As peritoneal or intestinal lesions are already difficult to detect by ultrasound outside pregnancy, a correct observation throughout pregnancy is more than questionable. As a consequence, current knowledge on the development of endometriotic lesions during and after pregnancy predominantly relies on the development of endometrioma. The limited diagnostic quality of imaging techniques does not allow us to differentiate between regression and complete disappearance of lesions. Therefore, endometriomas or other endometriotic lesions which became undetectable after pregnancy might in fact still be present but radically reduced, and below the detection limit (Benaglia et al., 2013). Also, with a regression from 20 ± 9 mm before pregnancy to 18 ± 7 mm ($N = 21$) after pregnancy (Benaglia et al., 2013) the clinical relevance of such regression is questionable.

The limited reliability to sonographically differentiate between endometriosis and other benign or malignant adnexal tumours and the fact that lesions other than endometriomas may also increase in size during pregnancy (Machida et al., 2008), further hampers any final conclusion on the effect of pregnancy on the development of endometriosis. Thus, it remains unclear, whether all the changes described in the available studies should be attributed to endometriotic lesions. Data are even more sparse when it comes to long-term development of endometriosis after one or several pregnancies.

Pregnancy-associated amenorrhoea likely decreases the risk for new lesions, i.e. lack of endometriotic fragments makes the initiation of new lesions through transplacental improbable (Meresman *et al.*, 2002; Bulun, 2009; Ueda *et al.*, 2010; Beavis *et al.*, 2011). Interruption of cyclic changes at ectopic endometrial sites may reduce lesions size and induce the regression of disease symptoms (Ueda *et al.*, 2010; Coccia *et al.*, 2012).

Further mechanisms suggested to be potentially involved in the modification of size of endometriosis lesions in pregnancy are variations of cervix and uterus size throughout pregnancy, mechanisms of oedema absorption and fibrosis retraction (Coccia *et al.*, 2012). However, any detailed insight into the nature of such changes is currently lacking. Moreover, vaginal parturition enlarges the internal ostium of the uterine cervix and might decrease endometriosis recurrences by reducing tubal transportation of endometrial debris, so that the likelihood of developing new lesions via transplacental might drop after a first vaginal delivery (Bullett *et al.*, 1997).

The beneficial effect of pregnancy on endometriosis-associated pain seems to be related to a decrease in the intra- and perilesional inflammatory condition and to reduced production of prostaglandins and cytokines (Herrmann Lavoie *et al.*, 2007). A reduction in lesion size might contribute to a reduction of endometriosis-associated symptoms. However, higher endogenous estrogen production has also been reported to modulate chronic pelvic pain through neuropathic mechanisms involving changes in the peripheral nervous system that sensitize the central response: estrogens modulate nociceptive responses in functional pain syndromes (Craft, 2007). They seem to be directly and indirectly involved in nerve fibre modulation, in particular in sympathetic nerve spouting as part of pain signalling in endometriosis (Morotti *et al.*, 2014). In agreement with these findings, hormonal treatments may reduce nerve fibre density in eutopic and ectopic endometrium (Tokushige *et al.*, 2008, 2009).

Nowadays, many women with endometriosis achieve a pregnancy and with the improving success rates of ART in those who do not conceive spontaneously, clinicians are increasingly often confronted with a combination of pregnancy and endometriosis (Dunselman *et al.*, 2014). Therefore, future methodologically well designed (correctly powered, systematic evaluation of endometriotic lesions and endometriosis-related symptoms, consideration of surgical, hormonal and other therapies, etc.) longitudinal long-term studies, ideally beginning prior to a first pregnancy should provide more information about the natural history of endometriomas and other endometriotic lesions during pregnancy and the lactation period as well as on the long-term development of endometriosis after pregnancy. A particular field of interest is the decidualization of endometriotic lesions, e.g. the question of why decidualization occurs in only some of the endometriotic lesions and whether it results in the ultimate regression of lesions, as cells become terminally differentiated and consequently have a limited survival time (Koch, 2013). Another open question is whether any regression of endometriotic lesions observed during pregnancy represents only a pregnancy-related, temporary change or a final development towards necrosis and actual disappearance of lesions. The investigation of whether local adaptation to the embryo has any systemic effect on endometriotic lesions will allow a better understanding of interaction between pregnancy and the development of endometriosis and also allow a better understanding of factors involved in the development of endometriosis.

Conclusion

Based on the limited and poor-quality available evidence, pregnancy does not seem to systematically result in benefits for women with endometriosis (McArthur and Ulfelder, 1965; Schenken *et al.*, 1987; Roman *et al.*, 2007). While some lesions show regression, others remain stable or increase. Available knowledge on the pathophysiology of pregnancy/lactation and endometriosis does not contribute to an understanding of why endometriotic lesions should regress or disappear during pregnancy/lactation. As the aetiology of endometriosis is only partly understood, a precise understanding of the interactions between pregnancy and endometriosis seems unlikely in the near future. The only clear beneficial effect is the lack of new endometrium fragments distributed into the abdominal cavity as a result of amenorrhoea. As endometriosis in pregnancy is associated with rare but often severe complications, the few observed beneficial effects on disease development and clinical symptoms should carefully be balanced against potential harms. Given the highly variable effect of pregnancy on endometriotic lesions and the likely recurrence of pain symptoms some time after childbirth, women should be advised not to discontinue periodic evaluations, and possibly medical treatment, after parturition, in the conviction of having been cured by pregnancy itself.

Authors' roles

All authors contributed to the identification and critical evaluation of the relevant literature, analysis of study results and to drafting the article including the critical discussion of findings. B.L. conceived of the theme, prepared the proposal, completed literature research and contributed clinical and scientific expertise as a gynaecological endocrinologist. F.D. performed the initial literature research, analysed resulting studies, drafted a first version of the article and participated in finalization of the article. N.O.-K. contributed expertise from an obstetrical perspective. C.F. contributed expertise in the methodology of systematic reviews as well as knowledge in obstetrics and gynaecological endocrinology. All authors approved the final version of the article.

Funding

SNF (Swiss National Fond) travel grant to B.L.

Conflicts of interest

None of the authors has any conflict of interest.

References

- Amos. Demonstration: Decidua in Adenomyom und Bauchdeckentumor. Verhandlungen der Gesellschaft für Geburtsh. u. Gyn. zu Berlin. *Z Geburtsh Gynäkol* 1905;54:171.
- Bailleux M, Bernard J-P, Benachi A, Deffieux X. Ovarian endometriosis during pregnancy: a series of 53 endometriomas. *Eur J Obstet Gynecol Reprod Biol* 2015. <http://doi.org/10.1016/j.ejogrb.2015.09.037>

- Barbieri M, Somigliana E, Oneda S, Ossola MW, Acaia B, Fedele L. Decidualized ovarian endometriosis in pregnancy: a challenging diagnostic entity. *Hum Reprod* 2009;**24**:1818–1824.
- Bashir RM, Montgomery EA, Gupta PK, Nauta RM, Crockett SA, Collea JV, al-Kawas FH. Massive gastrointestinal hemorrhage during pregnancy caused by ectopic decidua of the terminal ileum and colon. *Am J Gastroenterol* 1995;**90**:1325–1327.
- Beavis AL, Matsuo K, Grubbs BH, Srivastava SA, Truong CM, Moffitt MN, Maliglig AM, Lin YG. Endometriosis in para-aortic lymph nodes during pregnancy: case report and review of literature. *Fertil Steril* 2011;**95**:2429.e9–13.
- Beecham CT. Surgical treatment of endometriosis with special reference to conservative surgery in young women. *J Am Med Assoc* 1949;**139**:971.
- Benagiano G, Brosens I, Lippi D. The history of endometriosis. *Gynecol Obstet Invest* 2014;**78**:1–9.
- Benaglia L, Somigliana E, Calzolari L, Busnelli A, Cardellicchio L, Ragni G, Fedele L. The vanishing endometrioma: the intriguing impact of pregnancy on small endometriotic ovarian cysts. *Gynecol Endocrinol* 2013;**29**:863–866.
- Bergqvist A, Ljungberg O, Myhre E. Human endometrium and endometriotic tissue obtained simultaneously: a comparative histological study. *Int J Gynecol Pathol* 1984;**3**:135–145.
- Bilotas MA, Olivares CN, Ricci AG, Baston JI, Bengochea TS, Meresman GF, Barañao RI. Interplay between endometriosis and pregnancy in a mouse model. Jeong J-W (ed). *PLoS One* 2015;**10**:e0124900.
- Bromley B, Benacerraf B. Adnexal masses during pregnancy: accuracy of sonographic diagnosis and outcome. *J Ultrasound Med* 1997;**16**:447–452; quiz 453–4.
- Brosens IA, Verleyen A, Cornillie F. The morphologic effect of short-term medical therapy of endometriosis. *Am J Obstet Gynecol* 1987;**157**:1215–1221.
- Brosens IA, Fusi L, Brosens JJ. Endometriosis is a risk factor for spontaneous hemoperitoneum during pregnancy. *Fertil Steril* 2009a;**92**:1243–1245.
- Brosens JJ, Parker MG, McIndoe A, Pijnenborg R, Brosens IA. A role for menstruation in preconditioning the uterus for successful pregnancy. *Am J Obstet Gynecol* 2009b;**200**:615.e1–6.
- Brosens IA, Lier MC, Mijatovic V, Habiba M, Benagiano G. Severe spontaneous hemoperitoneum in pregnancy may be linked to in vitro fertilization in patients with endometriosis: a systematic review. *Fertil Steril* 2016;**106**:692–703.
- Bulletti C, de Ziegler D, Rossi S, Polli V, Massoneau M, Rossi E, Albonetti A, Negrini V, Flamigni C. Abnormal uterine contractility in nonpregnant women. *Ann NY Acad Sci* 1997;**828**:223–229.
- Bulletti C, Montini A, Setti PL, Palagiano A, Ubaldi F, Borini A. Vaginal parturition decreases recurrence of endometriosis. *Fertil Steril* 2010;**94**:850–855.
- Bulun SE. Endometriosis. *N Engl J Med* 2009;**360**:268–279.
- Busacca M, Marana R, Caruana P, Candiani M, Muzii L, Calia C, Bianchi S. Recurrence of ovarian endometrioma after laparoscopic excision. *Am J Obstet Gynecol* 1999;**180**:519–523.
- Busacca M, Chiaffarino F, Candiani M, Vignali M, Bertulesi C, Oggioni G, Parazzini F. Determinants of long-term clinically detected recurrence rates of deep, ovarian, and pelvic endometriosis. *Am J Obstet Gynecol* 2006;**195**:426–432.
- Canlorbe G, Goubin-Versini I, Azria E, Abdul-Razak R, Muray J-M. Ectopic decidua: variability of presentation in pregnancy and differential diagnoses. *Gynecol Obstet Fertil* 2012;**40**:235–240.
- Chertin B, Prat O, Farkas A, Reinus C. Pregnancy-induced vesical decidualized endometriosis simulating a bladder tumor. *Int Urogynecol J Pelvic Floor Dysfunct* 2007;**18**:1111–1112.
- Clement PB. Perforation of the sigmoid colon during pregnancy: a rare complication of endometriosis. Case report. *Br J Obstet Gynaecol* 1977;**84**:548–550.
- Clement PB. The pathology of endometriosis: a survey of the many faces of a common disease emphasizing diagnostic pitfalls and unusual and newly appreciated aspects. *Adv Anat Pathol* 2007;**14**:241–260.
- Coccia ME, Rizzello F, Palagiano A, Scarselli G. Long-term follow-up after laparoscopic treatment for endometriosis: multivariate analysis of predictive factors for recurrence of endometriotic lesions and pain. *Eur J Obstet Gynecol Reprod Biol* 2011;**157**:78–83.
- Coccia ME, Rizzello F, Palagiano A, Scarselli G. The effect of the hormonal milieu of pregnancy on deep infiltrating endometriosis: serial ultrasound assessment of changes in size and pattern of deep endometriotic lesions. *Eur J Obstet Gynecol Reprod Biol* 2012;**160**:35–39.
- Cohen J, Naoura I, Castela M, N'Guyen Von T, Oster M, Fontaine R, Chabbert-Buffet N, Daraï E, Aractingi S. Pregnancy affects morphology of induced endometriotic lesions in a mouse model through alteration of proliferation and angiogenesis. *Eur J Obstet Gynecol Reprod Biol* 2014;**183**:70–77.
- Condous G, Khalid A, Okaro E, Bourne T. Should we be examining the ovaries in pregnancy? Prevalence and natural history of adnexal pathology detected at first-trimester sonography. *Ultrasound Obstet Gynecol* 2004;**24**:62–66.
- Corson SL. Self-prediction of ovulation using a urinary luteinizing hormone test. *J Reprod Med* 1986;**31**:760–763.
- Craft RM. Modulation of pain by estrogens. *Pain* 2007;**132**:S3–S12.
- Cummings AM, Metcalf JL. Effect of surgically induced endometriosis on pregnancy and effect of pregnancy and lactation on endometriosis in mice. *Proc Soc Exp Biol Med* 1996;**212**:332–337.
- D'Hooghe TM, Kyama C, Debrock S, Meuleman C, Mwenda JM. Future directions in endometriosis research. *Ann NY Acad Sci* 2004;**1034**:316–325.
- diZerega GS, Barber DL, Hodgen GD. Endometriosis: role of ovarian steroids in initiation, maintenance, and suppression. *Fertil Steril* 1980;**33**:649–653.
- Dunselman GAJ, Vermeulen N, Becker C, Calhaz-Jorge C, D'Hooghe T, De Bie B, Heikinheimo O, Horne AW, Kiesel L, Nap A et al. ESHRE guideline: management of women with endometriosis. *Hum Reprod* 2014;**29**:400–412.
- Eskenazi B, Warner ML. Epidemiology of endometriosis. *Obstet Gynecol Clin North Am* 1997;**24**:235–258.
- Fair KP, Patterson JW, Murphy RJ, Rudd RJ. Cutaneous decidualosis. *J Am Acad Dermatol* 2000;**43**:102–107.
- Flieder DB, Moran CA, Travis WD, Koss MN, Mark EJ. Pleuro-pulmonary endometriosis and pulmonary ectopic decidualosis: a clinicopathologic and immunohistochemical study of 10 cases with emphasis on diagnostic pitfalls. *Hum Pathol* 1998;**29**:1495–1503.
- Fruscella E, Testa AC, Ferrandina G, Manfredi R, Zannoni GF, Ludovisi M, Malagessa M, Scambia G. Sonographic features of decidualized ovarian endometriosis suspicious for malignancy. *Ultrasound Obstet Gynecol* 2004;**24**:578–580.
- Gainey HL, Keeler JE, Nicolay KS. Endometriosis in pregnancy, clinical observations. *Am J Obstet Gynecol* 1952;**63**:511–523.
- Ganesh AL, Chakravarty B. Spontaneous viable pregnancies in cervical and rectal endometriosis: a report of two cases. *Fertil Steril* 2007;**87**:697. e1–4.
- Garcia-Velasco JA, Alvarez M, Palumbo A, González-González A, Ordás J. Rupture of an ovarian endometrioma during the first trimester of pregnancy. *Eur J Obstet Gynecol Reprod Biol* 1998;**76**:41–43.
- Gellersen B, Brosens J. Cyclic AMP and progesterone receptor cross-talk in human endometrium: a decidualizing affair. *J Endocrinol* 2003;**178**:357–372.
- Gellersen B, Brosens IA, Brosens JJ. Decidualization of the human endometrium: mechanisms, functions, and clinical perspectives. *Semin Reprod Med* 2007;**25**:445–453.
- Gregora M, Higgs P. Endometriomas in pregnancy. *Aust NZ J Obstet Gynaecol* 1998;**38**:106–109.
- Guerrero S, Ajossa S, Piras S, Parodo G, Melis GB. Serial ultrasonographic evaluation of a decidualized endometrioma in pregnancy. *Ultrasound Obstet Gynecol* 2005;**26**:304–306.
- Hay WFW. Endometriosis of the vagina. *J Maine M A* 1939;**30**:260.
- Herrmann Lavoie C, Fraser D, Therriault M-J, Akoum A. Interleukin-1 stimulates macrophage migration inhibitory factor secretion in ectopic endometrial cells of women with endometriosis. *Am J Reprod Immunol* 2007;**58**:505–513.
- Iwamoto H, Suzuki M, Watanabe N, Minai M, Hirata S, Hoshi K. Case study of a pregnant woman with decidualized ovarian endometriosis whose preoperative findings suggested malignant transformation. *Eur J Gynaecol Oncol* 2006;**27**:301–303.
- Kistner RW. Conservative management of endometriosis. *J Lancet* 1959a;**79**:179–183.
- Kistner RW. Endometriosis and infertility. *Clin Obstet Gynecol* 1959b;**2**:877–889.
- Kobayashi H, Iwai K, Niuro E, Morioka S, Yamada Y. Fetal programming theory: implication for the understanding of endometriosis. *Hum Immunol* 2014;**75**:208–217.
- Koch Y. Die Wirkung von hCG auf die Dezidualisierung ektopter endometrialer Läsionen als therapeutischer Ansatz zur Behandlung der Endometriose. In: Grümmer R, Heubner ML (eds). 2013. https://duepublico.uni-duisburg-essen.de/servlets/DocumentServlet/Document/34716/Diss_Koch.pdf.
- Koga K, Takemura Y, Osuga Y, Yoshino O, Hirota Y, Hirata T, Morimoto C, Harada M, Yano T, Taketani Y. Recurrence of ovarian endometrioma after laparoscopic excision. *Hum Reprod* 2006;**21**:2171–2174.

- Leone Roberti Maggiore U, Ferrero S, Mangili G, Bergamini A, Inversetti A, Giorgione V, Viganò P, Candiani M. A systematic review on endometriosis during pregnancy: diagnosis, misdiagnosis, complications and outcomes. *Hum Reprod Update* 2016;**22**:70–103.
- Lier MCI, Brosens IA, Mijatovic V, Habiba M, Benagiano G. Decidual bleeding as a cause of spontaneous hemoperitoneum in pregnancy and risk of preterm birth. *Gynecol Obstet Invest* 2017;**82**:313–321.
- Liu X, Yuan L, Shen F, Zhu Z, Jiang H, Guo S-W. Patterns of and risk factors for recurrence in women with ovarian endometriomas. *Obstet Gynecol* 2007;**109**:1411–1420.
- Luke B, Gopal D, Cabral H, Stern JE, Diop H. Pregnancy, birth, and infant outcomes by maternal fertility status: the Massachusetts Outcomes Study of Assisted Reproductive Technology. *Am J Obstet Gynecol* 2017;**217**:327.e1–327.e14.
- Machida S, Matsubara S, Ohwada M, Ogozuma M, Kuwata T, Watanabe T, Izumi A, Suzuki M. Decidualization of ovarian endometriosis during pregnancy mimicking malignancy: report of three cases with a literature review. *Gynecol Obstet Invest* 2008;**66**:241–247.
- McArthur JW, Ulfelder H. The effect of pregnancy upon endometriosis. *Obstet Gynecol Surv* 1965;**20**:709–733.
- Meigs JV. Endometrial hematomas of the ovary. *Boston M S J* 1922;**187**:1.
- Meigs JV. Endometriosis; etiologic role of marriage age and parity; conservative treatment. *Obstet Gynecol* 1953;**2**:46–53.
- Meresman GF, Augé L, Barañao RI, Lombardi E, Tesone M, Sueldo C. Oral contraceptives suppress cell proliferation and enhance apoptosis of eutopic endometrial tissue from patients with endometriosis. *Fertil Steril* 2002;**77**:1141–1147.
- Metzger DA, Haney AF. Endometriosis: etiology and pathophysiology of infertility. *Clin Obstet Gynecol* 1988;**31**:801–812.
- Missmer SA, Hankinson SE, Spiegelman D, Barbieri RL, Malspeis S, Willett WC, Hunter DJ. Reproductive history and endometriosis among premenopausal women. *Obstet Gynecol* 2004;**104**:965.
- Miyakoshi K, Tanaka M, Gabionza D, Takamatsu K, Miyazaki T, Yuasa Y, Mukai M, Yoshimura Y. Decidualized ovarian endometriosis mimicking malignancy. *Am J Roentgenol* 1998;**171**:1625–1626.
- Mobbs GA, Pfanner DW. Endometriosis of the lung. *Lancet* 1963;**1**:472.
- Mocquot P, Musset R. Remarques sur la physiologie pathologique des endometrioses a propos de trois observations d'endometriose du cul-de-sac posterieur du vagin. *Gynecol Obstet* 1949;**48**:135.
- Moen MH, Muus KM. Endometriosis in pregnant and non-pregnant women at tubal sterilization. *Hum Reprod* 1991;**6**:699–702.
- Morotti M, Vincent K, Brawn J, Zondervan KT, Becker CM. Peripheral changes in endometriosis-associated pain. *Hum Reprod Update* 2014;**20**:717–736.
- Müller J. Zur Endometriose der Harnblase. (Funktionelle Veränderungen). *Z Urol* 1939;**30**:723.
- Nakatani Y, Hara M, Misugi K, Korehisa H. Appendiceal endometriosis in pregnancy. Report of a case with perforation and review of the literature. *Acta Pathol Jpn* 1987;**37**:1685–1690.
- Nisolle-Pochet M, Casanas-Roux F, Donnez J. Histologic study of ovarian endometriosis after hormonal therapy. *Fertil Steril* 1988;**49**:423–426.
- Olshausen. Demonstration: Bauchdeckentumor. Verhandlung der Gesellschaft fur Geburtsh. u. Gyn. zu Berlin. *Z Geburtsh Gynäkol* 1904;**53**:343.
- Parazzini F, Ferraroni M, Fedele L, Bocciolone L, Rubessa S, Riccardi A. Pelvic endometriosis: reproductive and menstrual risk factors at different stages in Lombardy, northern Italy. *J Epidemiol Community Health* 1995;**49**:61–64.
- Pateman K, Moro F, Mavrelos D, Foo X, Hoo W-L, Jurkovic D. Natural history of ovarian endometrioma in pregnancy. *BMC Womens Health* 2014;**14**:128.
- Phupong V, Rungkruxirivorn T, Tantbirojn P, Triratanachai S, Vasuratna A. Infected endometrioma in pregnancy masquerading as acute appendicitis. *Arch Gynecol Obstet* 2004;**269**:219–220.
- Porpora MG, Pallante D, Ferro A, Crisafi B, Bellati F, Benedetti Panici P. Pain and ovarian endometrioma recurrence after laparoscopic treatment of endometriosis: a long-term prospective study. *Fertil Steril* 2010;**93**:716–721.
- Portes L, Francois E, Varangot J. Sur un cas d'endometriose vaginale ayant evolue au cours d'une grossesse. *Bull Soc Gynecol Obstet* 1939;**28**:467.
- Portes L, Varangot J. Endometriose et gestation. *Gynecol Obstet* 1939;**40**:298.
- Razzi S, Rubegni P, Sartini A, De Simone S, Fava A, Cobellis L, Fimiani M, Petraglia F. Umbilical endometriosis in pregnancy: a case report. *Gynecol Endocrinol* 2004;**18**:114–116.
- Redwine DB. Ovarian endometriosis: a marker for more extensive pelvic and intestinal disease. *Fertil Steril* 1999;**72**:310–315.
- Roman H, Friederich L, Khalil H, Maroteau-Pasquier N, Hochain P, Marpeau L. Treating severe endometriosis by pregnancy: a risky business. *Gynecol Obstet Fertil* 2007;**35**:38–40.
- Rubegni P, Sbrano P, Santopietro R, Fimiani M. Case 4. Umbilical endometriosis. *Clin Exp Dermatol* 2003;**28**:571–572.
- Sammour RN, Leibovitz Z, Shapiro I, Degani S, Levitan Z, Aharoni A, Tal J, Lurie M, Ohel G. Decidualization of ovarian endometriosis during pregnancy mimicking malignancy. *J Ultrasound Med* 2005;**24**:1289–1294.
- Sampson JA. The life history of ovarian hematomas (hemorrhagic cysts) of endometrial (Mullerian) type. *Am J Obstet Gynecol* 1922;**4**:451.
- Sampson JA. Benign and malignant endometrial implants in the peritoneal cavity, and their relation to certain ovarian tumors. *Surg Gynecol Obstet* 1924;**38**:287.
- Sangi-Haghpeykar H, Poindexter AN. Epidemiology of endometriosis among parous women. *Obstet Gynecol* 1995;**85**:983–992.
- Schenken RS, Williams RF, Hodgen GD. Effect of pregnancy on surgically induced endometriosis in cynomolgus monkeys. *Am J Obstet Gynecol* 1987;**157**:1392–1396.
- Schweitzer KJ, van Bekkum E, de Groot CJM. Endometriosis with intestinal perforation in term pregnancy. *Int J Gynaecol Obstet* 2006;**93**:152–153.
- Scott RB. Endometriosis and pregnancy—with a report of two cases. *Am J Obstet Gynecol* 1944;**47**:608–632.
- Scott RB, Te Linde RW. Clinical external endometriosis; probable viability of menstrually shed fragments of endometrium. *Obstet Gynecol* 1954;**4**:502–510.
- Seracchioli R, Mabrouk M, Frascà C, Manuzzi L, Savelli L, Venturoli S. Long-term oral contraceptive pills and postoperative pain management after laparoscopic excision of ovarian endometrioma: a randomized controlled trial. *Fertil Steril* 2010;**94**:464–471.
- Setúbal A, Sidiropoulou Z, Torgal M, Casal E, Lourenço C, Koninckx P. Bowel complications of deep endometriosis during pregnancy or in vitro fertilization. *Fertil Steril* 2014;**101**:442–446.
- Sherard GB, Hodson CA, Williams HJ, Semer DA, Hadi HA, Tait DL. Adnexal masses and pregnancy: a 12-year experience. *Am J Obstet Gynecol* 2003;**189**:358–362; discussion 362–363.
- Skidmore RA, Woosley JT, Katz VL. Decidualized umbilical endometriosis. *Int J Gynaecol Obstet* 1996;**52**:269–273.
- Takeuchi M, Matsuzaki K, Nishitani H. Magnetic resonance manifestations of decidualized endometriomas during pregnancy. *J Comput Assist Tomogr* 2008;**32**:353–355.
- Tokushige N, Markham R, Russell P, Fraser IS. Effects of hormonal treatment on nerve fibers in endometrium and myometrium in women with endometriosis. *Fertil Steril* 2008;**90**:1589–1598.
- Tokushige N, Markham R, Russell P, Fraser IS. Effect of progestogens and combined oral contraceptives on nerve fibers in peritoneal endometriosis. *Fertil Steril* 2009;**92**:1234–1239.
- Ueda Y, Enomoto T, Miyatake T, Fujita M, Yamamoto R, Kanagawa T, Shimizu H, Kimura T. A retrospective analysis of ovarian endometriosis during pregnancy. *Fertil Steril* 2010;**94**:78–84.
- von Elm E, Altman DG, Egger M, Pocock SJ, Gøtzsche PC, Vandenbroucke JP, STROBE Initiative. The Strengthening the Reporting of Observational Studies in Epidemiology (STROBE) statement: guidelines for reporting observational studies. *Bull World Health Organ* 2007;**85**:867–872.
- Wiegatz I, Kissler S, Engels K, Strey C, Kaufmann M. Umbilical endometriosis in pregnancy without previous surgery. *Fertil Steril* 2008;**90**:199.e17–e20.
- Yap C, Furness S, Farquhar C. Pre and post operative medical therapy for endometriosis surgery. Furness S (ed). *Cochrane Database Syst Rev* 2004;CD003678.
- Yazbek J, Salim R, Woelfer B, Aslam N, Lee CT, Jurkovic D. The value of ultrasound visualization of the ovaries during the routine 11–14 weeks nuchal translucency scan. *Eur J Obstet Gynecol Reprod Biol* 2007;**132**:154–158.
- Zanetta G, Mariani E, Lissoni A, Ceruti P, Trio D, Strobelt N, Mariani S. A prospective study of the role of ultrasound in the management of adnexal masses in pregnancy. *BJOG* 2003;**110**:578–583.