

Neural Correlate of Anterograde Amnesia in Wernicke–Korsakoff Syndrome

Louis Nahum · Jean-Michel Pignat · Aurélie Bouzerda-Wahlen · Damien Gabriel · Maria Chiara Liverani · François Lazeyras · Radek Ptak · Jonas Richiardi · Sven Haller · Gabriel Thorens · Daniele F. Zullino · Adrian G. Guggisberg · Armin Schnider

Received: 8 October 2013 / Accepted: 4 August 2014 / Published online: 23 August 2014
© Springer Science+Business Media New York 2014

Abstract The neural correlate of anterograde amnesia in Wernicke–Korsakoff syndrome (WKS) is still debated. While the capacity to learn new information has been associated with integrity of the medial temporal lobe (MTL), previous studies indicated that the WKS is associated with diencephalic lesions, mainly in the mammillary bodies and anterior or dorsomedial thalamic nuclei. The present study tested the hypothesis that amnesia in WKS is associated with a disrupted neural circuit between diencephalic and hippocampal structures. High-density evoked potentials were recorded in four severely amnesic patients with chronic WKS, in five patients with chronic alcoholism without WKS, and in ten age matched controls. Participants performed a continuous recognition task of pictures

previously shown to induce a left medial temporal lobe dependent positive potential between 250 and 350 ms. In addition, the integrity of the fornix was assessed using diffusion tensor imaging (DTI). WKS, but not alcoholic patients without WKS, showed absence of the early, left MTL dependent positive potential following immediate picture repetitions. DTI indicated disruption of the fornix, which connects diencephalic and hippocampal structures. The findings support an interpretation of anterograde amnesia in WKS as a consequence of a disconnection between diencephalic and MTL structures with deficient contribution of the MTL to rapid consolidation.

Keywords Wernicke–Korsakoff syndrome · Anterograde amnesia · Fornix · Medial temporal lobe · DTI

L. Nahum · J.-M. Pignat · A. Bouzerda-Wahlen · D. Gabriel · M. C. Liverani · R. Ptak · A. G. Guggisberg · A. Schnider
Laboratory of Cognitive Neurorehabilitation, Department of Clinical Neurosciences and Dermatology, Medical Faculty, University Hospitals of Geneva, Geneva, Switzerland

L. Nahum (✉) · R. Ptak · A. G. Guggisberg · A. Schnider
Division of Neurorehabilitation, Department of Clinical Neurosciences, University Hospitals of Geneva,
Av. de Beau-Séjour 26, 1211 Geneva, Switzerland
e-mail: louis.nahum@hcuge.ch

J.-M. Pignat · F. Lazeyras · J. Richiardi · S. Haller
Division of Radiology, Department of Neuroscience and Department of Neurology, University Hospitals of Geneva, Geneva, Switzerland

J. Richiardi
Department of Neurology and Neurological Sciences, Stanford University School of Medicine, Stanford, CA, USA

G. Thorens · D. F. Zullino
Division of Addictology, Department of Psychiatry, University Hospitals of Geneva, Geneva, Switzerland

Introduction

Wernicke–Korsakoff syndrome (WKS) is the chronic amnesic state following Wernicke encephalopathy, an acute neurological disorder characterized by ataxia, vestibular dysfunction, nystagmus, drowsiness and a confusional state (Victor et al. 1989). WKS results from thiamine deficiency caused by malnutrition, malabsorption or in most cases nowadays, chronic alcohol abuse. The cognitive deficits associated with WKS consist of a variably severe anterograde amnesia and executive dysfunctioning (Kopelman et al. 1989; Victor et al. 1989); confabulations are often present initially and may continue beyond the acute stage (Schnider 2008; Schnider et al. 2013).

The neural correlate of the anterograde amnesia in WKS remains poorly understood (Kopelman 1995; Schnider 2008). Post-mortem studies demonstrated damage to the mammillary bodies and the thalamic nuclei (Gamper 1928;

Mayes et al. 1988; Victor et al. 1989; Harding et al. 2000). Victor et al. (1989) suggested that the dorsomedial nucleus of the thalamus rather than the mammillary bodies was critical, while two other studies came to the opposite conclusion (Mair et al. 1979; Mayes et al. 1988). More recently, Harding et al. (2000) suggested that neural loss in the anterior thalamic nuclei, rather than the mammillary bodies or dorsomedial thalamic nuclei, explained anterograde amnesia in their patients.

Structural imaging studies described generalised cerebral atrophy in patients with WKS (Christie et al. 1988; Jacobson and Lishman 1990; Jernigan et al. 1991), several studies emphasised hippocampal (Sullivan and Pfefferbaum 2009, but see Colchester et al. 2001), thalamic and mammillary body atrophy (Squire et al. 1990; Jernigan et al. 1991; Colchester et al. 2001; Sullivan and Pfefferbaum 2009) or medial thalamic signal abnormalities (Halavaara et al. 2003).

Metabolic imaging studies produced variable findings, too. Several authors reported extensive hypometabolism in the cerebral cortex (Hunter et al. 1989; Paller et al. 1997), while others reported more focal hypometabolism variably affecting the thalamic nuclei (Heiss et al. 1992; Benson et al. 1996; Matsuda et al. 1997; Aupée et al. 2001), the cingulum, the frontal lobe, and the medial temporal lobe (Heiss et al. 1992; Reed et al. 2003; Aupée et al. 2001; Caulo et al. 2005; Schnider et al. 2013).

It emerges from these studies that amnesia in the WKS is associated with damage to diencephalic structures and accompanied by hypometabolism in cortical regions associated with the limbic Papez circuit, including the medial temporal lobes (MTL). Some authors, therefore, hypothesized that the amnesia in WKS results from a disruption of a neural network, more specifically disconnections between diencephalic (fornix and mammillary bodies in particular) and cortical structures (frontal and temporal lobe) (Warrington and Weiskrantz 1982; Aupée et al. 2001; Kessels and Kopelman 2012) or between the cerebellum and cerebral cortex areas (Wijnia and Goossens 2010). Direct evidence is lacking.

In the present study, we tested the hypothesis that amnesia in WKS results from a disruption between diencephalic and MTL regions in four patients by combining two methods. Diffusion tensor imaging was used to assess the integrity of the fornix, which connects hippocampal formation with diencephalic structures. Recording of high-density evoked potential during a specific memory task was used to investigate functional MTL involvement. The experimental paradigm consisted of a continuous recognition task, in which all stimuli were repeated once, either immediately (One-back items) or after nine intervening stimuli (Ten-back items). In a previous surface EEG study (James et al. 2009), we found that One-back items induced an early frontal positivity at 200–300 ms in healthy subjects emanating from the left MTL, as concluded from

source localization (James et al. 2009). This provenance was confirmed by intracranial recordings in epileptic patients (Nahum et al. 2011). We hypothesized that, in contrast to healthy participants and non-amnesic alcoholic patients, WKS patients would not generate the early positive MTL potential, associated with loss of hippocampal connections in the fornix.

Methods

Participants

Four right-handed patients with alcoholic Wernicke-Korsakoff syndrome (WKS, aged 55.8 ± 7 years), four right-handed (aged 49, 50, 50, and 57 years) and one left-handed (aged 46 years) patients with alcohol dependence, and 10 right-handed healthy control subjects (aged 56.2 ± 4.5 years) with no history of neurological or psychiatric illness participated in this study. As only half of the healthy control subjects who had an EEG also had an MRI, DTI data were completed by seven additional right-handed healthy control subjects matched for age and education and with no history of neurological or psychiatric illness. All participants provided written informed consent to participate in the study. The Ethical Committee of the University Hospital of Geneva approved the study.

The patients with WKS and control subjects did not differ significantly on age (Mann–Whitney U test, $U > 10$, $p > 0.05$, see Table 1) or education (Mann–Whitney U test, $U = 13$, $p = 0.3$, see Table 1). Alcoholic patients were slightly younger than the control subjects (Mann–Whitney U test, $U = 13$, $p = 0.03$, see Table 1) but did not differ significantly on education (Mann–Whitney U test, $U = 18.5$, $p = 0.46$, see Table 1). All patients with WKS were hospitalized for neurorehabilitation at the time of testing. Non-amnesic alcoholic patients were recruited from the day clinic for addictions of Geneva.

Control subjects and alcoholic patients underwent a brief neuropsychological evaluation to exclude cognitive dysfunction (Table 1); both obtained normal scores except alcoholic patient CC, who had a score of verbal fluency between 2nd and 5th centile of the normative data. Table 1 shows that the patients with WKS had poor performance on immediate and delayed free recall of a list of words (CERAD Word List Memory task, Welsh et al. 1994), on verbal and non-verbal fluency, and on cognitive flexibility in the Trail Making Test (Army Individual Test Battery 1944) compared to the healthy control group and the patient control group. WKS Patients 1 and 2 had lower scores in the memory task than WKS patients 3 and 4.

No lesion was demonstrated in three patients with WKS while bilateral damage of the mammillary bodies was found in patient 1 in the acute stage. All patients with WKS had cerebral atrophy. Alcoholic control patient DD had

Table 1 Demographic data and neuropsychological results of the healthy participants, alcoholic patients and patients with Wernicke-Korsakoff syndrome

	Healthy participants (mean ± SD)	OH patients (mean ± SD)	WKS patient 1 (score)	WKS patient 2 (score)	WKS patient 3 (score)	WKS patient 4 (score)
Age (years)	56.2 ± 4.5	50.4 ± 4*	57	65	49	52
Sex	3F; 7M	2F; 3M	M	F	M	M
Education (years)	11.4 ± 2.4	11.8 ± 3.4	12	10	10	8
MMSE (Folstein et al. 1975)	29.7 ± 0.5	29 ± 1.2	16*	18*	23*	23*
Digit span (Wechsler 1945)	5.6 ± 0.5	6.2 ± 0.8	5	5	5	5
CERAD (Welsh et al. 1994) Free recall	24 ± 3.5	22.8 ± 4	8*	7*	10*	11*
Delayed recall	8 ± 1.4	6.4 ± 1.5	0*	0*	0*	2*
Recognition	10 ± 0	9.2 ± 1.3	0*	1*	5*	3*
TMT B (AITB 1944) Error	0.1 ± 0.3	0.2 ± 0.4	0	0	0	0
Time (ms)	68.9 ± 17.7	65.8 ± 33.6	180*	180*	163*	138*
Verbal fluency (Thurstone and Thurstone 1962)	30.6 ± 7.5	22.6 ± 6.7	3*	22	9*	15*
Non-verbal fluency (Regard et al. 1982)	31.9 ± 6.7	29.8 ± 9.4	12*	16*	14*	16*

OH alcoholic patient, WKS patient with Wernicke–Korsakoff syndrome

* Significant difference between individual score of WKS patient or average score of OH patients and average score of the healthy control group ($p < 0.05$)

frontal and cerebellar signal change and patient AA had moderate frontal atrophy; other alcoholic patients had no visible structural abnormalities.

Case Vignettes

WKS Patient 1

This 57 year-old locksmith with chronic alcoholism was admitted to hospital 3 days after developing a confusional state, nystagmus, and gait ataxia. A diagnosis of WKS was made and thiamine substitution started. While the ataxia rapidly resolved, amnesia with severe confabulations and disorientation persisted. When transferred to neurorehabilitation after one month, he was still severely amnesia, repeatedly asking the same questions. He confabulated on a single topic, an obligation he had actually had 20 years previously. Details on the confabulatory behaviour of this case have been published separately (Schnider et al. 2013). He stopped confabulating 6 months later but remained amnesic.

WKS Patient 2

This 65 year-old woman, a retired bank assistant, had a 30 year history of alcoholism. 2 years prior to the examination, she suffered an acute WKS following a 2-months period of fasting. Under thiamine, gait ataxia and oculomotor disturbances rapidly recovered, but she remained profoundly disoriented and amnesic for months. In discussions, she would repeat the same questions over and over again. She would

retain significant events for a maximum of an hour. She correctly recollected her childhood but did not remember events or celebrities of the last 30 years and repeatedly tried to call her mother who had died 34 years ago. According to her husband, she produced no confabulations.

WKS Patient 3

This 49 year-old man had a long history of alcoholism and occasional consumption of illicit drugs (cannabis, cocaine). He had lost his job as an accountant 3 years previously. He was found in a confusional state at his home, unable to stand or walk, with nystagmus and visual as well as auditory hallucinations. Upon substitution of thiamine, his gait rapidly improved but severe amnesia persisted. He was admitted to neurorehabilitation after 2 months. He would not recognize personnel and did not retain daily events. He was disoriented and occasionally confabulated on invented obligations. He entered the study two-and-a-half months after the start of the WKS.

WKS Patient 4

This 52 year-old man had worked as a road sweeper. He lived alone and was known for chronic alcoholism. He consulted with his physician because of weakness, weight loss, and memory difficulties for 2 weeks. Treatment with thiamine was started. Thiamine blood level was confirmed to be abnormally low, supporting a diagnosis of WKS. He was hospitalized. An MRI showed moderate brain atrophy and

diffuse vascular lesions of the white matter. After 2 months, he suffered a generalized seizure attributed to severe hyponatraemia. His condition slowly improved. He was transferred to neurorehabilitation after 3 months because of persisting memory problems with temporo-spatial disorientation but no confabulations; he had no motor impairment. He participated in the study three-and-a-half months after the beginning of the symptoms. He returned home after 1 month of neurorehabilitation and partially resumed his job.

Alcoholic Patients

OH Patients AA to EE

All alcoholic patients had a long-term alcohol abuse (ranging from 10 to 30 years) but had never experienced delirium, psychotic symptoms, or cognitive deficits. They had been suffering from depression (patient AA, patient BB, patient EE) or anxiety-depressive disorders (patient CC and patient DD). Additionally, Patient DD experienced an isolated epileptic seizure in 2010. At the time of the experiment, patients AA, BB, and EE regularly consumed alcohol (respectively 15, 20 and 40 units a week) while patients CC and DD were abstinent for respectively three and 4 months. All patients took an antidepressant or an anxiolytic medication; patient AA took an antiepileptic medication too.

Memory Task

Learning Task

Subjects performed two separate continuous recognition tasks known to involve the left MTL (James et al. 2009; Nahum et al. 2011). Each was composed from a distinct set of 120 concrete black on white line drawings (Snodgrass and Vanderwart 1980). All pictures were repeated once during the task, either immediately following a 2-s stimulation-free interval after the initial presentation (One-back items, $N = 60$) or after nine intervening items (Ten-back items, $N = 60$). Stimuli were presented on a 17 inches monitor for 1,000 ms, with an interstimulus interval of 2,000 ms filled with a fixation cross. Subjects had to indicate picture recurrences by pressing a button on the response box with the middle finger, new pictures by pressing another button with the index finger of their dominant hand. The two tasks were performed consecutively, separated by a 2 min break. Both lasted about 12 min. Responses were pooled for analysis.

In an earlier study with healthy subjects (James et al. 2009) surface EEG showed that One-back items induced an early frontal positivity at 200–300 ms in healthy subjects, which appeared to emanate from the left MTL according to inverse solution analysis. The conclusion was confirmed by intracranial recordings in two epileptic patients (Nahum et al. 2011). The behavioural correlate of this electrocortical

response was less efficient recognition of the One-back items than Ten-back items after 30 min, corresponding to the absent spacing effect, that is, the disadvantage for long term retention of immediate item repetition in comparison to repetition after several intervening items (Crowder 1976; Greene 1989). We suggested that the observed MTL activity in response to immediate picture repetitions reflects interference with an ongoing consolidation process initiated by the previous new picture, which would require off-line processing to be fully effective (James et al. 2009).

Delayed Recognition Task

To test for the long term retention of items, participants performed a delayed recognition task 30 min after the termination of the two learning tasks, which contained all 240 pictures from the memory task plus 120 new pictures in random order. Subjects had to indicate pictures that had appeared in the learning task.

EEG Acquisition and Event-Related Potentials Analysis

EEG was continuously recorded during the continuous recognition task (learning task) with an Active-Two Biosemi EEG system (BioSemi Active-Two, V.O.F., Amsterdam, The Netherlands) with 128 scalp electrodes. Signals were sampled at 512 Hz and filtered at a bandwidth of 0.1–104 Hz. All analyses were conducted using Cartool Software (<http://brainmapping.unige.ch/Cartool.htm>). Epochs from 50 ms prestimulus to 800 ms poststimulus onset were averaged along each item type (New, One-back, Ten-back) and for each subject to calculate the event-related potential (ERP). Epochs with artefacts (blinks, eye movements and other sources of transient noise) were rejected. There was no statistical difference of the total number of epochs per condition between groups of subjects (Kruskal–Wallis tests, all $p > 0.1$; mean \pm SD; healthy participants—New: 41 ± 12 ; One-back: 32 ± 13 ; Ten-back: 38 ± 13 ; WKS patients—New: 54 ± 18 ; One-back: 49 ± 24 ; Ten-back: 54 ± 16 ; OH patients—New: 40 ± 5 ; One-back: 37 ± 6 ; Ten-back: 40 ± 10).

Baseline correction was applied to the 50 ms prestimulus period. Bad electrodes were interpolated using a spherical spline interpolation (Perrin et al. 1987). On average, 8.5 electrodes were interpolated per subject (max. 18, min. 6). ERPs were then bandpass-filtered to 1–30 Hz and recalculated against the average reference before group averaging.

Waveform Analysis

Based on previous studies (James et al. 2009; Nahum et al. 2011) and inspection of the grand-mean ERP of the healthy control group, amplitude differences between the three different types of items (One-back, Ten-back, New) were

tested at frontal electrode Fz in the 250–350 ms time window following stimulus onset. In the healthy controls, grand-means ERPs were compared statistically at each time point (1 time point = 0.97 ms) with paired *t* test to determine differences in response to the three stimulus types over the whole group. In the patients, single-trial epochs were compared statistically at each time point with unpaired *t*-test for dependent samples in each patient to determine individual differences in response to the three stimulus types. *p* values were corrected for multiple comparisons ($p < 0.017$) and were considered if they persisted over at least 20 ms to reduce the risk of false-positive effects (Rossell et al. 2003; James et al. 2009).

Image Data Processing

Structural magnetic resonance images and DTI scans were acquired on a Siemens 3.0-Tesla Trio scanner (Siemens Medical Solutions, Erlangen, Germany). Head support was applied to reduce head motion. The protocol contained a high-resolution T1-weighted, 3-D gradient-echo with magnetization preparation (MPRAGE) sequence covering the whole skull for creation of the head models used in the source estimation analysis; 192 slices of 1.1 mm thickness were obtained in coronal plane, with a repetition time (TR) of 2,500 ms, echo time (TE) of 3 ms, inversion time (TI) of 1,100 ms, and acquisition time (AT) of 5 min 9 s. DTI acquisition consisted of echo planar imaging (EPI) sequence using monopolar diffusion gradients in 30 directions (b -value = 1,000 s/mm²); 60 axial slices were acquired parallel to the AC-PC line, with slice thickness of 2 mm, an in plane resolution of 1.8×1.8 mm², and TR, TE and AT of 8,200, 82 ms, and 4 min 40 s, respectively. No normalization were performed on the acquired images.

Image Data Analysis

ROI-Based Analysis

Fractional anisotropy (FA) maps were computed with the Diffusion Toolkit v0.6.2.1 software (<http://trackvis.org/>) using the deterministic Interpolated Streamline algorithm (Conturo et al. 1999). To further constrain the course of fiber tracts, an angle threshold of 15 degrees was applied. Visualization and analysis of the bundles were then carried out by the TrackVis v0.5.2.1 Toolbox (<http://trackvis.org/>).

A multiple region of interest (ROI) method was used to ensure precise delimitation of the fornix (Jones et al. 2005; Fitzsimmons et al. 2009). Three ROIs (depicted by disks of a radius of approximately 3.5 cm) were defined and only the tracts that run through all ROIs were selected. ROIs were delimited as follows: the first ROI was positioned on the coronal plane of the anterior descending part of the fornix body; the second ROI was placed on the sagittal plane of the

fornix crura at its curvature, such that the fornix bundles passed perpendicularly to the ROI; the third ROI was positioned at the junction of the crura with the hippocampal tail in a coronal plane making an angle of 45 degrees with the sagittal plane. After extraction of the fornix tracts, for each subject, the mean FA value of all voxels along the reconstructed tract and the number of tracts (NT) were measured for the whole tract as well as for the right and left fornix separately.

Statistical procedures were then performed using Matlab[®] R2011a (The MathWorks, Inc., Natick, Massachusetts, USA, <http://www.mathworks.com>) in order to test for differences in FA mean and in NT within each side of the fornix comparing individually each patient and each alcoholic patient with the healthy controls group. We first subtracted the response of interest (either mean FA or NT) for each WKS patient and each alcoholic patient from the values of each subject of the healthy group, resulting in sets, D , of 12 differences for each patient (D_p with $p = \{1,2,3,4\}$) and for each alcoholic subject (D_a with $a = \{1,2\}$). Then, we applied a normality test on D_p and D_a : the null hypothesis of normality was rejected (with and without Bonferroni correction) for the left fornix in WKS patients and alcoholic subjects (NT and FA, $p < 0.02$), therefore, a non parametric test, the Wilcoxon signed-rank test, was selected.

Tract-Based Spatial Statistics Analysis

Tract-based spatial statistics (TBSS) analysis of the DTI data was carried out using standard procedures and standard parameters using the FSL software package (Smith et al. 2004), as described in detail before (Smith et al. 2006, 2007). In principle, TBSS performs a spatial normalization of the DTI data, which is the prerequisite for voxel-wise image comparison between subjects. In order to reduce potential mis-registrations as the source for false-positive or false-negative analysis results, TBSS reconstructs a group average skeleton of the brain, which consists of the most important white matter tracts. TBSS then projects all individual FA data onto this mean FA tract skeleton using non-linear registration. Voxel-wise statistical analyses were corrected for multiple comparisons implementing threshold-free cluster enhancement (TFCE) considering fully corrected *p* values < 0.05 as significant (Smith and Nichols 2009). Age and gender were used as non-explanatory co-regressors.

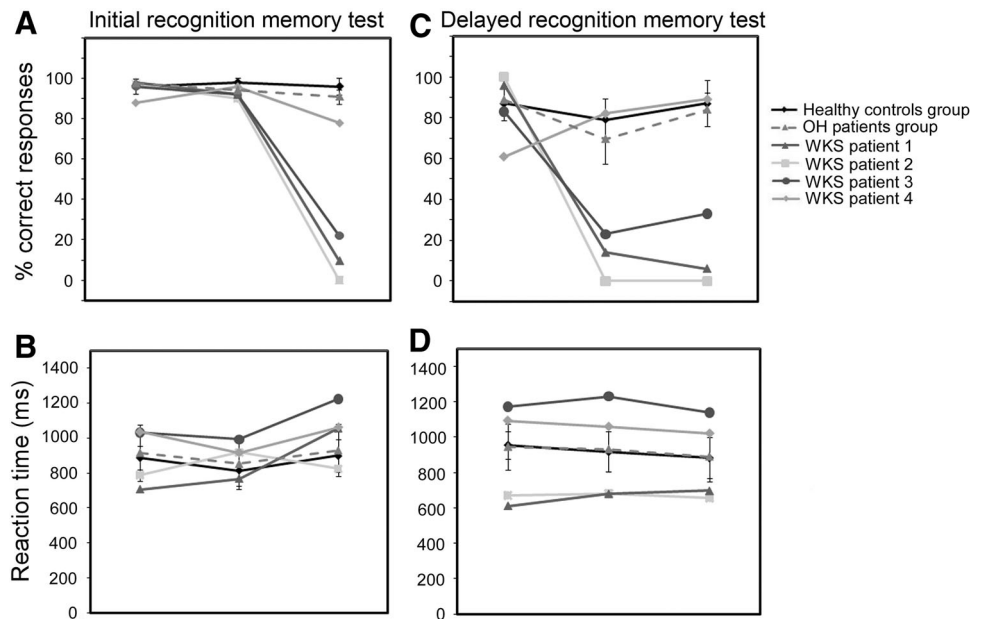
Results

Behaviour

Initial Recognition Test

Healthy subjects recognized immediate repetitions (One-back items) more rapidly and tended to recognize them

Fig. 1 Behavioural results. (a) accuracy in the initial recognition memory test (b) reaction time in the initial recognition memory test (c) accuracy in the delayed recognition memory test (d) reaction time in the delayed recognition memory test. Vertical bar depicts the standard deviation of the mean for the healthy control group and the alcoholic patients group. WKS Wernicke–Korsakoff patient, OH alcoholic patient



more accurately than delayed repetitions (Ten-back items vs. One-back items: accuracy, $F(1,9) = 4.8$; $p = 0.057$, reaction time, $F(1,9) = 73.5$; $p < 0.001$) and new items (accuracy, $F(1,9) = 4.4$; $p = 0.06$, reaction time, $F(1,9) = 22.4$; $p = 0.001$) (Fig. 1a).

The four patients with WKS recognized One-back items more accurately than Ten-back items. Figure 1a indicates that recognition of delayed repetition was severely impaired in all patients with WKS compared to controls (controls, 96 ± 4.2 % correct responses; WKS patients, 27 ± 35 %; Mann–Whitney U test, $U = 0$, $p = 0.005$). In particular, WKS patients 1 and 2 recognized less than 10 % of the Ten-back items (patient 1, 9.5 % correct recognitions; patient 2, no correct recognition). Recognition of immediate repetitions was also slightly worse in patients with WKS than healthy controls (controls, 98 ± 2 % correct responses; WKS patients, 91 ± 2.5 %; Mann–Whitney U test, $U = 2$, $p = 0.01$). By contrast, correct rejection of new pictures (new items) did not significantly differ between the two groups (controls, 95.5 ± 3.9 % correct responses; WKS patients, 94.75 ± 4.6 %; Mann–Whitney U test, $U = 14.5$, $p = 0.44$). Reaction times did not significantly differ between the two groups (Fig. 1b, all $U > 8$; $p > 0.05$).

Alcoholic patients did not significantly differ from the healthy control group on accuracy (New, 97 ± 2.2 % of correct responses; One-back items, 94 ± 3.4 %; Ten-back items, 91 ± 3.5 %) or reaction time (New, 916 ± 162 ms; One-back items, 852.5 ± 147 ms; Ten-back items, 931 ± 141 ms) over all stimulus types (Mann–Whitney U test, all comparisons, $U > 10$; $p > 0.05$).

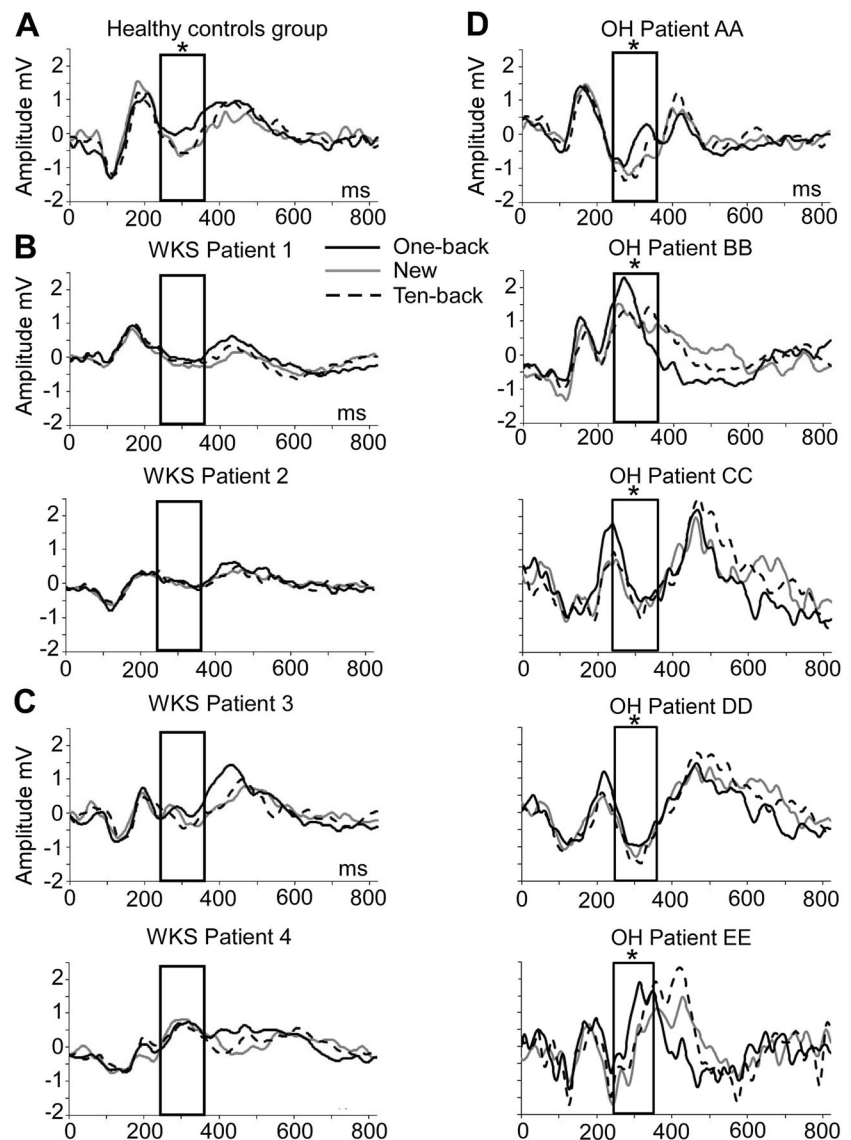
Delayed Recognition Test

Thirty minutes after the continuous recognition tasks (learning task), the healthy control participants recognized Ten-back better and faster than One-back items (accuracy, Fig. 1c, $F(1,9) = 22.4$; $p = 0.001$; reaction time, Fig. 1d, $F(1,9) = 20.8$; $p = 0.001$), confirming the presence of a spacing effect. Alcoholic patients did not differ from normal controls in terms of accuracy (New, 89.2 ± 7.3 % of correct responses; One-back items, 68.8 ± 13.3 %; Ten-back items, 84 ± 8.1 %) or reaction time (New, 950 ± 131 ms; One-back items, 939 ± 136 ms; Ten-back items, 890.8 ± 143.9 ms; Mann–Whitney U test, all comparisons, $U > 11$; $p > 0.05$).

As a group, the patients with WKS recognized both One-back and Ten-back items from the initial test less accurately than healthy controls (One-back items, controls, 79.5 ± 10.5 % correct recognitions; WKS patients, 29.8 ± 36.1 %; Mann–Whitney U test, $U = 6$, $p = 0.048$; Ten-back items, controls, 87.2 ± 11.2 % correct; WKS patients, 32 ± 40.6 %, $U = 5$, $p = 0.034$). Individually, however, patient 4 had a score in the controls' range (Fig. 1c). Again, WKS patients 1 and 2 recognized less than 10 percent of the Ten-back items (patient 1, 6 % correct recognitions; patient 2, no correct recognition). They recognized less than 15 % of the One-back items (patient 1, 14 % correct recognitions; patient 2, no correct recognition).

Correct rejection of new pictures (New items) (controls, 87 ± 8.3 % of correct responses; WKS patients, 85 ± 17.6 %; Mann–Whitney U test, $U = 18.5$, $p = 0.83$)

Fig. 2 ERPs results. ERP Waveforms in response to the three types of items at electrode Fz (a) in the healthy controls group (b) in the two patients with Wernicke–Korsakoff syndrome (WKS patients 1 and 2) who did have the lower proportion retention of items (c) in the two patients with Wernicke–Korsakoff syndrome (WKS patients 3 and 4) who did have the higher proportion retention of items (d) in the five alcoholic patients (OH patients AA, BB, CC, DD and EE). The black boxes delimit the period of interest between 250 and 350 ms. $*p < 0.05$



and reaction times (Fig. 1d, all $U > 20$; $p > 0.05$) did not significantly differ between the two groups.

Event-Related Potentials

As expected from the previous study with young subjects (James et al. 2009), there was an early frontal positivity between approximately 250 ms and 350 ms induced by One-back items on frontal electrodes in every control participant (Fig. 2a for the Grand Mean) and alcoholic control subject (Fig. 2d). Paired t -tests between mean amplitudes of the ERP responses associated with One-back items and the two other stimulus types in this time window at electrode Fz confirmed the specificity of this electrocortical response in favour of One-back items in the healthy control group (all $p < 0.017$). Unpaired t -tests on the amplitude of all ERP responses in response to One-back

items and the two other types of items indicated that this effect was present in all healthy participants (participants 1–10) (all $p < 0.017$, except for the contrast One-back > Ten-back items, which was non-significant in healthy participant 1 and significant at $p < 0.05$ in participants 6 and 9; the contrast One-back > New items was significant at $p < 0.05$ in healthy participants 6 and 10).

In the five alcoholic control subjects, unpaired t tests on the amplitude of all ERP responses associated with One-back items and the two other types of items also confirmed this effect, (all $p < 0.017$, except for OH patients DD and CC: $p < 0.05$).

In contrast to healthy participants and alcoholic control subjects, this early evoked potential response was absent in WKS patients 1 and 2 (Fig. 2b) and delayed in patients 3 and 4 (Fig. 2c). Unpaired t -tests between ERP amplitudes associated with One-back items and the two other item

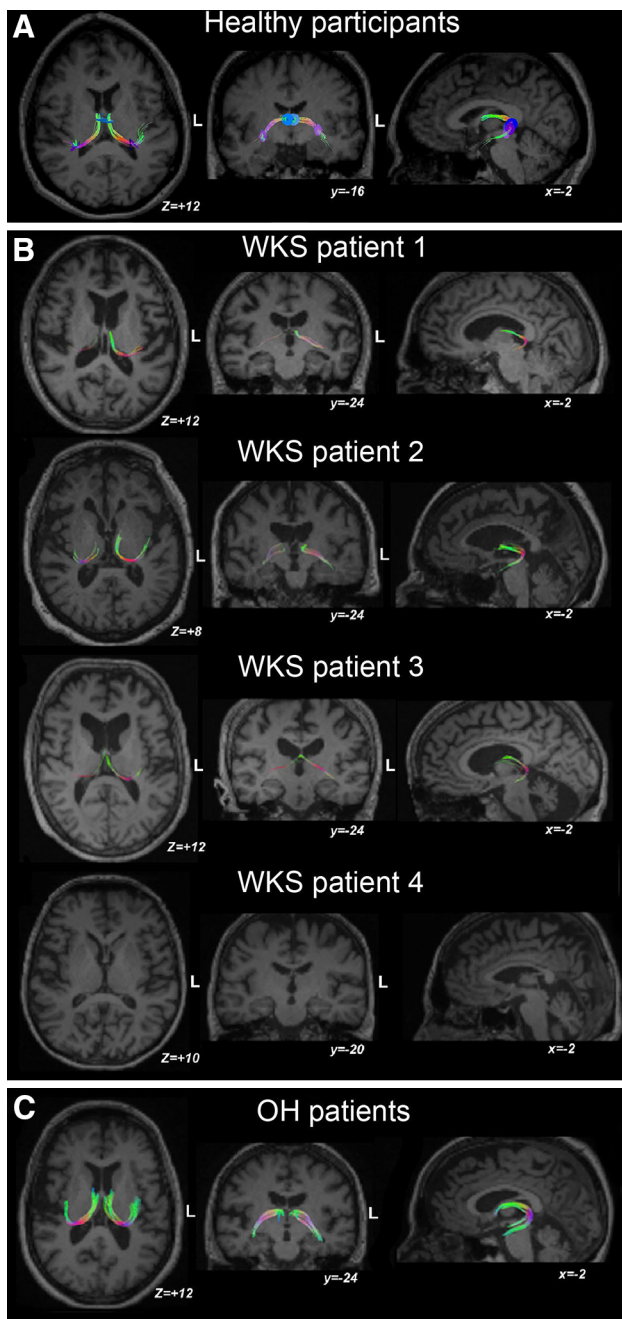


Fig. 3 (a) Fornix illustration of the median of the healthy control group compared to (b) each patient with Wernicke–Korsakoff (WKS) patients 1–4 (c) and to alcoholic patients. Coordinates (x, y, z) are given in Talairach space

types revealed no statistical differences in the 250–350 ms time window in any WKS patient (all $p > 0.05$). Unpaired t-tests over the period from 250 ms to 800 ms revealed a larger amplitudes in response to One-back items than the two other item types between 400 and 500 ms WKS patients 3 and 4, who demonstrated less severe amnesia in the experimental ($p < 0.05$, see Fig. 1) and the standardized memory test (see Table 1). There was no significant

difference between Ten-back items and New items in the 250–350 ms time window in healthy participants, alcoholic control subjects, or the WKS patients (all $p > 0.05$).

Diffusion Tensor Imaging

Figure 3a, b shows that each WKS patient had a significant reduction of number of tracts (NT) in the fornix on both sides compared to healthy controls (right side, $p < 0.001$; left side, $p = 0.013$). Mean FA was reduced across the patients and on both sides ($p < 0.001$), except for the right fornix of patient 1 ($p = 0.176$). NT of the fornix of the alcoholic patients did not differ from healthy controls ($p > 0.001$) except for the right fornix of alcoholic patient BB ($p = 0.009$, Fig. 3c). Mean fornix FA was significantly reduced in alcoholic patients AA and BB for both fornix and in alcoholic patients CC and EE for the left fornix compared to the healthy controls ($p < 0.005$).

Tract-Based Spatial Statistics Analysis

Group comparison for FA skeleton maps revealed significant FA reductions of the fornix on both sides in patients with WKS compared to healthy controls or alcoholic patients ($p < 0.05$ TFCE corrected).

Discussion

The present study provides new evidence for the hypothesis that anterograde amnesia in WKS emanates from disconnection of the MTL resulting from disrupted neural circuits that connect the diencephalon with the hippocampal formation (Warrington and Weiskrantz 1982; Kessels and Kopelman 2012). In contrast to healthy controls and non-amnesic alcoholic participants, patients with WKS failed to activate the left MTL upon immediate picture repetition, as manifested by the absence of an early electrical potential emanating from the left MTL (James et al. 2009; Nahum et al. 2011). The lack of MTL activity was associated with bilateral fibre damage in the fornix, as reflected by fractional anisotropy and number of tract estimation.

The present study replicates previous findings that immediate repetition of a visual stimulus induces an early frontal electrical potential (James et al. 2009; Kim et al. 2001), although the onset of this potential was 50 ms later than in our previous study (James et al. 2009), occurring around 250–350 ms. The delay parallels slower reaction times in the present study (814 ± 90 ms) and presumably reflects the fact that the present control group was considerably older (mean age 18 years higher). Patients with very severe amnesia (patients 1 and 2) did not have this potential. Conversely, the two patients with

residual long term retention (patients 3 and 4) had a delayed potential around 400 and 500 ms, respectively. The observation underscores the functional importance of this potential.

Immediate picture repetition was also associated with less efficient delayed recognition of these pictures that pictures repeated after nine intervening pictures in the healthy subjects. As previously argued (James et al. 2009; Nahum et al. 2011), immediate stimulus repetition apparently interferes with an ongoing consolidation process involving the MTL which has to continue off-line in order to be fully efficient. This process may involve cortical networks, as indirectly indicated by abnormal network activation in amnesia (Barcellona-Lehmann et al. 2010). The fornix, affected in all WKS patients of the present study, is likely to be central for these interactions. It is a key structure of the limbic Papez circuit (Papez 1937; Aggleton and Brown 1999), which is important for memory, in particular recollection-based memory (Brown et al. 2010). It allows the diencephalon to communicate with the MTL, including the hippocampus (Brown et al. 2010). Via the fornix, the hippocampus is connected with the mammillary bodies, the septal region, the prefrontal cortex, and the nucleus accumbens. Lesions within this circuit may induce severe amnesia (Moudgil et al. 2000; Yoneoka et al. 2004; Rahme et al. 2007; Renou et al. 2008). Atrophy of the fornix is specifically associated with the degree of amnesia in mild cognitive impairment (Metzler-Baddeley et al. 2012) and fronto-temporal dementia (Hornberger et al. 2012). Our findings suggest that such damage prevents the hippocampal complex from executing its normal function of memory consolidation. Our findings are also compatible with the observation of patients suffering from WKS, who have normal structural MRI with an apparently intact MTL (Antunez et al. 1998; Caulo et al. 2005), similar to three of our four patients. MTL disconnection due to fornix damage may presumably explain decreased MTL metabolism in WKS (Heiss et al. 1992; Lechevalier et al. 2000; Reed et al. 2003) and the MTL atrophy observed in several studies (Sullivan and Marsh 2003; Visser et al. 1999). The present study, using an experimental paradigm known to involve the MTL, provides direct evidence in favour of these hypotheses. However, future neuroimaging studies using high spatial resolution methods and large sample of patients should hopefully confirm these hypotheses and the link between immediate repetition of visual stimuli and hippocampal activation. The present results are also congruent with a previous fMRI study indicating absence of MTL activation during a recognition task in a patient with WKS who had damage to the thalamus, the mammillary bodies, and the fornix as revealed by MRI (Caulo et al. 2005). In the present study, only one patient had circumscribed damage at structural

MRI (patient 1, mammillary bodies and medial thalamus). In comparison, DTI identified fornix abnormalities in all patients with WKS, which plausibly explain the MTL hypoactivation revealed by the ERPs.

In conclusion, the present results support a disconnection hypothesis of anterograde amnesia in WKS: patients with WKS did not produce an electrophysiological response which is evoked in healthy subjects and had diffusion abnormalities in the fornix. The findings reconcile divergent views on anterograde amnesia in WKS interpreting it either as a diencephalic or hippocampal disorder.

Acknowledgments Study supported by Swiss National Science Foundation Grant no. 320030-132447 to AS and by the Center for Biomedical Imaging (CIBM) of the Geneva and Lausanne Universities, the EPFL and the Geneva and Lausanne University Hospitals.

References

- Aggleton JP, Brown MW (1999) Episodic memory, amnesia, and the hippocampal–anterior thalamic axis. *Behav Brain Sci* 22:425–444
- Antunez E, Estruch R, Cardenal C et al (1998) Usefulness of CT and MR imaging in the diagnosis of acute Wernicke's encephalopathy. *Am J Roentgenol* 171:1131–1137
- Army Individual Test Battery (1944) Manual of Directions and Scoring. War Department, Adjutant General's Office, Washington, DC
- Aupée AM, Desgranges B, Eustache F et al (2001) Voxel-based mapping of brain hypometabolism in permanent amnesia with PET. *Neuroimage* 13:1164–1173
- Barcellona-Lehmann S, Morand S, Bindschaedler C et al (2010) Abnormal cortical network activation in human amnesia: a high-resolution evoked potential study. *Brain Topogr* 23:72–81. doi:10.1007/s10548-009-0124-3
- Benson DF, Djenderedjian A, Miller BL et al (1996) Neural basis of confabulation. *Neurology* 46:1239–1243
- Brown MW, Warburton EC, Aggleton JP (2010) Recognition memory: material, processes, and substrates. *Hippocampus* 20:1228–1244. doi:10.1002/hipo.20858
- Caulo M, Van Hecke J, Toma L et al (2005) Functional MRI study of diencephalic amnesia in Wernicke-Korsakoff syndrome. *Brain* 128:1584–1594
- Christie JE, Kean DM, Douglas RH et al (1988) Magnetic resonance imaging in pre-senile dementia of the Alzheimer-type, multi-infarct dementia and Korsakoff's syndrome. *Psychol Med* 18:319–329
- Colchester A, Kingsley D, Lasserson D et al (2001) Structural MRI Volumetric Analysis in Patients with Organic Amnesia, 1: methods and Comparative Findings Across Diagnostic Groups. *J Neurol Neurosurg Psychiatry* 71:13–22. doi:10.1136/jnnp.71.1.13
- Conturo TE, Lori NF, Cull TS et al (1999) Tracking neuronal fiber pathways in the living human brain. *Proc Natl Acad Sci USA* 96:10422–10427
- Crowder RG (1976) Principles of learning and memory. Lawrence Erlbaum Associates, Hillsdale
- Fitzsimmons J, Kubicki M, Smith K et al (2009) Diffusion tractography of the fornix in schizophrenia. *Schizophr Res* 107:39–46. doi:10.1016/j.schres.2008.10.022
- Folstein MF, Folstein SE, McHugh PR (1975) "Mini-mental state": a practical method for grading the cognitive state of patients for the clinician. *J Psychiatr Res* 12(3):189–198

- Gamper E (1928) Zur Frage der Polioencephalitis haemorrhagica der chronischen Alkoholiker. Anatomische Befunde beim alkoholischen Korsakow und ihre Beziehungen zum klinischen Bild. *Dtsch Z Nervenheilk* 102:122–129
- Greene RL (1989) Spacing effects in memory: evidence for a two-process account. *J Exp Psychol Learn Mem Cogn* 15:371–377
- Halavaara J, Brander A, Lyytinen J et al (2003) Wernicke's encephalopathy: is diffusion-weighted MRI useful? *Neuroradiology* 45:519–523
- Harding A, Halliday G, Caine D, Kril J (2000) Degeneration of anterior thalamic nuclei differentiates alcoholics with amnesia. *Brain* 123:141–154
- Heiss WD, Pawlik G, Holthoff V et al (1992) PET correlates of normal and impaired memory functions. *Cerebrovasc Brain Metab Rev* 4:1–27
- Hornberger M, Wong S, Tan R et al (2012) In vivo and post-mortem memory circuit integrity in frontotemporal dementia and Alzheimer's disease. *Brain* 135:3015–3025
- Hunter R, McLuskie R, Wyper D et al (1989) The pattern of function-related regional cerebral blood flow investigated by single photon emission tomography with 99mTc-HMPAO in patients with presenile Alzheimer's disease and Korsakoff's psychosis. *Psychol Med* 19:847–855
- Jacobson RR, Lishman WA (1990) Cortical and diencephalic lesions in Korsakoff's syndrome: a clinical and CT scan study. *Psychol Med* 20:63–75
- James C, Morand S, Barcellona-Lehmann S, Schnider A (2009) Neural transition from short to long term memory: an ERP study. *Hippocampus* 19:371–378
- Jernigan TL, Schafer K, Butters N, Cermak LS (1991) Magnetic resonance imaging of alcoholic Korsakoff patients. *Neuropsychopharmacology* 4:175–186
- Jones DK, Catani M, Pierpaoli C et al (2005) A diffusion tensor magnetic resonance imaging study of frontal cortex connections in very-late-onset schizophrenia-like psychosis. *Am J Geriatr Psychiatry* 13:1092–1099
- Kessels RPC, Kopelman MD (2012) Context memory in Korsakoff's syndrome. *Neuropsychol Rev* 22:117–131. doi:10.1007/s11065-012-9202-5
- Kim M, Kim J, Kwon JS (2001) The effect of immediate and delayed word repetition on event-related potential in a continuous recognition task. *Brain Res Cogn Brain Res* 11:387–396
- Kopelman MD (1995) The Korsakoff syndrome. *Br J Psychiatry* 166:154–173
- Kopelman MD, Wilson BA, Baddeley AD (1989) The autobiographical memory interview: a new assessment of autobiographical and personal semantic memory in amnesic patients. *J Clin Exp Neuropsychol* 11:724–744
- Lechevalier B, Aupee AM, de la Sayette V et al (2000) Function imaging of the hippocampus in Korsakoff's syndrome. *Bull Acad Natl Med* 184:1491–1497
- Mair WG, Warrington EK, Weiskrantz L (1979) Memory disorder in Korsakoff's psychosis: a neuropathological and neuropsychological investigation of two cases. *Brain* 102:749–783
- Matsuda K, Yamaji S, Ishii K et al (1997) Regional cerebral blood flow and oxygen metabolism in a patient with Korsakoff syndrome. *Ann Nucl Med* 11:33–35
- Mayes AR, Meudell PR, Mann D, Pickering A (1988) Location of lesions in Korsakoff's syndrome: neuropsychological and neuropathological data on two patients. *Cortex* 24:367–388
- Metzler-Baddeley C, Hunt S, Jones DK et al (2012) Temporal association tracts and the breakdown of episodic memory in mild cognitive impairment. *Neurology* 79:2233–2240
- Moudgil SS, Azzouz M, Al-Azzaz A et al (2000) Amnesia due to fornix infarction. *Stroke* 31:1418–1419
- Nahum L, Gabriel D, Spinelli L et al (2011) Rapid consolidation and the human hippocampus: intracranial recordings confirm surface EEG. *Hippocampus* 21:689–693. doi:10.1002/hipo.20819
- Paller KA, Acharya A, Richardson BC et al (1997) Functional neuroimaging of cortical dysfunction in alcoholic Korsakoff's syndrome. *J Cogn Neurosci* 9:277–293. doi:10.1162/jocn.1997.9.2.277
- Papez JW (1937) A proposed mechanism of emotion. *Arch Neurol Psychiat* 38:725–743
- Perrin F, Pernier J, Bertrand O et al (1987) Mapping of scalp potentials by surface spline interpolation. *Electroencephalogr Clin Neurophysiol* 66:75–81
- Rahme R, Moussa R, Awada A et al (2007) Acute Korsakoff-like amnesic syndrome resulting from left thalamic infarction following a right hippocampal hemorrhage. *Am J Neuroradiol* 28:759–760
- Reed LJ, Lasserson D, Marsden P et al (2003) FDG-PET findings in the Wernicke–Korsakoff syndrome. *Cortex* 39:1027–1045. doi:10.1016/s0010-9452(08)70876-1
- Regard M, Strauss E, Knapp P (1982) Children's production on verbal and non-verbal fluency tasks. *Percept Mot Skills* 55:839–844
- Renou P, Ducreux D, Batouche F, Denier C (2008) Pure and acute Korsakoff syndrome due to a bilateral anterior fornix infarction: a diffusion tensor tractography study. *Arch Neurol* 65:1252–1253
- Rossell SL, Price CJ, Nobre AC (2003) The anatomy and time course of semantic priming investigated by fMRI and ERPs. *Neuropsychologia* 41:550–564
- Schnider A (2008) *The confabulating mind. How the brain creates reality.* Oxford University Press, Oxford
- Schnider A, Nahum L, Pignat JM et al (2013) Isolated prospective confabulation in Wernicke–Korsakoff syndrome: a case for reality filtering. *Neurocase* 19:90–104
- Smith SM, Nichols TE (2009) Threshold-free cluster enhancement: addressing problems of smoothing, threshold dependence and localisation in cluster inference. *Neuroimage* 44:83–98. doi:10.1016/j.neuroimage.2008.03.061
- Smith SM, Jenkinson M, Woolrich MW et al (2004) Advances in functional and structural MR image analysis and implementation as FSL. *Neuroimage* 23(Suppl 1):S208–S219
- Smith SM, Jenkinson M, Johansen-Berg H et al (2006) Tract-based spatial statistics: voxelwise analysis of multi-subject diffusion data. *Neuroimage* 31:1487–1505
- Smith SM, Johansen-Berg H, Jenkinson M et al (2007) Acquisition and voxelwise analysis of multi-subject diffusion data with tract-based spatial statistics. *Nat Protoc* 2:499–503. doi:10.1038/nprot.2007.45
- Snodgrass JG, Vanderwart M (1980) A standardized set of 260 pictures: norms for name agreement, image agreement, familiarity, and visual complexity. *J Exp Psychol Hum Learn Mem* 6:174–215
- Squire LR, Amaral DG, Press GA (1990) Magnetic resonance imaging of the hippocampal formation and mammillary nuclei distinguish medial temporal and diencephalic amnesia. *J Neurosci* 10:3106–3117
- Sullivan EV, Marsh L (2003) Hippocampal volume deficits in alcoholic Korsakoff's syndrome. *Neurology* 61:1716–1719
- Sullivan EV, Pfefferbaum A (2009) Neuroimaging of the Wernicke–Korsakoff syndrome. *Alcohol Alcohol* 44:155–165. doi:10.1093/alcalc/agn103
- Thurstone LL, Thurstone TG (1962) *Primary mental abilities* (Rev.). Science Research Associates, Chicago
- Victor M, Adams RD, Collins GH (1989) *The Wernicke-Korsakoff syndrome*, 2nd edn. F.A Davis, Philadelphia
- Visser PJ, Krabbendam L, Verhey FRJ et al (1999) Brain correlates of memory dysfunction in alcoholic Korsakoff's syndrome. *J Neurol Neurosurg Psychiatry* 67:774–778. doi:10.1136/jnnp.67.6.774

- Warrington EK, Weiskrantz L (1982) Amnesia: a disconnection syndrome? *Neuropsychologia* 20:233–248
- Wechsler D (1945) A standardized memory scale for clinical use. *J Psychol* 19:87–95
- Welsh KA, Butters N, Mohs RC et al (1994) The consortium to establish a registry for Alzheimer's disease (CERAD). Part V. A normative study of the neuropsychological battery. *Neurology* 44:609–614
- Wijnia JW, Goossensen A (2010) Cerebellar neurocognition and Korsakoff's syndrome: an hypothesis. *Med Hypotheses* 75:266–268. doi:[10.1016/j.mehy.2010.02.035](https://doi.org/10.1016/j.mehy.2010.02.035)
- Yoneoka Y, Takeda N, Inoue A et al (2004) Acute Korsakoff syndrome following mammillothalamic tract infarction. *Am J Neuroradiol* 25:964–968