

Multilocular sinonasal malignant melanoma: a poor prognostic subgroup?

O. Stanimirov Rossi · Domenic Vital · M. B. Soyka ·
T. N. Roth · G. F. Huber · D. Holzmann

Received: 19 February 2014 / Accepted: 8 May 2014 / Published online: 29 May 2014
© Springer-Verlag Berlin Heidelberg 2014

Abstract Clinical observations show that two subtypes of sinonasal malignant melanoma exist: uni- and multilocular melanoma. The aim of this retrospective study was to determine the prevalence and outcome of multilocular sinonasal malignant melanoma. All patients with sinonasal malignant melanoma treated at our institution between 1992 and 2011 were included. Survival and recurrence data were analyzed related to the distribution pattern of the tumors and other factors. Twenty-five patients were identified and included in the analysis. Seven patients (28 %) suffered from multilocular, the remaining 18 patients (72 %) from unilocular sinonasal malignant melanoma. The first group showed a significantly worse disease-free survival, whereas disease-specific and overall survival did not differ between the two subtypes. Multilocular sinonasal malignant melanoma is associated with an unfavorable disease-free survival compared to its unilocular counterpart.

Keywords Sinonasal malignant melanoma · Multilocularity · Prevalence · Outcome

Introduction

Mucosal melanomas account for about 1 % of all malignant melanomas and approximately 4 % of malignant sinonasal

tumors [1, 2]. It can arise from the epithelial surfaces of the head and neck area, the genitourinary tract and the anorectum [3, 4]. Fifty-five percent of all mucosal melanomas are localized in the head and neck area, of which one-third are oral mucosal melanomas and two-thirds sinonasal malignant melanomas (SNMM) [1, 2, 5, 6]. The latter represents a highly aggressive subgroup of this disease [1, 2] and, consequently, a diagnostic and therapeutic challenge for all involved specialists.

Regarding clinical observations, two distribution patterns of mucosal malignant melanoma exist: (a) uni- and (b) multilocular malignant melanoma [7, 8]. The latter were arbitrarily defined in the past in the context of genitourinary tract melanomas as tumors with growth in multiple locations at initial diagnosis or local recurrence outside the scar tissue [8]. However, the prevalence of multilocular sinonasal malignant (mSNMM) melanomas as well as its therapeutic and prognostic implications were not studied in detail.

Surgery (either open or endoscopic) has been shown to be the first-line treatment [2, 6, 9], whereas postoperative radiotherapy or radiotherapy alone have been discussed controversially. Some studies have shown increased local tumor control without increase in overall survival [3, 10–13], whereas others did not find any better local control with postoperative radiotherapy [1, 2, 14].

The aim of this study was to determine the prevalence of mSNMM, to analyze its outcome in relation to patients with unilocular sinonasal malignant melanoma (uSNMM) and to assess potential implications regarding its treatment.

Materials and methods

The ethical committee of the local authority permits retrospective studies on patient data as long as they are imposed

O. Stanimirov Rossi and D. Vital contributed equally to this study.

O. Stanimirov Rossi · D. Vital (✉) · M. B. Soyka · T. N. Roth ·
G. F. Huber · D. Holzmann
Department of Otorhinolaryngology, Head and Neck Surgery,
Zurich University Hospital, Frauenklinikstrasse 24,
8091 Zurich, Switzerland
e-mail: domenic.vital@usz.ch

by a member of the treatment institution and as long as anonymized data are used. All patients with SNMM treated at our institution between 1992 and 2011 were included in this study. Patients with mucosal malignant melanoma of the head and neck area other than SNMM were excluded, also those with SNMM and incomplete data or primarily palliative treatment. The medical records were reviewed for age, gender, pigmentation of SNMM (melanotic vs. amelanotic), origin and distribution pattern of SNMM (uni- vs. multilocular), treatment modalities such as outcome parameters. A multilocular distribution pattern was defined as the presence of multiple lesions with different localizations at the initial diagnosis, whereas the criterion of a margin free of cells of malignant melanoma between the lesions had to be fulfilled. Loco-regional tumor control and survival were analyzed with respect to the following factors: age, gender, pigmentation of SNMM, origin, distribution pattern and modality of therapy (i.e., the surgical approach and the use of a postoperative radiotherapy). Due to the complex anatomical region of the sinonasal system, it was not possible to obtain surgical margins as recommended in the treatment of cutaneous malignant melanoma. Therefore, surgical margins were defined arbitrarily: after resection of the tumor, resection margins were assessed separately. If they were found to be free of tumor upon histological examination, we considered the removal to be R0. In cases, in which the SNMM could macroscopically be removed completely with the inability to obtain an additional marginal specimen (i.e., due to the proximity of vital structures), margins were classified to be “close”.

Differences in the two different groups of patients (uni- vs. multilocular) at time of the initial treatment were assessed using Fisher's exact, the Chi-square (nominal variables) and Mann–Whitney *U* tests (age). Kaplan–Meier curves were assessed using the Cox regression analysis (age) and the log-rank test (all other factors) to analyze the outcome of the two patient groups.

Results

Baseline characteristics

Twenty-five patients were identified and included in the analysis. The tumors of 7 patients (28 %) were defined as mSNMM, the remaining 18 patients (72 %) as uSNMMs. Their characteristics are shown in Tables 1 and 2. Statistical analysis did not reveal any significant differences between uSNMM and mSNMM except for the frequency of sufficient, close or insufficient surgical margins ($P < 0.001$) and the use of a postoperative radiotherapy ($P = 0.007$). All patients with close or insufficient surgical excision, except for one 82-year-old woman, underwent postoperative radiotherapy. This female patient refused a postoperative

radiation. A further patient with uSNMM and sufficient surgical margins underwent postoperative radiation due to extension of the primary into the maxillary sinus.

Loco-regional tumor control

Loco-regional tumor control failed in 15 patients (60 %), of whom 3 patients (12 %) showed persistence after the first-line therapy and 12 patients presented with local recurrence (48 %). Of the patients with failure of local tumor control, additional three patients (12 %) developed delayed lymph node metastasis of the neck during follow-up. Loco-regional tumor control of patients with mSNMM was non-significantly lower compared to patients with uSNMM ($P = 0.094$). Age, gender, tumor origin and pigmentation, surgical approach and postoperative radiotherapy did not have any significant influence on loco-regional tumor control.

Distant metastasis

14 (56 %) out of the 25 patients developed distant metastases during the follow-up period. Distribution pattern such as all the other analyzed factors had no influence on the development of distant metastases.

Disease-free survival

Overall disease-free survival (DFS) was 58.7 % after 1 year, 32.6 % after 2 years and 18.6 % after 5 years (Fig. 1). A trend was observed comparing the DFS of patients with amelanotic and melanotic melanoma with the latter showing better results ($P = 0.068$). Patients with mSNMM showed a significantly inferior DFS compared to patients with uSNMM ($P = 0.023$), representing a DFS of 28.6 % after 1 year such as 14.6 % after 2 and 5 years in patients with mSNMM compared to 70.6, 41.2 and 23.5 %, respectively, in patients with uSNMM (Fig. 2). All the other analyzed factors did not show any significant influence on DFS.

Disease-free and overall survival

Only three deaths were reported to be disease-related, resulting in a disease-specific survival (DSS) of 95.7 % after 1 and 2-years and 87.7 % after 5 years. With only three disease-related deaths, the number of incidents was too small to perform a statistical analysis.

Overall survival (OS) was 95.4 % after 1 year, 72.1 % after 2 years and 55.4 % after 5 years. Mean survival was 67 months (95 % CI 46–88 months). Multilocularity such as all the other analyzed factors did not show a statistically significant effect on DSS and OS (Fig. 1).

Table 1 Characteristics of patients with SNMM

	All patients (<i>n</i> = 25 patients)	Uni-SNMM (<i>n</i> = 18 patients)	Multi-SNMM (<i>n</i> = 7 patients)	Statistical significance
Age	65.9 ± 12.4 years	65.9 ± 11.6 years	65.9 ± 15.2 years	<i>P</i> = 0.79
Female/male	17/8 patients (68/32 %)	13/5 patients (72/28 %)	4/3 patients (57/43 %)	<i>P</i> = 0.64
Histology				
Amelanotic	8 patients (32 %)	5 patients (28 %)	3 patients (43 %)	<i>P</i> = 0.66
Melanotic	16 patients (64 %)	12 patients (67 %)	4 patients (57 %)	
N/a	1 patient (4 %)	1 patient (6 %)		
Tumor origin				<i>P</i> = 0.20
Nasal cavity	15 patients (60 %)	9 patients (50 %)	6 patients (86 %)	
Paranasal sinuses	5 patients (20 %)	4 patients (22 %)	1 patient (14 %)	
Nasal septum	5 patients (20 %)	5 patients (28 %)		
KIT mutation ^a	0 patients (0 %)			
BRAF mutation ^b	0 patients (0 %)			
NRAS mutation ^b	1 patient (4 %)		1 patient (14 %)	
N + neck at diagnosis	0 patients (0 %)			<i>P</i> = 1.00
Surgical approach				
Transnasal	17 patients (72 %)	12 patients (67 %)	5 patients (71 %)	
Open	8 patients (28 %)	6 patients (33 %)	2 patients (29 %)	<i>P</i> < 0.001
Surgical margins				
Sufficient	15 patients (60 %)	15 patients (83 %)		
Close	2 patients (8 %)	1 patient (6 %)	1 patients (14 %)	<i>P</i> = 0.007
Insufficient	8 patients (32 %)	2 patients (11 %)	6 patients (86 %)	
Postoperative radiotherapy	10 patients (40 %)	4 patients (22 %)	6 patients (86 %)	
Systemic therapy				
Chemotherapy	6 patients (24 %)	4 patients (22 %)	2 patients (29 %)	<i>P</i> = 1.00
Targeted therapy ^d	5 patients (20 %)	3 patients (17 %)	2 patients (29 %)	<i>P</i> = 0.60
Other ^e	1 patient (4 %)		1 patient (14 %)	

SNMM sinonasal malignant melanoma, *n/a* not available

^a KIT mutation status available in 12 patients (45 %)

^b BRAF and NRAS mutation status available in four patients (16 %)

^c Temozolomide, dacarbazine, cisplatin, eldisine, taurolidine, gemcitabine, oxaliplatin, capecitabine, paclitaxel

^d Ipilimumab, sorafenib, bevacizumab

^e Interferon alpha

Discussion

We report two major findings: (1) Multilocularity was shown in almost 30 % of our SNMM patients. (2) DFS of patients with mSNMM is significantly worse compared to patients with uSNMM. However, overall survival of these two distinct subgroups of patients does not differ.

Multilocular sinonasal malignant melanoma

SNMM is an aggressive disease showing failure of loco-regional tumor control in almost two-thirds and distant metastasis in more than half of patients during the follow-up period. Regarding loco-regional tumor control, our results lie within those published by other authors [11,

13, 15], whereas survival seems to be slightly better than reported by others [1–3, 9, 11, 15–18]. On the basis of clinical observations, this study proposes the existence of a multilocular type of SNMM (mSNMM), which has not been examined adequately up to present. In contrast to reports studying mucosal melanomas other than its sinonasal counterparts, we did not define recurrences outside the scar tissue as “multilocular”. Potentially, an inadequately treated uSNMM showing local recurrence would have been mistaken as mSNMM by using this definition. The prevalence of mSNMM in our patient cohort is 28 %, showing an inferior loco-regional tumor control and an inferior DFS compared to uSNMM. However, overall survival of SNMM did not differ among uni- or multilocularity. Similar findings were attributed to vulvovaginal mucosal melanomas

Table 2 Patients with sinonasal malignant melanoma

No	Age/sex	Histo	Origin	Distrib	Approach	Marg	Postop RT	LR (mts)	RR (mts)	DM (mts)	FU (mts)	Outcome
1	f/76	mel	Nasal cavity	uni	Transnasal	suff	No	44	No	No	83	DUTM
2	f/78	amel	Paranasal sinuses	uni	Transnasal	suff	No	18	No	No	23	DUTM
3	m/75	amel	Nasal cavity	uni	Transnasal	suff	No	7	No	No	24	DUTM
4	f/68	mel	Nasal cavity	uni	Transnasal	suff	No	No	No	22	31	DUTM
5	m/63	amel	Nasal cavity	uni	Transnasal	suff	No	No	No	55	65	DUTM
6	m/40	mel	Nasal cavity	multi	Transnasal	insuff	Yes	tp	24	38	47	DUTM
7	f/78	mel	Paranasal sinuses	uni	Open	close	Yes	81	No	No	88	DUTM
8	f/72	mel	Nasal cavity	uni	Transnasal	suff	No	No	No	No	124	DOD
9	f/71	mel	Nasal cavity	uni	Open	suff	No	41	No	61	72	AWD
10	m/50	mel	Nasal septum	uni	Transnasal	suff	No	63	No	95	132	DUTM
11	f/73	mel	Nasal cavity	uni	Transnasal	suff	No	8	No	8	12	DOD
12	f/66	amel	Nasal septum	uni	Transnasal	suff	No	23	No	No	70	AWOD
13	m/53	amel	Nasal cavity	multi	Transnasal	insuff	Yes	tp	5	11	17	DUTM
14	f/52	mel	Nasal septum	uni	Transnasal	suff	No	18	No	No	63	AWOD
15	m/68	mel	Paranasal sinuses	uni	Open	suff	Yes	No	No	4	13	DUTM
16	m/79	amel	Paranasal sinuses	multi	Open	insuff	Yes	No	No	17	17	LTFU
17	f/82	amel	Nasal cavity	multi	Transnasal	insuff	No	tp	No	10	10	LTFU
18	f/49	mel	Paranasal sinuses	uni	Open	insuff	Yes	No	No	8	14	DUTM
19	f/57	mel	Nasal cavity	uni	Open	insuff	Yes	No	No	No	59	AWOD
20	f/64	mel	Nasal cavity	multi	Transnasal	close	Yes	8	No	No	58	AWOD
21	f/77	mel	Nasal cavity	multi	Transnasal	insuff	Yes	No	No	10	15	AWOD
22	f/66	mel	Nasal cavity	multi	Open	insuff	Yes	No	No	No	21	AWOD
23	f/63	amel	Nasal cavity	uni	Transnasal	suff	No	7	No	38	41	DOD
24	f/43	mel	Nasal septum	uni	Transnasal	suff	No	No	No	No	1	AWOD
25	m/84	n/a	Nasal septum	uni	Open	suff	No	13	20	23	24	AWD

f female, m male, *histo* histology, *mel* melanotic, *amel* amelanotic, *n/a* not applicable, *distrib* distribution, *uni* unilocal, *multi* multilocal, *marg* surgical margins, *suff* sufficient, *insuff* insufficient, *postop RT* postoperative radiotherapy, *mts* months, *LR* local failure of therapy, *RR* regional failure of therapy, *DM* distant metastasis, *FU* follow-up, *DUTM* death unrelated to melanoma, *DOD* death of disease, *AWD* alive with disease, *AWOD* alive without disease, *LTFU* lost to follow-up

and also to SNMM in prior studies [7, 8]. In our opinion, the inferior loco-regional control rate and DFS are primarily due to the difficulty in obtaining sufficient resection and not due to a higher aggressivity of these tumors. On the other hand, the question why some small tumors show a multilocal distribution pattern and other, considerably larger, tumors remain unilocal is unanswered.

Postoperative radiotherapy

In the context of the aggressive behavior of SNMM, authors argue that the high incidence of loco-regional failures justifies the use of a postoperative radiotherapy and recommend this therapy, especially in extensive disease [10, 11]. However, the efficacy of radiotherapy in SNMM is discussed controversially. While some authors consider SNMM to be relatively radioresistant [15, 19] and did not find advantages in tumor control with postoperative radiotherapy [1, 2, 14], others detected better local tumor control rates without improving

survival [3, 10–13]. An improved loco-regional tumor control would be suitable, especially in cases of mSNMM, in which it is difficult to obtain sufficient surgical margins. Statistical analysis, however, did not reveal any difference among patients treated with or without postoperative radiotherapy. Nevertheless, baseline characteristics of patients with and without radiotherapy were considerably different. While patients with radiotherapy were predominantly suffering from mSNMM and showed insufficient or close margins, those without had safe margins and uSNMM biasing the whole analysis. To overcome this hurdle, a large prospective randomized trial would be needed. Recently, neutron therapy has demonstrated improved outcomes in a number of radioresistant histologies [19]; among others, this therapy was effective in the treatment of head and neck malignant melanomas [19]. At present, the lack of an adjuvant therapy with proven efficacy demands consequent follow-up examinations including PET/CT imaging, which has been showed to be the imaging of choice during follow-up [20].

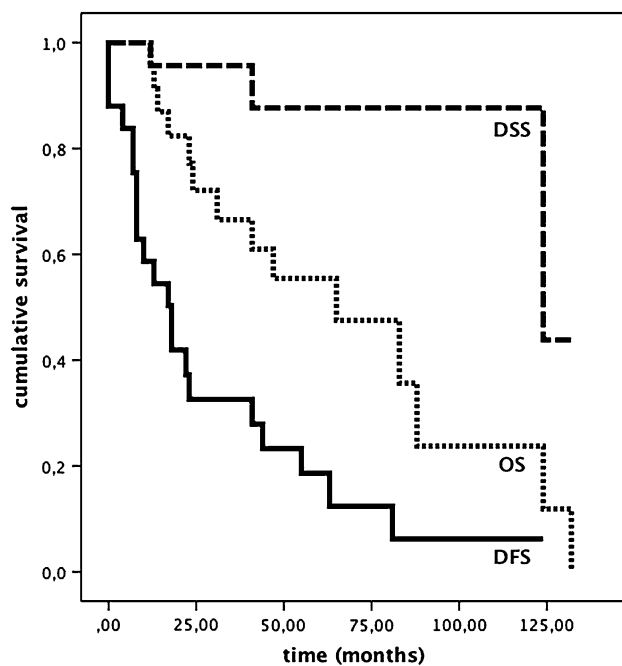


Fig. 1 Disease-free survival (DFS), Disease-specific survival (DSS) and overall survival (OS) of patients with sinonasal malignant melanoma

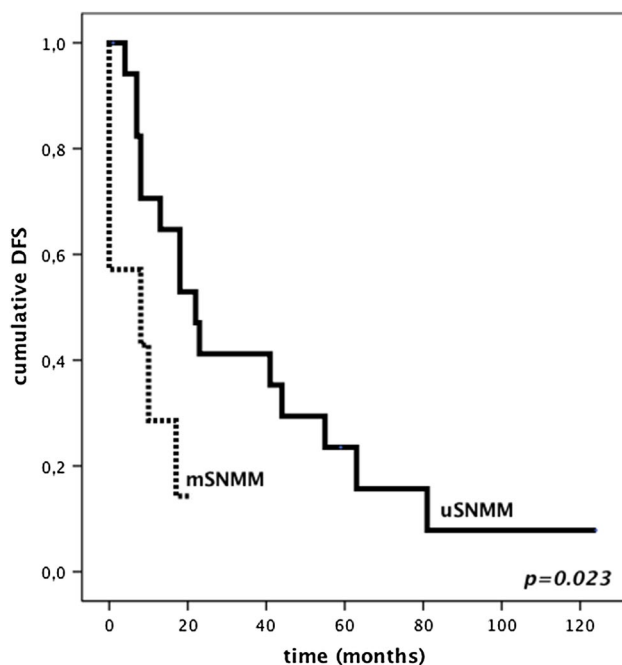


Fig. 2 DFS of patients with unilocular (uSNMM) and multilocular sinonasal melanoma (mSNMM)

Systemic therapy

Mutations of the KIT gene are reported to be present in up to 20 % of the cases with mucosal malignant melanoma; aberrations of the BRAF gene usually are absent in these

patients [21–23]. Therefore, BRAF inhibitors, for which encouraging tumor regressions of cutaneous malignant melanoma have been observed [24], do not represent a treatment option for patients with SNMM. In contrast to the prevalence of mucosal melanomas with KIT mutations reported in the literature, none of our patients undergoing mutational analysis showed aberrations of the KIT gene. While some authors conclude that there is lack of efficacy to treat these patients with KIT inhibitors [25, 26], others hypothesize that patients with a non-mutated, but amplified KIT gene might also benefit of targeted therapies [27]. In our five patients (20 %) treated with ipilimumab or sorafenib, the use of a targeted therapy was carefully evaluated in a multidisciplinary team in each case.

Treatment with interferon alpha may improve survival of patients with high-risk melanomas if used as an adjuvant (postoperative) treatment [28]. It was given together with dacarbazine and taurolidine in one single patient (4 %) with local tumor persistence after resection and development of regional failure and distant metastasis shortly thereafter.

The use of a “conventional” chemotherapy for patients with high-risk malignant melanomas of the head and neck area is discussed controversially [29]. Despite the limited and heterogenic data for the use of chemotherapy in SNMM, it might be of overall survival benefit in a (neo) adjuvant setting of patients with distant metastatic disease [30]. Six (24 %) of our patients received chemotherapy for that purpose. The size of our patient collective, however, is far too small to evaluate the results of all the systemic therapies.

Other factors

Our limited data did not attribute a prognostic role to the tumor localization. Other authors also did not find a relationship between localization and outcome [2]; there are further studies presenting worse results in SNMM originating from the maxillary sinus, the ethmoid or the sphenoid sinus and a better prognosis in septal and/or anterior inferior nasal cavity involvement [5, 15, 31]. These findings could be explained by an earlier diagnosis of SNMM in the anterior part of the nasal cavity, including the anterior nasal septum. Furthermore, there are localizations (for example the frontal skull base), in which it is more difficult to obtain adequate surgical margins. Consequently, we suspect the loco-regional tumor control to be different depending on tumor localization.

Limitations of the study

Our study has several limitations. First of all, this is a retrospective study on a relatively small number of

patients. Consequently, results of the statistical analysis have to be carefully interpreted in the light of the small cohort. Secondly, the presence of mSNMM is arbitrarily defined on a clinical basis. Despite a careful definition of multilocularity, a multilocular primary cannot be differentiated completely from satellite metastasis or skip lesions, which are—of course—related to a worse outcome. Nevertheless, we think that the presence of a potential multilocular subtype of SNMM and the lack of adjuvant therapy with proven efficacy to treat microscopic residual disease should influence the planning of future treatment concepts of SNMM and further clinical studies.

Conclusions

In almost 30 % of the cases, SNMM show a multilocular distribution pattern. mSNMM is associated with an unfavorable DFS compared to its unilocular counterpart.

Conflict of interest None.

References

- Lund VJ, Howard DJ, Harding L, Wei WI (1999) Management options and survival in malignant melanoma of the sinonasal mucosa. *Laryngoscope* 109:208–211
- Lund VJ, Chisholm EJ, Howard DJ, Wei WI (2012) Sinonasal malignant melanoma: an analysis of 115 cases assessing outcomes of surgery, postoperative radiotherapy and endoscopic resection. *Rhinology* 50:203–210
- Bachar G, Loh KS, O'Sullivan B, Goldstein D, Wood S, Brown D et al (2008) Mucosal melanomas of the head and neck: experience of the Princess Margaret Hospital. *Head Neck* 30:1325–1331
- Keller DS, Thomay AA, Gaughan J, Olszanski A, Wu H, Berger AC et al (2013) Outcomes in patients with mucosal melanomas. *J Surg Oncol*. doi:10.1002/jso.23445
- Roth TN, Gengler C, Huber GF, Holzmann D (2010) Outcome of sinonasal melanoma: clinical experience and review of the literature. *Head Neck* 32:1385–1392
- Mendenhall WM, Amdur RJ, Hinerman RW, Werning JW, Villaret DB, Mendenhall NP (2005) Head and neck mucosal melanoma. *Am J Clin Oncol* 28:626–630
- Kingston NJ, Jones RW, Baranyai J (2004) Recurrent primary vulvovaginal malignant melanoma arising in melanoma in situ—the natural history of lesions followed for 23 years. *Int J Gynecol Cancer* 14:628–632
- Lotem M, Anteby S, Peretz T, Ingber A, Avinoach I, Prus D (2003) Mucosal melanoma of the female genital tract is a multifocal disorder. *Gynecol Oncol* 88:45–50
- Moreno MA, Roberts DB, Kupferman ME, DeMonte F, El-Naggar AK, Williams M et al (2010) Mucosal melanoma of the nose and paranasal sinuses, a contemporary experience from the M. D. Anderson Cancer Center. *Cancer* 116:2215–2223
- Krengli M, Jereczek-Fossa BA, Kaanders JH, Masini L, Beldi D, Orecchia R (2008) What is the role of radiotherapy in the treatment of mucosal melanoma of the head and neck? *Crit Rev Oncol Hematol* 65:121–128
- Owens JM, Roberts DB, Myers JN (2003) The role of postoperative adjuvant radiation therapy in the treatment of mucosal melanomas of the head and neck region. *Arch Otolaryngol Head Neck Surg* 129:864–868
- Bridger AG, Smee D, Baldwin MA, Kwok B, Bridger GP (2005) Experience with mucosal melanoma of the nose and paranasal sinuses. *ANZ J Surg* 75:192–197
- Temam S, Mamelle G, Marandas P, Wibault P, Avril MF, Janot F et al (2005) Postoperative radiotherapy for primary mucosal melanoma of the head and neck. *Cancer* 103:313–319
- Patel SG, Prasad ML, Escrig M, Singh B, Shaha AR, Kraus DH et al (2002) Primary mucosal malignant melanoma of the head and neck. *Head Neck* 24:247–257
- Dauer EH, Lewis JE, Rohlinger AL, Weaver AL, Olsen KD (2008) Sinonasal melanoma: a clinicopathologic review of 61 cases. *Otolaryngol Head Neck Surg* 138:347–352
- Prasad ML, Busam KJ, Patel SG, Hoshaw-Woodard S, Shah JP, Huvo AG (2003) Clinicopathologic differences in malignant melanoma arising in oral squamous and sinonasal respiratory mucosa of the upper aerodigestive tract. *Arch Pathol Lab Med* 127:997–1002
- Koivunen P, Bäck L, Pukkila M, Laranne J, Kinnunen I, Grénman R et al (2012) Accuracy of the current TNM classification in predicting survival in patients with sinonasal mucosal melanoma. *Laryngoscope* 122:1734–1738
- Thompson LD, Wieneke JA, Miettinen M (2003) Sinonasal tract and nasopharyngeal melanomas: a clinicopathologic study of 115 cases with a proposed staging system. *Am J Surg Pathol* 27:594–611
- Liao JJ, Parvathaneni U, Laramore GE, Thompson JA, Bhatia S, Futran ND et al (2013) Fast neutron radiotherapy for primary mucosal melanomas of the head and neck. *Head Neck*. doi:10.1002/hed.23428
- Haerle SK, Soyka MB, Fischer DR, Murer K, Strobel K, Huber GF et al (2012) The value of 18F-FDG-PET/CT imaging for sinonasal malignant melanoma. *Eur Arch Otorhinolaryngol* 269:127–133
- Cohen Y, Rosenbaum E, Begum S, Goldenberg D, Esche C, Lavie O et al (2004) Exon 15 BRAF mutations are uncommon in melanomas arising in nonsun-exposed sites. *Clin Cancer Res* 10:3444–3447
- Curtin JA, Busam K, Pinkel D, Bastian BC (2006) Somatic activation of KIT in distinct subtypes of melanoma. *J Clin Oncol* 24:4340–4346
- Went PT, Dirnhöfer S, Bundi M, Mirlacher M, Schraml P, Mangialaio S et al (2004) Prevalence of KIT expression in human tumors. *J Clin Oncol* 22:4514–4522
- Hersey P, Bastholt L, Chiarion-Sileni V, Cinat G, Dummer R, Eggermont AM et al (2009) Small molecules and targeted therapies in distant metastatic disease. *Ann Oncol* 20(Suppl 6):vi35–vi40
- Ugurel S, Hildenbrand R, Zimpfer A, La Rosée P, Paschka P, Sucker A et al (2005) Lack of clinical efficacy of imatinib in metastatic melanoma. *Br J Cancer* 92:1398–1405
- Wyman K, Atkins MB, Prieto V, Eton O, McDermott DF, Hubbard F et al (2006) Multicenter phase II trial of high-dose imatinib mesylate in metastatic melanoma: significant toxicity with no clinical efficacy. *Cancer* 106:2005–2011
- Satzger I, Küttler U, Völker B, Schenck F, Kapp A, Gutzmer R (2010) Anal mucosal melanoma with KIT-activating mutation and response to imatinib therapy—case report and review of the literature. *Dermatology* 220:77–81
- Mocellin S, Lens MB, Pasquali S, Pilati P, Chiarion Sileni V (2013) Interferon alpha for the adjuvant treatment of cutaneous melanoma. *Cochrane Database Syst Rev*. doi:10.1002/14651858.CD008955.pub2

29. Papaspyrou G, Garbe C, Schadendorf D, Werner JA, Hauschild A, Egberts F (2011) Mucosal melanomas of the head and neck: new aspects of the clinical outcome, molecular pathology, and treatment with c-kit inhibitors. *Melanoma Res* 21:475–482
30. Gore MR, Zanation AM (2012) Survival in sinonasal melanoma: a meta-analysis. *J Neurol Surg B Skull Base* 73:157–162
31. McLean N, Tighiouart M, Muller S (2008) Primary mucosal melanoma of the head and neck. Comparison of clinical presentation and histopathologic features of oral and sinonasal melanoma. *Oral Oncol* 44:1039–1046