

Cite this article as: Carrel TP, Weber A. Selective, segmental decalcification: a safe alternative to extensive debridement of a severely calcified annulus during repair of mitral regurgitation. *Interact CardioVasc Thorac Surg* 2016;23:665–7.

# Selective, segmental decalcification: a safe alternative to extensive debridement of a severely calcified annulus during repair of mitral regurgitation

Thierry P. Carrel and Alberto Weber\*

Department of Cardiovascular Surgery, Inselspital, University Hospital and University of Bern, Bern, Switzerland

\* Corresponding author. Tel: +41-442553679; fax: +41-442554446; e-mail: alberto.weber@usz.ch (A. Weber).

Received 28 October 2015; received in revised form 21 March 2016; accepted 9 April 2016

## Abstract

Resection of the calcium bar and creation of a more compressible annulus with pericardium are necessary in case of extensive calcification of the mitral valve annulus in patients with advanced myxomatous degenerative disease. Such annular bar calcification is technically challenging and represents a risk factor for death following mitral valve operations, because of atrio-ventricular rupture or encroachment of the coronary arteries. We describe a safe limited segmental annular debridement away from the coronary arteries that allows enough flexibility of the remaining calcified annulus to perform reduction annuloplasty in a young female patient with severe mitral regurgitation and a highly dilated and severely calcified mitral annulus.

**Keywords:** Mitral valve repair • Calcified annulus

## CASE REPORT

A 44-year old woman with severe mitral regurgitation was referred because of rapid increasing shortness of breath and impaired physical capacity (New York Heart Association class II–III).

The preoperative chest radiograph revealed a dilated and severely calcified mitral annulus. On preoperative echocardiogram, severe mitral regurgitation was confirmed with a Carpentier's Type I lack of leaflet coaptation due to an annular diameter larger than 60 mm, without segmental prolapse and without stenosis. The left ventricular ejection fraction was 70%, and the end-diastolic diameter of the left ventricle (LV) was 72 mm. Coronary angiography showed normal coronaries, left dominant and highlighted the proximity of the circumflex artery along the bar calcification of the mitral annulus, which extended from one trigon to the other (Fig. 1A).

Because of increasing symptoms and LV dilatation, indication for mitral valve repair or replacement was confirmed. Surgery was performed through median sternotomy, and cardiopulmonary bypass was instituted using aortic and bicaval cannulation. The mitral valve was approached through a left atriotomy. The heaviest calcifications were located on the annulus bar between trigons, but the leaflets and the subvalvular apparatus were free of calcifications.

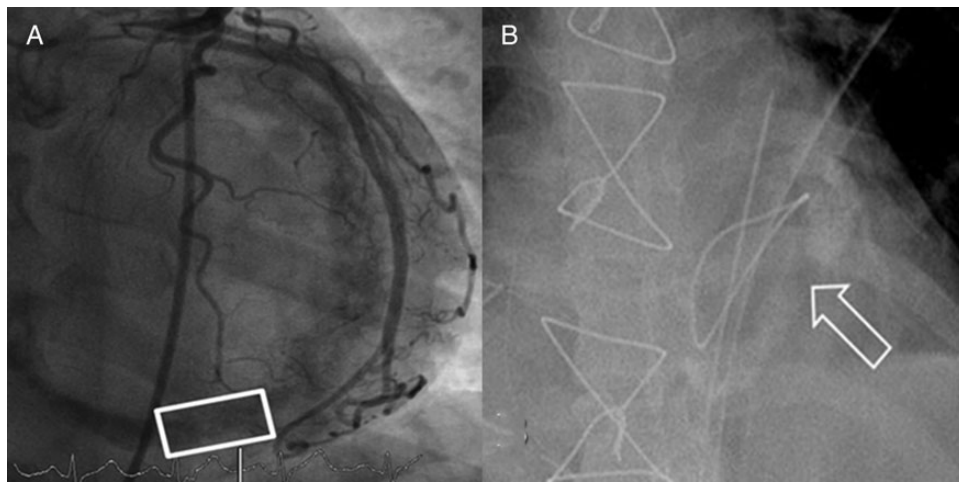
To avoid replacement, edge-to-edge repair was first attempted, but approximation of the anterior and posterior leaflets was impossible due to the extreme antero-septal dimension of the dilated valve. Replacement was considered, but placement of the sutures around the calcifications would have had a significant risk

of circumflex coronary artery injury. In addition, also the largest mechanical prosthesis (33 mm) would not have matched with the size of the mitral annulus. The proximity of the circumflex artery and partially also the right coronary artery made an extensive debridement of the annulus not appealing.

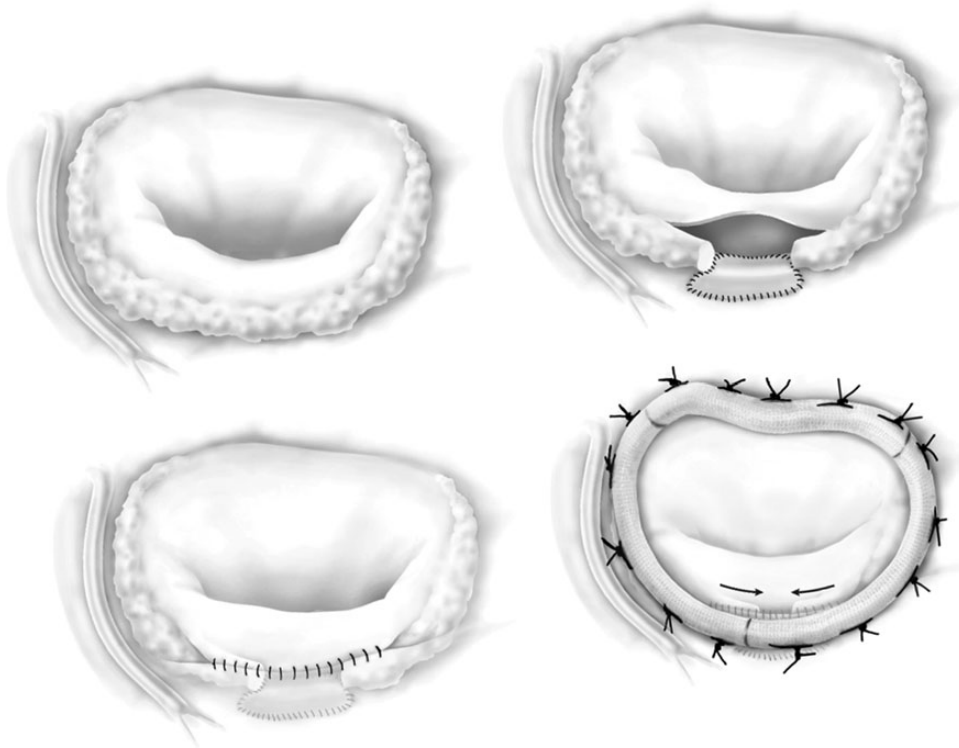
Finally, guided by the preoperative coronary angiography, an annular portion between P2 and P3 was defined where no coronary artery underlies the annulus (Fig. 1A). Detachment of the posterior leaflet from the annulus was performed and the selected calcified bar segment was completely resected up to the atrioventricular groove to a length extension of ~2 cm. This portion of the calcium bar was removed *en bloc*; however, in order to separate it from the main annulus, very limited and controlled fragmentation was needed; by this, clean calcium bar borders remained on site. The defect was repaired with a xenopericardial patch sutured to the ventricle, the groove and to the atrial side. The posterior leaflet was sutured back to the annulus/atrial wall (Fig. 2).

No sealant was used. This limited manoeuvre rendered the annulus more flexible and made a downsized ring annuloplasty with a 40-mm saddle-shaped mitral ring possible, by reducing significantly the initial annular diameter (Figs 1B and 2). Sutures for the annuloplasty were partially stitched through the bar or to the atrial wall. A water test revealed no residual regurgitation and the surface of coaptation was larger than 1 cm. After closure of the left atrium, cardiopulmonary bypass was discontinued without difficulty, and sinus rhythm returned spontaneously.

Intraoperative transoesophageal echocardiography confirmed a surface of coaptation of 1.3 cm with no residual regurgitation



**Figure 1:** (A) Mitral annulus segment without proximity to the circumflex coronary artery or the right coronary artery (within the white frame). (B) Chest radiography at discharge. Arrow points at the created gap in the calcium bar, which was shrunk by the annuloplasty.



**Figure 2:** Cartoon of the surgical technique.

and normal left ventricular function. The postoperative course was uneventful, oral anticoagulation was initiated for 3 months and the patient was discharged in satisfactory condition. At the 6-month follow-up, her clinical condition and echocardiographic examination remained stable.

## DISCUSSION

Patients with extensive annular calcification who require mitral valve surgery may present significant challenges to the surgeon. Removal of the calcium bar with subsequent annular reconstruction has been recommended [1, 2]. However, this remains a major

surgical challenge and is related to a higher operative mortality rate of up to 9.7% [3]. In degenerative mitral valve disease with extensive calcification of the mitral annulus only, with the absence of rheumatic disease and/or significant calcification of leaflets or subvalvular structures, valve repair should be preferred over replacement, especially in young patients [2]. Durable repair has been demonstrated after calcium debridement [4].

The patient presented in this short report had two distinct problems: (i) the calcification of the annulus and (ii) the huge diameter of the mitral annulus (~6 cm). In addition, coronary angiography demonstrated a dangerous proximity of the circumflex artery to the calcified mitral annulus. To limit the risk of the procedure, we used a technique that differs slightly from that

described by others: we decided to limit the decalcification to an annular segment where no coronary artery could be damaged. The extent of the debridement was thereby limited to the purpose of disrupting annular rigidity and allowing enough flexibility to perform a downsized annuloplasty and achieve better leaflet coaptation. Of course, the risk of atrioventricular disruption still exists at the site of decalcification, but the patch reconstruction is greatly facilitated when the gap is limited. An edge-to-edge repair was considered, but the antero-septal dimensions of the valve made this not suitable. In addition, suboptimal results of this technique without annuloplasty or in cases with a calcified annulus have been reported [5].

Although the clinical result with an intact valve repair was still excellent after 6 months, we remain concerned about late ring dehiscence, despite the fact that the great surface of coaptation achieved probably relieves the annulus from tension. Also, potential progression of the remaining calcification that may later extend to the leaflets or chordae remains an issue but, again, if tension of the annulus is reduced, progression of the disease may be delayed.

The technique of selective, limited, segmental debridement of the mitral annulus to provide enough flexibility for annuloplasty

was relatively easy to perform and is easily reproducible in the presence of a heavily calcified mitral annulus combined with huge annular dilatation. This technique most probably limits the risk of damage to the coronary arteries.

**Conflict of interest:** none declared.

## REFERENCES

- [1] Carpentier AF, Pellerin M, Fuzellier JF, Relland JY. Extensive calcification of the mitral valve annulus: pathology and surgical management. *J Thorac Cardiovasc Surg* 1996;111:718–29.
- [2] Feindel CM, Tufail Z, David TE, Ivanov J, Armstrong S. Mitral valve surgery in patients with extensive calcification of the mitral annulus. *J Thorac Cardiovasc Surg* 2003;126:777–82.
- [3] Cammack PL, Edie RN, Edmunds LH Jr. Bar calcification of the mitral annulus. A risk factor in mitral valve operations. *J Thorac Cardiovasc Surg* 1987;94:399–404.
- [4] Grossi EA, Galloway AC, Steinberg BM, LeBoutillier M III, Delianides J, Baumann FG *et al*. Severe calcification does not affect long-term outcome of mitral valve repair. *Ann Thorac Surg* 1994;58:685–7; discussion 688.
- [5] Maisano F, Caldarola A, Blasio A, De Bonis M, La Canna G, Alfieri O. Midterm results of edge-to-edge mitral valve repair without annuloplasty. *J Thorac Cardiovasc Surg* 2003;126:1987–97.

## Discover a wealth of knowledge

### Oxford Journals Archive

- uncover backfiles of content dating from 1849
- instant access to 146 years of research
- seamless access from Volume 1, Issue 1
- access by IP range, Athens or Shibboleth
- COUNTER-compliant usage statistics