

Strahlenther Onkol 2014 · 190:386–393  
 DOI 10.1007/s00066-013-0508-x  
 Received: 20 August 2013  
 Accepted: 8 November 2013  
 Published online: 7 February 2014  
 © Springer-Verlag Berlin Heidelberg 2014

S. Janssen<sup>1</sup> · C. Glanzmann<sup>1</sup> · G. Huber<sup>2</sup> · G. Studer<sup>1</sup>

<sup>1</sup> Department of Radiation Oncology, University Hospital Zurich

<sup>2</sup> Department of Otorhinolaryngology, Head and Neck Surgery, University Hospital Zurich

## Individualized IMRT treatment approach for cervical lymph node metastases of unknown primary

In approximately 3–5% of patients presenting with squamous cell cancer (SCC) metastases in cervical lymph nodes, the primary is not found despite extensive clinical evaluation [1, 2]. Treatment of those patients remains controversial lacking evidence from prospective randomized trials. Recommendations include neck dissection and/or radio(chemo)therapy. For more advanced stages, multimodal treatment is recommended. Induction chemotherapy before radio(chemo)therapy followed by surgery depending on response may be an additional option [2, 3, 4]; however, its value is not proven. The main controversial aspect is the radiotherapy (RT) treatment volume. Planning treatment volumes (PTVs) often include the affected lymph node region as well as contralateral cervical lymph nodes and the mucosal sites of the pharynx in order to cover a putative primary (comprehensive RT) [5].

Several retrospective single institution studies compared comprehensive conventional radiation to involved field radiation. While some groups demonstrated better local outcome using extended fields [5, 6, 7], others did not show an advantage for more extensive RT [4, 8, 9, 10]. Furthermore, omitting hypopharyngeal and laryngeal mucosa seems to be feasible as well [1, 11].

Introduction of intensity-modulated radiotherapy (IMRT) in patients with head and neck cancer showed an improved therapeutic ratio compared to historic conventional three-dimensional techniques [12]. Recently, in the era of IMRT, several study groups used IMRT in patients with cervical lymph node metas-

tases of unknown primary cancer (UPC) and confirmed those good results [13, 14, 15, 16, 17, 18, 19].

The purpose of this article is to evaluate the outcome of risk-adapted PTVs in patients with cervical lymph node metastases of UPC treated with IMRT.

### Material and methods

#### Patients

From January 2006 to November 2012, 28 consecutive patients presenting with cervical lymph node metastases of UPC were treated in our department with IMRT either postoperatively (n=20) or as definitive treatment (n=8). Diagnosis was proven histologically in all patients showing metastases of SCC. PET-CT was performed routinely before treatment start and was considered for delineation. Patient- and treatment-related parameters are summarized in **Tab. 1**. Mean/median follow-up time was 31.6/30.5 months (range 3–78 months). Details regarding surgical neck dissection prior to radiation (n=20) or as postirradiation elective neck dissection (END) are listed in **Tab. 2**.

Regular follow-up visits were carried out in our joint clinic at the Department of Otorhinolaryngology, Head and Neck Surgery. Institutional standards for patient assessment included physical examination and flexible fiber optic endoscopy approximately every 2 months in the first year of follow-up, every 3 months in the second to third year and every 6 months in the fourth to fifth years.

### Treatment

#### IMRT

Unilateral irradiation was preferred. Based on individual risk factors including clinical, surgical, histopathological, and imaging information, we enlarged treatment fields to the putative mucosal site or the contralateral neck. One crucial risk factor was suspicious enhancement of contralateral lymph nodes or oropharyngeal structures in PET-CT (n=4). In those cases, a biopsy of the questionable region was carried out revealing no malignancy. Nevertheless a certain risk of involvement was supposed in that case—which was the reason to extend PTVs. Other risk factors suggestive for bilateral nodal irradiation were status after pT1 floor of the mouth carcinoma in the past (n=1), recurrent lymph node metastases (n=1), and level I involvement (n=2). “Classical” extensive bilateral treatment was reserved for N2c and bilateral N3 patients (n=5; postoperative: n=1; definitive: n=4). One patient with extensive N3 disease (I16 ccm) was only treated unilaterally due to advanced age and poor general condition. Doses and PTVs based on the affected cervical node levels are shown in **Tab. 3**.

**Fig. 1, 2, and Fig. 3** demonstrate uni- and bilateral RT volumes. We used simultaneously integrated boost (SIB) technique in all patients [20, 21]. SIB-IMRT was performed using the schedules below.

In definitive IMRT patients (n=8):

- SIB2.00: 35 fractions with daily SIB doses of 2.00 Gy (PTV1)/1.70 Gy (PTV2) and 1.54 Gy (PTV3) to a total boost dose of 70.00 Gy (five fractions a week).

Tab. 1 Patient- and treatment-related parameters	
Mean age (years)	66 (range 45–86)
Gender	
– Male	22 (79%)
– Female	6 (21%)
RT sequence	
– Postoperative IMRT	20 (71%)
– Definitive IMRT	8 (29%)
RT volume	
– Bilateral IMRT	13 (46%)
– Unilateral IMRT	15 (54%)
RT doses	
– 33×2=66 Gy	16 (57%)
– 32×2=64 Gy	1 (4%)
– 35×2=70 Gy	2 (7%)
– 30×2.2=66 Gy	1 (4%)
– 33×2.11=69.63 Gy	7 (24%)
– 32×2.11=67.52 Gy	1 (4%)
N status	
– N1	2 (7%)
– N2a	8 (28%)
– N2b	12 (43%)
– N2c	3 (11%)
– N3	3 (11%)
Lymph node involvement	
– Level I	2
– Level II	18
– Level III	9
– Level IV	5
– Level V	1
– Bilateral	4
ECE	11 (39%)
R1/2	6/20 (21%)
Cisplatin or cetuximab concomitant	20 (71%)
Preoperative chemotherapy	2 (7%)

*ECE* extra capsular extension, *RT* radiotherapy, *IMRT* intensity-modulated radiotherapy.

Tab. 2 Extent of neck dissection and number of positive lymph nodes for all 20 patient receiving surgery prior to radiation. In 4 of 8 patients with definitive irradiation, an elective neck dissection (END) was performed		
	Extent of neck dissection (level)	Positive lymph nodes
1	II–IV left	4/31
2	II–IV left	1/12
3	II–IV left	9/24
4	I–IV right	2/6
5	II–III left	2/18
6	I–V right	18/30
7	I–IV right	3/14
8	II–IV right	1/25
9	II–IV right	1/27
10	II–V right	1/14
11	II–V left	3/14
12	I–V right	1/39
13	I–IV right	1/21
14	I	1/1
15	I–II left	2/4
16	I–IV left	0/29 (after lymph node excision)
17	I–IV right	0/12 (after lymph node excision)
18	II–IV left	1/9
19	I–IV both sides	8/51 right, 4/37 left
20	II–V left	1/13
END 1	II–III right	0/17
END 2	performed externally (no information)	
END 3	II–IV right and II–III left	0/15 right, 0/6 left
END 4	II–V right	0/2

the prescribed dose encompassed at least 95% of the PTV. Additionally, no more than 2% of any PTV received >110% of its prescribed dose, whereas no more than 1% of any PTV received <93% of the prescribed dose.

Target volumes were delineated as follows: the involved lymph nodes included the gross extent of primary disease, taking clinical and radiological findings into account; clinical target volume (CTV) was defined by adding 10–15 mm margin to the gross tumor volume (GTV), another 2–3 mm margin was added from CTV to PTV 1 dependent on proximity to critical structures (e.g., spinal cord or brachial plexus); PTV2 covered areas considered at high risk for potential microscopic disease; and PTV3 included the clinically negative mucosa or lymphatic pathways (elective PTV coverage).

In patients with substantial parts of the pharynx and/or larynx involved in the PTV, 2.0 Gy per session was given. To ensure sufficient dose delivery to the skin close to GTVs, bolus material (0.5–1 cm thickness) was used in patients with skin involvement and/or <5 mm between GTV and the overlying skin.

Irradiation was delivered with five or seven coplanar beam angles by a 6-MV dynamic MLC system (Varian Medical Systems, Palo Alto, CA, USA) using the sliding window technique, or using the volumetric modulated rapid arc technique (VMAT; since April 2010). Patients were immobilized from head to shoulders using a commercially available thermoplastic mask in supine position.

## Systemic therapy

Systemic therapy preferably consisted of cisplatin (40 mg/m<sup>2</sup> weekly) and was switched to cetuximab in case of cisplatin-related adverse effects (cetuximab loading dose: 400 mg/m<sup>2</sup> followed by weekly applications of 250 mg/m<sup>2</sup> [22]). For patients with contraindications against cisplatin, cetuximab was favored primarily. The indication for systemic therapy was made based on extent of nodal involvement, resection status, extra-nodal extension, age, and Karnofsky performance score. In 2 patients with extended disease (cN3 and cN2c), three cycles of neoadjuvant chemotherapy with TPF (docetaxel

- SIB2.11: 33 fractions with daily SIB doses of 2.11 (PTV1)/1.80 Gy (PTV 2) and 1.64 Gy (PTV3) to a total boost dose of 69.60 Gy (five fractions a week).

In postoperative patients (n=20):

- SIB2.00: 32–33 fractions with daily SIB doses of 2.00 Gy (PTV 1)/1.80 Gy (PTV2)/1.64 Gy (PTV3) to a total boost dose of 64–66.00 Gy (five fractions a week).
- SIB2.11: 33 fractions of daily SIB doses of 2.11 (PTV1)/1.80 Gy (PTV 2)

and 1.64 Gy (PTV3) to a total boost dose of 69.60 Gy (five fractions a week).

- SIB2.2: 30 fractions with daily SIB doses of 2.2 Gy (PTV1)/2.0 Gy (PTV2) and 1.64 Gy (PTV3) to a total dose of 66.00 Gy (five fractions a week) (carried out in 1 patient)

In 1 patient two IMRT series were carried out instead of SIB (50 Gy, 16 Gy boost, single dose: 2.0 Gy, 6 fractions/week).

The dose was normalized to the mean dose in PTV1. For intensity optimization,

S. Janssen · C. Glanzmann · G. Huber · G. Studer

**Individualized IMRT treatment approach for cervical lymph node metastases of unknown primary****Abstract**

**Purpose.** The goal of the present study was to evaluate the outcome of risk-adapted planning treatment volumes (PTVs) in patients with cervical lymph node metastases of unknown primary cancer (UPC) treated with intensity-modulated radiotherapy (IMRT).

**Patients and material.** Between January 2006 and November 2012, 28 patients with cervical lymph node metastases of UPC were treated in our institution with IMRT either postoperatively (n=20) or as definitive treatment (n=8). Nodal involvement distributed as follows: N1 (n=2), N2a (8), N2b (10), N2c (4), and N3 (4). Systemic therapy with cisplatin or cetuximab was added concomitantly in 20 of 28 patients (71%). Radiotherapy

using simultaneously integrated boost (SIB-IMRT) was carried out with 2.0 or 2.11 Gy single doses up to 66/70 Gy.

**Results.** Mean/median follow-up was 31.6/30.5 months (range 3–78 months). In all, 15 of 28 patients were treated with unilateral SIB-IMRT (54%). An elective PTV to the contralateral oropharynx and contralateral level II–III lymph nodes was carried out in 8 patients with PET-CT suspected but not histologically proven involvement, recurrences or former tumor of the oropharynx. More extended treatment fields were reserved for patients with N2c or bilaterally N3 status (n=5). The 3-year overall survival, mucosal control, neck control and distant metastasis-free survival rates were 76, 100, 93, and 88%, respec-

tively. No patient suffered from a locoregional recurrence. Two patients treated with radiotherapy alone had persistent nodal disease. No grade II or higher late sequel has been observed.

**Conclusion.** Our single center approach to treat patients with cervical lymph node metastases of UPC with individualized, risk-adapted SIB-IMRT resulted in high locoregional tumor control and was well tolerated.

**Keywords**

Radiotherapy, intensity-modulated · Treatment outcome · Neoplasm metastasis, unknown primary · Cisplatin · Cetuximab

**Individualisierter IMRT-Bestrahlungsansatz bei zervikalen Lymphknotenmetastasen mit unbekanntem Primärtumor****Zusammenfassung**

**Ziel.** Evaluation von intensitätsmodulierter Radiotherapie (IMRT) mit risikoadaptierten Planungszielvolumina („planning treatment volumes“, PTVs) bei Patienten mit zervikalen Lymphknotenmetastasen bei unbekanntem Primarius („unknown primary cancer“, UPC).

**Patienten und Methoden.** Zwischen Januar 2006 und November 2012 wurden 28 Patienten mit zervikalen Lymphknotenmetastasen eines UPC in unserer Abteilung mit IMRT entweder postoperativ (n=20) oder definitiv (n=8) behandelt. Das Ausmaß des Lymphknotenbefalls stellte sich folgendermaßen dar: N1 (n=2), N2a (n=8), N2b (n=10), N2c (n=4) und N3 (n=4). Bei 20/28 Patienten (71%) wurde eine simultane Systemtherapie mit Cisplatin oder Cetuximab appliziert. Die Bestrahlung mit integriertem Boost (SIB-IMRT) erfolgte in Einzeldosen von 2,0 oder

2,11 Gy bis zu einer Gesamtdosis von 66 bis 70 Gy.

**Ergebnisse.** Die durchschnittliche/mediane Nachbeobachtungszeit betrug 31,6/30,5 Monate (Spanne 3–78 Monate). Von 28 Patienten wurden 15 mit einer unilateralen SIB-IMRT behandelt (54%). Bei 8 Patienten mit histologisch nicht bestätigten, suspekten Befunden im PET-CT, Rezidiven oder Zustand nach Oropharynxtumoren wurde eine elektive Bestrahlung des kontralateralen Oropharynx und der kontralateralen Level-II- bis Level-III-Lymphknoten durchgeführt. Darüberhinausgehende Erweiterungen des PTV wurden bei Patienten mit N2c- oder bilateralem N3-Status durchgeführt (n=5). Das Gesamtüberleben, die Mukosakontrolle, die lokale Tumorkontrolle und das fernmetastasenfreie Überleben nach 3 Jahren

betragen 76, 100, 93 und 88%. Kein Patient erlitt ein lokoregionäres Rezidiv. Bei 2 Patienten persistierte der Lymphknotenbefund nach definitiver Radiotherapie. Grad II oder höhergradige Spätnebenwirkungen wurden nicht beobachtet.

**Schlussfolgerung.** Die Behandlung von Patienten mit zervikalen Lymphknotenmetastasen eines UPC mit einer individualisierten, risikoadaptierten SIB-IMRT führt zu einer hohen lokoregionären Tumorkontrolle und ist gut tolerabel.

**Schlüsselwörter**

Intensitätsmodulierte Strahlentherapie · Behandlungsergebnis · Neoplasmetastasierung, unbekannter Primarius · Cisplatin · Cetuximab

75 mg/m<sup>2</sup> day 1, cisplatin 75 mg/m<sup>2</sup> day 1, and 5-fluorouracil 750 mg/m<sup>2</sup> days 1–5) were administered.

**Surgery**

The extent of neck dissection and the number of positive lymph nodes in operated patients is shown in **Tab. 2**.

**Statistics**

Statistical calculation was performed using the statistic program implemented in StatView (Version 4.5; SAS Institute, Cary, NC, USA).

**Results****Outcome**

Mean/median follow-up was 31.6/30.5 months (range 3–78 months). The 3-year overall survival rate was 76%. The 3-year mucosal control rate, nodal control rate, and distant metastasis-free survival were 100, 93, and 88%, respectively (**Fig. 4**). Two patients with a nodal mass of 63 and 116 ccm, respec-

**Tab. 3** Simplified description of doses and planning treatment volumes applied, based on lymph node involvement in patients with cervical lymph node metastases of unknown primary cancer treated in our institution with SIB-IMRT

Affected lymph node levels <sup>a</sup>	70/66 Gy	60 Gy	54 Gy
Level I (n=2)	Bilateral level I	Bilateral I, III Bilateral OP	Ipsilateral SCR Ipsilateral level IV, V Ipsilateral RPN
Level II (n=18)	Ipsilateral level II–III	Ipsilateral OP	Ipsilateral SCR Ipsilateral level IV, V Ipsilateral level IB Ipsilateral RPN
Level III (n=9)	Ipsilateral level II–III	Ipsilateral IV	Ipsilateral SCR Ipsilateral level IV, V Ipsilateral RPN Ipsilateral HP
Level IV <sup>b</sup> (n=5)	Ipsilateral level (II), I, IV		Ipsilateral SCR Ipsilateral level V Ipsilateral RPN Ipsilateral HP
Higher risk for bilateral involvement (additionally to the volumes described above) (n=9)			Contralateral level II–III Contralateral OP

*OP* oropharynx, *HP* hypopharynx, *RPN* retropharyngeal nodes, *SCR* supraclavicular lymph node region. <sup>a</sup>In case of N2c and bilateral N3 status bilaterally radiation was performed. <sup>b</sup>Level IV and V were not involved solitary.

**Tab. 4** Elective mucosal irradiation. Simplified description (individual adaption due to involved lymph node levels). Examples shown in Fig. 1 and Fig. 2

RT volumes		
Lymphatic regions included	Mucosa included	
	Oropharyngeal	Hypopharyngeal
Postoperative bilateral (n=9)	Ipsilateral 54/60 Gy Contralateral 54 Gy	Ipsilateral 54/60 Gy Contralateral 54 Gy or not included
Postoperative unilateral (n=11)	Ipsilateral 54/60 Gy	Ipsilateral 54 Gy or not included (majority)
Definitive bilateral (n=4)	Bilateral 60 Gy (around midline 54 Gy)	Ipsilateral 54 Gy or only upper 1/3 54 Gy or not included
Definitive unilateral (n=4)	Ipsilateral 54 Gy	Ipsilateral 54 Gy or not included (majority)

tively, suffered from nodal persistence following definitive radio- and radiochemotherapy. No patient developed a nodal recurrence. By the time of analysis 9 patients were dead: 6/9 for other reasons than UPC [sepsis, severe pneumonia (not aspiration induced) and cranial bleeding], 3 patients suffered from a progressive second malignancy (1 sigma-carcinoma, 2 lung cancers). Five of 28 patients (18%) developed distant metastases [brain (n=2), bones (n=4), liver (n=2), lung (n=1)], 4, 5, 6, 19, and 36 months after completion of RT. The patients with nodal persistence were inoperable and due to their poor general condition, comorbidity (gastrointestinal malignancy) and/or age, no systemic therapy was carried out. Lo-

cally no complications were observed during follow-up.

### Planning treatment volumes

Unilateral SIB-IMRT was performed in 15/28 patients (54%), either postoperatively (n=11) or as definitive treatment (n=4). In 2 of 15 patients unilateral lymph nodes with contralateral mucosa was irradiated (10 to <20 Gy to the contralateral pathways, Fig. 3). In case of risk factors (see methods) we enlarged treatment volumes to the contralateral lymph node sites [n=13 (46%), postoperatively: 9, definitive: 4]. Contralateral elective PTVs usually included level II and III and the contralateral oropharyngeal mucosa (54 Gy).

Dose prescriptions for different treatment volumes are summarized in Tab. 3. An overview of the lymphatic pathways and the mucosal areas included in the PTVs is shown in Tab. 4.

### Systemic therapy

A total of 20 patients received systemic therapy. In 14 of 17 patients receiving chemotherapy, cisplatin had to be stopped after 1 (n=3), 2 (n=2), 3 (n=4), and 4 (n=5) cycles due to rising levels of creatinine (n=6), cytopenia (n=3), reduced general condition (n=4), or tinnitus (n=2). In 6 of the latter a switch to cetuximab was performed. Three patients received cetuximab as first choice due to previously diagnosed chronic renal failure or hearing impairment. Side effects of cetuximab therapy were acneiform skin reaction (grade III, n=3). One patient developed a grade IV allergic reaction.

### Treatment tolerance

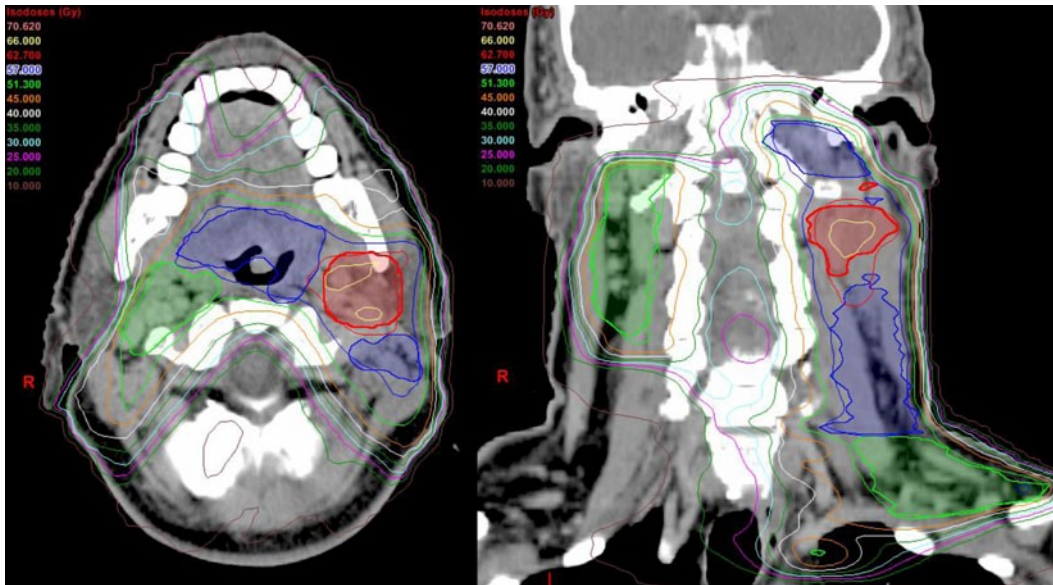
#### Early side effects

Grade III acute radiation induced dermatitis was observed in 11 patients (39%). Three patients suffered from cetuximab-related acneiform skin reaction grade III (11%). One patient reacted with a grade IV anaphylactic shock on loading dose cetuximab and had to be treated on intensive care unit before he fully recovered. One patient developed a grade III glottis edema in the last week of definitive radiotherapy which resolved a few weeks after treatment completion without any invasive therapy (glucocorticoids only). This patient had a N3 disease and was only treated unilaterally due to reduced general condition. He died from cranial bleeding 3 months after completion of radiotherapy.

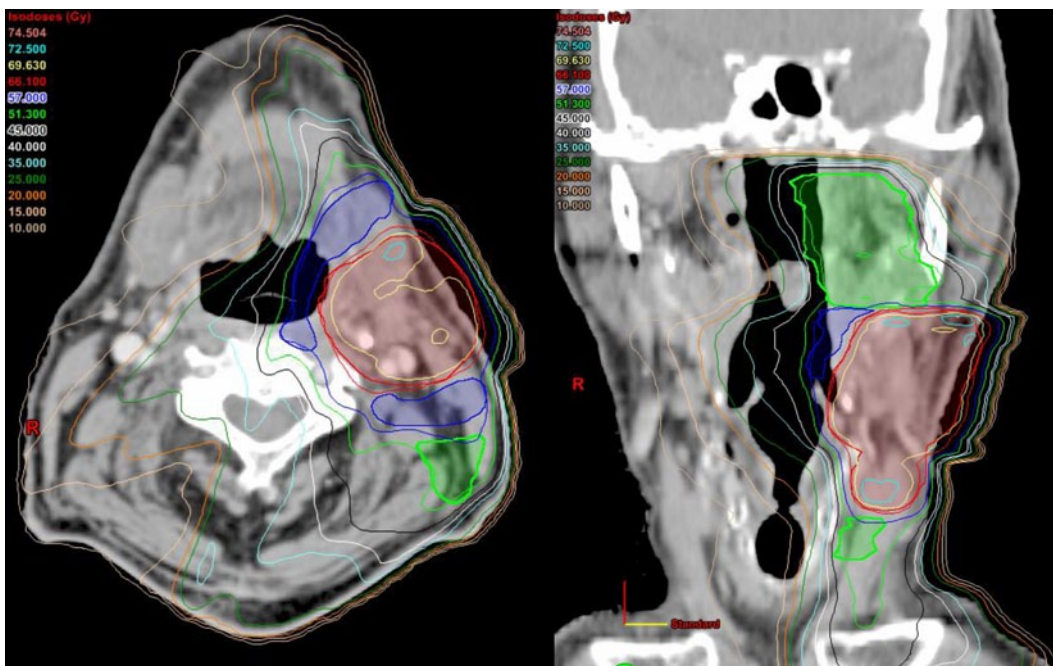
During radiochemotherapy, 3 patients had to be hospitalized due to reduced general condition. One patient having received bilateral IMRT received a gastric tube to ensure nutrition. All acute adverse effects were reversible.

#### Late term effects

No grade II or higher late sequel was seen.



**Fig. 1** ◀ Example of a post-operative bilateral SIB-IMRT. Planning treatment volumes (PTV) with affected lymph nodes in left level II, contralateral level II–III were treated electively up to 54 Gy, *red line*: PTV1 (TD 66 Gy/2 Gy), *blue line*: PTV2 (TD 60 Gy/1.8 Gy), *green line*: PTV 3 (TD 54 Gy/1.64 Gy)



**Fig. 2** ◀ Example of a definitive unilateral SIB-IMRT. Planning treatment volumes (PTV) with affected lymph nodes in left level III. *red line*: PTV1 (TD 69.63 Gy/2.11 Gy), *blue line*: PTV2 (TD 59.4 Gy/1.8 Gy), *green line*: PTV 3 (TD 54.12 Gy/1.64 Gy)

## Discussion

The goal was to evaluate the effectiveness of individualized IMRT target volumes in patients with cervical lymph nodes of UPC.

### Planning treatment volumes

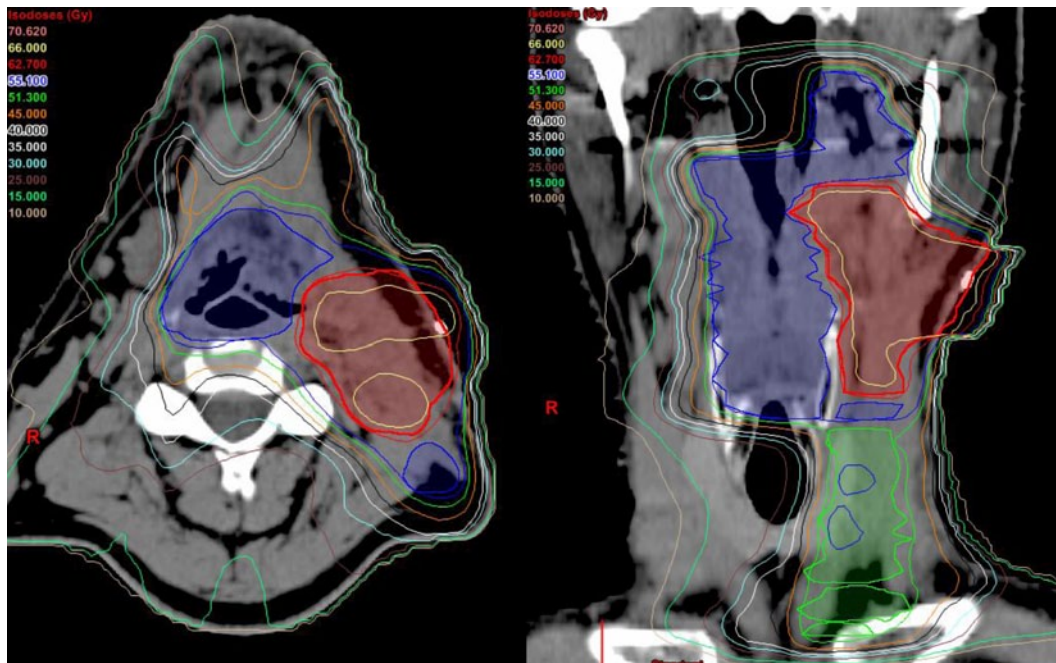
Several study groups compared extended treatment fields as described above with volumes confined to the unilateral lymph node side. As some mostly older studies show extensive radiation of bilateral neck

and entire mucosal axis to be superior in locoregional control [5, 6, 7], other studies did not reveal any differences between bilateral and unilateral neck irradiation [8, 9, 10]. In a different approach Barker et al. [11] showed larynx-sparing radiotherapy to result in a high likelihood of locoregional control and survival. Wallace et al. [1] also practicing elimination of larynx and hypopharynx from RT portals showed comparable outcomes in a larger patient collective (n=179). Patel et al. [23] reserved extended RT for patients at higher risk of locoregional failure such

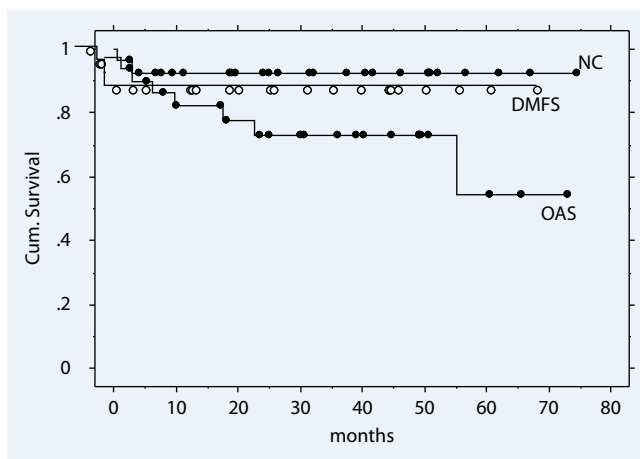
as N2–3 status. Studies dealing with different PTVs in UPC patients are summarized in **Tab. 5**. Except for sporadic patients being treated with IMRT in those series most of the patients received RT in the pre-IMRT area.

### Intensity-modulated radiotherapy

IMRT offers the ability to discriminate between different target volumes, to deliver multiple doses to different targets simultaneously and to reduce the rate and severity of toxicity [15, 19]. Taking those potential



**Fig. 3** ◀ Example of a post-operative unilateral SIB-IMRT including the contralateral mucosa. Planning treatment volumes (PTV) with affected lymph nodes in left level II. *red line*: PTV1 (TD 66 Gy/2 Gy), *blue line*: PTV2 (TD 60 Gy/1.8 Gy), *green line*: PTV 3 (TD 54 Gy/1.64 Gy)



**Fig. 4** ◀ Neck control (NC), distant metastasis-free survival (DMFS), and overall survival (OAS) for patients with cervical lymph nodes of unknown primary cancer (UPC) treated with SIB-IMRT

advantages of IMRT into account several recent studies have been published showing the feasibility of this technique in patients with UPC. The study with the largest patient group (n=52) presented a local control rate and a locoregional control rate after 5 years of 94 and 88%, respectively ([15], Tab. 6). Nevertheless, in all IMRT studies standardized bilateral radiation fields were used for all patients.

### Individualized IMRT treatment volumes

For every patient in our cohort the RT volume was defined depending on the potential risk of lymph node involvement according to Eisbruch et al. [24, 25]. This ap-

proach was adapted to patients with UPC. A summary of our dose and PTV schedule is shown in [Tab. 3](#) and [Tab. 4](#). The primary goal was to avoid extensive volumes while treating patients without oncological compromise. Boost dose was delivered to the involved lymph node areas which were usually level II–III/IV. Adjacent unilateral lymph node levels were also included and treated up to 54 Gy or 60–66 Gy, respectively. The rates of mucosal and nodal control and overall survival are comparable with findings in other studies (see [Tab. 5](#) and [Tab. 6](#)). The 2 patients in our study with persistent disease had large tumor masses of 63 and 116 ccm, respectively. No patient developed a newly diagnosed locoregional failure.

The advantages of IMRT in sparing the parotid glands, pharyngeal tissues, oral mucosa and mandible bone are well documented. In our study, bilateral SIB-IMRT was carried out in 13/28 (46%) patients. In those cases, the mean dose of the contralateral parotid was kept under 20 Gy. Chen et al. [13] observed a median dose of 23.3 Gy to the contralateral parotid gland (compared to 50.5 Gy in conventional 3D treatment). In case of unilateral treatment the contralateral parotid gland only received a median dose of 6.9 Gy in our study which translated to no grade II or higher xerostomia. Another advantage of IMRT in unilateral treatment is the ability to reduce dysphagia while sparing the pharyngeal constrictors. In our series only one patient was in need of a temporary gastric tube.

Chen et al. [14] showed concurrent chemoradiation to be associated with significant more toxicity without a clear advantage to overall survival and locoregional control in UPC patients. Lacking larger randomized trials in patients with UPC, concomitant systemic therapy was generously given as it was shown to be superior in head in neck cancer patients in general especially in presence of certain risk factors like positive resection margins and extra capsular spread [22, 26, 27, 28]. This is supported by Shoushtari et al. [17] who recommend the addition of che-

**Tab. 5** Studies using different radiation–volume concepts in patients with unknown primary cancer

Study, year	Patients (n)	Surgery only (%)	RT (%)	RT + ND (%)	CTx (%)	RT volume		5-year OS (%)	5-year NC (%)	5-year DFS (%)
						Unilateral	Bilateral			
Reddy and Marks 1997 [5]	52	0	40	60	0	Neck: 31%	Neck incl. NP, OP, HP: 69%	40	73 ipsilat	51
Grau et al. 2000 [7]	277	8	77	9	0	Neck only: 9%	Neck incl. NP, OP, HP, LA: 91%	36	51	48
Christiansen 2005 [29]	28	0	39	61	18	Neck: 11%	Neck (incl. possible primary site): 89%	40	73	
Barker et al. 2005 [11]	17	0	29	71	6		Neck + NP, OP	82		88
Beldi et al. 2007 [6]	113	0	48	52	19	Neck: 29%	Neck: 12% Neck + NP, OP, HP: 59%	41		27
Patel et al. 2007 [23]	70	11	65	14	0	Neck: 82%	Neck + NP, OP, HP, LA 18%	56	84 ipsilat 93 contralat.	62
Ligey et al. 2009 [8]	95	0	17	83	45	Neck: 57% Neck + mucosa: 5%	Neck: 1% Neck + mucosa: 37%	24		
Wallace et al. 2011 [1]	179	0	39	61	7	Neck: 3%	Neck plus: OC, OP: 4% OP, NP: 15% OP, HP: 1% NP, OP, HP: 77%	52	81	73
Fakhrian et al. 2012 [9]	65	0	6	94	56	Neck: 26%	Neck, NP, OP, HP, LA: 74%	48		48
Total	844	0	6–77	9–94	0–56			47 range: 24–82	76 range: 51–93	57 range: 27–88

*RPN* retropharyngeal nodes, *NP* nasopharynx, *OP* oropharynx, *HP* hypopharynx, *LA* larynx, *OC* oral cavity, *CTx* chemotherapy, *OS* overall survival, *NC* neck control, *DFS* disease-free survival.

**Tab. 6** Selective studies using IMRT in patients with cervical lymph node metastases of unknown primary cancer

Study (ref) year	Pat	RT (%)	RT + ND (%)	CTx (%)	RT volume		OS (%)	NC (%)	DFS (%)
					Unilateral	Bilateral			
Lu 2008 [16]	18	50	50	33		Bilateral neck + putative mucosal site incl. NP, OP, RPN	74.2 (2 years)	88.3 (2 years)	88.2 (2 years)
Madani et al. 2008 [19]	23	17	83	13		Bilateral neck + extended putative mucosal	74.8 (2 years)	87 (2 years)	76.3 (2 years)
Frank et al. 2010 [15]	52	75	25	27		Bilateral neck (contralateral without Level I/V) entire pharyngeal axis 33%: without HP, LA	89 (5 years)	94 (5 years)	88 (5 years)
Shoushtari et al. 2011 [17]	27	15	75	30		bilateral neck + RPN, Waldeyer's ring	70.9 (5 years)	88.5 (5 years)	85.2 (5 years)
Sher 2011 [30]	24	54	46	92		Bilateral neck + musosa incl. NP, OP, HP, LA	92 (2 years)	100 (2 years)	96 (2 years)
Chen et al. 2011 [13, 14]	27	30	70	63		Bilateral neck + mucosal axis (incl. NP, OP, LA, HP)	86 (2 years)	89 (2 years)	84 (2 years)
Villeneuve et al. 2012 [18]	25	93	7	72		Bilateral neck + ipsilateral putative pharyngeal mucosa (NP, OP, HP, LA)	100 (3 years)	100 (3 years)	100 (3 years)
Own cohort 2014	28	29	71	71	Risk adapted	Unilateral: 54% bilateral: 46%	76 (3 years)	93 (3 years)	81 (3 years)
Total	224	15–93	7–83	13–92	n=15 (own)	n=209 (93%)	83 (2–5 years) range: 71–100	93 (2–5 years) range: 87–100	86 (2–5 years) range: 76–100

*RPN* retropharyngeal nodes, *NP* nasopharynx, *OP* oropharynx, *HP* ypopharynx, *LA* larynx, *ND* neck dissection, *RT* radiotherapy, *CTx* chemotherapy, *OS* overall survival, *NC* neck control, *DFS* disease-free survival.

motherapy in UPC cancer patients with extracapsular extension and bulky N2 or N3 disease.

To summarize, our results are comparable to modern IMRT studies as well as studies evaluating reduced treatment fields (■ **Tab. 5, 6**). We observed no grade II or higher late sequelae so far. We tried to establish some factors standing for a higher risk for potential contralateral disease and/or mucosa involvement. Those risk factors are of course not evidenced based and to some extent subjectively motivated by the treating radio-oncologist. Nevertheless, in the lack of randomized trials, this approach seems to be effective in terms of locoregional control so far and should be confirmed in a larger patient cohort with longer follow-up.

## Conclusion

**Risk-adapted individualized reduction of PTVs is feasible in IMRT treatment of cervical lymph node metastases of UPC showing high mucosal and nodal control rates and a very good treatment tolerance.**

## Corresponding address

### Prof. Dr. G. Studer

Department of Radiation Oncology,  
University Hospital Zurich  
Rämistr. 1000, 8091 Zurich  
Switzerland  
gabriela.studer@usz.ch

## Compliance with ethical guidelines

**Conflict of interest.** S. Janssen, C. Glanzmann, G. Huber, and G. Studer state that there are no conflicts of interest.

The accompanying manuscript does not include studies on humans or animals.

## References

- Wallace A, Richards GM, Harari PM et al (2011) Head and neck squamous cell carcinoma from an unknown primary site. *Am J Otolaryngol* 32:286–290
- Jereczek-Fossa BA, Jassem J, Orecchia R (2004) Cervical lymph node metastases of squamous cell carcinoma from an unknown primary. *Cancer Treat Rev* 30:153–164
- Balaker AE, Abemayor E, Elashoff D, St John MA (2012) Cancer of unknown primary: does treatment modality make a difference? *Laryngoscope* 122:1279–1282
- Strojan P, Ferlito A, Medina JE et al (2013) Contemporary management of lymph node metastases from an unknown primary to the neck: I. A review of diagnostic approaches. *Head Neck* 35:123–132
- Reddy SP, Marks JE (1997) Metastatic carcinoma in the cervical lymph nodes from an unknown primary site: results of bilateral neck plus mucosal irradiation vs. ipsilateral neck irradiation. *Int J Radiat Oncol Biol Phys* 37:797–802
- Beldi D, Jereczek-Fossa BA, D'Onofrio A et al (2007) Role of radiotherapy in the treatment of cervical lymph node metastases from an unknown primary site: retrospective analysis of 113 patients. *Int J Radiat Oncol Biol Phys* 69:1051–1058
- Grau C, Johansen LV, Jakobsen J et al (2000) Cervical lymph node metastases from unknown primary tumours—results from a national survey by the Danish Society for Head and Neck Oncology. *Radiother Oncol* 55:121–129
- Ligey A, Gentil J, Crehange G et al (2009) Impact of target volumes and radiation technique on loco-regional control and survival for patients with unilateral cervical lymph node metastases from an unknown primary. *Radiother Oncol* 93:483–487
- Fakhrian K, Thamm R, Knapp S et al (2012) Radio(chemo)therapy in the management of squamous cell carcinoma of cervical lymph nodes from an unknown primary site. A retrospective analysis. *Strahlenther Onkol* 188:56–61
- Nieder C, Gregoire V, Ang KK (2001) Cervical lymph node metastases from occult squamous cell carcinoma: cut down a tree to get an apple? *Int J Radiat Oncol Biol Phys* 50:727–733
- Barker CA, Morris CG, Mendenhall WM (2005) Larynx-sparing radiotherapy for squamous cell carcinoma from an unknown head and neck primary site. *Am J Clin Oncol* 28:445–448
- Lee N, Puri DR, Blanco AI, Chao KS (2007) Intensity-modulated radiation therapy in head and neck cancers: an update. *Head Neck* 29:387–400
- Chen AM, Li BQ, Farwell DG et al (2011) Improved dosimetric and clinical outcomes with intensity-modulated radiotherapy for head-and-neck cancer of unknown primary origin. *Int J Radiat Oncol Biol Phys* 79:756–762
- Chen AM, Farwell DG, Lau DH et al (2011) Radiation therapy in the management of head-and-neck cancer of unknown primary origin: how does the addition of concurrent chemotherapy affect the therapeutic ratio? *Int J Radiat Oncol Biol Phys* 81:346–352
- Frank SJ, Rosenthal DI, Petsuksiri J et al (2010) Intensity-modulated radiotherapy for cervical node squamous cell carcinoma metastases from unknown head-and-neck primary site: M. D. Anderson Cancer Center outcomes and patterns of failure. *Int J Radiat Oncol Biol Phys* 78:1005–1010
- Lu H, Yao M, Tan H (2009) Unknown primary head and neck cancer treated with intensity-modulated radiation therapy: to what extent the volume should be irradiated. *Oral Oncol* 45:474–479
- Shoushtari A, Saylor D, Kerr KL et al (2011) Outcomes of patients with head-and-neck cancer of unknown primary origin treated with intensity-modulated radiotherapy. *Int J Radiat Oncol Biol Phys* 81:e83–e91
- Villeneuve H, Despres P, Fortin B et al (2012) Cervical lymph node metastases from unknown primary cancer: a single-institution experience with intensity-modulated radiotherapy. *Int J Radiat Oncol Biol Phys* 82:1866–1871
- Madani I, Vakaet L, Bonte K et al (2008) Intensity-modulated radiotherapy for cervical lymph node metastases from unknown primary cancer. *Int J Radiat Oncol Biol Phys* 71:1158–1166
- Studer G, Huguenin PU, Davis JB et al (2006) IMRT using simultaneously integrated boost (SIB) in head and neck cancer patients. *Radiat Oncol* 1:7
- Studer G, Furrer K, Davis BJ et al (2006) Postoperative IMRT in head and neck cancer. *Radiat Oncol* 1:40
- Bonner JA, Harari PM, Giral J et al (2006) Radiotherapy plus cetuximab for squamous-cell carcinoma of the head and neck. *N Engl J Med* 354:567–578
- Patel RS, Clark J, Wyten R et al (2007) Squamous cell carcinoma from an unknown head and neck primary site: a “selective treatment” approach. *Arch Otolaryngol Head Neck Surg* 133:1282–1287
- Eisbruch A, Marsh LH, Dawson LA et al (2004) Recurrences near base of skull after IMRT for head-and-neck cancer: implications for target delineation in high neck and for parotid gland sparing. *Int J Radiat Oncol Biol Phys* 59:28–42
- Eisbruch A, Foote RL, O'Sullivan B et al (2002) Intensity-modulated radiation therapy for head and neck cancer: emphasis on the selection and delineation of the targets. *Semin Radiat Oncol* 12:238–249
- Bernier J, Domezge C, Ozsahin M et al (2004) Postoperative irradiation with or without concomitant chemotherapy for locally advanced head and neck cancer. *N Engl J Med* 350:1945–1952
- Forastiere AA, Goepfert H, Maor M et al (2003) Concurrent chemotherapy and radiotherapy for organ preservation in advanced laryngeal cancer. *N Engl J Med* 349:2091–2098
- Cooper JS, Pajak TF, Forastiere AA et al (2004) Postoperative concurrent radiotherapy and chemotherapy for high-risk squamous-cell carcinoma of the head and neck. *N Engl J Med* 350:1937–1944
- Christiansen H, Hermann RM, Martin A et al. Neck lymph node metastases from an unknown primary tumor retrospective study and review of literature. *Strahlenther Onkol*. 2005; 181: 355–356
- Sher DJ, Balboni TA, Haddad RI et al. Efficacy and toxicity of chemoradiotherapy using intensity-modulated radiotherapy for unknown primary of head and neck. *Int J Radiat Oncol Biol Phys*. 2011; 80:1405–1411