

# Performance of turbo high-pitch dual-source CT for coronary CT angiography: first ex vivo and patient experience

Fabian Morsbach · Sonja Gordic · Lotus Desbiolles · Daniela Husarik ·  
Thomas Frauenfelder · Bernhard Schmidt · Thomas Allmendinger  
Simon Wildermuth · Hatem Alkadhi · Sebastian Leschka

Received: 3 February 2014 / Revised: 15 April 2014 / Accepted: 28 April 2014 / Published online: 17 May 2014  
© European Society of Radiology 2014

## Abstract

**Objectives** To evaluate image quality, maximal heart rate allowing for diagnostic imaging, and radiation dose of turbo high-pitch dual-source coronary computed tomographic angiography (CCTA).

**Methods** First, a cardiac motion phantom simulating heart rates (HRs) from 60–90 bpm in 5-bpm steps was examined on a third-generation dual-source 192-slice CT (prospective ECG-triggering, pitch 3.2; rotation time, 250 ms). Subjective image quality regarding the presence of motion artefacts was interpreted by two readers on a four-point scale (1, excellent; 4, non-diagnostic). Objective image quality was assessed by calculating distortion vectors. Thereafter, 20 consecutive patients (median, 50 years) undergoing clinically indicated CCTA were included.

**Results** In the phantom study, image quality was rated diagnostic up to the HR75 bpm, with object distortion being 1 mm or less. Distortion increased above 1 mm at HR of 80–90 bpm. Patients had a mean HR of 66 bpm (47–78 bpm). Coronary segments were of diagnostic image quality for all patients with HR up to 73 bpm. Average effective radiation dose in patients was  $0.6 \pm 0.3$  mSv.

**Conclusions** Our combined phantom and patient study indicates that CCTA with turbo high-pitch third-generation dual-source 192-slice CT can be performed at HR up to 75 bpm

while maintaining diagnostic image quality, being associated with an average radiation dose of 0.6 mSv.

## Key points

- CCTA is feasible with the turbo high-pitch mode.
- Turbo high-pitch CCTA provides diagnostic image quality up to 73 bpm.
- The radiation dose of high-pitch CCTA is 0.6 mSv on average.

**Keywords** High-pitch CT · Heart rate · Radiation dose · Image quality · Coronary CT angiography

## Introduction

Technical advances in computed tomography (CT) have given radiologists powerful tools to reduce patient dose [1, 2]. This is particularly true for coronary CT angiography (CCTA), in which patient dose has been lowered considerably in the past decade [1]. One of the most recent techniques for reducing radiation dose was prospective electrocardiography (ECG)-triggering at a high pitch, which became available with second-generation dual-source CT [3–5]. With this technique, the entire heart volume can be imaged within the diastolic phase of one heartbeat with an ECG-triggered high-pitch acquisition (table feed 458 mm/s). Hereby, radiation dose could be reduced to range around 1 mSv [3–5]. However, this mode is limited to patients with regular and relatively low heart rates <60 beats per minute (bpm) [6–8].

The use of automated attenuation-based tube voltage selection and tube current in CCTA has shown additional potential for reducing radiation dose while maintaining image quality [9]. In addition, iterative reconstructions can be used in CTCA for another reduction in radiation dose [10]. For example, Schuhbaeck et al. [11] showed that radiation dose can be

F. Morsbach · S. Gordic · L. Desbiolles · D. Husarik ·  
T. Frauenfelder · H. Alkadhi (✉) · S. Leschka  
Institute of Diagnostic and Interventional Radiology, University  
Hospital Zurich, Raemistrasse 100, 8091 Zurich, Switzerland  
e-mail: hatem.alkadhi@usz.ch

L. Desbiolles · S. Wildermuth · S. Leschka  
Division of Radiology and Nuclear Medicine, Kantonsspital St.  
Gallen, St. Gallen, Switzerland

B. Schmidt · T. Allmendinger  
Siemens AG, Healthcare Sector, Forchheim, Germany

lowered to below 0.1 mSv when using a protocol at 80 kVp and when the patient exhibits a heart rate of 60 bpm or less.

Recently, third-generation dual-source 192-slice CT was introduced, which is characterised by another acceleration of table feet to 737 mm/s (pitch 3.2 at a broader detector) and a gantry rotation time of 250 ms (compared with 280 ms of second-generation dual-source CT), allowing for ECG-gated CT at a temporal resolution of 66 ms. Based on these technical features, it is expected that CCTA with third-generation dual-source 192-slice CT may be feasible at higher heart rates as compared to second-generation dual-source CT at a diagnostic image quality.

The purpose of this feasibility study was to evaluate the image quality, maximal heart rate allowing for diagnostic imaging and radiation dose of turbo high-pitch dual-source CCTA with prospective ECG-gating in a cardiac motion phantom study, and to confirm these results in vivo.

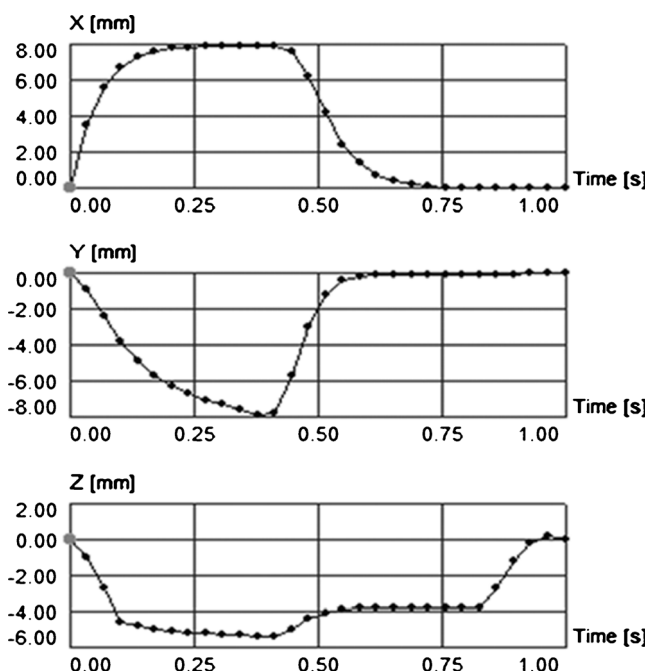
## Material and methods

### Ex-vivo study

#### Phantom preparation

The ex vivo part of our study included images with a cardiac motion phantom [12] coupled to a three-dimensional (3D) motion simulator (QRM-Sim4D-Cardio; Quality Assurance in Radiology and Medicine, Moehrendorf, Germany). The motion simulator permits a range of motion of  $80 \times 40 \times 80$  mm (*x*-, *y*- and *z*-axis) and a maximum frequency of 3 Hz, thereby creating motion sequences simulating 3D heart motion with corresponding simulated ECG (Fig. 1), which can be fed out to the CT machine's ECG control panel. This allows for an ECG-synchronised CT image resembling physiological coronary artery movement. Attached to the 3D motion simulator is the motion arm with a probe holder fitted for multiple tubes. We used three parallel arranged tubes mimicking coronary arteries filled with contrast medium (iopromidum, Ultravist 370; Bayer Schering Pharma, Berlin, Germany) and saline in order to achieve an attenuation of 350 HU at 100 kVp. The inner diameter of the tubes was 3 mm. The tubes were submerged in a water tank and were inserted in the mediastinal aperture of a fitted chest phantom consisting of materials made from epoxy resin and additives, such as calcium carbonate, magnesium oxide, hydroxyapatite and microspheres to obtain soft tissue, lung and bone equivalent structures [12].

The phantom was set to simulate heart rates starting from 60 bpm and increasing in steps of 5 bpm each consecutive image. The maximum heart rate was 90 bpm.



**Fig. 1** Movement pattern output in *x*-, *y*- and *z*-axis of the 3D motion simulator for a simulated heart rate of 60 bpm

#### CT data acquisition—phantom

All examinations were performed on a third-generation dual-source CT system (SOMATOM Force, Siemens Healthcare, Forchheim, Germany) equipped with integrated circuit detectors (Stellar Infinity; Siemens Healthcare) [13]. Examinations were performed using the turbo high-pitch mode at a pitch of 3.2 (table feed 737 mm/s), and using the following imaging parameters: tube voltage of 100 kVp with automated tube-current modulation and a reference tube current-time product of 270 mAs/rotation; collimation of  $96 \times 0.6$  mm; slice acquisition of  $192 \times 0.6$  mm by means of a *z*-flying focal spot; gantry rotation time of 250 ms. The examinations were performed with prospective ECG-gating and acquisition start was synchronised to 60 % of the R-R interval of the simulated ECG.

Images were reconstructed using advanced model-based iterative reconstruction (ADMIRE, strength level 3; Siemens Healthcare) with a medium soft tissue kernel (Bv40) and a slice thickness of 0.6 mm at an increment of 0.4 mm (field of view, 200 mm; pixel matrix,  $512 \times 512$ ). Images were anonymised and transferred to an external workstation (Multi-Modality Workplace; Siemens Healthcare) for further analysis.

#### Subjective image analysis—phantom

Two independent readers (F.M. and S.G. with 3 years of experience in cardiac imaging each) rated the image quality of the tubes in three different cross-sections on multiplanar

reformations visualising the upper, middle and lower part of each tube. The rating was performed using a four-point Likert scale as previously shown [14]: 1=excellent image quality without visible object distortion or image blurring; 2=good image quality with minor object distortion or blurring; 3=fair image quality, intermediate blurring; 4=non-diagnostic image quality with severe object distortion or blurring. Scores of 1–3 were considered as having a diagnostic image quality.

#### Objective image quality analysis—phantom

Objective image quality was assessed by calculating the object distortion vector as previously described [14]. Using multiplanar reconstructions, one reader (L.D. with 4 years of experience in cardiac imaging) measured the change of the outer diameter of the tube ( $x$ ) and the change of the tube length ( $z$ ) for all datasets and calculated the object distortion vector ( $d$ ) using Eq. 1.

$$d = \sqrt{x^2 + z^2} \quad (1)$$

#### Patient study

##### Patient population

Between November 2013 and January 2014, 33 consecutive patients undergoing clinically indicated CCTA were included. All patients were referred to CCTA for evaluation of suspected coronary artery disease, had an intermediate risk of coronary artery disease and suffered from atypical chest pain. The indications were in accordance with current guidelines and recommendations [15]. Patients were included if the patients' ECG after nitrate application (see below) indicated a heart rate  $\leq 75$  bpm and when no arrhythmias were detected. Exclusion criteria were impaired renal function (estimated glomerular filtration rate  $< 30$  ml/min) ( $n=0$ ), known hypersensitivity to iodinated contrast material ( $n=0$ ), pregnancy ( $n=0$ ), and high and/or irregular heart rate ( $n=13$ ). CCTA in these 13 patients was performed in the step-and-shoot ( $n=5$ ) or in the spiral mode with retrospective ECG-gating ( $n=8$ ). Thus, the final study population consisted of 20 patients (median age, 50 years; age range, 43–82 years; 17 men, 3 women). Full patient demographics are shown in Table 1.

IRB approval was obtained; written informed consent was waived because of the retrospective design of the study.

##### CT data acquisition—patients

The images ranged from the level of the tracheal bifurcation to the diaphragm. All patients received a single oral dose of 2.5 mg isosorbiddinitrate sublingually (Isoket, Schwarz Pharma, Monheim, Germany) 3 min prior to the scan. Sixty

**Table 1** Patient characteristics, image quality, imaging parameters, and radiation dose parameters

No. of patients	20
Age (range) [years]	50 (43–82)
Female sex	15 % (3/20)
Heart rate (range) [bpm]	67±9 (47–78)
Body mass index (range) [kg/m <sup>2</sup> ]	25.5±2.1 (22.6–28.5)
Total no. of coronary artery segments	270
Excellent image quality (score 1)	82.1 % (222/270)
Good image quality (score 2)	10.4 % (28/270)
Moderate image quality (score 3)	7.1 % (19/270)
Non-diagnostic image quality (score 4)	0.4 % (1/270)
Attenuation (range) [HU]	556±127 (393–755)
Image noise (range) [HU]	32±10 (26–47)
SNR (range)	17±14 (11–48)
CNR (range)	28±10 (19–48)
Tube voltage (range) [kVp]	86±10 (70–100)
Tube current-time product (range) [mAs]	447±144 (358–616)
Scan length (range) [mm]	125±6 (110–138)
CTDI <sub>vol</sub> (range) [mGy·cm]	2.9±0.9 (1.5–3.4)
DLP (range) [mGy·cm-1]	46±20 (23–84)
Radiation dose estimate (range) [mSv]	0.6±0.3 (0.3–1.1)

SNR signal-to-noise ratio, CNR contrast-to-noise ratio, CTDI<sub>vol</sub> CT volume dose index, DLP dose length product

millilitres contrast media (iopromidum, Ultravist 370, 370 mg iodine/ml; Bayer Schering Pharma, Berlin, Germany) were injected in an antecubital vein, followed by a chaser of 40 ml diluted contrast media (20 % vol) with a dual-head power injector (Stellant; Medrad, Inianola, USA) at a flow rate of 6.0 ml/s. Image initiation was controlled by bolus tracking with a region of interest (ROI) in the ascending aorta, using a signal attenuation threshold of 120 HU. Examinations were performed with prospective ECG-gating during one heart cycle starting at 60 % of the RR-Interval. Automated tube voltage (CAREkV; Siemens) and tube current modulation (CAREdose; Siemens) was used with the following imaging parameters: 100 reference kVp, 270 reference mAs, field-of-view (FoV) 200 mm, pixel matrix 512×512. Data were reconstructed with advanced iterative reconstruction (ADMIRE, strength level 3) with a medium soft tissue kernel (Bv40), a slice thickness of 0.6 mm and an increment of 0.4 mm.

##### Image analysis

Signal-to-noise ratio (SNR), contrast-to-noise ratio (CNR) and image noise were assessed as objective determinants of image quality by the two readers who also performed the objective image quality readout. Calculations of the SNR and CNR in the aorta were independently performed by readers as

previously shown [16]. First, the vessel contrast was calculated as the difference in the mean attenuation (in HU) between the aorta at the level of the left main artery (LM) and the mean attenuation in the epicardial fat tissue at the same slice position. Attenuation in the ascending aorta was measured with a ROI of predefined size ( $155 \text{ mm}^2$ ) avoiding calcifications and plaques. Second, image noise was determined as the standard deviation (SD) of attenuation in the ROI in the ascending aorta. Third, the SNR was calculated by dividing the attenuation in the aorta by the SD, while CNR was calculated using Eq. 2.

$$\text{CNR} = \frac{(\text{attenuation}_{\text{aorta}} - \text{attenuation}_{\text{fat tissue}})}{\text{SD}_{\text{aorta}}} \quad (2)$$

All images were independently evaluated and classified by the two independent radiologists who previously performed the image analysis of the phantom study. The readers were blinded to any text information in the images and any clinical information. For analysis of CCTA data, coronary arteries were segmented according to the 15-segment model of the American Heart Association [17]. The intermediary artery was designated as segment 15, if present. All segments with a diameter of at least 1.5 mm at their origin were included.

The image datasets were presented the observers in random order. For the classification of subjective image quality each coronary artery segment was classified using the same modified Likert scale used above in the phantom study [14]. A score of 1–3 was considered acceptable in terms of image quality for routine clinical diagnostics.

#### Estimation of the CT radiation dose

For an estimation of the CT radiation dose, the CT volume dose index ( $\text{CTDI}_{\text{vol}}$ ), the dose-length-product (DLP) and the scan length were recorded, as previously shown [18]. The effective dose of CTCA was derived from the product of the dose-length product and a conversion coefficient for the chest according to a method proposed by the *European Working Group for Guidelines on Quality Criteria in CT* [19]. A conversion coefficient of  $k=0.014 \text{ mSv} \cdot \text{mGy}^{-1} \cdot \text{cm}^{-1}$  was applied [19, 20].

#### Statistical analysis

Quantitative variables were expressed as mean  $\pm$  standard deviation and categorical variables as frequencies or percentages. The inter-reader agreement regarding qualitative evaluation was analysed by using the intra-class correlation coefficient (ICC, two-way random). According to Landis and Koch [19], a value between 0 and 0.20 was considered as slight agreement; 0.21–0.40 as fair; 0.41–0.60 as moderate; 0.61–0.80 as substantial; 0.81–1 as almost perfect agreement. Wilcoxon signed-rank test was used to test for significant difference in image quality. Pearson's correlation coefficients were used to test for the inter-observer agreement of the noise and contrast attenuation measurements. A two-tailed  $P$  value of  $<0.05$  was considered to indicate statistically significant differences. All statistical analysis was conducted using IBM SPSS Statistics (release 21; Chicago, IL, USA).

## Results

#### Ex vivo study

The inter-observer agreement for subjective image quality grading was almost perfect ( $\text{ICC}=0.894$ ,  $P<0.001$ ). Image quality was diagnostic for all images at a simulated heart rate up to 75 bpm, while at heart rates of 80–90 bpm 63 % of tubes (17/27) were considered of non-diagnostic image quality (Table 2). The image quality at heart rates  $\leq 75$  bpm was significantly superior to that at heart rates of  $\geq 80$  bpm ( $P=0.005$ ). Figure 2 illustrates the image quality of the middle tube at the various heart rates.

The distortion vector remained low at heart rates up to 75 bpm (0 mm) and increased to 1 mm at 80 bpm and continued to increase to more than 4 mm at 90 bpm (Table 2 and Fig. 3).

#### Patient study


Patients had an average heart rate of  $66 \pm 9$  bpm (range, 47–78 bpm). In one patient, heart rate prior to examination was

**Table 2** Subjective and objective image quality in the phantom study in relation to the simulated heart rate

	Simulated heart rate						
	60 bpm	65 bpm	70 bpm	75 bpm	80 bpm	85 bpm	90 bpm
Excellent image quality (score 1)	100 % (9/9)	100 % (9/9)	100 % (9/9)	–	–	–	–
Good image quality (score 2)	–	–	–	89 % (8/9)	11 % (1/9)	–	–
Moderate image quality (score 3)	–	–	–	11 % (1/9)	67 % (6/9)	33 % (3/9)	–
Non-diagnostic image quality (score 4)	–	–	–	–	22 % (2/9)	67 % (6/9)	100 % (9/9)
Object distortion vector [mm]	0	0	0	0	$1 \pm 1$ mm	$2.8 \pm 1$ mm	$4.5 \pm 1$ mm



**Fig. 2** Image quality examples of the contrast medium filled tubes at the different simulated heart rates. Image quality is excellent to good (score 1 and 2) for heart rates of  $\leq 75$  bpm and fair to non-diagnostic (score 3 and 4) at heart rates  $\geq 80$  bpm



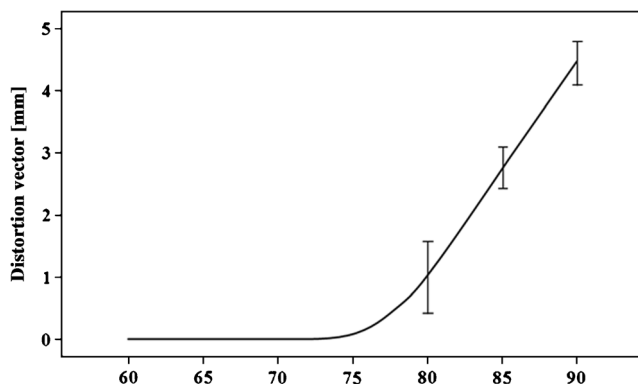
below 75 bpm but slightly increased during data acquisition to an average of 78 bpm. The examination duration for CCTA was  $160 \pm 11$  ms (141–176 ms). The automatic attenuation-based tube voltage selection algorithm choose 70 kVp in one patient, 80 kVp in four patients, 90 kVp in three patients and 100 kVp in two patients, with corresponding increases in effective tube currents (range, 358–616 mAs/rotation).

The inter-observer agreements were almost perfect for measurements of the attenuation (mean difference,  $30 \pm 13$  HU;  $r=0.84$ ,  $P<0.01$ ) and noise (mean difference,  $8 \pm 4$  HU;  $r=0.81$ ,  $P<0.01$ ). Thus, the average of measurements from both readers was used for further analysis.

The inter-observer agreement was almost perfect for subjective image quality per coronary segment (ICC=0.905;  $P<0.001$ ).

Both readers graded in heart rates of up to 73 bpm all coronary segments of diagnostic image quality (i.e. scores of 1–3) (Table 2 and Fig. 4). In the one patient with a heart rate during image acquisition of 78 bpm, the middle segment of the right coronary artery (RCA) was of non-diagnostic image quality due to severe blurring, while the other coronary segments in this patient were of diagnostic image quality (Fig. 5).

The average radiation dose of all CCTA studies in patients was  $0.6 \pm 0.3$  mSv (Table 2).



**Fig. 3** Plot of the distortion vector [mm] at the different simulated heart rates [bpm]. Note the increasing distortion of the tubes at 80 bpm and higher heart rates

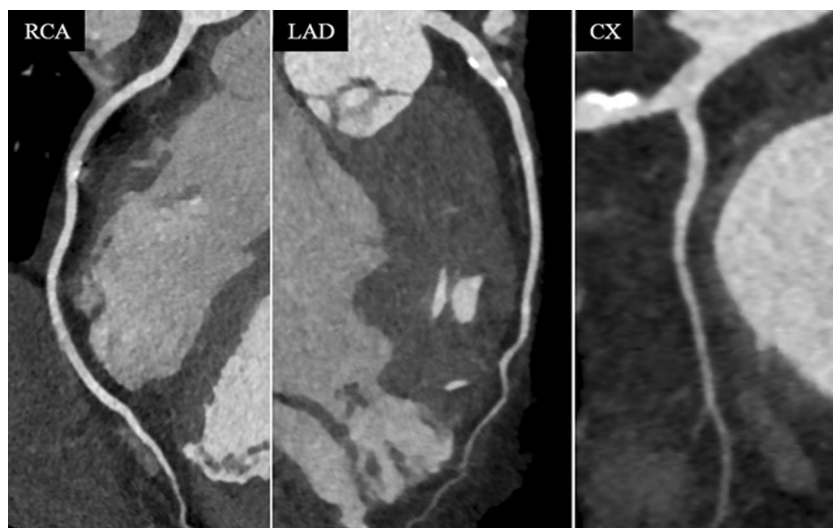
## Discussion

The high-pitch acquisition mode of dual-source systems recently introduced into CCTA permits imaging of the entire heart within one heart beat by continuous and fast movement of the table during CT data acquisition. This mode constitutes an important step forward towards high quality imaging at low radiation doses [3, 5, 21]. With second-generation dual-source CT, the pitch can be increased to a maximum of 3.4 which corresponds to a table speed of 458 mm/s at the given detector width, thus resulting in an acquisition time of the heart of around 0.25 s. Using the high-pitch data acquisition mode with prospective ECG-gating with second-generation dual-source CT, radiation exposure for CCTA can be reduced to around 1 mSv.

As a drawback of the high-pitch acquisition, the projection data of the entire heart needs to be acquired in a single diastasis of the cardiac cycle necessitating a relatively low heart rate (and hence, a relatively long diastole). Thus, the application of high-pitch CCTA has been restricted to patients with a heart rate of 60 bpm or below when using second-generation dual-source CT [5, 6, 14, 22, 23]. In addition, the heart rhythm needs to be stable as the optimal starting time-point for image acquisition has to be foreseen several heart-beats earlier.

The results of our phantom and in vivo feasibility study indicate that the heart rate threshold for high-pitch acquisition with third-generation dual-source CCTA is elevated to 75 bpm. The relevant technical advances of third-generation compared with second-generation dual-source CT in regard to CCTA is the higher acquisition speed (737 mm/s compared with 458 mm/s) and, in addition, the further improvement in temporal resolution (66 ms owing to a gantry rotation time of 0.25 s, compared with 75 ms at a gantry rotation time of 0.28 s). Therefore, compensation of object movement is superior in third-generation dual-source CT due to the faster z-axis coverage at higher heart rates and the higher temporal resolution of each acquired slice decreasing the geometric object distortion and vessel blurring. The results of the phantom study are supported by our first clinical observations in

**Fig. 4** CCTA in a 50-year-old patient with a heart rate of 73 bpm during data acquisition. Image quality was excellent to good (*score 1 and 2*) in all segments of the RCA, LAD and LCX. Radiation dose of this CCTA study was 0.5 mSv

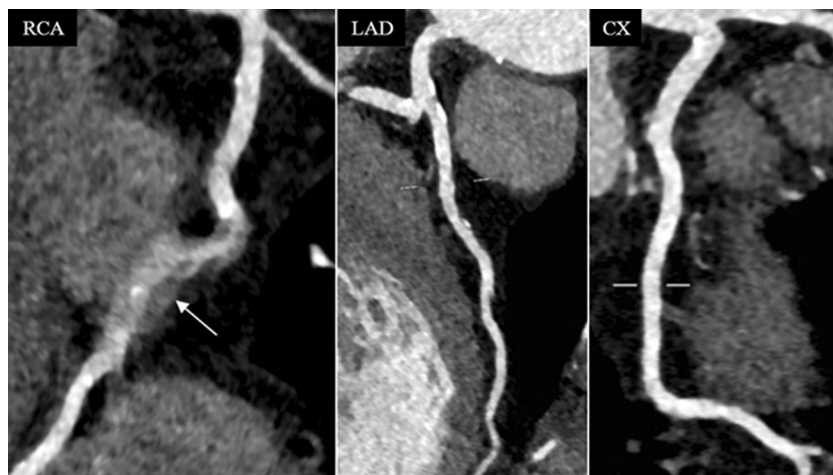

clinically indicated CCTA. Turbo high-pitch CCTA could be successfully performed in all patients with diagnostic image quality at heart rates up to 73 bpm, while image quality of one segment in a patient with a heart rate of 78 bpm was of non-diagnostic image quality. The average radiation dose in the patient part of our study was 0.6 mSv, representing a further reduction as compared to previous reports with second-generation dual-source CT.

We used automated attenuation-based tube potential selection as another means for radiation dose reduction as previously shown [9]. This technique has automatically selected 80 kVp in most of the patients, yielding a high and diagnostic image quality at a high CNR of the vessels. This is in accordance with results from a recent study by Cao et al. [24], who investigated image quality in 120 patients randomly assigned with an 80-kVp protocol. All data were reconstructed with an iterative reconstruction algorithm, which has repetitively shown to be beneficial in terms of image quality in low-dose CCTA [11].

Some limitations of our study have to be addressed. The transfer of the phantom study results into clinical practice is limited. We used a cardiac motion phantom in order to simulate the natural movement of coronary arteries at different heart rates. However, the cardiac phantom simulates a stable heart rhythm, while heart rate variability during CCTA acquisition has been reported to be an important contributor to image quality impairment [25, 26]. Moreover, the tubes in our phantom study were of uniform size and orientation. In order to compensate for these limitations, however, we also included in this study the results of 20 patients referred for clinically indicated CCTA who underwent a similar CT protocol. Still, the small patient population used in our study and the lack of a reference standard for the assessment of coronary artery stenosis necessitates future studies in larger population. Moreover, this study did not exploit all options of the imaging system for lowering the radiation dose to the lowest possible dose, but was aimed at an evaluation of the heart rate dependency of the turbo-flash option for CCTA. For example, a

**Fig. 5** CCTA in a 50-year-old patient with a heart rate of 78 bpm. Image quality was excellent to good (*score 1 and 2*) in all segments of the LAD and LCX, while image quality was non-diagnostic (*score 4*) for segment 2 of the RCA due to blurring artefacts (*arrow*). Radiation dose of this CCTA study was 0.6 mSv



higher strength level of the iterative reconstruction used is associated with a lower image noise, which could be translated to a lower radiation dose (through a reduction of the effective tube current). Finally, we did not test the accuracy of turbo flash CCTA compared with catheter coronary angiography. However, the purpose of this study was to determine the image quality, required heart rate, and radiation dose of the turbo high-pitch mode for CCTA. Finally, the results of this study are only valid for the investigated third-generation dual-source CT system in the turbo-flash mode. Modern CT systems from different vendors provide other acquisition techniques which are beyond the scope of this study.

In conclusion, our combined phantom and in vivo study indicates that CCTA with turbo high-pitch third-generation dual-source 192-slice CT can be performed at heart rates up to 75 bpm while maintaining diagnostic image quality, being associated with an average radiation dose of 0.6 mSv.

**Acknowledgments** The scientific guarantor of this publication is Sebastian Leschka. The authors of this manuscript declare relationships with the following companies: B. Schmidt and T. Allmendinger are employees of Siemens Healthcare. H. Alkadhi and S. Leschka previously served as speakers for Siemens Healthcare. The authors state that this work has not received any funding. No complex statistical methods were necessary for this paper. Institutional Review Board approval was not required because of use of a phantom and also the retrospective nature of the study of clinically indicated CCTA. Written informed consent was waived by the Institutional Review Board. Methodology: retrospective experimental study performed at one institution

## References

- Alkadhi H, Leschka S (2011) Radiation dose of cardiac computed tomography - what has been achieved and what needs to be done. *Eur Radiol* 21:505–509
- Tamm EP et al (2011) Quality initiatives: CT radiation dose reduction: how to implement change without sacrificing diagnostic quality. *Radiographics* 31:1823–1832
- Achenbach S et al (2009) Coronary computed tomography angiography with a consistent dose below 1 mSv using prospectively electrocardiogram-triggered high-pitch spiral acquisition. *Eur Heart J* 31:340–346
- Achenbach S et al (2009) High-pitch spiral acquisition: a new scan mode for coronary CT angiography. *J Cardiovasc Comput Tomogr* 3:117–121
- Leschka S et al (2009) Diagnostic accuracy of high-pitch dual-source CT for the assessment of coronary stenoses: first experience. *Eur Radiol* 19:2896–2903
- Alkadhi H et al (2010) Low-dose, 128-slice, dual-source CT coronary angiography: accuracy and radiation dose of the high-pitch and the step-and-shoot mode. *Heart* 96:933–938
- Goetti R et al (2010) High-pitch dual-source CT coronary angiography: systolic data acquisition at high heart rates. *Eur Radiol* 20:2565–2571
- Stolzmann P et al (2011) Predictors of image quality in high-pitch coronary CT angiography. *AJR Am J Roentgenol* 197:851–858
- Layritz C et al (2013) Automated attenuation-based selection of tube voltage and tube current for coronary CT angiography: reduction of radiation exposure versus a BMI-based strategy with an expert investigator. *J Cardiovasc Comput Tomogr* 7:303–310
- Moscariello A et al (2011) Coronary CT angiography: image quality, diagnostic accuracy, and potential for radiation dose reduction using a novel iterative image reconstruction technique-comparison with traditional filtered back projection. *Eur Radiol* 21:2130–2138
- Schuhbaeck A et al (2013) Image quality of ultra-low radiation exposure coronary CT angiography with an effective dose <0.1 mSv using high-pitch spiral acquisition and raw data-based iterative reconstruction. *Eur Radiol* 23:597–606
- Ulzheimer S, Kalender WA (2003) Assessment of calcium scoring performance in cardiac computed tomography. *Eur Radiol* 13:484–497
- Morsbach F et al (2013) Stenosis quantification in coronary CT angiography: impact of an integrated circuit detector with iterative reconstruction. *Invest Radiol* 48:32–40
- Farshad-Amacker NA et al (2013) Effect of high-pitch dual-source CT to compensate motion artifacts: a phantom study. *Acad Radiol* 20:1234–1239
- Taylor AJ et al (2010) ACCF/SCCT/ACR/AHA/ASE/ASNC/NASCI/SCAI/SCMR 2010 Appropriate Use Criteria for Cardiac Computed Tomography. A Report of the American College of Cardiology Foundation Appropriate Use Criteria Task Force, the Society of Cardiovascular Computed Tomography, the American College of Radiology, the American Heart Association, the American Society of Echocardiography, the American Society of Nuclear Cardiology, the North American Society for Cardiovascular Imaging, the Society for Cardiovascular Angiography and Interventions, and the Society for Cardiovascular Magnetic Resonance. *Circulation* 122:e525–555
- Husmann L et al (2006) Influence of cardiac hemodynamic parameters on coronary artery opacification with 64-slice computed tomography. *Eur Radiol* 16:1111–1116
- Austen WG et al (1975) A reporting system on patients evaluated for coronary artery disease. Report of the Ad Hoc Committee for Grading of Coronary Artery Disease, Council on Cardiovascular Surgery, American Heart Association. *Circulation* 51:5–40
- Stolzmann P et al (2007) Radiation dose estimates in dual-source computed tomography coronary angiography. *Eur Radiol* 18:592–599
- Menzel HG, Schibilla H, Teunen D (eds) (2000) European guidelines on quality criteria for computed tomography. Publication No. EUR 16262 EN. European Commission, Luxembourg
- Einstein AJ et al (2010) Radiation dose from single-heartbeat coronary CT angiography performed with a 320-detector row volume scanner. *Radiology* 254:698–706
- Lell M et al (2009) High-pitch electrocardiogram-triggered computed tomography of the chest: initial results. *Invest Radiol* 44:728–733
- Baumuller S et al (2009) Dual-source versus 64-section CT coronary angiography at lower heart rates: comparison of accuracy and radiation dose. *Radiology* 253:56–64
- Sun G et al (2012) 320-detector row CT coronary angiography: effects of heart rate and heart rate variability on image quality, diagnostic accuracy and radiation exposure. *Br J Radiol* 85:e388–e394
- Cao JX et al (2013) Radiation and contrast agent doses reductions by using 80-kV tube voltage in coronary computed tomographic angiography: a comparative study. *Eur J Radiol* 83:309–314
- Leschka S et al (2008) Effect of decrease in heart rate variability on the diagnostic accuracy of 64-MDCT coronary angiography. *AJR Am J Roentgenol* 190:1583–1590
- Matt D et al (2007) Dual-source CT coronary angiography: image quality, mean heart rate, and heart rate variability. *AJR Am J Roentgenol* 189:567–573