

“Damage Control” in Severely Injured Patients

Why, When, and How?

Marius Keel, Ludwig Labler, Otmar Trentz¹

Abstract

The concept of “damage control” is established in the management of severely injured patients. This strategy saves life by deferring repair of anatomic lesions and focusing on restoring the physiology. The “lethal triad” hypothermia, coagulopathy, and acidosis are physiological criteria in the selection of injured patients for “damage control”. Other criteria, such as scoring of injury severity or the time required to accomplish definitive repair, are also useful in determining the need for “damage control”. The staged sequential procedures of “damage control” include, after the selection of patients (stage 1), “damage control surgery” or “damage control orthopedics” (stage 2), resuscitation in the intensive care unit (stage 3), “second-look” operations or scheduled definitive surgery (stage 4), and the secondary reconstructive surgery (stage 5). The concept of “damage control” was carried out in a third of 622 severely injured patients in our division. Although level I evidence is lacking, the incidence of posttraumatic complications and the mortality rate were reduced. However, better understanding of the significance and kinetics of physiological parameters including inflammatory mediators could help to optimize the “damage control” concept concerning the selection of patients and the time points of staged sequential surgery.

Key Words

Trauma · Injury · Host defense response · Primary survey · Life-saving surgery · Emergency room thoracotomy · Damage control · Damage control surgery · Damage control orthopedics · Bail-out procedure · Vacuum-assisted closure · Abdominal compartment syndrome · Systemic inflammatory response syndrome · Mortality

Eur J Trauma 2005;31:212–21

DOI 10.1007/s00068-005-2034-8

Introduction

The term “damage control” (DC) was coined by the US Navy and refers to keeping afloat a badly damaged ship by procedures to limit flooding, stabilize the vessel, isolate fires and explosions and avoid their spreading [1]. These measures permit damage assessment and gain time to establish plans for definitive salvage. The analogy to the care of a severely injured patient with impending physiological exhaustion is evident and the expression DC was adopted by civilian trauma centers [1, 2].

Battlefield victims with exsanguinating extremity injuries have undergone rapid amputation or deep bleeding wounds have been treated with tamponade packing for hundreds of years. At the beginning of the 20th century, Pringle and Halsted described the digital compression of the portal triad and the use of packing for severe liver injury [3, 4]. These techniques fell out of favor and reappeared with success in the 1970s and 1980s [5–8]. The earlier the liver packing was used the better survival was observed [7]. The concept of abbreviated laparotomy was first described by Stone et al. in 1983 [8]. In this report, abdominal hemorrhage was controlled by tamponade, bowel injuries were resected with oversewing of the bowel ends, noncritical vessels and injured ureters were ligated, and biliopancreatic injuries were drained. The definitive repair of these injuries was carried out after correction of the coagulopathy. The term “damage control” for a successful treatment of penetrating abdominal injuries was popularized by Rondono et al. in 1993 [2]. This strategy has become the

¹Division of Trauma Surgery, University Hospital Zurich, Zurich, Switzerland.

Received: March 23, 2005; revision accepted: April 19, 2005.

standard of care for abdominal trauma of severely injured patients and was defined as rapid abbreviated laparotomy to stop hemorrhage and peritoneal soiling and staged sequential repair after ongoing resuscitation and recovery from the lethal triad hypothermia, acidosis, and coagulopathy [9].

Based on the DC concept for abdominal injuries, the application of the same principles to the management of multiply injured patients with associated fractures of the long bones and pelvic fractures was named “damage control orthopedics” (DCO) [10]. This term was introduced in the 1990s after description of increased incidence of adult respiratory distress syndrome (ARDS) related to the early definitive stabilization (“early total care” [ETC]) of femoral fractures with reamed intramedullary nailing [11, 12]. These pulmonary complications mostly developed in patients with severe chest injuries and after severe hemorrhagic shock [12].

During the last decade several reviews about the DC concept for abdominal as well as for thoracic and orthopedic injuries were published [1, 10, 11, 13, 14]. The aim of this review article is to summarize some physiological considerations and the work-up for severely injured patients with the integration of the DC concept. Answers to the questions why, when and how DC should be done are given. In addition, some data about the own experiences in DC procedures in severely injured patients are presented.

Why? – Pathophysiological Considerations for “Damage Control”

The trauma impact itself determines primary organ or soft-tissue injuries and fractures (first hit, trauma load) with local tissue damages as well as a systemic inflammation with release of pro-inflammatory (“systemic inflammatory response syndrome” [SIRS]) and anti-inflammatory (“compensatory anti-inflammatory response syndrome” [CARS]) cytokines, complement factors, proteins of the contact phase and coagulation systems, acute-phase proteins, neuroendocrine mediators, and an accumulation of immunocompetent cells at the local side of tissue damage (host defense response) [15]. In addition, respiratory distress with hypoxia, uncontrolled hemorrhage with cardiovascular instability, ischemia/reperfusion injuries, avital tissues and contaminations act early as endogenous (antigenic load) second hits. First and second hits can result in the development of the triad hypothermia (core temperature

< 35 °C), coagulopathy, and acidosis [1, 16–20]. Each of these life-threatening abnormalities exacerbates the others, contributing to spiraling cycle with cellular hypoxia and failure of the coagulation system. The core temperature of trauma patients decreases rapidly through a prolonged “on-scene time”. This is aggravated by the administration of cold fluids, the presence of extended abdominal or chest wounds, and the removal of clothing in the emergency room [17]. Hypothermia will shift the oxygen dissociation curve to the left, reduces oxygen delivery and the liver’s ability to metabolize citrate and lactate and may decrease the heart rate, cardiac output, or glomerular filtration rate, and increase systemic vascular resistance and arrhythmias [1, 20]. The failure to normalize either an abnormal lactate serum level or base deficit by 48 h after trauma has been correlated with mortalities ranging from 86% to 100% [18].

Furthermore, prolonged surgical interventions with severe tissue damages, evaporative heat loss or blood loss, inadequate or delayed surgical or intensive care after neglected or missed injuries as well as massive transfusions represent exogenous second hits (interventional or surgical load) with exacerbation of the systemic inflammation and lethal triad [15]. Therefore, the philosophy of DC is to abbreviate surgical interventions by deferring repair of anatomic lesions before the development of irreversible physiological endpoints. This operative concept reduces the mortality rate and the incidence of posttraumatic complications (host defense failure) such as sepsis, ARDS, multiple organ dysfunction syndrome (MODS) or failure (MOF) of severely injured patients [1, 10, 11].

Initial Management – Life-Saving Surgery

Physicians initially treating injured patients must conduct a systemic work-up. According to the Advanced Trauma Life Support (ATLS®) course patients undergo the primary survey of airway, breathing, circulation, neurologic status and core temperature [21]. Patients with extensive trauma who are unconscious (Glasgow Coma Scale [GCS] < 9 points) or in shock benefit from immediate endotracheal intubation and oxygenation. On rare occasions such as severe maxillofacial injuries or laryngeal fractures, patients require a surgical airway management (cricothyroidotomy or tracheostomy) as life-saving procedure (Figure 1). Simultaneous with airway management, a quick assessment of the patient will determine the degree of shock present. A patient with a

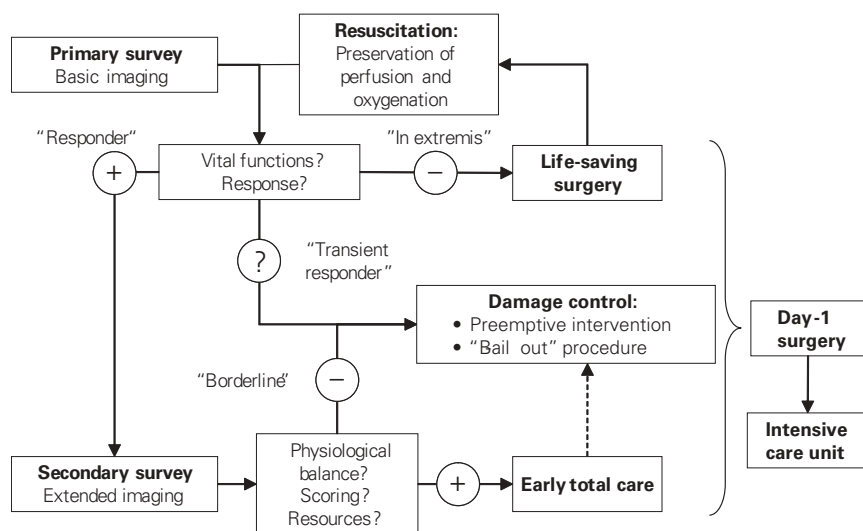


Figure 1. Algorithm of “day-1 surgery”. See text for details and explanations.

systolic blood pressure < 90 mmHg, a thready pulse and flat neck veins is assumed to have hypovolemic shock until proven otherwise. If the neck veins are distended, tension pneumothorax or pericardial tamponade are the most common diagnoses. For tension pneumothorax a needle decompression into the second intercostal space in the midclavicular line followed by a tube thoracostomy represents the life-saving procedure (Figure 1). Pericardial tamponade is mostly observed in patients with penetrating injuries to the torso. A left anterolateral emergency room thoracotomy (ERT) with opening of the pericardium can be life-saving [13].

If the patient’s primary problem in shock is blood loss, the intention is to stop the bleeding and replace the blood loss. Obvious and occult blood loss should be detected immediately. An external bleeding of an open fracture or central amputation as well as closed fractures of long bones should be clinically obvious, whereas hidden blood loss in pleural cavities and the abdomen inclusive of the retroperitoneum and the pelvis are tested by the basic imaging during the primary survey including chest X-ray, ultrasound of abdomen and retroperitoneum and a plain film of the pelvis. Blood loss through vascular injuries in fractures or central amputations should be stopped by manual compression followed by clamping or ligation.

As soon as possible blood work is obtained that includes arterial blood gas analysis, hematocrit, hemoglobin, lactate level, base deficit, pH, toxicology, blood type and cross-match, and a screening battery of other laboratory tests including coagulation parameters. The

fluid used to resuscitate a hypotensive patient and the further work-up will depend on the patient’s response to initial fluid load (2 l crystalloids), the laboratory and further clinical analyses [1, 21]. All fluids need to be at body temperature or above. In addition, to prevent a hypothermia patients can be placed on warming mattresses and their environment kept warm using warm air blankets. The “rapid responder” may require no more than crystalloid to replace the volume deficit and progress to the secondary survey, which focuses on a complete physical examination that directs further diagnostic studies (extended imaging) such as CT

scan trauma protocol (Figure 1). The “transient responder” may need the addition of blood. In exsanguinating patients, type 0 blood should be given, whereas in more stable patients it is prudent to wait for typed and cross-matched blood. With extensive hemorrhage and massive transfusions, component therapy must be directed by monitoring specific coagulative defects. The application of platelets, stored (previously thawed) fresh frozen plasma (FFP) or fibrinogen are well established, whereas the adjunctive treatment of coagulopathy with recombinant activated factor VII (rFVIIa) in trauma patients is undergoing trials [22].

Bickell et al. found that the survival in patients with penetrating torso trauma was improved, if fluid replacement was delayed after immediate surgical control of bleeding [23]. They suggested that immediate volume replacement in these patients might disrupt blood clot that had obliterated a bleeding vessel. The left anterolateral ERT with thoracic aortic cross-clamping and open cardiopulmonary resuscitation as life-saving intervention represents an accepted indication for patients sustaining penetrating cardiac injuries that arrive in trauma centers after a short scene/transport time with witnessed and/or objectively measured vital parameters (patients “in extremis”; Figure 1) [24]. Cardiac injuries may be temporized by digital pressure or the use of a Foley catheter to tamponade bleeding. The pericardium is then opened longitudinally above the phrenic nerve and the cardiac injury repaired. In addition, this access allows to cannulate the right atrium with a catheter for massive resuscitation. For patients sustaining penetrat-

ing noncardiac thoracic injuries or as an adjunct to an emergency room laparotomy (“crash”-laparotomy) for repair of exsanguinating abdominal vascular injuries the ERT or sternotomy should be performed selectively due to its low survival rate (10%) [24]. In addition, in patients sustaining cardiopulmonary arrest secondary to blunt trauma ERT should be carried out only rarely due to its very low survival rate (1.5%) [24]. In patients with exsanguinating abdominal hemorrhage after penetrating or blunt trauma and without response to fluids “crash”-laparotomy can be needed to control the abdominal aorta either digitally at the aortic hiatus or by placement of an aortic infradiaphragmatic cross clamp [25].

When? – Indications for “Damage Control”: Stage 1

If patients “in extremis” survive life-saving procedures, DC interventions are used for associated injuries. On the basis of clinical and laboratory findings during primary or secondary survey a decision for DC as “pre-emptive intervention” should be made: stage 1 of DC (Figure 1) [26]. Patients with a “transient response” to resuscitation with a hypotension (< 90 mmHg) in excess of 70 min or a transfusion rate of 10–15 units of packed red blood cells should be transferred to the operating room (OR) without delay and undergo DC procedures [1]. In addition, attempts have been made to define physiological criteria for the initiation of DC based on hypothermia (< 34 °C), coagulopathy (prothrombin time > 19 s or partial thromboplastin time > 60 s; platelet count < 90,000) and acidosis (pH < 7.2 or lactate serum level > 5 mmol/l), but this has still not been standardized and validated by prospective studies [1, 26, 27]. Further cited indications especially for DCO concern type and severity of injury (Injury Severity Score [ISS] > 35 points; severe head injury AIS [Abbreviated Injury Scale] > 2 points; multiple injuries with an ISS > 20 points and additional thoracic trauma AIS > 2 points; multiple injuries with abdominal/pelvic trauma and hemorrhagic shock; radiographic evidence of bilateral pulmonary contusion) as well as type of surgery (presumed operation time > 60 min and expected major blood loss) [10, 11, 27, 28]. These first-hit and second-hit phenomena predispose these patients “at risk” or “borderline” to deterioration after surgery and justify the decision for DC.

During ETC interventions intraoperative problems can arise or unexpected associated injuries are found. Inability to achieve hemostasis due to coagulopathy, in-

accessible major venous injury, time-consuming procedures in a patient with suboptimal response to resuscitation, reassessment of intraabdominal contents, and inability to reapproximate abdominal fascia due to visceral edema are reasons for turning to the DC concept as “bail-out” procedure (Figure 1) [1].

Furthermore, ancillary issues indicating benefits of DC are limited resources in a mass casualty, a limited experience of the surgical team in complex injuries, or a fatigued and overwhelmed surgical team. However, selecting DC too careless may mean an unnecessarily premature termination of surgery in patients who would otherwise have recovered from a single definitive procedure. It would subject the patients to risks and expense of multiple surgical interventions.

How? – Staged Sequential Procedures

“Damage control surgery” (DCS) for nonorthopedic injuries and DCO for musculoskeletal injuries, respectively, can be described as staged sequential procedures [1, 10, 11, 26]. In stage 2 of DC an abbreviated surgery for rapid control of hemorrhage and contamination, stabilization of long bones or large joints and pelvic ring, provisional closure of wounds or abdominal cavity is carried out [26]. Thereafter, the patient is moved to the intensive care unit (ICU), where stage 3 consists of ongoing core rewarming, correction of coagulopathy, fluid resuscitation and optimization of hemodynamic status with correction of the acidosis, reexamination of the patient (“tertiary survey”) to diagnose missed injuries as well as specific management of patients with traumatic brain injury (TBI). When normal physiology has been restored, “second looks” or staged definitive surgery (stage 4) can be undertaken usually within 24–72 h after trauma [1, 26] (Table 1). Concerning definitive fracture repair there is a “window of opportunity” between days 4 and 10 after trauma [10, 11, 27]. Extensive secondary reconstructive surgery (stage 5) is recommended after recovering from the status of immunosuppression (CARS) and from a catabolic to an anabolic metabolism (≥ 4 weeks), respectively (Table 1) [15].

“Damage Control Surgery”: Stage 2

Thoracic injuries. The anterolateral thoracotomy permits rapid access to the thoracic cavity [1, 13, 24]. If a pulmonary hilar hematoma or active hemorrhage are present, cross-clamping of the pulmonary hilum may be necessary. Stapled, nonanatomic wedge resections of the lung can achieve hemostasis and control of air leaks.

Table 1. Operative phases. See text for details and explanations.

Physiological status	Operative interventions	Timing
Balance: Vital functions? Response?	Life-saving surgery	Day-1 surgery
	Damage control surgery	
	Early total care	
Hyperinflammation (SIRS)	"Second look" only!	Days 2-3
Window of opportunity	Scheduled definitive surgery	Days 4-10
Immunosuppression (CARS)	No elective surgery!	Days 11-21
Recovery	Secondary reconstructive surgery	≥ 4 weeks

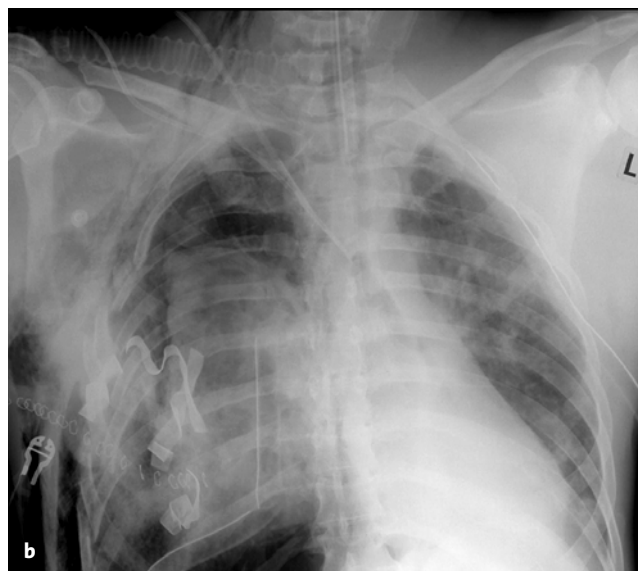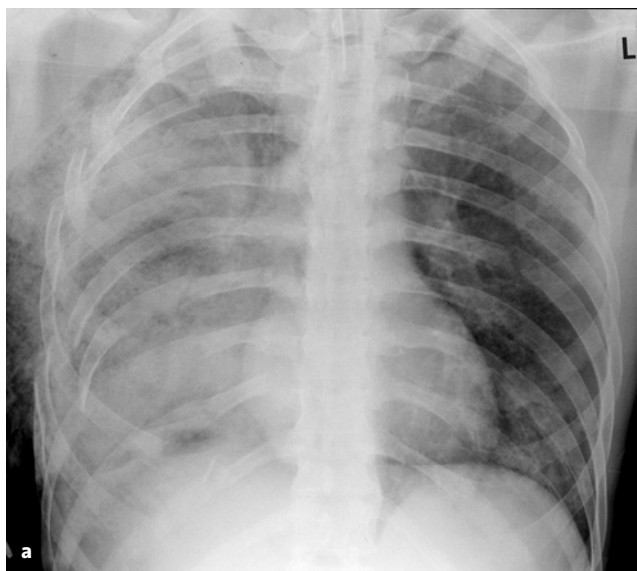
Pulmonary tractotomy using long clamps or stapler may be an effective way to control hemorrhage in penetrating lung injury [29]. Resection of the affected lobe or lung for injuries involving hilar bronchi or vessels is preferable to extensive repairs. Packing the thoracic cavity is useful for chest wall or diffuse bleeding from the pulmonary parenchyma (Figure 2) [1, 13].

Abdominal injuries. The DC laparotomy includes five components: control of hemorrhage, exploration, control of contamination, definitive packing, and rapid abdominal closure [1, 26]. The incision of choice is midline from xiphoid process to pubic symphysis.

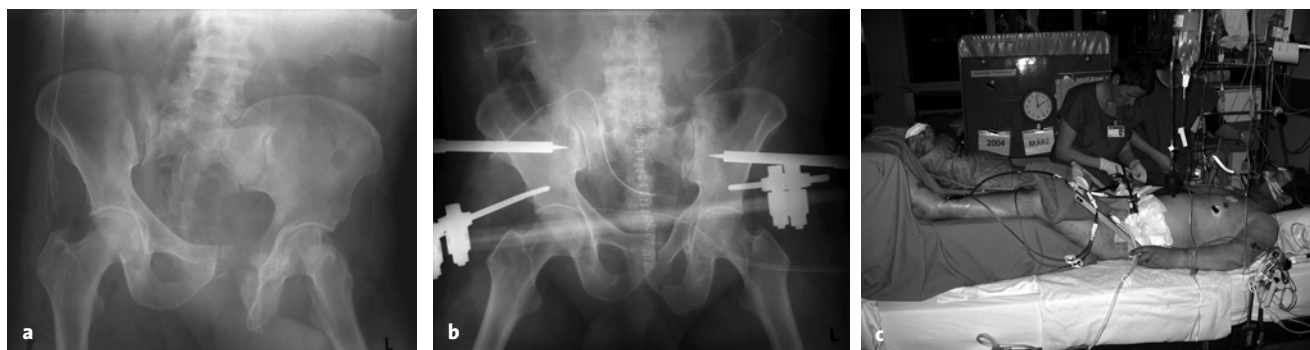To control hemorrhage, blood and clot are quickly removed digitally and by suction. Thereafter, lateral re-

traction of abdominal wall is performed to enable initial resuscitative four-quadrant packing. If bleeding seems controlled with packing, this is an excellent time to allow the anesthesia team to stabilize the patient with volume therapy. Temporary infradiaphragmatic aortic occlusion or balloon catheter tamponade may be necessary for completion of hemorrhage control. The exact exploration follows pack removal, beginning from the suspected sites of injury. Abdominal vascular injuries are managed as described below. Techniques to control liver bleeding include, besides the workhorse of perihepatic packing after Pringle maneuver, direct ligation of bleeding vessels, hepatorrhaphy, cauterization, topical hemostatic agents, partial resection, hepatic artery ligation, catheter balloon tamponade or angiographic embolization [3-7]. Splenic injuries require mostly an immediate splenectomy. Attempts at splenorrhaphy or partial resection should be reserved for stable patients. Occasionally, the splenic fossa needs packing to allow tamponade of small vessels until coagulopathy is reversed. If no compelling bleeding source has been found, then retroperitoneal vascular, renal or pelvic injuries are likely sources [1]. Severe renal injury in the exsanguinating patient is best dealt by nephrectomy, if a contralateral kidney is palpable [1]. Alternatives are retroperitoneal packing or postoperative embolization.

Hollow viscus injury must be controlled with clamps, staples, suturing, or resection without anastomosis. Injuries to the pancreas should be primarily managed by



Figures 2a and 2b. Chest X-ray of a multiply injured patient with flail chest at admission (a) and 24 h after right anterolateral thoracotomy with packing of the thoracic cavity (b).



Figures 3a to 3c. Plain films of the pelvis of a multiply injured patient with vertical shear injury of the right side preoperatively (a) and postoperatively (b) after application of a pelvic clamp and external fixator as well as pelvic packing and abdominal vacuum-assisted closure after laparotomy. Physiological restoration of the patient in the ICU (c).

drains and packing. Urethral and bladder injuries of unstable patients are managed temporarily with splinting and/or suprapubic urinary diversion [1].

After temporary control of hemorrhage and contamination a decision for definitive repair of a part or all intraabdominal injuries should be made according to the physiological parameters. In the face of the “lethal triad” a definitive packing is followed by a rapid skin closure [1, 26]. Leaving the fascia open limits the risk of abdominal compartment syndrome (ACS) and preserves the fascial edges [1, 26, 30]. Massive visceral edema makes the closure sometimes impossible and the open abdomen can be temporarily closed with a prosthetic material, zipper (Ethizip[®]), plastic sheet or a vacuum pack technique such as the abdominal vacuum-assisted closure (V.A.C.[®]) [31].

Vascular injuries. Percutaneous vascular control using balloon tamponade through the wound site has been described. Simple lateral repair of vascular injury is a rapid technique, whereas end-to-end anastomosis or graft interposition are time-consuming [1]. As “bail-out” procedure most arteries and veins can be ligated to save the patient’s life. However, ligation of the aorta, vena cava, superior mesenteric artery, or common or external iliac artery often precipitates significant ischemia with a high mortality and should be reserved only for desperate situations [1]. An alternative to ligation may be the rapid placement of temporary arterial or venous shunts [32, 33].

Pelvic fractures. The management of multiply injured patients with pelvic ring disruption and severe hemorrhage is still under debate [34, 35]. It is well accepted that the displaced pelvic ring injury must rapidly be reduced and stabilized by external fixator for the anterior pelvic ring and C-clamp for the posterior ring

(Figure 3) [34, 36]. The methods by which control of hemorrhagic shock is achieved vary from laparotomy with pelvic packing to angiographic embolization. The rationale for pelvic packing is the following: bleeding from the venous plexus can only be effectively controlled by local packing with the pelvic ring as stable abutment; arterial bleeding can also be successfully treated by pelvic packs; bleeding from large-bore vessels can be controlled surgically; complex pelvic injuries are often combined with intraperitoneal lesions [34]. However, in rare situations with persistent hemorrhagic shock combined procedures with intra- or postoperative angiographic embolization are necessary.

Extremity fractures and soft-tissue injuries. Closed or open fractures of long bones or highly unstable large joints should be temporarily stabilized by external fixators [10, 11]. For some closed or open fractures the fast application of locking compression plates (LCPs) as internal fixators in a minimally invasive technique represents an alternative (Figure 4). Open wounds and fractures should undergo a debridement with resection of avital tissues to limit the antigenic load. Fasciotomy should be performed liberally in the settings of ischemia, imminent or manifest compartment syndromes. Wounds are temporarily closed by Epigard[®] or V.A.C.[®] [37]. However, in patients with a massive coagulopathy tamponades as temporary closure are preferable to avoid persistent bleeding. In mangled extremity, very little time and blood should be spent debating the limb salvageability [1].

Head injuries. Although the aim of neurotrauma procedures is to avoid secondary brain damages, placement

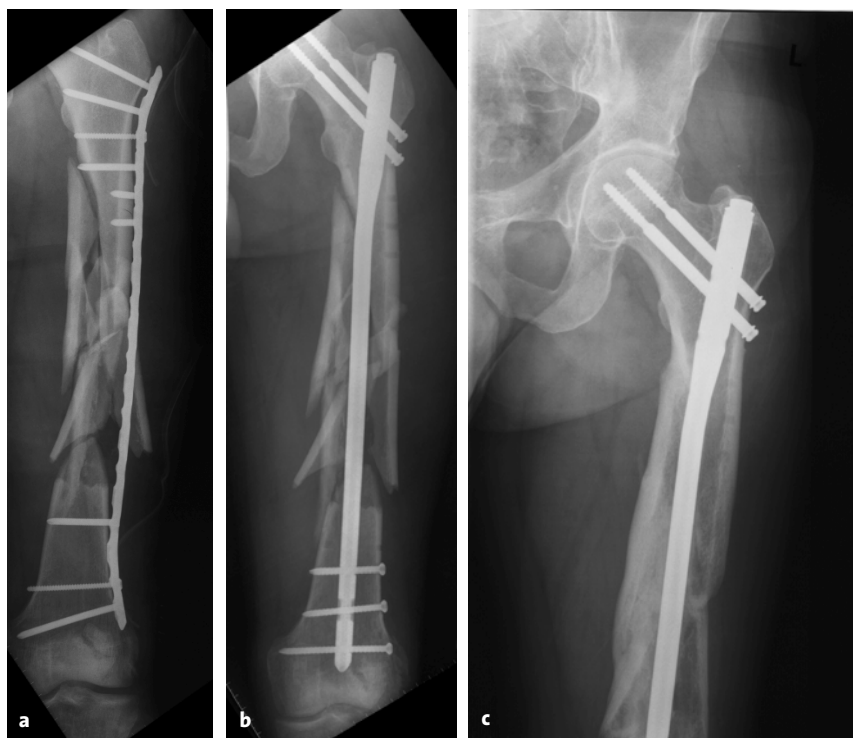of a ventricular catheter through a burr hole, craniotomy or craniectomy (removal of the bone flap) with arrest of intracranial bleeding and evacuation of intracranial hematoma, or a decompressive craniectomy are not abbreviated surgical interventions and belong to the ETC concept. However, an immediate decompressive craniectomy for an epidural hematoma is life-saving [38].

Resuscitation in ICU: Stage 3

Priorities in the ICU focus on restoration of the lethal triad hypothermia, coagulopathy, and acidosis as well as an optimization of the oxygen delivery [1, 16–19, 25]. Endpoints include a core temperature $> 35^{\circ}\text{C}$, normalization of the prothrombin time, and a systemic lactate level < 2.5 mmol/l within 12 h [1, 26].

Additionally, an array of supportive therapies are established to avoid secondary hits and organ damages [15]. Secondary brain injuries with elevated intracranial pressure (ICP) due to cerebral edema or ischemia/reperfusion injuries can be limited by applying different neuroprotective strategies, such as optimization of the cerebral perfusion pressure (CPP) through increase of mean arterial pressure and release of cerebrospinal fluid (CSF), controlled hyperventilation, moderate hypothermia, and whenever these therapeutic regimens fail to reduce ICP, intravenous administration of barbiturate may become necessary [15, 38]. An early enteral nutrition through gastric or duodenal tubes reduces the accumulation of pathogenic bacteria in the intestinal tract and avoids an atrophy of intestinal mucosa, an essential bacterial barrier. Immune-enhanced enteral nutrition (IEEN; e.g., arginine, glutamine) reduces the posttraumatic hypermetabolism and improves the immunocompetence [15].

A common, serious, and often insidious complication of abbreviated laparotomy is the ACS with progressive oliguria and advancing hypoxemia [1, 26, 30]. The most accurate and simple method to detect an evolving ACS is measuring bladder pressure via the Foley catheter [1, 26, 30].



Figures 4a to 4c. X-rays of the left multiply fractured femur of a severely injured patient after stabilization with a locking compression plate (LCP) as internal fixator through small incisions (a), after definitive stabilization with an antegrade femoral nail (b), and 1 year after trauma with complete consolidation of the fracture (c).

“Second Look” and Scheduled Definitive Surgery: Stage 4

Timing for return to the OR is governed by the injury pattern, the planned operative procedure, the physiological response in the ICU, or the development of complications [1, 26]. Patients, who have been packed for hemorrhage control, are returned to the OR within 24 h post-injury as “second look” for removal of packs, clotted blood, and fluid collections, debridement of avital tissue, reconstructions of digestive tract, urethral or bladder injuries, colostomy formation, duodenal feeding access, and rarely extensive procedures such as pancreaticoduodenectomy. Recurrent or persistent bleeding (more than 10 units of packed red blood cells in the early postoperative period) will necessitate immediate repacking or angiographic embolization. Patients who develop ACS or intestinal necrosis undergo relaparotomy without delay. After temporary closure of the abdomen by V.A.C.[®] because of extensive reperfusion-induced gut distension, “second looks” are delayed 48–72 h, awaiting sufficient edema resorption to allow abdominal fascial closure if possible, otherwise a new V.A.C.[®] is applied to reduce the edema [31].

Definitive operations (nailing, plating) of extremity or pelvic fractures as well as plastic reconstructive surgery for the closure of open wounds (e.g., muscle transfer) of severely injured patients should be delayed until after the 4th day from initial surgery [10–12]. An imminent or manifest compartment syndrome of extremities in the posttraumatic course or after fracture stabilization requires an immediate fasciotomy.

Secondary Reconstructive Surgery: Stage 5

Reconstructive operations after abdominal injuries include abdominal wall reconstruction or anastomosis after colostomy [1, 26]. Staged laparotomy can be complicated by open abdomen incisional hernia. Fascial approximation is precluded by fascial retraction after multiple delayed procedures or abdominal wall loss through the trauma itself or infection. The usual approach to abdominal wall reconstruction is to bridge the fascial defect with a synthetic mesh template to facilitate secondary wound healing or a bilateral fascial release, rarely a local muscle flap rotation is necessary [1, 26]. However, the use of abdominal V.A.C.[®] has resulted in higher fascial closure rates (90%), obviating the need for subsequent hernia repair in most patients [31]. The utility of the vacuum-assisted fascial closure technique is not limited to the early postoperative period, but can be successful as much as ≥ 4 weeks after the initial operation [31].

Complex reconstructive procedures of ligamentary joint injuries, secondary joint prosthesis or nerve reconstructions can be planned in this stage. Furthermore, the bone defect after craniectomy is repaired or the bone flap replaced in secondary cranioplasty procedure once all the brain swelling has subsided ≥ 6 weeks after trauma.

Own Experiences in “Damage Control”

In a 6-year period 622 severely injured patients with an ISS > 16 points were included in a retrospective analysis, if they arrived at the ICU after surviving day-1 surgery. 205 patients (33%) were classified to the DC group, 417 (67%) to the ETC group (Table 2). The ISS and the injury pattern were different in the two groups, while the age was comparable. The ISS was significantly higher, and the injury pattern was more complex in the DC group (Table 2). Concerning physiological parameters at admission, core temperature, prothrombin time %, serum lactate level, and hemoglobin were more pathologic in the DC group (Table 2). In addition, a higher proportion of severe hemorrhagic shock (grades

Table 2. Demographic data and physiological parameters at admission of severely injured patients managed by “damage control” or “early total care”. Data are presented in % or in mean \pm SEM (standard error of mean). ATLS[®]: Advanced Trauma Life Support; ISS: Injury Severity Score.

	“Damage control”	“Early total care”
Demographic data		
• Patients (n)	205 (33%)	417 (67%)
• Age (years)	40.2 \pm 1.3	39.8 \pm 0.8
• ISS (points)	36.1 \pm 0.9	31.8 \pm 0.6
Injury pattern		
• Head	56%	84%
• Thorax	64%	55%
• Abdomen	46%	22%
• Pelvis	37%	15%
• Extremity	86%	46%
Penetrating injuries	15%	7%
Physiological parameters at admission		
• Core temperature (°C)	34.6 \pm 0.1	35.6 \pm 0.1
• Prothrombin time % (PT%)	69.2 \pm 1.5	82.3 \pm 0.9
• Serum lactate level (mmol/l)	4.1 \pm 0.9	2.9 \pm 0.1
• Hemoglobin (g/dl)	9.4 \pm 0.7	11.8 \pm 0.1
• Severe hemorrhagic shock (grades III or IV according to ATLS [®] classification [21])	19%	7%

III or IV according to the ATLS[®] classification [21, 24]) could be observed in the DC group (Table 2).

Patients surviving the first 3 days on ICU developed more infectious or septic complications in the DC group, whereas the incidence of severe SIRS was comparable

Table 3. Posttraumatic morbidity and mortality of severely injured patients after “damage control” or “early total care” management and arriving on intensive care unit (ICU). Data are presented in % or in mean \pm SEM (standard error of mean). MODS: multiple organ dysfunction syndrome; SIRS: systemic inflammatory response syndrome.

	“Damage control”	“Early total care”
Morbidity ^a		
• Severe SIRS (3 or 4 SIRS criteria are fulfilled [15])	46%	41%
• Sepsis (4 SIRS criteria and detected infectious focus [15])	30%	19%
• Infections	57%	42%
• Pneumonia	31%	27%
• MODS score (Marshall et al. [39]) (points)	7.9 \pm 0.3	6.3 \pm 0.2
Mortality		
• Head injury (tentorial herniation)	49%	77%
• Hemorrhagic shock	16%	2%
• Multiple organ failure	35%	21%

^a Data of morbidity concern only patients surviving the first 3 days after arriving on ICU

(Table 3). In accordance with the septic complications the mean multiple organ dysfunction score was higher in the DC group compared with the ETC group [39]. However, the mortality rate was equal in both groups (Table 3). Head injury was the killer in the ETC group, whereas in the DC group the causes of death were more heterogeneous.

Although the ISS and the incidence of infectious and septic complications are higher in the DC group, the mortality rate is identical. These data emphasize the benefit of the decision for the DC concept for severely injured patients with a complex injury pattern. However, head injury represents the leading killer after DC and ETC management of severely injured patients.

Conclusion

The concept of DC is well established for the management of thoracic, abdominal, vascular, pelvic, extremity and soft-tissue injuries in severely injured patients. Although level I evidence is lacking, reasonably clear indications and defined endpoints for each stage were evolved and the mortality rate was reduced [1, 26]. However, better understanding of the significance and kinetics of physiological parameters including inflammatory mediators (“beside immunomonitoring”) could help us in the decision-making for selection of patients and the optimal time points of staged sequential surgery to limit second hits and therefore to optimize the DC concept [10, 11, 13, 15].

References

- Shapiro MB, Jenkins DH, Schwab CW, et al. Damage control: collective review. *J Trauma* 2000;49:969–78.
- Rotondo MF, Schwab W, McGonigal MD, et al. Damage control: an approach for improved survival in exsanguinating penetrating abdominal injury. *J Trauma* 1993;35:375–83.
- Pringle J. Notes on the arrest of hepatic hemorrhage due to trauma. *Ann Surg* 1908;48:541–9.
- Halsted WS. Ligature and suture material. *JAMA* 1913;LX:1119–26.
- Walt AJ. The mythology of hepatic trauma – or Babel revisited. *Am J Surg* 1978;135:12–8.
- Feliciano DV, Mattox KL, Jordan GL Jr. Intra-abdominal packing for control of hepatic hemorrhage: a reappraisal. *J Trauma* 1981;21:285–90.
- Garrison J, Richardson D, Hilakos A, et al. Predicting the need to pack early for severe intra-abdominal hemorrhage. *J Trauma* 1996;40:923–9.
- Stone HH, Strom PR, Mullins RJ. Management of the major coagulopathy with onset during laparotomy. *Ann Surg* 1983;197:532–5.
- Burch J, Oritz V, Richardson R, et al. Abbreviated laparotomy and planned reoperation for critically injured patients. *Ann Surg* 1992;215:476–84.
- Giannoudis PV. Aspects of current management: surgical priorities in damage control in polytrauma. *J Bone Joint Surg Br* 2003;85:478–83.
- Pape HC, Giannoudis PV, Krettek C. The timing of fracture treatment in polytrauma patients: relevance of damage control orthopaedic surgery. *Am J Surg* 2002;183:622–9.
- Pape HC, Hildebrand F, Perschy S, et al. Changes in the management of femoral shaft fractures in polytrauma patients: from early total care to damage control orthopedic surgery. *J Orthop Trauma* 2004;18:Suppl:513–23.
- Wall MJ, Soltero E. Damage control for thoracic injuries. *Surg Clin North Am* 1997;77:863–78.
- Porter JM, Ivatury RR, Nassoura ZE. Extending the horizons of “damage control” in unstable trauma patients beyond the abdomen and gastrointestinal tract. *J Trauma* 1997;42:559–61.
- Keel M, Trentz O. Pathophysiology of polytrauma: a review. *Injury* 2005;in press.
- Ferrara A, MacArthur J, Wright H, et al. Hypothermia and acidosis worsen coagulopathy in the patient requiring massive transfusion. *Am J Surg* 1990;160:515–8.
- Gregory J, Flancbaum L, Townsend M, et al. Incidence and timing of hypothermia in seriously injured patients. *J Trauma* 1991;31:795–800.
- Abramson D, Scalea T, Hitchcock R, et al. Lactate clearance and survival following injury. *J Trauma* 1993;35:584–9.
- Gubler K, Gentilello L, Hassantash S, et al. The impact of hypothermia on dilutional coagulopathy. *J Trauma* 1994;36:847–51.
- Cosgrif N, Moore EE, Sauaia A, et al. Predicting life-threatening coagulopathy in the massively transfused patient: hypothermia and acidosis revisited. *J Trauma* 1997;42:857–62.
- Collicott PE, Hughes I. Training in Advanced Trauma Life Support. *JAMA* 1980;243:1156–9.
- Parr MJA, Alabdi T. Damage control surgery and intensive care. *Injury* 2004;35:713–22.
- Bickell WH, Wall MJ Jr, Pepe PE, et al. Immediate versus delayed fluid resuscitation for hypotensive patients with penetrating torso injuries. *N Engl J Med* 1994;331:1105–9.
- Demetriades D, Asensio JA. Trauma management. Georgetown: Landes Bioscience, 2000.
- Carrillo EH, Bergamini TM, Miller FB, et al. Abdominal vascular injuries. *J Trauma* 1997;43:164–71.
- Moore EE. Staged laparotomy for the hypothermia, acidosis, and coagulopathy syndrome. *Am J Surg* 1996;172:405–10.
- Pape HC, Giannoudis PV, Krettek C, et al. Timing of fixation of major fractures in blunt polytrauma – the role of conventional indicators in clinical decision making. *J Orthop Trauma* 2005;in press.
- Giannoudis PV, Veysi VT, Pape HC, et al. When should we operate on major fractures in patients with severe head trauma? *Am J Surg* 2002;183:261–7.
- Wall MJ, Villavicencio RT, Miller CC, et al. Pulmonary tractotomy as an abbreviated thoracotomy technique. *J Trauma* 1998;45:1015–23.
- Ertel W, Oberholzer A, Platz A, et al. Incidence and clinical pattern of the abdominal compartment syndrome after “damage control”-laparotomy in 311 patients with severe abdominal and/or pelvic trauma. *Crit Care Med* 2000;28:1747–53.
- Miller PR, Meredith JW, Johnson JC, et al. Prospective evaluation of vacuum-assisted fascial closure after open abdomen. Planned ventral hernia rate is substantially reduced. *Ann Surg* 2004;239:608–16.
- Reilly P, Rotondo M, Carpenter J, et al. Temporary vascular continuity during damage control: intraluminal shunting for proximal superior mesenteric artery injury. *J Trauma* 1995;39:757–60.

33. Reber PU, Patel AG, Sapio NL, et al. Selective use of temporary intravascular shunts in coincident vascular and orthopedic upper and lower limb trauma. *J Trauma* 1999;47:72–6.
34. Ertel W, Eid K, Keel M, et al. Therapeutical strategies and outcome of polytraumatized patients with pelvic injuries – a six-year experience. *Eur J Trauma* 2000;6:14–7.
35. Ertel W, Keel M, Eid K, et al. Control of severe hemorrhage using C-clamp and pelvic packing in multiply injured patients with pelvic ring disruption. *J Orthop Trauma* 2001;15:468–74.
36. Ganz R, Krushell R, Jakob R, et al. The antishock pelvic clamp. *Clin Orthop* 1991;267:71–8.
37. Labler L, Keel M, Trentz O. Vacuum-assisted closure (V.A.C.®) for temporary soft tissue coverage in type III open fracture of lower extremities. *Eur J Trauma* 2004;5:305–12.
38. Rosenfeld JV. Damage control neurosurgery. *Injury* 2004;35:655–60.
39. Marshall JC, Cook DJ, Christou NV, et al. Multiple organ dysfunction score: a reliable descriptor of a complex clinical outcome. *Crit Care Med* 1995;23:1638–52.

Address for Correspondence

Marius Keel, MD
Division of Trauma Surgery
University Hospital Zurich
Rämistraße 100
8091 Zürich
Switzerland
Phone (+:41/44) 255-3657, Fax -4406
e-mail: marius.keel@usz.ch