

## Novel *CACNA1A* mutation(s) associated with slow saccade velocities

Stefan Kipfer · Simon Jung · Johannes R. Lemke · Anna Kipfer-Kauer ·  
Jeremy P. Howell · Alain Kaelin-Lang · Thomas Nyffeler · Klemens Gutbrod ·  
Angela Abicht · René M. Müri

Received: 30 June 2013 / Revised: 23 August 2013 / Accepted: 6 September 2013 / Published online: 18 September 2013  
© Springer-Verlag Berlin Heidelberg 2013

**Abstract** Mutations in the voltage-gated Cav2.1 P/Q-type calcium channel (*CACNA1A*) can cause a wide spectrum of phenotypes, including the episodic ataxia type 2. Beside the growing number of descriptions of novel *CACNA1A* mutations with episodic ataxia type 2 phenotype; there are only rare reports on interictal oculomotor signs other than nystagmus. We describe a novel *CACNA1A* mutation and an unclassified *CACNA1A* in-frame variant in a Swiss family presenting as the episodic ataxia type 2 phenotype associated with reduced saccade velocity. In this case series interictal clinical examination showed only minimal neurological findings as mild limb ataxia and nystagmus, but most interestingly saccade analysis of all three affected individuals demonstrated reduced mean saccade velocity. Genetic testing of *CACNA1A* revealed a de novo frame-shift mutation (c.2691dupC/p.Thyr898Leufs\*170) in the index patient in addition to an unclassified in-frame variant (c.6657\_6659dupCCA/p.His2220dup) segregating in all

three affected individuals. The de novo frame-shift *CACNA1A* mutation and the unclassified in-frame *CACNA1A* variant were associated with the episodic ataxia type 2 phenotype and reduced mean saccade velocity, which suggests involvement of brainstem or neural pathways connecting brainstem and the cerebellum in this disease.

**Keywords** Episodic ataxia type 2 · *CACNA1* mutation · Saccadic eye movements · Nystagmus

### Introduction

The episodic ataxia type 2 (EA2) is an autosomal dominant inherited disorder usually presenting with recurrent episodes of vertigo and ataxia lasting for hours to days. Attacks may be triggered by alcohol, fever, and physical or emotional stress. Symptoms range from pure ataxia to other neurological symptoms such as migraine-like headache, fluctuating limb weakness, dystonia (e.g., torticollis), and epileptic seizures [1, 2]. Clinical onset is typically in the first two decades of life. The EA2 is caused by

**Electronic supplementary material** The online version of this article (doi:10.1007/s00415-013-7099-4) contains supplementary material, which is available to authorized users.

S. Kipfer (✉) · S. Jung · T. Nyffeler · K. Gutbrod · R. M. Müri  
Perception and Eye Movement Laboratory, Departments of  
Clinical Research and Neurology, Inselspital, Bern University  
Hospital, and University of Bern, Freiburgstrasse 10, 3010 Bern,  
Switzerland  
e-mail: s.kipfer@gmx.ch

S. Kipfer  
Department of Neurology, Kantonsspital Olten, Baslerstrasse  
150, 4600 Olten, Switzerland

J. R. Lemke  
Division of Human Genetics, Inselspital, University of Bern  
Children's Hospital, Freiburgstrasse 10, 3010 Bern, Switzerland

A. Kipfer-Kauer · J. P. Howell  
Department of Ophthalmology, Kantonsspital Luzern,  
Spitalstrasse 10, 6000 Luzern 16, Switzerland

A. Kaelin-Lang  
Department of Neurology, Movement Disorders Center,  
Inselspital, Bern University Hospital, and University of Bern,  
Freiburgstrasse 10, 3010 Bern, Switzerland

A. Abicht  
Medical Genetics Center (MGZ), Bayerstrasse 3-5, 80335  
Munich, Germany

mutations in the *CACNA1A* gene on chromosome 19p13 which encodes the pore forming  $\alpha 1$  subunit of voltage-gated Cav2.1 P/Q-type calcium channels which are predominantly expressed on cerebellar Purkinje cells [3]. The EA2 is allelic with familial hemiplegic migraine type 1 (FHM1) and CAG-repeat expansions in The *CACNA1A* cause spinocerebellar ataxia type 6 (SCA6) [4]. In addition to the clinical overlap of FHM1, SCA6 and EA2, a wide range of EA2 phenotypes have been associated with mutations in *CACNA1A*.

Different ictal and interictal neuro-ophthalmologic findings are associated with EA2 [1, 3, 5]. Patients may present with spontaneous nystagmus during an acute episode. Interictally, up to 90 % of EA2 patients show nystagmus such as gaze-evoked and downbeat nystagmus [1, 6]. Beside the growing number of descriptions of novel *CACNA1A* mutations with EA2 phenotype, there are only rare reports on interictal oculomotor signs other than nystagmus [7–10]. The current study describes a novel *CACNA1A* mutation and an unclassified in-frame variant in three members of a Swiss family presenting as EA2 phenotype with interictal reduced saccade velocity.

## Subjects and methods

Four members of a Caucasian family in Switzerland were examined in the University Hospital of Bern. Due to the typical history, we suspected EA2 in the 22-year-old female index patient, her mother and one of her two siblings. Genetic testing for *CACNA1A* mutation, clinical and neurophysiologic studies were performed after obtaining written informed consent.

### Mutation analysis

Screening of all coding areas as well as exon–intron boundaries of the *CACNA1A* gene have been performed by conventional bidirectional Sanger sequencing. Deletions and duplications have been excluded by Multiplex Ligation-dependent Probe Amplifications (MRC-Holland P279).

Detected variants were compared to a control cohort of 180 alleles sequenced similarly under equal conditions as well as 10,308 alleles from the exome variant server (<http://evs.gs.washington.edu/EVS>) comprising 7,120 alleles of European and 3,188 alleles of African ancestry.

### Phenotype analysis

For the quantification of interictal cerebellar deficit, we used the International Cooperative Ataxia Rating Scale

(ICARS) [11]. Clinical subtests included evaluation of posture and gait, kinetic functions, speech and oculomotor functions.

### Saccade analysis

Quantitative testing of saccades was performed on all three mutation carriers. Visually guided horizontal saccades were recorded binocularly with a sampling frequency of 300 Hz using the infrared-based video EyeBrain® Tracker (EBT®). After the presentation of a central fixation point for a variable duration (2,400–3,600 ms), the lateral target with an amplitude of 22° to the left or right (20 repetitions to each side) appeared for 1,000 ms. Mean and peak velocity of adducting (add) and abducting (abd) saccades were separately calculated for right (RE) and left eye (LE) and compared to a normative database (data of 63 healthy control subjects aged 18–80 years). The significance between proband and the control group was tested according to Crawford and Howell [12]. A *p* value of <0.05 was accepted as statistically significant.

## Results

### Proband 1 (index patient)

A 22-year-old woman was referred to the neuro-ophthalmologic unit in June 2011 with migraine and unusual visual symptoms. She reported a 3-year history of recurrent acute episodes with vertigo, slurred speech, ataxia, severe gait impairment and oscillopsia provoked by emotional stress or by alcohol consumption. She experienced two attacks per month at an average each lasting for several hours. The interictal clinical investigation revealed mild limb ataxia, primary position upbeat- and gaze-evoked nystagmus and saccadic smooth pursuit (see online video) corresponding to an ICARS score of 7. Suppression of the vestibulo-ocular reflex was incomplete. Interictal saccade analysis by oculography revealed a reduction of mean saccade velocity with preserved peak velocity and significant slowing of adducting saccades consistent with internuclear ophthalmoplegia (INO) (Table 1; Fig. 1 and online Figure). Compared to the control group, the reduction of mean horizontal saccade velocity was significant (*p* values: RE add < 0.001, RE abd = 0.001, LE add = 0.001, LE abd = 0.002). The EEG and EMG examination was normal without signs of epileptic activity or neuromuscular transmission failure. The MRI of the brain showed slight atrophy of the cerebellar vermis. The laboratory screening including serologic and metabolic analysis was unremarkable. Genetic testing revealed a de novo frame-shift *CACNA1A* mutation (c.2691dupC/p.Thr898Leufs\*170) located

in the loop between protein domains II and III. Additionally, we detected an unclassified in-frame variant (c.6657\_6659dupCCA/p.His2220dup). After the introduction of an acetazolamide treatment (500 mg per day) the patient experienced only three short attacks during the follow up period of 1 year.

#### Proband 2 (brother)

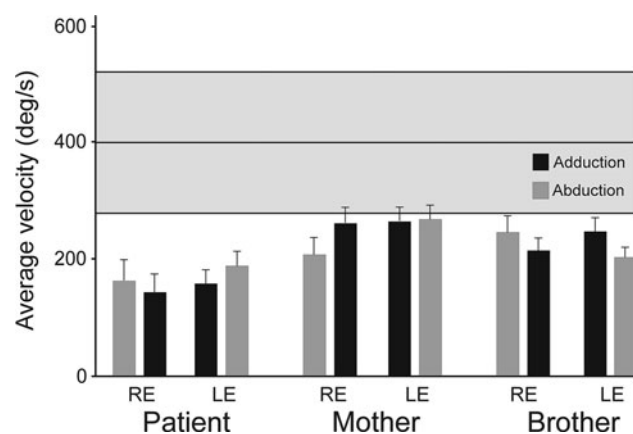
The 20-year-old brother of the index patient experienced rare and short (some minutes) lasting vertigo attacks during physical exercise. These episodes were associated with a strange feeling in the head, tingling in the mouth and unsteadiness. Nevertheless, these attacks were not

hindering sport activities. Around the age of five, his mother had observed recurrent episodes of torticollis with eye deviation. Furthermore, according to the available medical history there have been several episodes of disturbed consciousness of unknown etiology. In clinical examination, the proband showed hypometric saccades corresponding to an ICARS score of 1. Compared to the control group, the reduction of mean saccade velocity was significant ( $p$  values: RE add = 0.006, RE abd = 0.02, LE add = 0.021, LE abd = 0.004). Genetic testing revealed that the patient also carries the unclassified in-frame *CACNA1A* variant (c.6657\_6659dupCCA/p.His2220dup) but not the frame-shift mutation c.2691dupC.

**Table 1** Clinical and paraclinical EA2 proband characteristics

Proband no.	1 (patient)	2 (brother)	3 (mother)
Age (year)	22	20	55
p.Thr898Leufs*170	Y	N	N
p.His2220dup	Y	Y	Y
Clinical features			
Ataxia	Y	N	Y
Nystagmus	Y	N	N
VOR-suppression	A	I	I
Saccadic smooth pursuit	Y	N	N
Hypometric saccades	Y	Y	Y
SWJ	N	N	N
Ocular motor studies			
Slow saccade velocity	Y	Y	Y
INO	Y	N	N

NA not ascertained, Y yes, N no, I intact, A abnormal, SWJ square wave jerks, INO internuclear ophthalmoplegia, VOR vestibulo-ocular reflex



**Fig. 1** Interictal saccade analysis. Bar graphs showing mean saccade velocity (+SEM). Beside reduction of mean saccade velocity there is a more pronounced deceleration of adducting saccades (consistent with INO) in the index patient (proband 1). Gray shaded area indicating 90 %-confidence interval. RE right eye, LE left eye

#### Proband 3 (mother)

The 55-year-old mother of the index patient reported recurrent spells of disturbances in consciousness during febrile episodes in infancy. Clinical investigation revealed minor ataxia of the upper extremities and hypometric, horizontally slow saccades corresponding to an ICARS score of 6. Saccade analysis showed significantly reduced mean saccade velocities for the right eye but not for left eye analysis ( $p$  values: RE add = 0.048, RE abd = 0.007, LE add = 0.053, LE abd = 0.055). Genetic testing did not identify the frame-shift mutation but the unclassified in-frame *CACNA1A* variant (c.6657\_6659dupCCA/p.His2220dup).

#### Proband 4 (father)

The 56-year-old father of the index patient was unaffected. The clinical investigation was normal and genetic testing did neither identify the frame-shift nor the in-frame *CACNA1A* variant.

## Discussion

We describe a Swiss family presenting as EA2 phenotype with interictal reduced mean saccade velocity and the segregation of two novel *CACNA1A* variants. One of these variants is a frame-shift mutation (c.2691dupC/p.Thr898Leufs\*170) leading to a subsequent stop codon and presumably nonsense-mediated mRNA decay. Similar to other frame-shift mutations leading to EA2 the mutation c.2691dupC is predicted to cause a loss of channel function [13]. It is likely that c.2691dupC is a de novo mutation as it is not present in the parental DNA. In addition to the frame-shifting mutation c.2691dupC, the index patient carries an unclassified in-frame variant (c.6657\_6659dupCCA/p.His2220dup). Both variants were

absent in 180 control alleles and in 10,308 alleles of the exome variant server. Up to this point it remains unclear whether the de novo mutation occurred on the same allele already carrying the in-frame variant or in a compound heterozygous state. The functional impact of this histidine duplication in the C-terminus is unclear without functional studies. Interestingly, all three suspected EA2 cases of our family were found to be carriers of this variant. The segregation of p.His2220dup with an EA2 phenotype with interictal reduction of mean saccade velocity and mild ataxia in the family might point toward a pathogenic role of this variant.

The common interictal oculomotor finding in EA2 is primary position upbeat nystagmus [1, 6]. In this report we identified interictal reduction of mean saccade velocity and clinically hypometric saccades most pronounced in the index patient. An INO was additionally identified in the index patient. In the literature, general saccade slowing in EA2 was described only in three subjects of one EA2 kindred [8, 9], whereas Baloh et al. [10] found no slowing of peak saccade velocities. These prior findings and our results cannot be attributed to a pure cerebellar pathology [14]. Furthermore, the INO in the index patient is consistent with involvement of the brainstem [7]. The slowing of saccade velocity in our EA2 subjects suggests an additional disorder of neurotransmitter release of neuron subpopulations in brainstem pathways of saccades [3, 14]. It is widely accepted that specific *CACNA1A* mutations do not strictly predict EA2 phenotype, but a subtle interictal affection of saccades may be a more common early finding in EA2 probably in analogy to oculomotor findings in presymptomatic SCA6 subjects, which also show reduced saccade velocity [15]. Since approximately only one third of suspected EA2 cases could be associated with a detectable *CACNA1A* mutation [16, 17], oculography may be an additional helpful diagnostic tool, especially in cases with minimal interictal neurologic findings.

## Conclusions

The identified de novo frame-shift *CACNA1A* mutation and the unclassified in-frame *CACNA1A* variant were associated with episodic ataxia type 2 phenotype and reduced mean saccade velocity, which suggests involvement of brainstem or neural pathways connecting brainstem and cerebellum in this disease. Future studies will have to address the question whether saccade abnormalities are associated with individual genotypes or represent an early manifestation of general oculomotor dysfunction in EA2.

**Acknowledgments** The authors express their gratitude to all members of the affected family and would also like to thank Martina Gerber and Eveline Gentile of the Orthoptics unit (Inselspital Bern, Freiburgstrasse 10, 3010 Bern, Switzerland) as well as Tobia Brusa (engineer of the Perception and Eye Movement Laboratory) for their kind support.

**Conflicts of interest** None.

**Ethics committee approval** According to Swiss law, ethics committee approval is not applicable in the present study type. Patients' consents were obtained.

## References

- Riant F, Vahedi K, Tournier-Lasserre E (2011) Hereditary episodic ataxia. *Rev Neurol (Paris)* 167:401–407
- Rajakulendran S, Graves TD, Labrum RW et al (2010) Genetic and functional characterisation of the P/Q calcium channel in episodic ataxia with epilepsy. *J Physiol* 588:1905–1913
- Kullmann DM, Hanna MG (2002) Neurological disorders caused by inherited ion-channel mutations. *Lancet Neurol* 1:157–166
- Zhuchenko O, Bailey J, Bonnen P et al (1997) Autosomal dominant cerebellar ataxia (SCA6) associated with small polyglutamine expansions in the alpha 1A-voltage-dependent calcium channel. *Nat Genet* 15:62–69
- Romaniello R, Zucca C, Tonelli A et al (2010) A wide spectrum of clinical, neurophysiological and neuroradiological abnormalities in a family with a novel *CACNA1A* mutation. *J Neurol Neurosurg Psychiatry* 81:840–843
- Strupp M, Zwergal A, Brandt T (2007) Episodic ataxia type 2. *Neurotherapeutics* 4:267–273
- Rucker JC, Jen J, Stahl JS, Natesan N, Baloh RW, Leigh RJ (2005) Internuclear ophthalmoparesis in episodic ataxia type 2. *Ann N Y Acad Sci* 1039:571–574
- Subramony SH, Schott K, Raike RS et al (2003) Novel *CACNA1A* mutation causes febrile episodic ataxia with interictal cerebellar deficits. *Ann Neurol* 54:725–731
- Engel KC, Anderson JH, Gomez CM, Soechting JF (2004) Deficits in ocular and manual tracking due to episodic ataxia type 2. *Mov Disord* 19:778–787
- Baloh RW, Yue Q, Furman JM, Nelson SF (1997) Familial episodic ataxia: clinical heterogeneity in four families linked to chromosome 19p. *Ann Neurol* 41:8–16
- Trouillas P, Takayanagi T, Hallet M et al (1997) International Cooperative Ataxia Rating Scale for pharmacological assessment of the cerebellar syndrome. The Ataxia Neuropharmacology Committee of the World Federation of Neurology. *J Neurol Sci* 145:205–211
- Crawford JR, Howell DC (1998) Comparing an individual's test score against norms derived from small samples. *Clin Neuropsychol* 12:482–486
- Jen JC, Graves TD, Hess EJ et al (2007) Primary episodic ataxias: diagnosis, pathogenesis and treatment. *Brain* 130:2484–2493
- Leigh RJ, Zee DS (2006) The saccadic system. In: *The neurology of eye movement*, 4th ed. Oxford University Press, New York, pp 146–166
- Christova P, Anderson JH, Gomez CM (2008) Impaired eye movements in presymptomatic spinocerebellar ataxia type 6. *Arch Neurol* 65:530–536

16. Mantuano E, Romano S, Veneziano L et al (2010) Identification of novel and recurrent CACNA1A gene mutations in fifteen patients with episodic ataxia type 2. *J Neurol Sci* 291:30–36
17. Tomlinson SE, Hanna MG, Kullmann DM, Tan SV, Burke D (2009) Clinical neurophysiology of the episodic ataxias: insights into ion channel dysfunction in vivo. *Clin Neurophysiol* 120:1768–1776