

Cystic ameloblastoma in a 5-year-old boy

Veronika Wassermann · Thierry A. G. M. Huisman

Received: 9 November 2007 / Accepted: 26 November 2007 / Published online: 8 January 2008
© Springer-Verlag 2007

A 5-year-old boy presented with an indolent swelling of the left mandible without displacement or loosening of the teeth. A panoramic radiograph showed a large, well-defined, “bubbly”, multiloculated, lucent expansile lesion within the left posterior mandibular body and angle (Fig. 1). A contrast-enhanced CT scan showed a low-attenuation lesion with scalloping and partial resorption of the buccal and lingual mandibular cortex. The adjacent soft tissues were displaced; there was no extraosseous extension (Fig. 2). Tumor biopsy confirmed the presumed diagnosis of ameloblastoma. Resection of the left mandibular body/angle with immediate reconstruction was undertaken.

Ameloblastomas are benign epithelial neoplasms that develop from various sources of odontogenic epithelium [1, 2]; they represent 10% of all odontogenic tumors. Most ameloblastomas occur in the ramus and posterior body of the mandible (80%). They are usually seen in the third or fourth decade of life, but also occur in children. Their radiographic appearance varies. Differentiation from odontogenic keratocysts, odontogenic myxomas, aneurysmal bone cysts, and giant cell granulomas is limited [1, 2]. CT and MRI are helpful in exactly delineating and determining the extension of the lesion, but imaging is not pathognomonic [2]. Tumor biopsy remains mandatory.

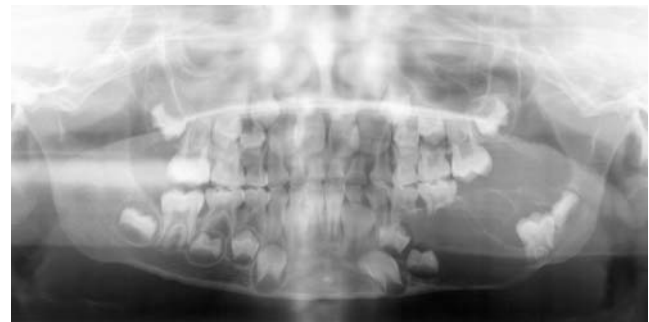


Fig. 1 Panoramic radiograph

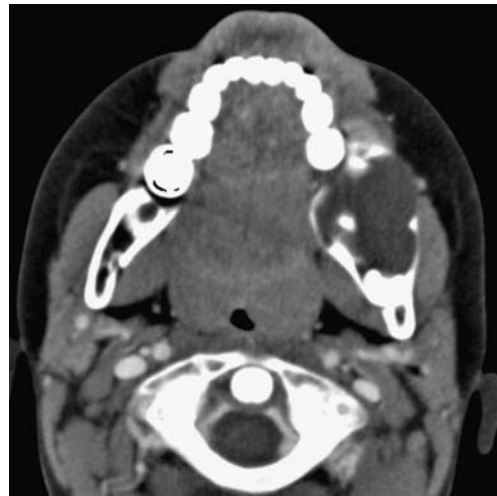

Fig. 2 Contrast-enhanced CT image

References

1. Cihangiroglu M, Akfirat M, Yildirim H (2002) CT and MRI findings of ameloblastoma in two cases. *Neuroradiology* 44:434–437
2. Asami J, Hisatomi M, Yanagi Y et al (2005) Assessment of ameloblastomas using MRI and dynamic contrast-enhanced MRI. *Eur J Radiol* 56:25–30

V. Wassermann · T. A. G. M. Huisman (✉)
Department of Diagnostic Imaging,
University Children's Hospital Zurich,
Steinwiesstrasse 75,
Zurich CH-8032, Switzerland
e-mail: thierry.huisman@kispi.unizh.ch