

Peripheral blood levels of matrix metalloproteinase-9 predict lesion volume in acute stroke

Nils H. Ulrich · T. Dehmel · H. J. Wittsack ·
B. C. Kieseier · R. J. Seitz

Received: 1 August 2011 / Accepted: 23 February 2012 / Published online: 7 March 2012
© Springer-Verlag 2012

Abstract Matrix metalloproteinases (MMPs) have been implicated to play an important role in the destruction of the extracellular matrix in diseases of the central nervous system. This study investigated whether the expression of one of these proteases, MMP-9 in blood, is related to the size of human brain infarcts assessed with magnetic resonance imaging. Consecutively, twenty-one acute stroke patients were included prospectively into our study. In blood samples drawn within 24 h after onset, MMP-9 RNA-expression and proteolytic-activity were analyzed by quantitative polymerase chain reaction and gelatin zymography, respectively. The ischemic lesion volumes in time to peak perfusion maps and diffusion weighted imaging were measured morphometrically. RNA-expression levels of MMP-9 in peripheral blood mononuclear cells (PBMCs) correlated with the brain infarct lesion (TTP-delay 4 s, $r = -0.61$, $p = 0.007$; TTP-delay 6 s: $r = -0.58$, $p = 0.012$; DWI $r = -0.47$; $p = 0.047$). Our preliminary results demonstrate that MMP-9 RNA is upregulated in PBMCs in proportion to ischemia. These findings suggest that MMP-9 might contribute to the manifestation of ischemic brain damage. Since MMP-9 is

upregulated in acute ischemia inhibition of MMP-9 may represent a complementary treatment target in acute stroke therapy.

Keywords Stroke · Metalloproteinases · MMP-9 · Perfusion weighted imaging · Diffusion weighted imaging · Magnetic resonance imaging

Introduction

Brain ischemia activates a complex cascade of events including glutamate release, leukocyte infiltration and breakdown of the blood–brain barrier leading to vasogenic edema [1]. In experimental stroke models it was found that matrix metalloproteinases (MMPs) are involved in the destruction of the basal lamina and the extracellular matrix [1]. Furthermore, inhibition of matrix metalloproteinase-9 expression was found in experimental stroke models to reduce infarct size [2, 3]. A particular role is the closure of the blood–brain barrier by matrix metalloproteinase inhibition which reduces rtPA-mediated mortality in cerebral ischemia with delayed reperfusion [4, 5].

In this present study, we explored the expression of MMP-9 in relation to the volume of ischemia as assessed in perfusion imaging and the volume of the infarct lesion as assessed in diffusion weighted imaging (DWI) in acute stroke patients. In previous magnetic resonance imaging (MRI) studies we have shown that abnormalities in time-to-peak (TTP) maps of brain perfusion and in DWI in acute stroke provide reliable means to assess the volume of ischemic brain damage in acute stroke [6, 7].

In this study, we used the volume of ischemia as found in TTP maps and the volume of ischemic tissue damage as found in DWI maps related to the expression of MMP-9

N. H. Ulrich (✉)
Department of Neurosurgery, University Hospital Zurich,
Frauenklinikstrasse 10, 8091 Zurich, Switzerland
e-mail: nils.ulrich@usz.ch

N. H. Ulrich · T. Dehmel · B. C. Kieseier · R. J. Seitz
Department of Neurology, University Hospital Dusseldorf,
Dusseldorf, Germany

H. J. Wittsack
Institute of Diagnostic Radiology, University Hospital
Dusseldorf, Dusseldorf, Germany

measured with quantitative polymerase chain reaction and gelatin zymography in peripheral blood.

Materials and methods

Study population and clinical protocol

Consecutively, twenty-one acute stroke patients aged 62.7 ± 14.3 years, 11 males and 10 females were included into the study. They were moderately affected as assessed with the NIH stroke scale, 6.3 ± 5.2 points, and received multimodal MRI within 4.6 ± 1.9 h after stroke onset. All patients received complete stroke-imaging including magnetic resonance imaging (MRI), diffusion weighted imaging (DWI), perfusion weighted imaging (PWI), and magnetic resonance angiography (MRA). Eight patients reached the hospital within 6 h to qualify for systemic thrombolysis therapy, three did not reach the hospital in time, and the other 10 did not required thrombolysis therapy. All patient characteristics can be revised in Tables 1 and 2. Venous blood samples were taken 17.5 ± 5.7 h after stroke onset. All patients gave informed consent.

Table 1 Summary of data of the study population

Patient no.	Age/sex	Baseline NIHSS	Blood sampling after onset (h)	Thrombolysis (Y/N)
1. (P.H.)	71/M	4	22	N
2. (G.G.)	64/M	10	21	Y
3. (A.M.)	65/M	4	23	N
4. (R.K.)	61/F	2	11	N
5. (V.R.)	62/F	4	16	N
6. (H.T.)	34/F	2	8	Y
7. (H.W.)	64/M	10	11	N
8. (F.A.)	69/F	10	20	Y
9. (W.W.)	57/M	2	14	N
10. (S.M.)	85/F	11	9	Y
11. (M.A.)	78/F	3	23	N
12. (R.W.)	79/M	4	22	Y
13. (K.M.)	73/F	13	23	N
14. (Ö.P.)	63/F	3	18	N
15. (B.V.)	43/F	0	23	N
16. (S.R.)	41/F	4	22	N
17. (W.K.)	58/M	4	9	Y
18. (W.J.)	58/F	16	20	Y
19. (K.H.)	69/M	11	21	Y
20. (L.I.)	62/F	8	18	N
21. (P.B.)	36/F	3	22	N

M male, *F* female, *NIHSS* National Institutes of Health Stroke Scale, *Y* yes, *N* no, *h* hours

Table 2 Characteristics of the study population

Age, years (SD)	62.7 ± 14.3
Sex (M), No. (%)	11 (52.4)
Hypertension, No (%)	14 (66.6)
Smoker, No. (%)	14 (66.7)
Diabetics, No. (%)	5 (23.8)
Hypercholesterolemia, No. (%)	8 (42.8)
Coronary disease, No. (%)	5 (23.8)
Previous strokes, No. (%)	9 (42.9)
NIHSS, points (SD)	6.3 ± 5.2

y years, *SD* standard deviation, *M* male, *NIHSS* National Institutes of Health Stroke Scale

MRI protocol

The MRI was performed with a 1.5-T whole-body imaging system (Siemens Magnetom Vision, Siemens Medical Systems, Germany). TTP parametric maps and DWI maps were calculated using in-house written software STROKETOOL[®].

Lesion volumetry on perfusion/diffusion-weighted MR images

The abnormalities of TTP and DWI were measured using volumetric analysis in relation to reference of the contralateral non-affected hemisphere in each patient as described previously [7]. We used a time delay of 6 s after bolus arrival relative to the unaffected contralateral hemisphere to assess the subsequent infarct lesion [6, 7]. A TTP delay of 4 s estimated the critically ischemic brain tissue that could be salvaged by early reperfusion [6, 7]. A threshold of 20 percent relative to the non-affected hemisphere was used for assessing the DWI lesion [6, 7].

MMP-9 zymography and quantitative PCR

Proteolytic activity of MMP-9 in peripheral blood mononuclear cells (PBMCs) was assayed by gelatin zymography [8]. To study MMP-9 mRNA-expression we used a semi-quantitative PCR (qPCR) and applied the SYBR Green Method (SYBR Green Master Mix, Applied Biosystems, Darmstadt, Germany).

Statistical analysis

Statistical analyses were performed with SPSS for windows, Version 15.0 (SPSS inc., Chicago, USA). *P* values <0.05 were considered statistically significant.

Results

The perfusion lesion volumes with a TTP-delay of 4 s were on average 33.3 ± 56.6 and 22.6 ± 40.7 ml for a TTP-delay of 6 s. Both lesion volumes correlated with the MMP-9 mRNA expression in PBMCs as assessed with the ΔCt -value (TTP-delay 4 s, $r = -0.61$; $p = 0.007$; TTP 6 s, $r = -0.58$; $p = 0.012$). ΔCt resulting from subtracting the measured Ct value of the housekeeping gene (18S), from the measured Ct value of the target gene (MMP9). As a result, the smaller the delta Ct value, the higher the expression of the target gene. This is illustrated in Fig. 1. The DWI lesion volumes were on average 7.6 ± 15.4 ml showing a slight correlation with the ΔCt -value of mRNA expression (Fig. 1c, $r = -0.47$; $p = 0.047$). There was no correlation of the lesion volumes with the proteolytic MMP-9 activity in PBMCs as assessed with zymography. There was no significant differences between thrombolysed patients and not-thrombolysed patients either in the MMP-9 mRNA expression ($p = 0.766$) or in the proteolytic MMP-9 activity ($p = 0.111$).

Discussion

Our preliminary findings have shown that MMP-9 RNA-expression in PBMCs correlated significantly with the lesion volume in acute cerebral stroke as assessed by MRI. Specifically, our findings show that the perfusion deficit correlated with MMP-9 expression in qPCR and this correlation was stronger than that with the DWI changes. These data support previous findings that revealed high MMP-9 levels in peripheral blood samples after ischemic stroke in humans indicating poor neurological outcome and hemorrhagic transformation after thrombolytic therapy [5]. Still, it is difficult to suggest that the MMP-9 RNA may represent a good biomarker for the severity of acute brain ischemia since our study is exploratory and we do not present any data on sensitivity or specificity.

Cerebral ischemia can be assessed non-invasively even within minutes after stroke onset using perfusion MRI. In acute stroke the perfusion deficit can be determined using time-to-peak (TTP) maps, which show the delay of the arrival of gadolinium in the brain after intravenous application as compared with the contralesional non-affected cerebral hemisphere [6, 7]. The tissue volume with a TTP-delay of 4 s was shown to have the highest correlation with the neurological deficit, while the tissue volume with a TTP-delay of 6-s images signifies the remaining infarct lesion [6, 7]. In fact, in early MRI within 3 h after stroke onset DWI lesions were not fully developed [7]. Thus, our findings suggest that the RNA-expression of MMP-9 signified the severity of ischemia rather than the manifest

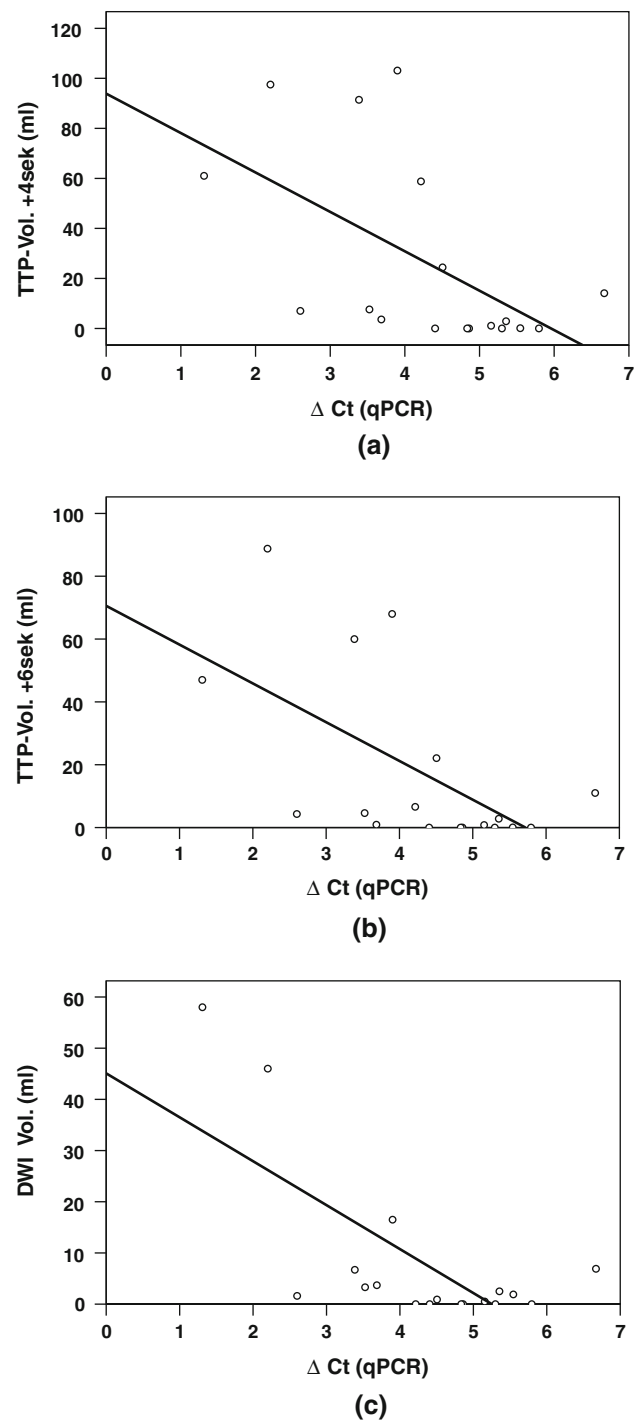


Fig. 1 Relation of MRI lesion volumes and MMP-9 expression. **a** Relation of TTP-delay 4 s and ΔCt ($r = -0.61$; $p = 0.007$). **b** Relation of TTP-delay 6 s and ΔCt ($r = -0.58$; $p = 0.012$). **c** Relation of DWI and ΔCt ($r = -0.47$; $p = 0.047$)

infarct volume. This was surprising, since the blood samples were taken only hours after stroke onset (<24 h) contradicting an early immunological reaction in the acute phase of stroke. Also, PBMCs represent 60–75% of all

circulating leukocytes and are known to account for the majority of fast MMP-9 pro-enzyme release into blood [9]. In fact, animal studies have shown that the expression of MMP-9 is responsible for the extent of the brain infarct [3, 10]. It is possible that this discrepancy was due to eight patients treated successfully with systemic thrombolysis in our group. But this may also reflect that proteolytic activity of MMP-9 in zymography did not show a relation with the lesions volumes. Nevertheless, as thrombolytic therapy was reported to activate MMP-9, complementary therapy by antagonizing MMP-9 may be beneficial in acute stroke patients [2, 11–13]. In fact, specific antagonists have been applied to inhibit the expression of MMP-9 and found to counteract the development of the infarct in a stroke model [4]. Thus, we would like to speculate that inhibition of MMP-9 might be a promising additional approach for salvaging brain tissue threatened by acute severe ischemia.

References

- Rosenberg GA, Navratil M, Barone F, Feuerstein G (1996) Proteolytic cascade enzymes increase in focal cerebral ischemia in rat. *J Cereb Blood Flow Metab* 16(3):360–366
- Horstmann S, Kalb P, Koziol J, Gardner H, Wagner S (2003) Profiles of matrix metalloproteinases, their inhibitors, and laminin in stroke patients: influence of different therapies. *Stroke* 34(9):2165–2170
- Romanic AM, White RF, Arleth AJ, Ohlstein EH, Barone FC (1998) Matrix metalloproteinase expression increases after cerebral focal ischemia in rats: inhibition of matrix metalloproteinase-9 reduces infarct size. *Stroke* 29(5):1020–1030
- Asahi M, Asahi K, Jung JC, del Zoppo GJ, Fini ME, Lo EH (2000) Role for matrix metalloproteinase 9 after focal cerebral ischemia: effects of gene knockout and enzyme inhibition with BB-94. *J Cereb Blood Flow Metab* 20(12):1681–1689
- Montaner J, Molina CA, Monasterio J, Abilleira S, Arenillas JF, Ribo M et al (2003) Matrix metalloproteinase-9 pretreatment level predicts intracranial hemorrhagic complications after thrombolysis in human stroke. *Circulation* 107(4):598–603
- Neumann-Haefelin T, Wittsack HJ, Wenserski F, Siebler M, Seitz RJ, Modder U et al (1999) Diffusion- and perfusion-weighted MRI. The DWI/PWI mismatch region in acute stroke. *Stroke* 30(8):1591–1597
- Wittsack HJ, Ritzl A, Fink GR, Wenserski F, Siebler M, Seitz RJ et al (2002) MR imaging in acute stroke: diffusion-weighted and perfusion imaging parameters for predicting infarct size. *Radiology* 222(2):397–403
- Heussen C, Dowdle EB (1980) Electrophoretic analysis of plasminogen activators in polyacrylamide gels containing sodium dodecyl sulfate and copolymerized substrates. *Anal Biochem* 102(1):196–202
- Parks WC, Wilson CL, Lopez-Boado YS (2004) Matrix metalloproteinases as modulators of inflammation and innate immunity. *Nat Rev Immunol* 4(8):617–629
- Planas AM, Sole S, Justicia C, Farre ER (2000) Estimation of gelatinase content in rat brain: effect of focal ischemia. *Biochem Biophys Res Commun* 278(3):803–807
- Pfefferkorn T, Rosenberg GA (2003) Closure of the blood-brain barrier by matrix metalloproteinase inhibition reduces rtPA-mediated mortality in cerebral ischemia with delayed reperfusion. *Stroke* 34(8):2025–2030
- Wang X, Tsuji K, Lee SR, Ning M, Furie KL, Buchan AM et al (2004) Mechanisms of hemorrhagic transformation after tissue plasminogen activator reperfusion therapy for ischemic stroke. *Stroke* 35(11 Suppl 1):2726–2730
- Tsuji K, Aoki T, Tejima E, Arai K, Lee SR, Atochin DN et al (2005) Tissue plasminogen activator promotes matrix metalloproteinase-9 upregulation after focal cerebral ischemia. *Stroke* 36(9):1954–1959