

# Endovascular Treatment of Anterior Circulation Cerebral Aneurysms by Using Guglielmi Detachable Coils

## A 10-Year Single-Center Experience with Special Emphasis on the Use of Three-Dimensional GDC

Jana Wolynski<sup>1,2</sup>, Pasquale Mordasini<sup>1,2</sup>, Gerhard Schroth<sup>1</sup>, Alain Barth<sup>2</sup>, Rolf W. Seiler<sup>2</sup>, Luca Remonda<sup>1</sup>

### Abstract

**Purpose:** To analyze the immediate, long-term angiographic and clinical results of endovascular treatment of anterior circulation aneurysms with special regard to the use of three-dimensional Guglielmi detachable coils (3D-GDC).

**Patients and Methods:** Between 1993 and 2003, 116 patients with 116 anterior circulation aneurysms were treated. 88 patients (75.9%) underwent embolization due to high surgical risk. To analyze the use of 3D-GDC, patients treated before (group 1) and after (group 2) implementation of 3D-GDC in 1999 were compared. Mean duration of angiographic follow-up was 13.9 months. Clinical follow-up was set at hospital discharge and using a questionnaire for long-term follow-up (mean 46.8 months).

**Results:** Overall, at initial intervention, complete occlusion was achieved in 65 aneurysms (56.0%), neck remnant in 42 (36.2%), and incomplete occlusion in nine (7.8%). Procedure-related permanent morbidity was 4.3% and mortality 2.6%. Recanalization rate at radiologic follow-up was 16.7%. Occlusion success at initial treatment correlated with aneurysm neck size ( $p = 0.001$ ). Clinical outcome at hospital discharge was dependent on Hunt & Hess grade at presentation ( $p = 0.01$ ). Subgroup analysis revealed that the use of 3D-GDC produced a higher initial obliteration rate compared to standard coils, but did not reach statistical significance ( $p = 0.059$ ). Neither aneurysm neck size nor aneurysm dome size nor the use of 3D-GDC significantly influenced recanalization rate.

**Conclusion:** GDC technology is effective and safe, particularly in case of patients with high surgical risk. Aneurysm neck size was predictive of occlusion rate and Hunt & Hess grade of clinical outcome. Introduction of 3D-GDC probably improved occlusion rate, but did not significantly influence recanalization rate.

**Key Words:** Guglielmi detachable coils · Three-dimensional GDC · Cerebral aneurysms · Endovascular treatment · Subarachnoid hemorrhage

Clin Neuroradiol 2007;17:98–107

DOI 10.1007/s00062-007-7010-8

### Endovaskuläre Therapie zerebraler Aneurysmen durch dreidimensionale Guglielmi-detachable-Coils

#### Zusammenfassung

**Ziel:** Die Autoren analysierten retrospektiv den Kurzzeit- sowie den Langzeitverlauf der klinischen und angiographischen Ergebnisse der endovaskulären Behandlung zerebraler Aneurysmen der anterioren Strombahn. Speziell wurden der Nutzen und der Einfluss der dreidimensionalen Guglielmi-detachable-Coils (3D-GDC) verglichen mit der ausschließlichen Anwendung von Standard-Coils untersucht.

**Patienten und Methodik:** Zwischen 1993 und 2003 wurden 116 Patienten mit Aneurysmen des anterioren Stromgebietes mittels endovaskulärer Coil-Einlage behandelt. Davon wurden 88 Patienten (75,9%) aufgrund eines hohen chirurgischen

<sup>1</sup>Department of Neuroradiology, University Hospital of Bern, Switzerland,

<sup>2</sup>Department of Neurosurgery, University Hospital of Bern, Switzerland.

Received: August 28, 2006; revision accepted: March 18, 2007

Risikos endovaskulär behandelt. Um den Nutzen der 3D-GDC zu untersuchen, wurden die Patienten retrospektiv in zwei Gruppen eingeteilt: Gruppe 1 schloss Patienten ein, welche ausschließlich mit Standard-Coils behandelt wurden, Gruppe 2 Patienten mit 3D-GDC. Die durchschnittliche angiographische Nachkontrollzeit betrug 13,9 Monate. Die Patienten wurden bei Entlassung sowie nach einer durchschnittlichen Nachkontrollzeit von 46,8 Monaten klinisch beurteilt.

**Ergebnisse:** Insgesamt konnte eine komplette Ausschaltung in 65 Aneurysmen (56,0%) erreicht werden, ein restperfundierter Aneurysmahals blieb in 42 Fällen (36,2%) bestehen, und eine unvollständige Ausschaltung mit Restperfusion des Aneurysmalumens wurde bei neun Aneurysmen (7,8%) festgestellt. Die behandlungsspezifische Morbiditätsrate lag bei 4,3%, die Mortalitätsrate bei 2,6%. Eine Rekanalisierung bestand in 16,7% der Fälle zum Zeitpunkt der letzten radiologischen Nachkontrolle. Die Verschlussrate nach der initialen Behandlung korrelierte statistisch mit der Größe des Aneurysmahalses ( $p = 0,001$ ). Der klinische Zustand bei Entlassung aus dem Krankenhaus korrelierte mit dem Hunt-&-Hess-Grad bei Aufnahme ( $p = 0,01$ ). Die Analyse der Subgruppen zeigte, dass die Anwendung von 3D-GDC zu einer höheren Verschlussrate der Aneurysmen führte als die alleinige Anwendung von Standard-Coils. Dieser Unterschied war jedoch statistisch nicht signifikant ( $p = 0,059$ ). Weder die Größe des Aneurysmahalses noch der Aneurysmadurchmesser oder die Anwendung von 3D-GDC beeinflussten die Rekanalisierungsrate der Aneurysmen.

**Schlussfolgerung:** Die endovaskuläre Coil-Behandlung kann effektiv und sicher angewendet werden, speziell bei Patienten, welche ein hohes chirurgisches Risiko aufweisen. Die Halsgröße des Aneurysmas war für die Verschlussrate und der Hunt-&-Hess-Grad für den klinischen Verlauf signifikant. Die Einführung der 3D-GDC beeinflusste zwar die initiale Verschlussrate, jedoch nicht signifikant die Rekanalisierungsrate der Aneurysmen.

**Schlüsselwörter:** Guglielmi-detachable-Coils · Dreidimensionale GDC · Zerebrale Aneurysmen · Endovaskuläre Behandlung · Subarachnoidalblutung

## Introduction

The endovascular treatment of intracranial cerebral aneurysms with Guglielmi detachable coils (GDC) is well established and used in many institutions as a primary treatment modality. Numerous studies have demonstrated the safety and efficiency of this technique in treating ruptured and unruptured cerebral aneurysms [1–5]. Clinical and radiologic follow-up studies are essential to ascertain the long-term effect of endovascular treatment in respect to permanent occlusion and prevention of rebleeding [2, 6, 7].

Endovascular treatment of intracranial aneurysms has made remarkable progress over the last 10 years in terms of several technical developments of evolving coil technology, introduction of adjuvant devices, like intracranial stents, the TriSpan neck-bridge and balloon remodeling technique. However, the use of these new technical developments has to be evaluated further. The introduction of three-dimensional GDC (3D-GDC) made the treatment of intracranial aneurysms with an unfavorable geometry possible, with or without the need for adjunctive techniques as compared with conventional standard GDC [8, 9].

The purpose of this study was to evaluate retrospectively our 10-year GDC technology experience in endovascular treatment of anterior circulation cerebral aneurysms, its immediate and long-term efficacy as well

as analysis of the factors predictive of anatomic and clinical outcome. Secondly, we investigated the treatment efficacy before and after the introduction of 3D-GDC in 1999 at our institution.

## Patients and Methods

### Patient Population

We retrospectively reviewed the medical records and angiograms of 116 consecutive patients with 116 anterior circulation aneurysms who underwent endovascular treatment between March 1993 and January 2004 at our institution. The patients were selected for endovascular treatment after assessment by the referring neurosurgeons and the interventional neuroradiologists. The majority of lesions (75.9%) were selected for endovascular treatment because of increased risk of surgical procedure (poor neurologic grade, poor medical status, old age, anatomic difficulties or anticoagulation treatment) or after failed neurosurgical interventions.

In the sample, there were 76 women (65.5%) and 40 men (34.5%) with a mean age of 57.4 years (range: 28–84 years). 18 aneurysms (15.5%) were unruptured, eight were asymptomatic, and eight symptomatic due to a mass effect. In two cases patients suffered from SAH secondary to the rupture of another aneurysm. Initial clinical grading was performed according to the Hunt & Hess grading scale [10]. Bleeding on the CT scan was

quantified by using the Fisher scale [11]. Patient data and characteristics at admission are shown in Table 1.

### Procedure

14 patients, mostly treated before 2000, underwent the embolization procedure under local anesthesia and conscious sedation. All the other patients received general anesthesia. No systemic anticoagulation with heparin was administered during the intervention. We only used local flushing with heparin through the introduced catheter during the intervention. The femoral approach was used and carotid artery angiography was performed with nonionic contrast medium (Iopamiro® 300 Bracco, Milano, Italy) in order to define the optimal projection for the best definition of the aneurysm neck and its relationships with the parent vessel and adjacent arterial branches. Depending on the size of the aneurysm targeted for treatment, usually a Fast-Traker®-18 or -10, more recently an Excel®-14-microcatheter (Boston Scientific/Target, Natick, MA, USA) were used. The microcatheter was placed coaxially through a 6-F guide catheter (Envoy®, Cordis Neurovascular, Miami, FL, USA; or Guider®, Boston Scientific/Target). With the assistance of magnified flu-

oroscopy and digital biplane road mapping, the microcatheter was navigated into aneurysms with the aid of a 0.010- or 0.014-inch guide wire (Fas-Dasher®, Boston Scientific/Target or Silver Speed®, Micro Therapeutics, Irvine, CA, USA).

During our 10-year experience, advances have occurred in GDCs technology, and all of the currently available GDCs' have been used at various times over that time period (Standard/Soft/SR/Ultrasoft). Large and incidental aneurysms were typically treated using coils with a diameter of 0.0018 inch (GDC-18) whereas GDC-10s were mostly used in acute and small aneurysms.

TriSpan® and 3D-GDCs were introduced in 1999 for wide-necked aneurysms. In large or wide-necked aneurysms (15 cases) 3D-GDC-18s were used. In smaller and narrow-necked aneurysms 3D-GDC-10s were applied (45 cases). With one exception, it was our practice to introduce only one 3D-GDC in each of the treated aneurysms. In two patients with a wide-necked aneurysm a Neuroform®-stent (Boston Scientific/Target) was also used. In these cases we used anticoagulation with aspirin 500 mg i.v. during the procedure. Postinterventionally, the patients were treated with aspirin 100 mg and clopidogrel 75 mg. At our institution we did not use the remodeling technique until 2003.

The GDCs were delivered using biplane road mapping and the procedure was considered terminated when a solid cast of the aneurysm was achieved, when control angiography confirmed devascularization of the lumen of the aneurysm, or when herniation of the last GDC into the parent artery was observed. In older patients with aneurysms and unfavorable anatomy or in patients with poor neurologic condition, the procedure was sometimes discontinued when the dome as the most probable site of rupture was occluded in spite of visible neck remnant. After embolization the patients were transferred to the neurosurgical intensive care unit.

### Angiographic Analysis

The diagnostic, procedural, and follow-up angiograms were reviewed by experienced neuroradiologists. Based on angiographic data obtained at the time of embolization, the aneurysms were classified by their size and neck width. The size of aneurysms was measured according to their longest axis on selective angiograms. 59 aneurysms (50.9%) were read as small (< 7 mm), 45 (38.8%) as intermediate (7–12 mm), nine (7.8%) were classified as large (12–25 mm) and three (2.6%) aneurysms were labeled as giant (> 25 mm). 88 aneurysms (75.9%) had

**Table 1.** Patient data and characteristics.

Characteristics	n (%)
Sex	
• Male	40 (34.5)
• Female	76 (65.5)
Age (years)	
• Mean	57.4
• Range	28–84
Hunt & Hess grade at admission	
• 0 (not ruptured)	18 (15.5)
• I	14 (12.1)
• II	27 (33.3)
• III	23 (19.8)
• IV	17 (14.7)
• V	17 (14.7)
Fisher grade at admission (n = 86)	
• 0 (not ruptured)	14 (16.3)
• 1	7 (8.1)
• 2	3 (3.5)
• 3	20 (25.6)
• 4	42 (48.8)
Clinical follow-up (months)	
• Mean	46.8
• Range	3.3–130.5
Angiographic follow-up (months)	
• Mean	13.9
• Range	1.8–52

narrow necks ( $\leq 4$  mm), and 28 (24.1%) had wide necks ( $> 4$  mm). Fusiform aneurysms were excluded from the study.

Approximately one half of the aneurysms (60 aneurysms, 51.7%) were located at the anterior communicating artery. The next most common location was the carotid ophthalmic/paraclinoid segment (22 aneurysms, 19.0%). The distribution of aneurysms by location is shown in Table 2.

The aneurysm occlusion rate was estimated from the ratio of the occluded aneurysm area to the area of the initial aneurysm. An embolization was considered to be complete when dome, body or neck of the aneurysm were no longer filled with contrast. The term “neck remnants” referred to lesions with residual filling of a part of an aneurysm’s neck, and “incomplete occlusion” was defined by the contrast agent in the body and dome of the aneurysm. Two cases of failed GDC treatment were excluded from the study.

The first angiographic follow-up was obtained 6 months post embolization and in the course of time using DSA or MRA with ultrashort echo times [12]. The mean angiographic follow-up was 13.9 months (range: 3.3–130.5 months). In cases of stable angiographic findings within the 1st year after treatment, usually no further angiographic follow-ups were required. 38 patients (36.5% of survived group) were lost to radiologic follow-up, mostly because of poor medical status or advanced age. The changes observed on follow-up angiograms were classified as unchanged (defined by a similar degree of aneurysm occlusion, and recanalization) or increased (when the amount of contrast material filling the aneurysm or the latest follow-up angiogram was greater when compared with the immediate posttreatment angiographic results.) Improvement on the follow-up was defined as an improvement in one

outcome category (for example, from a residual neck to complete occlusion).

### Clinical Outcome Measures

Clinical condition at the time of treatment was determined with the Hunt & Hess grading scheme [10] and the World Federation of Neurologic Surgeons (WFNS) clinical grading scale [13]. Clinical outcome was assessed at hospital discharge using the Glasgow Outcome Scale (GOS) [14]. To determine the long-term clinical outcome, a questionnaire was used which allowed the calculation of the GOS based on the given answers.

### Statistical Analysis

Hunt & Hess grade, WFNS, GOS, Fisher score, aneurysm sac size and aneurysm neck size were analyzed for correlation with outcome endpoints using the  $\chi^2$ -test. Pearson’s correlations were used to detect correlations among all normally distributed variables, Spearman’s  $\rho$  were used for ordinal-scaled or not normally distributed variables. The rate of significance was considered at  $p < 0.05$  for a two-tailed hypothesis, if not otherwise specified in the text. Statistical tests were used with an explorative intention, and no  $\alpha$ -correction was performed.

## Results

### Immediate Angiographic Outcome

In the case of 116 aneurysms coil deployment could be successfully performed. In one patient the coil deployment was not possible because of the wide aneurysm neck. In another case, the procedure was interrupted because of coil dislocation. Both patients underwent microsurgical clipping and were excluded from the study.

In 65 aneurysms (56.0%), complete occlusion could be achieved, a neck remnant was found in 42 aneurysms (36.2%) and incomplete occlusion remained in nine (7.8%). 37 (62.7%) of the small aneurysms ( $< 7$  mm) could be completely obliterated, 17 (28.8%) remained with a neck remnant, and five (8.5%) were incompletely occluded. In the group of intermediate aneurysms (7–12 mm) a complete occlusion was observed in 22 aneurysms (48.9%), a neck remnant in 22 (48.9%), and in one (2.2%), only the dome could be obliterated. Five (55.6%) of nine large aneurysms (12–25 mm) showed complete occlusion, one (11.1%) a neck remnant, and three (33.3%) an incomplete occlusion. One (33.3%) of three giant aneurysms could be completely embolized, the other two (66.7%) showed neck remnants. The im-

**Table 2.** Aneurysm locations.

Location	Number of aneurysms	%
Anterior communicating artery	60	51.7
Posterior communicating artery	10	8.6
Paraclinoid internal carotid artery	22	19.0
Ophthalmic artery	2	1.7
Anterior cerebral artery	3	2.6
Middle cerebral artery	12	10.3
Pericallosal artery	6	5.2
Anterior choroidal artery	1	0.9
Total of aneurysms	116	100

mediate angiographic outcome sorted by aneurysm size is summarized in Table 3.

The aneurysm size showed no significant correlation with the initial occlusion rate. 57 (64.8%) of the narrow-necked aneurysms ( $\leq 4$  mm) were completely occluded, 26 (29.5%) had a neck remnant, and in five (5.6%), only the dome was occluded. Eight (28.6%) of the wide-necked ( $> 4$  mm) aneurysms showed complete occlusion, 16 (57.1%) had a neck remnant, and four (14.3%) incomplete occlusion (Figure 1). A significant correlation ( $p = 0.001$ ) was found between the initial occlusion rate and the aneurysm neck size.

### Long-Term Angiographic Outcome

Angiographic outcome was evaluated in 66 out of 116 patients (56.9%). 38 patients (36.5% of surviving patients) were lost to radiologic follow-up, mostly because of poor medical status or advanced age. Overall recanalization was observed in 16.7% of the aneurysms (11/66), while 83.3% of the aneurysms (55/66) remained intact.

Recanalization was detected in 11.8% of the small aneurysms (4/30), 16.7% of the intermediate aneurysms (4/24), and 33.3% of the large aneurysms (2/6). One (50.0%) of two treated giant aneurysms showed signs of recanalization, another (50.0%) remained stable. 13.7%

of narrow-necked (7/51) and 26.7% of wide-necked aneurysms (4/15) showed recanalization. No significant correlation between aneurysm dome or neck size and recanalization rate at latest follow-up was found.

The long-term radiologic follow-up of the aneurysms in which no complete obliteration was achieved demonstrated 29% of controlled neck remnants (9/30) becoming completely obliterated.

### Angiographic Outcome of Subset Groups

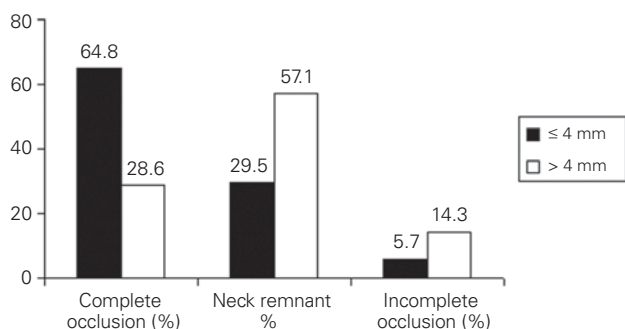
Following technical development of the GDC devices over time, we divided the treated patients for comparative purpose into two groups: group 1 which included 56 patients with 56 aneurysms mostly treated before 1999 using standard GDC alone and group 2 which included the 5-year experience gained after the introduction of 3D-GDC in 1999 with 60 patients with 60 aneurysms. Our point of interest was to analyze the impact of 3D-GDC on the occlusion and recanalization rates.

In group 1, 16 out of 28 small aneurysms (57.1%) demonstrated complete occlusion at initial treatment, eight (28.6%) had a neck remnant, and four (14.3%) were incompletely occluded. Ten (47.6%) of the intermediate aneurysms were completely occluded, ten (47.6%) showed a neck remnant, and one (4.8%) was incompletely obliterated. One (25.0%) of the four large aneurysms of the group 1 was completely embolized, another one (25.0%) showed a neck remnant, and the two (50.0%) remaining aneurysms were incompletely embolized. All three giant aneurysms were treated without help of 3D-GDC. One (33.3%) of them was completely occluded, and two (66.6%) had neck remnants (Figure 2a). Regarding to neck size, 26 aneurysms (61.9%) with narrow necks and only two aneurysms (14.3%) with wide necks could be completely occluded.

In group 2, 60 aneurysms (51.7%) were included. 21 (67.7%) of the small aneurysms were completely obliterated, nine (29.0%) had neck remnants, and one (3.2%) was incompletely occluded. Twelve (50.0%) of the intermediate aneurysms were completely occluded, another twelve (50.0%) showed neck remnants. Four of five large aneurysms (80.0%) were completely and one (20.0%) incompletely obliterated (Figure 2b). Complete obliteration could be achieved in 31 narrow-necked (67.4%) and six wide-necked aneurysms (42.9%). It was found that the use of 3D-GDC tended to affect the initial occlusion rate, but this tendency did not reach statistical significance ( $p = 0.059$ ).

**Table 3.** Initial angiographic results.

Aneurysm size	Complete n (%)	Neck remnant n (%)	Incomplete n (%)
$< 7$ mm (n = 59)	37 (62.7)	17 (28.8)	5 (8.5)
7–12 mm (n = 45)	22 (48.9)	22 (48.9)	1 (2.2)
12–25 mm (n = 9)	5 (55.6)	1 (11.1)	3 (33.3)
$> 25$ mm (n = 3)	1 (33.3)	2 (66.7)	0 (0)
Total (n = 118)	65 (56.0)	42 (36.2)	9 (7.8)



**Figure 1.** Percentage of aneurysm occlusion rate according to neck size at completion of the initial embolization.

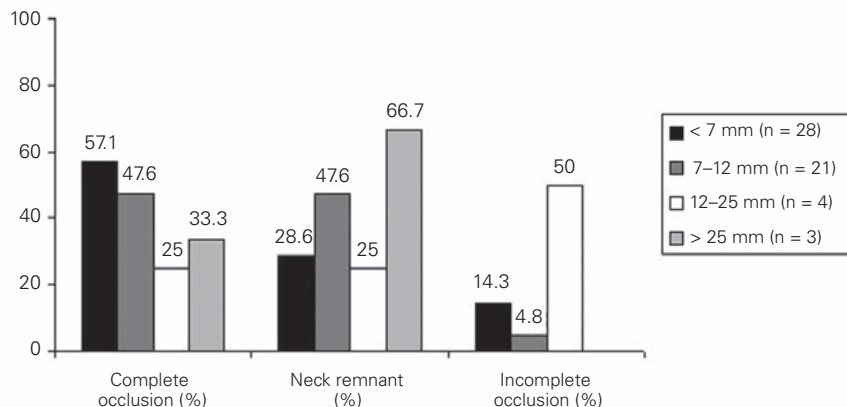
At angiographic follow-up, overall recanalization in group 1 was 22.2% (8/36). 16.7% of the small aneurysms (3/18) showed recanalization, corresponding to 21.3% of the intermediate aneurysms (3/13), 33.3% of the large (1/3) and 50.0% of the giant aneurysms (1/2). In group 2, overall recanalization rate was 10% (3/30). 6.3% of the small aneurysms (1/16), 9.1% of the intermediate aneurysms (1/11) and 33.3% of the large aneurysms (1/3) were recanalized. No statistically significant correlation between the recanalization rate and the use of 3D-GDC was found.

**Initial Clinical Outcome**

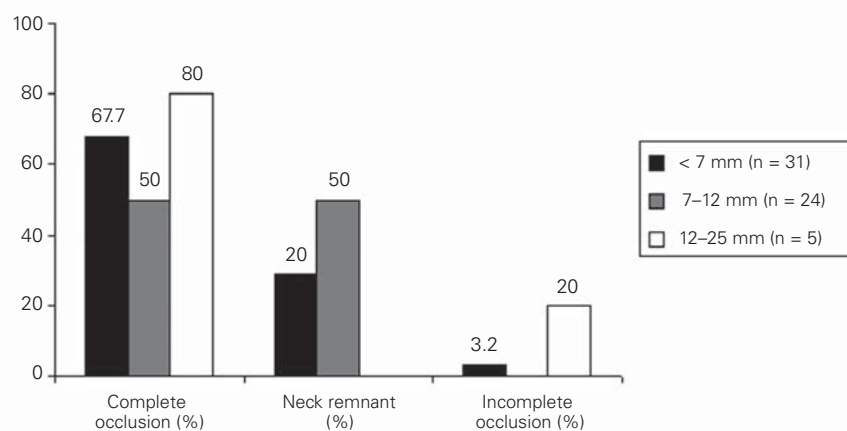
Of the 116 patients treated with the GDC system, 65 (56.0%) showed excellent and good recovery (GOS IV–V), 39 (33.6%) were severely disabled (GOS III–II), and twelve (10.4%) died (GOS I). Of the 18 patients presenting with unruptured aneurysms (Hunt & Hess grade 0), 14 (77.8%) showed a GOS V, one (5.6%) a GOS IV, and three (16.7%) a GOS II–III. Overall, 63.4% of the patients (52/82) presenting in Hunt & Hess grades 0–III achieved a GOS V or IV outcome score. Of 34 patients suffering from SAH Hunt & Hess grade IV and V, six (17.6%) died, 15 (44.2%) were dependent (GOS II and III), and 13 (38.2%) independent (GOS IV and V) at hospital discharge. The Hunt & Hess grades and GOS scores at hospital discharge are summarized in Table 4. The initial clinical outcome was significantly dependent on Hunt & Hess grade at presentation ( $p < 0.001$ ).

Other clinical parameters like hydrocephalus ( $p < 0.001$ ) or advanced age ( $p = 0.04$ ) were found to be significantly correlated with worse outcome measured by GOS score. Aneurysms of the anterior communicating artery were found to be particularly disadvantageous for

the clinical outcome ( $p = 0.03$ ). By contrast, aneurysms of the internal carotid artery showed a significant correlation with positive clinical outcome ( $p = 0.02$ ). Fisher



**Figure 2a**



**Figure 2b**

**Figures 2a and 2b.** Aneurysm morphology by group: percentage of aneurysm occlusion rate according to sac size at completion of the initial embolization in the early group before the introduction of 3D-GDC (a) and the group treated after introduction of 3D-GDC (b).

**Table 4.** Comparison of treated patients’ initial Hunt & Hess grades and GOS scores at hospital discharge.

Initial clinical outcome [n (%)]				
Hunt & Hess	Dead (GOS = 1)	Disabled (GOS = 2–3)	Good (GOS = 4)	Excellent (GOS = 5)
0 (n = 18)	0 (0)	3 (16.7)	1 (5.6)	14 (77.8)
I (n = 14)	0 (0)	2 (14.3)	3 (21.4)	9 (64.3)
II (n = 27)	3 (11.1)	9 (33.3)	1 (3.7)	14 (51.9)
III (n = 23)	3 (13.0)	10 (43.5)	2 (8.7)	8 (34.8)
IV (n = 17)	4 (23.5)	5 (29.4)	3 (17.6)	5 (29.4)
V (n = 17)	2 (11.8)	10 (58.8)	3 (17.6)	2 (11.8)
Total (n = 116)	12 (10.4)	39 (33.6)	13 (11.2)	52 (44.8)

score and size of aneurysms were not significantly correlated with clinical outcome.

### Long-Term Clinical Outcome

Long-term clinical follow-up could be achieved in 103 of 104 surviving patients (99.0%). Follow-up was performed using questionnaires in 97 patients (97%). Six patients died after clinical discharge: three patients died of consequences of the SAH and another three patients died of reasons unrelated to hemorrhage or GDC treatment (malignant tumor in two cases and cardiac insufficiency in one). In these patients the latest clinical control at our institution was used. One patient (0.9%) returned to her foreign residence and was lost to follow-up. The mean duration of clinical follow-up was 46.8 months (range: 3.3–130.5 months). 67.9% of the patients (70/103) achieved a GOS V–IV and 29.1% (30/100) showed a GOS III–II at the latest clinical follow-up. According to severity of hemorrhage, 72.2% of the patients (13/18) with unruptured aneurysms, 73.7% of the patients (42/57) with SAH Hunt & Hess grade I–III and 53.6% of the patients (15/28) with poor-grade aneurysms were independent at long-term follow-up. The detailed long-term clinical outcome according to Hunt & Hess grade is shown in Table 5.

### Procedure-Related Morbidity and Mortality

An aneurysm perforation occurred in one patient (0.9%) with an unruptured giant aneurysm of the internal carotid artery, resulting in serious permanent neurologic disability. Four patients (3.4%) had permanent neurologic deficits related to thromboembolism. The therapy for patients with thromboembolic complications included aspirin 500 mg intravenous or intraarterial thrombolysis during the intervention. After

the procedure the patients were treated with aspirin 100 mg. Coil dislocation, which was asymptomatic, occurred in one case (0.9%). Early postinterventional rebleeding of a treated aneurysm (within 5 days after treatment) occurred in three patients (2.6%), in one of whom the aneurysm was initially completely occluded and two aneurysms had neck remnants. All these three patients did not survive. There was no late rebleeding of a treated aneurysm after hospital discharge during the long-term follow-up period. Overall, a procedure-related morbidity of 4.3% and mortality of 2.6% were found.

### Retreatment/Repeated Embolization/Recoiling

In eleven patients (9.5%) a retreatment was required, nine patients underwent microsurgical clipping, and in two patients a recoiling was performed. The most frequent reason for retreatment was coil compaction (seven aneurysms). In four patients an incomplete coiling was used to prevent early rebleeding, therefore a retreatment (clipping in three cases and recoiling in one case) was performed.

### Discussion

#### Angiographic Outcome Results

In our findings, 56.0% of the aneurysms showed complete occlusion at initial treatment; a tendency to recanalize was found in 16.7% of the aneurysms at latest angiographic follow-up examination (mean 13.9 months). In the literature, initial overall complete occlusion is reported in 33–72.5% of aneurysms of the anterior and posterior circulation [4, 15]. Anterior circulation aneurysms were rarely investigated separately. Moret et al. reported about 72.5% complete occlusion rate in aneurysms of the anterior communicating artery

[15]. Recanalization rate is ranging from 14.3% to 28% within 1 year after treatment [16, 17]. Considering the differences in grading and terminology, our data are generally consistent with the findings of prior reports. The goal of many recent studies was to investigate the factors determining the success of occlusion and the cause of recurrences [7]. Small aneurysms with small necks are generally assumed to be treated completely and wide-necked aneurysms are supposed to be more vul-

**Table 5.** Comparison of treated patients' initial Hunt & Hess grades and GOS scores at long-term outcome.

Long-term clinical outcome [n (%)] Hunt & Hess	Long-term clinical outcome [n (%)]			
	Dead (GOS = 1)	Disabled (GOS = 2–3)	Good (GOS = 4)	Excellent (GOS = 5)
0 (n = 18)	0 (0)	5 (27.8)	2 (11.1)	11 (61.1)
I (n = 14)	0 (0)	2 (14.3)	3 (21.4)	9 (64.3)
II (n = 24)	1 (4.2)	6 (25.0)	4 (16.6)	13 (54.2)
III (n = 19)	1 (5.3)	5 (26.3)	3 (15.8)	10 (52.2)
IV (n = 13)	0 (0)	4 (30.8)	3 (23.0)	6 (46.2)
V (n = 15)	1 (6.7)	8 (53.3)	2 (13.4)	4 (26.6)
Total (n = 103)	3 (2.9)	30 (29.2)	17 (16.5)	53 (51.4)

nerable to recanalization [18]. In our findings, an initial occlusion success has been shown to be significantly correlated to aneurysm neck size and had a statistical trend to correlate with the aneurysmal dome size. In contrast to the findings of Raymond et al., no significant correlation between aneurysm dome/neck size and recanalization rate was observed [19].

Long-term angiographic follow-up is important to disclose modifications of the occlusion rate of the aneurysms. Retreatment due to recanalization was needed in eleven patients (9.5%; two patients underwent recoiling, nine patients clipping). There is still a concern about the length of the angiographic follow-up period [1, 6, 7, 17, 19]. Raymond et al. [19] and Murayama et al. [1] found new recanalization after > 1 year and recommended an angiographic follow-up period of at least 36 months. Sluzewski et al. concluded that if aneurysm occlusion is sufficient at 6 months, the yield of further follow-up angiography is very low [6]. In our series, all recurrences were already detected at the first radiologic control 6 months after treatment and no new or further major recurrences compared to the previous angiograms were found in the later follow-up angiograms.

#### Angiographic Outcome after the Introduction of 3D-GDC

The endovascular treatment of intracranial aneurysms using GDC has developed rapidly in the last decade in terms of microcatheter improvements, evolving coil technology (soft-coils, 3D-GDC), adjuvant devices (stents, TriSpan®, balloon protection of the neck, remodeling technique) and the positive effect of the learning curve. In order to try to quantify the effect on angiographic outcome, we divided the treated patients in two groups, before and after the introduction of 3D-GDC. 3D-GDCs were introduced in 1999 especially for wide-necked aneurysms [8, 9, 20].

Vallee et al. reported about significant improvement of coil packing and angiographic and volumic occlusion of aneurysms with a neck > 4 mm thanks to the use of 3D-GDC, provided a sac-to-neck ratio > 1.5 and the largest 3D coil was first positioned [21]. Mordasini et al. have investigated the benefit of 3D-GDCs in aneurysms of the posterior circulation and found that 3D coils facilitate initial dense packing of aneurysms > 7 mm [22]. The geometry of 3D-GDCs better fits the generally more spherical morphology of basilar tip aneurysms compared to anterior circulation aneu-

rysms and may therefore explain the denser packing of these aneurysms by using 3D-GDCs. In our findings the application of 3D-GDCs was especially effective in wide-necked and large aneurysms. The rate of initially completely occluded wide-necked aneurysms could be improved from 14.3% to 42.9%. Regarding the aneurysms > 12 mm a complete occlusion could be achieved in 80% of aneurysms (4/5) of group 2 (3D-GDC), compared to 25% (1/4) of group 1. The overall recanalization seems also to be improved using 3D-GDC (10.0% in group 2 compared to 22.2% in group 1).

#### Mortality/Morbidity

Our procedure-related mortality was 2.6% which corresponds to rates ranging from 0 to 7.8% in other series [1, 3–5, 15–17, 23, 24]. The most frequent complication which led to mortality was early rebleeding (in three cases) and one patient died in consequence of a thromboembolic event. The cause of early rebleeding (until 5 days after treatment) in sufficiently treated aneurysms (complete occlusion or small neck remnant), particularly in patients without any anticoagulation, remains unclear. In some cases rebleeding from another undetected aneurysm was suggested.

The permanent treatment-related morbidity rate of 4.3% compares with other series ranging from 1% to 9.1% [1–5, 15–17, 23, 24]. Corresponding to the reported findings, the complications due to thromboembolism were the prime reason for permanent morbidity (in four of five cases). One patient suffered from neurologic deficit due to early rebleeding. Our policy at the moment is not to use systemic anticoagulation therapy during the treatment procedure in order to achieve optimal clot formation and dense packing in the aneurysm. Our rates of thromboembolic complications are not higher than in series with systemic anticoagulation [1, 4, 5, 15, 24]. It is our policy to use aspirin 500 mg intravenous or intra-arterial thrombolysis during the intervention in cases of thromboembolic complications. After the procedure the patients were treated with aspirin 100 mg.

#### Long-Term Rebleeding

No late rebleeding was observed during the long-term follow-up (mean 3.9 years), although only 56.0% of the aneurysms could be completely obliterated. This confirms the low incidence of late rebleeding after GDC occlusion reported in other endovascular series ranging from 0 to 2.2% [4, 5, 16, 17, 25]. The International Sub-



arachnoid Aneurysm Trial (ISAT) showed a peak of rebleedings within 30 days after treatment [2]. In their presentation of the clinical outcomes 1 year after treatment, the authors of ISAT found 7/1,073 patients with rebleeding after 1 year. Our data may suggest that sufficient coiling of the dome of the aneurysm may be one of the important factors to prevent short-term and long-term rebleeding.

### Clinical Outcome Results

The overall mortality rate of patients with acute SAH in our series was 13% (15/116); half of these patients suffered from high-grade SAH (Hunt & Hess grade IV and V). Twelve lethal cases occurred at the hospital and three patients died of consequences of the hemorrhage later. Overall, 65 patients (56%) had excellent or good recovery (GOS V and IV) at hospital discharge. The reported data of clinical outcomes show noticeable variability, according to the structure of clinical presentation. Kuether et al. reported a favorable outcome in 81.6% of patients with ruptured aneurysms of the anterior circulation and an overall mortality of 15.8% [23].

Friedman et al. demonstrated in their study based on their 10-year experience a good and excellent outcome in 77% of the patients and a mortality rate of 12% [4]. In contrast to this finding, Murayama et al. in a large study of 818 patients reported about unchanged neurologic state in 90.6% and a mortality rate of 5.6% [1]. Finally, the results of the ISAT based on 1,086 endovascularly treated patients showed a good and excellent primary outcome in 74.6% and a mortality rate of 7.5% [2]. Therefore, despite the high part of poor-grade aneurysms, our findings are in line with reported data. In the long-term clinical follow-up (mean 46.8 months) we found a good and excellent outcome in 70% of the surviving patients. According to reported findings, the Hunt & Hess grade at presentation, the incidences of hydrocephalus and symptomatic vasospasm were found to be significant predictors of clinical outcome, whereas Fisher score was not. A comparison to surgical series seems to be difficult, because 37 (31.9%) of our patients underwent an additional surgical procedure either due to initially failed clipping (twelve patients), treatment of large intracranial hematoma (six patients), clipping in case of recurrences (eleven patients), or clipping of another coexisting aneurysm (five patients). In four cases GDC treatment was performed after incomplete clipping.

### Limitations of the Study

A major drawback of the study is the retrospective and nonrandomized design with a loss of 36.5% of patients to angiographic follow-up and the short lower limit for angiographic and clinical follow-up of 3.3 months. Therefore, the reported frequencies of recanalization and clinical outcomes may not be representative and may bias the results between the two treatment groups.

### Conclusion

GDC technology is an effective and safe technique for the treatment of anterior circulation aneurysms, particularly in case of patients with high surgical risk due to poor neurologic grade, poor medical status, old age, anatomic difficulties or anticoagulation treatment. Aneurysm neck size was predictive of occlusion rate, but not aneurysm size. Hunt & Hess grade was predictive of clinical outcome. The introduction of 3D-GDC in our practice tended to improve the occlusion rate, especially in larger aneurysms, but did not influence the recanalization rate. There was no late rebleeding of treated aneurysms during our mean observation time of 3.9 years.

### References

1. Murayama Y, Nien YL, Duckwiler G, Gobin YP, Jahan R, Frazee J, Martin N, Vinuela F. Guglielmi detachable coil embolization of cerebral aneurysms: 11 years' experience. *J Neurosurg* 2003;98:959-66.
2. Molyneux A, Kerr R, Stratton I, Sandercock P, Clarke M, Shrimpton J, Holman R, International Subarachnoid Aneurysm Trial (ISAT) Collaborative Group. International Subarachnoid Aneurysm Trial (ISAT) of neurosurgical clipping versus endovascular coiling in 2 143 patients with ruptured intracranial aneurysms: a randomised trial. *Lancet* 2002; 360:1267-74.
3. Raftopoulos C, Mathurin P, Boscherini D, Billa RF, Van Boven M, Hantson P. Prospective analysis of aneurysm treatment in a series of 103 consecutive patients when endovascular embolization is considered the first option. *J Neurosurg* 2000;93:175-82.
4. Friedman JA, Nichols DA, Meyer FB, Pichelmann MA, McIver JI, Toussaint LG 3rd, Axley PL, Brown RD Jr. Guglielmi detachable coil treatment of ruptured saccular cerebral aneurysms: retrospective review of a 10-year single-center experience. *AJNR Am J Neuroradiol* 2003; 24:526-33.
5. Vinuela F, Duckwiler G, Mawad M. Guglielmi detachable coil embolization of acute intracranial aneurysm: perioperative anatomical and clinical outcome in 403 patients. *J Neurosurg* 1997;86:475-82.
6. Sluzewski M, van Rooij WJ, Rinkel GJ, Wijndal D. Endovascular treatment of ruptured intracranial aneurysms with detachable coils: long-term clinical and serial angiographic results. *Radiology* 2003;227:720-4.
7. Molyneux AJ, Kerr RS, Yu LM, Clarke M, Sneade M, Yarnold JA, Sandercock P, International Subarachnoid Aneurysm Trial (ISAT) Collaborative Group. International Subarachnoid Aneurysm Trial (ISAT) of neurosurgical clipping versus endovascular coiling in 2 143 patients with ruptured intracranial aneurysms: a randomised comparison of effects on survival, dependency, seizures, rebleeding, subgroups, and aneurysm occlusion. *Lancet* 2005;366:809-17.

8. Cloft HJ, Joseph GJ, Tong FC, Goldstein JH, Dion J. Use of three-dimensional Guglielmi detachable coils in the treatment of wide-necked cerebral aneurysms. *AJNR Am J Neuroradiol* 2000;21:1312-14.
9. Malek AM, Higashida RT, Phatouros CC, Dowd CF, Halbach VV. Treatment of an intracranial aneurysm using a new three-dimensional-shape Guglielmi detachable coil: technical case report. *Neurosurgery* 1999;44:1142-5.
10. Hunt WE, Hess RM. Surgical risk as related to the time of intervention in the repair of intracranial aneurysms. *J Neurosurg* 1968;28:14-20.
11. Fisher CM, Kistler JP, Davis JM. Relation of cerebral vasospasm to subarachnoid hemorrhage visualized by computerized tomographic scanning. *Neurosurgery* 1980;6:1-9.
12. Gönner F, Heid O, Remonda L, Nicoli G, Baumgartner RW, Godoy N, Schroth G. MR angiography with ultrashort echo time in cerebral aneurysms treated with Guglielmi detachable coils. *AJNR Am J Neuroradiol* 1998;19:1324-8.
13. Drake CG. Report of World Federation of Neurological Surgeons Committee on a universal subarachnoid haemorrhage grading scale. *J Neurosurg* 1988;68:985-6.
14. Jennett B, Bond M. Assessment of outcome after severe brain damage. *Lancet* 1975;1:480-4.
15. Moret J, Pierot L, Boulin A, Castaings L, Rey A. Endovascular treatment of anterior communicating artery aneurysms using Guglielmi detachable coils. *Neuroradiology* 1996;38:800-5.
16. Darwish B, Rajak S, Wickremesekera A, Hunn M, Balakrishnan V, Braithwaite D, FitzJohn T. Clinical and angiographic outcome after Guglielmi detachable coil embolization of intracranial aneurysms. *Aust N Z J Surg* 2003;73:717-21.
17. Ng P, Khangure M, Phatouros CC, Bynevelt M, Apsimon H, McAuliffe W. Endovascular treatment of intracranial aneurysms with Guglielmi detachable coils: analysis of midterm angiographic and clinical outcome. *Stroke* 2002;33:210-7.
18. Zubillaga F, Guglielmi G, Vinuela F, Duckwiler G. Endovascular occlusion of intracranial aneurysms with electrically detachable coils: correlation of aneurysm neck size and treatment results. *AJNR Am J Neuroradiol* 1994;15:815-20.
19. Raymond J, Guilbert F, Weill A, Georganos SA, Juravsky L, Lambert A, Lamoureux J, Chagnon M, Roy D. Long-term angiographic recurrences after selective endovascular treatment of aneurysms with detachable coils. *Stroke* 2003;34:1398-403.
20. Guglielmi G. Treatment of an intracranial aneurysm using a new three-dimensional-shape Guglielmi detachable coil: technical case report. *Neurosurgery* 1999;45:959-61.
21. Vallee JN, Pierot L, Bonafe A, Turjman F, Flandroy P, Berge J, Rodesch G, Bracard S. Endovascular treatment of intracranial wide-necked aneurysms using three-dimensional coils: predictors of immediate anatomic and clinical results. *AJNR Am J Neuroradiol* 2004; 25:298-306.
22. Mordasini P, Schroth G, Guzman R, Barth A, Seiler RW, Remonda L. Endovascular treatment of posterior circulation cerebral aneurysms by using Guglielmi detachable coils: a 10-year single centre experience with special regard to technical development. *AJNR Am J Neuroradiol* 2005;26:1732-8.
23. Kuether TA, Nesbit GM, Barnwell SL. Clinical and angiographic outcomes, with treatment data, for patients with cerebral aneurysms treated with Guglielmi detachable coils: a single-center experience. *Neurosurgery* 1998;43:1016-25.
24. Debrun GM, Aletich VA, Kehrli P, et al. Selection of cerebral aneurysms for treatment using Guglielmi detachable coils: the preliminary University of Illinois at Chicago experience. *Neurosurgery* 1998;43:1281-97.
25. Sluzewski M, van Rooij WJ. Early rebleeding after coiling of ruptured cerebral aneurysms: incidence, morbidity, and risk factors. *AJNR Am J Neuroradiol* 2005;26:1739-43.

**Address for Correspondence**

Luca Remonda, MD  
Institut für Diagnostische & Interventionelle  
Neuroradiologie  
Inselspital  
Freiburgstraße 4  
3010 Bern  
Switzerland  
Phone (+41/31) 632-4549, Fax -4872  
e-mail: luca.remonda@insel.ch