

Bernhard Frey
Katharina Waldvogel
Christian Balmer

Clinical applications of photoplethysmography in paediatric intensive care

Received: 6 July 2007
Accepted: 13 November 2007
Published online: 11 December 2007
© Springer-Verlag 2007

Abstract *Objective:* The photoplethysmographic wave is displayed by most pulse oximeters. It may be used as a non-invasive alternative to invasive arterial blood pressure trace analysis for continuous haemodynamic monitoring in selected situations. *Patients and setting:* Four cardiac patients treated in a tertiary neonatal-paediatric intensive care unit. *Measurements:* Simultaneous monitoring of the photoplethysmographic wave, ECG, and invasive blood pressure. *Results and conclusions:* Photoplethysmography allows for monitoring pulse rate in patients with (possible) heart rate/pulse rate dissociation (pacemaker dependency, pulsatile ventricular assist device); monitoring sudden changes in heart beat volume, which are unrelated to respiration (pulseless electrical activity, pulsus alternans); and monitoring respiratory-dependent fluctuations of the plethysmographic wave (heart failure, hypovolaemia, asthma, upper airway obstruction, pericardial effusion). Deterioration, slowly evolving over time, may be detected by this method.

Keywords Paediatrics · Pulse oximetry · Photoplethysmography · Cardiovascular monitoring

Introduction

Pulse oximetry has become one of the most valuable monitoring techniques

in intensive care for continuous evaluation of arterial haemoglobin oxygen saturation. In addition to the digital read-out of oxygen saturation, most pulse oximeters display a plethysmographic waveform, which can help clinicians to distinguish an artefactual signal from the true signal [1]; however, there may be further clinical applications of the plethysmographic waveform. Photoplethysmography detects changes in blood volume in the tissue under where the probe is applied. The displayed pulse waves arise from heart-beat-dependent volume changes in the terminal arterial bed. The slower respiratory waves are caused by blood volume changes in the venous bed. These characteristics make the plethysmographic wave a useful tool for non-invasive haemodynamic monitoring in some clinical settings in the paediatric intensive care unit.

Methods

We present examples recorded from children we treated in our tertiary neonatal and paediatric intensive care unit. A Solar 8000M Modular Patient Monitor was used (GE Medical Systems, Freiburg, Germany) with built-in Nellcor N-100 pulse oximeter (Nellcor, Pleasanton, Calif.).

Monitoring pulse rate

Case 1

A 16-year-old boy with severe cardiomyopathy was put on a pulsatile ventricular assist device (Berlin Heart, Berlin, Germany). He was non-invasively monitored by pulse oximetry and ECG. While the plethysmographic wave shows the ventricular-assist device frequency of 60/min, the ECG shows the electrical activity of the own heart (atrio-ventricular pacing, 129/min; Fig. 1).

Similarly, in the cardiac pacemaker-dependent child, ECG monitoring alone may not trigger an alarm in the case of cardiac arrest. In the presence of cardiac arrest, the ECG monitor may continue to count pacemaker artefact. Pulse-rate monitoring by pulse oximetry is also useful in arrhythmias such as bigeminy. Analysis of the plethysmographic wave may be helpful in distinguishing arrhythmia from artefact on the ECG and may give clues to the haemodynamic relevance of the arrhythmia.

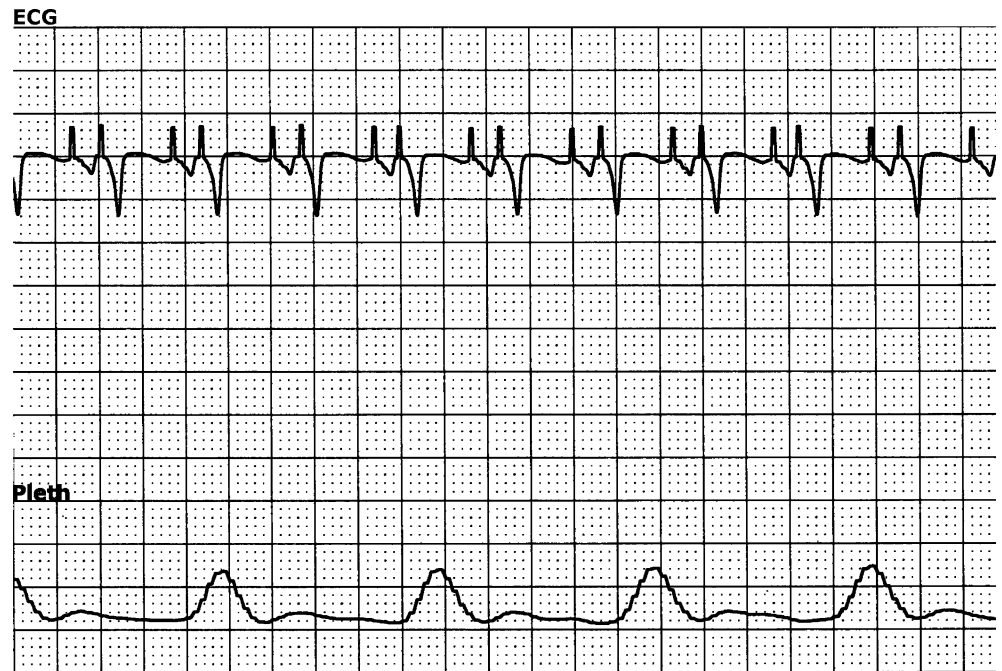
The pulse-rate display of the pulse oximeter is useful for two main reasons: firstly, the pulse-rate value should correlate with the measured heart rate, before the saturation reading is accepted. Secondly, related to cardiac output, pulse rate is relevant and not heart-/ECG rate; therefore, whenever dissociation between heart-/ECG rate and pulse rate is anticipated, as in case 1 or in a pacemaker-dependent child who is at risk of respiratory failure or loss of pacemaker capture, plethysmography becomes an important monitoring tool [2].

Monitoring respiratory-dependent fluctuations of the plethysmographic wave

Case 2

A 5-month-old boy with junctional ectopic tachycardia after heart surgery (tetralogy of Fallot repair) was first treated with cooling and amiodarone. Heart rate decreased from 210 to 157/min. Analysis of the plethysmographic wave revealed pronounced (ventilation-dependent) fluctuations (Fig. 2a). The ventilation-related systolic arterial pressure fluctuations (pulsus paradoxus) were 10 mmHg. With sequential atrio-ventricular pacing (176/min) and unchanged ventilation parameters (peak inspira-

Fig. 1 Electrocardiogram and plethysmographic wave (*Pleth*) of case 1. The patient's heart rate is 129/min on the ECG tracing (atrio-ventricular pacing), while the completely dissociated pulse generated by the mechanical assist device is seen at 60/min



tory pressure 24 cm H₂O, PEEP 4 cm H₂O, frequency 34/min, muscle paralysis), the plethysmographic fluctuations were less pronounced (Fig. 2b, 5 min after the start of pacing). The systolic arterial pressure fluctuations decreased to 3 mmHg. The mean arterial blood pressure remained unchanged. No volume was infused. Cardiac output was not measured.

We assume that restoration of AV synchrony by pacing resulted in improved cardiac output and that the decrease in respiratory-dependent blood pressure fluctuations was related to the improved cardiac performance.

In cardiac patients with stable respiratory state, variations in respiratory-dependent blood pressure fluctuations (pulsus paradoxus) may indicate variations in cardiac performance [3]. In mechanical ventilation, the cyclic, constant intrathoracic pressure variations induce cyclic changes of arterial systolic blood pressure (reversed pulsus paradoxus) which are related to cyclic changes in left ventricular stroke volume [4]. In mechanic-

ally ventilated patients, a strong correlation and a good agreement between respiratory variation in arterial pulse pressure and respiratory variation in pulse oximetry plethysmographic waveform amplitude has been shown [5]. Lacking invasive arterial blood pressure monitoring or in the case of technical problems (e.g. damped wave), analysis of the photoplethysmographic wave may facilitate demonstrating successful therapy or titrating therapy, as shown in case 2 and recently demonstrated for volume dependency in adult patients [6]. Pulsus paradoxus due to heart failure in paroxysmal supraventricular tachycardia (SVT) is also detectable by pulse oximetry [7]. High respiratory-dependent fluctuations of the plethysmographic wave in an infant with SVT almost completely disappeared after conversion to a regular sinus rhythm [7].

Increasing respiratory-dependent fluctuations of the plethysmographic wave (pulsus paradoxus) may alert the clinician in other situations too: status asthmaticus [8]; upper airway obstruction [9]; and peri-

cardial effusion [10]. In children at risk of pericardial tamponade, increasing respiratory-dependent fluctuations of the plethysmographic wave may be an early sign of aggravation, before appearance of the classical signs such as tachycardia, hypotension and distension of the external jugular vein [10].

There is scarce information regarding the physiological principles underlying these clinical observations. Two types of photoplethysmographic waves can be recognized: the pulse waves and the slower respiratory waves. The respiratory waves are caused by blood volume changes in the venous bed. Respiration-dependent intrathoracic pressure changes produce variations in venous return to the right side of the heart and thus in blood volume mainly in the venous bed, since the venous compliance is ten times greater than the arterial [11]. These respiratory-dependent volume changes of the venous bed are detected by the amplitude of the plethysmographic respiratory wave. The amplitude changes of

the plethysmographic pulse wave are significantly influenced by the distensibility of the arterial wall, which is controlled by the autonomic nervous system [11]. The amplitude of the plethysmographic respiratory wave seems to reflect variation in intrathoracic pressure more reliably [8]. In non-intubated children with or without respiratory disorders, it has been shown that the photoplethysmographic fluctuations of the upper peak (mm) correlated with invasively measured pulsus paradoxus (mmHg; $r = 0.85$) [8]. The degree of pulsus paradoxus reflects the severity of the underlying disorder. In patients receiving mechanical ventilation, reversed pulsus paradoxus can be monitored

(inspiratory *increase* in systolic blood pressure) [12].

Monitoring sudden changes in heart beat volume, which are unrelated to respiration

Case 3

A 9-year-old boy with arrhythmias related to long QT syndrome was monitored in the ICU. The recording in Fig. 3 shows an episode of ventricular tachycardia (“torsades de pointe”), induced by an electrical impulse on the T wave via a newly implanted cardioverter/defibrillator (ICD) to test the device. During the ventricular tachycardia arterial

pressure and plethysmographic waves were flat. The CVP was increased.

Case 4

This is the same patient as case 1, before Berlin Heart implantation. He was spontaneously breathing and treated with dobutamine, captopril and diuretics (ejection fraction 30%, central venous oxygen saturation 54%). The photoplethysmographic wave showed diminutions of the amplitude on alternate beats (Fig. 4).

In case 3, photoplethysmographic waveform duplicates arterial pressure waveform morphological abnormalities. Activation of the “plethymo-

Fig. 2 Electrocardiogram, invasive arterial pressure and plethysmographic wave (*Pleth*) of case 2. This is a patient with post-operative junctional ectopic tachycardia who has variable AV association (without and with pacing) resulting in pronounced and less pronounced plethysmographic and arterial pressure fluctuations.
a Pronounced plethysmographic fluctuations with junctional rhythm (systolic arterial pressure fluctuations 10 mmHg; not obvious due to the large scale).
b Less pronounced plethysmographic fluctuations on atrio-ventricular sequential pacing (arterial pressure fluctuations 3 mmHg)

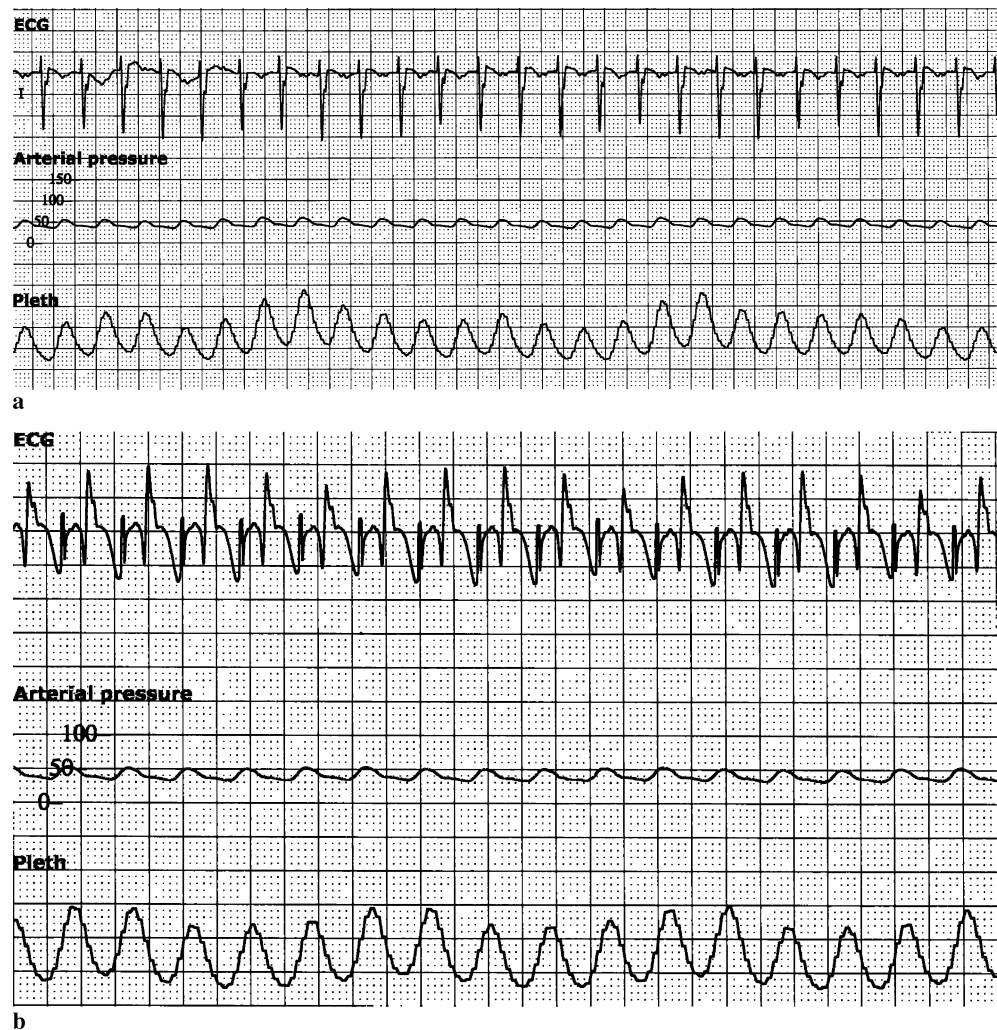


Fig. 3 Electrocardiogram, plethysmographic wave (*Pleth*), invasive arterial pressure and central venous pressure (*CVP*) of case 3. During ventricular tachycardia, the blood pressure and pleth tracings are flat. This example shows an invasively monitored patient with a disorder that typically is seen in patients without invasive monitoring

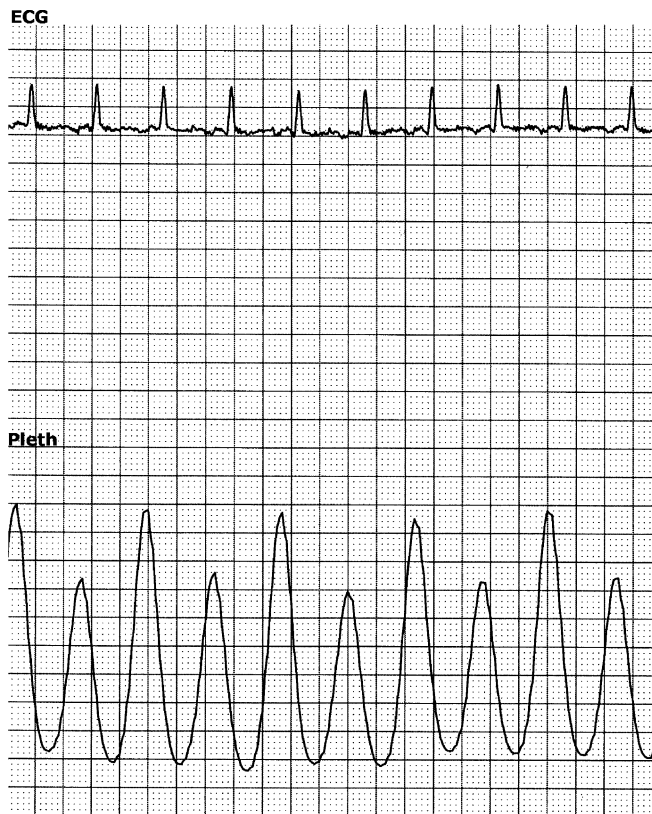
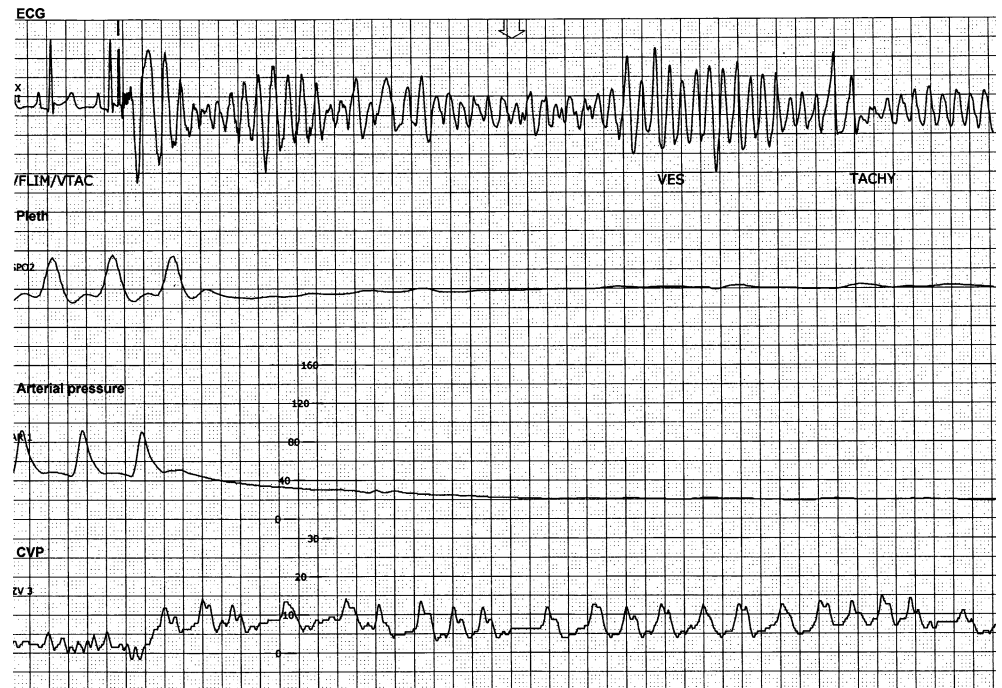


Fig. 4 Electrocardiogram and plethysmographic wave (*Pleth*) of case 4: a spontaneously breathing patient with severe dilated cardiomyopathy. The pleth wave shows diminutions of the amplitude on alternate beats (pulsus alternans)

graph non-pulsatile” alarm may be the first alert to the occurrence of pulseless electrical activity in a non-invasively monitored patient [2]. Pulsus alternans (case 4) is due to an alternating strength of contraction from one beat to the next (not attributable to bigeminal rhythms) seen in more severe forms of cardiac failure (e.g. cardiomyopathies, aortic stenosis). Plethysmography clearly demonstrates this phenomenon (case 4) [13]. Early detection of this abnormality may be useful in guiding diagnosis and treatment. The patient with cardiomyopathy and subsequent Berlin Heart support (cases 1 and 4) clearly shows the benefits of photoplethysmography. Firstly, when the patient had not yet an arterial line, the pulse oximeter tracing pointed to the severity of the myocardial dysfunction and more invasive monitoring was started. Subsequently, after the mechanical support had been implanted, invasive arterial monitoring was stopped and non-invasive monitoring by plethysmography resumed.

Limitations

Although we previously showed that photoplethysmography can be used quantitatively for estimation of the degree of pulsus paradoxus [8], the cases presented here clearly show qualitative applications of photoplethysmography. There are numerous manufacturers for pulse oximeters and photoplethysmographic probes; thus, the photoplethysmographic characteristics from each model and/or different manufacturers may differ. This applies to movement artefacts, ambient lighting, individual tissue characteristics and auto-gain features. Pulse oximeters with auto-gain features are less useful in depicting a persisting reduction in perfusion, but they remain valid in representing short cyclic variations in pulse volume, such as in pulsus paradoxus [8, 13]. Furthermore, in situations of peripheral vascular constriction (low cardiac output, catecholamine therapy and hypothermia) the probe (especially if in perfusion mode) may not work appropriately [1]; however, the qualitative features shown in this study may be present even in these circumstances. In fact, some of the presented patients were in low cardiac output and/or had catecholamine therapy. In the present case series, repeatability was not tested; however, repeatability was shown at least for airway obstruction [9], pericardial effusion [10] and pulsus paradoxus in spontaneously breathing [8] and ventilated patients [5]. Most importantly, this electronic device should not replace careful clinical monitoring, such as capillary refill, skin temperature and ECHO, and it may only be used as an adjunct to complete the clinical picture. Finally, this technique is but another electronic form of "feeling

the pulse". So far, this tool is without proven significance with regard to monitoring adverse events. Prospective investigations should be performed to identify how many of all patients can be monitored, how many artefacts do occur and whether therapy changes according to the readings.

Conclusion

The photoplethysmographic wave which is displayed by most pulse oximeters may be used for additional haemodynamic information in some selected situations when an arterial blood pressure monitoring is not available. The advantages of this method are its widespread use, non-invasiveness and continuity. Haemodynamic deterioration, whether suddenly occurring or slowly evolving over time, may be detected by this method. A problem with using photoplethysmography is movement artefact. There is only minimal reference to photoplethysmography monitoring, except for case series for assessment of pulsus paradoxus in obstructive airway disease [8, 9].

References

- Jubran A (2004) Pulse oximetry. *Intensive Care Med* 30:2017–2020
- Brownlee JR, Serwer GA, Dick M, Bauld T, Rosenthal A (1989) Failure of electrocardiographic monitoring to detect cardiac arrest in patients with pacemakers. *Am J Dis Child* 143:105–107
- Pizov R, Ya'ari Y, Perel A (1989) The arterial pressure waveform during acute ventricular failure and synchronized external chest compression. *Anesth Analg* 68:150–156
- Michard F, Teboul JL (2000) Using heart-lung interactions to assess fluid responsiveness during mechanical ventilation. *Crit Care* 4:282–289
- Cannesson M, Besnard C, Durand PG, Bohé J, Jacques D (2005) Relation between respiratory variations in pulse oximetry plethysmographic waveform amplitude and arterial pulse pressure in ventilated patients. *Critical Care* 9:R562–R568
- Feissel M, Teboul JL, Merlani P, Badie J, Faller JP, Bendjelid K (2007) Plethysmographic dynamic indices predict fluid responsiveness in septic ventilated patients. *Intensive Care Med* DOI 10.1007/s00134-007-0602-6
- Frey B (1999) Pulsus paradoxus indicating heart failure in paroxysmal supraventricular tachycardia: easy detection by pulse oximetry. *Intensive Care Med* 25:333–334
- Frey B, Butt W (1998) Pulse oximetry for assessment of pulsus paradoxus: a clinical study in children. *Intensive Care Med* 24:242–246
- Arnold DH, Spiro DM, Desmond RA, Hagood JS (2005) Estimation of airway obstruction using oximeter plethysmograph waveform data. *Resp Res* 6:65
- Tamburro RF, Ring JC, Womback K (2002) Detection of pulsus paradoxus associated with large pericardial effusions in pediatric patients by analysis of pulse-oximetry waveform. *Pediatrics* 109:673–677
- Dorlas JC, Nijboer JA (1985) Photoelectric plethysmography as a monitoring device in anaesthesia. *Br J Anaesth* 57:524–530
- Jardin F, Farcot JC, Gueret P, Prost JF, Ozier Y, Bourdarias JP (1983) Cyclic changes in arterial pulse during respiratory support. *Circulation* 68:266–274
- Dennis MJ (2000) Plethysmography: the new wave in haemodynamic monitoring – a review of clinical applications. *Aust Crit Care* 13:14–20

B. Frey (✉) · K. Waldvogel
University Children's Hospital, Department of Intensive Care and Neonatology, 8032 Zurich, Switzerland
e-mail: Bernhard.Frey@kispi.uzh.ch
Tel.: +41-44-2667359
Fax: +41-44-2667168

C. Balmer
University Children's Hospital, Department of Cardiology, 8032 Zurich, Switzerland