

David Holzmann · Thomas Kaufmann · Paula Pedrini  
Anton Valavanis

## Posterior epistaxis: endonasal exposure and occlusion of the branches of the sphenopalatine artery

Received: 23 January 2003 / Accepted: 3 April 2003 / Published online: 29 April 2003

© Springer-Verlag 2003

**Abstract** Intractable posterior epistaxis (PE) is a frequent emergency for which different treatment modalities are available. While nasal packing causes extreme discomfort and angiography with consecutive selective embolization is not available everywhere, recent studies emphasize the value of sphenopalatine artery (SPA) occlusion by different techniques and indicate success rates of 13–33%. In our institution, previously endoscopic management of PE consisted either of isolated coagulation of an identified bleeding source (group A) or cutting and coagulation of arterial branches running through the sphenopalatine foramen (SPF) (group B). According to our neuroradiological and rhinological experience we developed a modification of SPA transection and coagulation following identification of the division in conchal and septal branches of the SPA (group C). During a 26-month period the success rates of these three techniques in 95 patients were compared prospectively. The three modalities revealed a re-bleeding rate of 3 out of 21 (21%) in group A, 1 in 6 (16.7%) in group B and 3 in 69 (4.3%) in group C. At the level of the SPF, 36 out of 69 patients had one conchal branch, whereas 30 (43.5%) had two and 3 (4.4%) had three. If SPA transection and coagulation for intractable PE is adopted the anatomic varieties of the SPA with its division in conchal and septal branches have to be taken into account. According to our experience the septal branch of the SPA plays a major role in PE. Its occlusion significantly improves the success rate of PE treatment.

**Keywords** Epistaxis · Sphenopalatine · Artery · Angiography · Surgery

### Introduction

Epistaxis most commonly originates from the anterior part of the nose and can be controlled with chemical or electrical cauterization, anterior packing and/or posterior packing. Posterior epistaxis (PE) is potentially life-threatening and often requires transfer to a hospital, where packing, surgery or embolization is performed. Risk factors for epistaxis are history of hypertension, systolic blood pressure >140, alcohol use, tobacco use, coagulopathy, anticoagulation and non-steroidal anti-inflammatory drugs (NSAIDs). Balrow et al. [1] could demonstrate that such risk factors favor neither a surgical nor a non-surgical treatment. However, posterior site of bleeding, hematocrit <38% and the need for blood transfusion seem to be significant predictors for surgical treatment. Nasal packing is a stressful procedure and is known to cause not only extreme discomfort, but sometimes to lead to skin and mucosal necrosis, breathing impairment and aspiration [11]. From the anatomic [6] and angiographic [19, 23] work-up, we know that the anterior ethmoidal artery complex can be responsible for bleeding in the antero-superior portion of the nasal cavity, whereas the sphenopalatine artery (SPA) is most important in the posterior part of the nose. Knowledge of the collateral blood supply in the nasal cavity is essential in achieving control of the nasal blood circulation. Several neuroradiological studies pointed out the different anastomoses between the external carotid artery (ECA) and the internal carotid artery (ICA) relevant for the blood supply in the nose [2, 7, 13, 19, 23]. These anastomoses have to be taken into account when surgery or angiography with superselective embolization is adopted for PE.

During the last 2 decades, angiography and selective embolization gained more impact in the treatment of intractable PE [2, 9, 13, 17, 18, 20]. However, the indication of this option still has been biased by the availability of an experienced interventional neuroradiologist. Major com-

For this study, neither financial support nor funding was given.

D. Holzmann (✉) · T. Kaufmann · P. Pedrini  
Department of Otorhinolaryngology and Head and Neck Surgery,  
University Hospital of Zürich,  
Frauenklinikstr. 24, 8091 Zürich, Switzerland  
Tel.: +41-1-2555860, Fax: +41-1-2554556,  
e-mail: holzmann@orl.usz.ch

A. Valavanis  
Department of Neuroradiology, University Hospital of Zürich,  
Zürich, Switzerland

plications after embolization such as facial nerve paralysis or stroke are rare [5, 10] and depend very much on the experience of the neuroradiologist.

While ligation of the ECA was slowly replaced by surgical occlusion of the maxillary artery (MA) as introduced by Chandler and Serrins in 1965 [4], more recent studies recommend a more distal occlusion, i.e., of the sphenopalatine artery (SPA) [12, 16, 22]. The first microsurgical ligation of the SPA was described by Prades in the 1970s [14]. In our experience the endoscopic coagulation of the SPA still had an estimated rebleeding rate of approximately 20%, which is comparable with the recent study performed by Snyderman and colleagues [16]. Rockey and Anand [15] even found in their recently published study a recurrence rate of 33% in their ten operated patients. The goal of this prospective study is to present our surgical technique respecting the particular anatomy of the SPA and to present the results.

## Subjects and methods

Between 1 August 2000 and 31 October 2002, 245 patients were hospitalized for PE at the Department of Otorhinolaryngology and Head and Neck Surgery at the University Hospital of Zurich. None of these patients had undergone previous hospitalization for epistaxis or undergone surgery or embolization prior to the actual PE episode. Patients with Osler's disease were excluded. After initial packing, underlying risk factors potentially responsible for intractable PE such as oral anticoagulation and arterial hypertension were treated in all patients. If re-bleeding occurred after removal of nasal packing, patients were considered for endoscopic surgery. A total of 103 patients (42%) underwent surgery for intractable PE. Eight patients were excluded from this study since two suffered from severe coagulopathy resulting from progressive hepatic cirrhosis and six further patients were lost to follow-up. Thus, 95

(72 male, 23 female) of the 245 patients (38.8 %) who underwent surgery were included in this study. They were 25.5 to 91.5 years old (mean 62.1 years).

The following surgical concept was applied. After induction of general anesthesia a systematic nasal endoscopy of both nasal cavities was performed, first without any decongestion and then after superficial decongestion (cotton swabs in 30 ml oxybuprocain 2% with 30 drops of adrenalin 1:1,000).

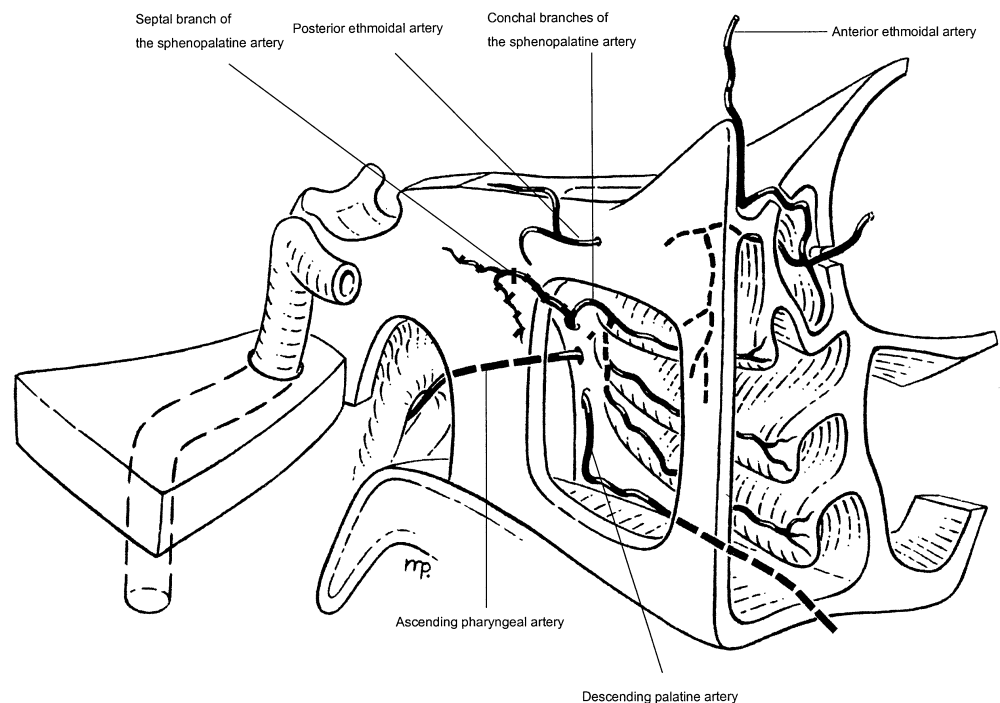
If a clear bleeding source was detected, only this bleeding source was coagulated using a monopolar suction-coagulator. All patients treated by this technique were collected in group A.

If nasal endoscopy did not reveal any clear bleeding source, the SPA was surgically occluded. This was performed by cutting the posterior end of the middle turbinate to expose the posterior fontanel of the maxillary sinus and the sphenopalatine foramen (SFA). By bluntly penetrating through the posterior fontanel the posterior wall of the maxillary sinus could be exposed. A mucosal flap over the sphenopalatine foramen (SPF) and the ethmoidal crest were elevated and if necessary the ethmoidal crest anterior to the SPF had to be removed to expose the foramen sufficiently. On the level of the SPF all arterial branches (i.e., the conchal branches of SPA) were identified, transected and coagulated. As a next step the sphenoid sinus was opened by bluntly penetrating through its anterior wall in the sphenothmoidal recess along the inferior edge of the superior turbinate. The obtained opening was enlarged by down-cutting punches until an arterial branch (i.e., the septal branch of the SPA) started to bleed (Fig. 1). Both ends of it were coagulated. Patients operated on by this technique were collected in group C.

Since not all surgeons were able to identify the septal branch, some patients underwent only surgical occlusion of the conchal branches at the SPA, whereas the septal branch was left untouched (group B) (Table 1).

The nasal cavity of all patients was packed for 24 h at the end of any surgery (groups A, B and C). Based on our experience with angiography in cases of epistaxis recurrence following surgical occlusion of the SPA, arteries that have been occluded only by coagulation without additional transection may recanalize within a few days. Thus, the occlusion of an artery in this study meant transection and coagulating the bleeding ends with a monopolar suction-coagulator. No clips were used.

**Fig. 1** Schematic oblique view to the sphenopalatine artery (SPA)



**Table 1** Surgical treatment of patients with intractable posterior epistaxis, *n* =95

Therapy	Group A, <i>n</i> =20	Group B, <i>n</i> =6	Group C, <i>n</i> =69
Local coagulation	+		
SPA without septal branch		+	
SPA with septal branch			+
Rebleeding	3 (21%)	1 (16.7%)	3 (4.3%)

## Results

All 95 surgically treated patients in this study were followed 2 to 18.3 months (mean 9.3 months). Twenty (21%) patients were treated endoscopically with coagulation of a clear bleeding source (group A), 6 (6.3%) patients were in group B and 69 (72.7%) in group C. Rebleeding occurred in three (21%) in group A, one (16.7%) in group B and three (4.3%) in group C. Recurrence of bleeding was noted in the three group-A patients after 6 and 10 days, respectively. They underwent revision surgery according to that used for group C patients and were free of bleeding thereafter. The patient in group B whose epistaxis recurred after 10 days underwent revision surgery with occlusion of the septal branch of the SPA as well as the anterior ethmoidal artery complex by an external approach. During follow-up (9 months) she did not have any bleeding again. One patient from group C reported a short episode of bleeding 6.5 months after surgery. The bleeding was mild and neither a consultation of his family doctor nor of an otorhinolaryngologist was necessary. In the remaining two patients of group C with an epistaxis recurrence on the same side within 5 to 8 h, the ethmoidal arteries were ligated through an external approach. They were free of bleeding the following 4 and 5 months, respectively (Table 1).

Complications after surgery were protracted crust formation with subjective sensation of dryness in the nose, pain and posterior rhinorrhea. This problem occurred in particular in groups B and C and was rarely seen in patients of group A. Most of these side effects disappeared within 2 to 4 weeks, except for persistent posterior rhinorrhea, which caused only mild discomfort in 12 patients of groups B and C. All patients could leave the hospital in good condition.

In patients where the sphenopalatine foramen was exposed, both authors counted the number of arterial branches of the SPA at the level of the SFA. In 69 out of 75 patients the numbers of arterial branches could be noted, 36 out of 69 (52.1%) patients had only one artery, 30 (43.5%) had two and 3 (4.4%) even had three arterial branches. In all patients of group C only one septal branch was identified.

## Discussion

The indication to perform surgical treatment for refractory PE cannot be standardized, since too many factors such as age, underlying cardiovascular diseases, courses of failed treatment with packing, etc., may influence the decision

to operate on patients with PE. Investigation of surgical ligation failures with consecutive angiographic investigations revealed that the ethmoidal arteries, internal carotid artery (ICA) branches (i.e., inferolateral trunk, vidian artery) and nasopharyngeal vessels (ascending pharyngeal, descending palatine, ascending palatine, accessory meningeal artery) may reconstitute flow beyond the proximal occlusion and explain early recurrent hemorrhage. The ethmoidal arteries are the collateral pathways to the septal territory. Embolization of the septal branch of the SPA beyond the site of anastomosis will be curative [2, 19]. Thus, bleeding recurrence can be reduced when the arterial blood supply is occluded at its most distal portion [23].

The SPA divides into a medial septal and lateral conchal branches [6, 19]. This division most frequently is located proximal to the sphenopalatine foramen (SPF). The septal branch courses along the inferior portion of the anterior wall of the sphenoid sinus, while the conchal branches most frequently course through the SPF to the middle and inferior turbinate (Fig. 1). In our small series, there were almost no recurrences after occluding all branches of the SPA. As mentioned, prominent ethmoidal arteries may predict further bleeding and a possible need for surgical occlusion.

The failure rate after MA ligation is reported to be between 5–22% [2, 8, 11], which is similar to the SPA clipping at the level of the SPF (13–33%) [15, 16]. The latter corresponds to the results of our group-B patients in which the septal branch was not occluded. Our recurrence rate was 16.7%. However, the number of our group-B patients is too small to finally define the treatment efficacy by closing solely the conchal branches in PE. Reviewing the literature on endoscopic SPA occlusion in PE [3, 15, 16, 21], most of the authors describe only one artery at the level of the SPF. Only one study [21] indicates that “sometimes” the SPA can already be divided into two branches. Of our patients, 48% (33/69) had more than one arterial branch at the level of the SPF. It might be that one of them represents the anastomosis of the ascending palatine artery with a conchal branch (Fig. 11).

According to our earlier neuroradiological and surgical experience, it is essential not only to coagulate the arterial branches by diathermy, since we could prove a recanalization after a few days. Thus, occluding the SPA endoscopically should mean to expose, transect and coagulate the conchal branches at the level of the SPF as well as to occlude the septal branch through a sphenoidotomy. If the different anastomoses in the blood supply of the nasal cavity are taken into account, it still remains unclear why treatment like that in group C provides such good results.

## Conclusion

At the level of the SPF many patients already have two or sometimes even three (conchal) branches of the SPA. If occlusion of SPA for intractable posterior epistaxis is attempted, better results can be achieved by occluding not only all conchal branches, but also the septal branch.

## References

1. Balrow DW, Deleyiannis WB, Pinczower EF (1997) Effectiveness of surgical management of epistaxis at a tertiary care center. *Laryngoscope* 107: 21–24
2. Breda SD, Choi IS, Persky MS, Weiss M (1989) Embolization in the treatment of epistaxis after failure of internal maxillary artery ligation. *Laryngoscope* 99: 809–813
3. Budrovich M, Saetti R (1992) Microscopic and endoscopic ligation of the sphenopalatine artery. *Laryngoscope* 102: 1390–1394
4. Chandler JR, Serrins AJ (1965) Transantral ligation of the internal maxillary artery of epistaxis. *Laryngoscope* 75: 1151–1159
5. Elden L, Montanera W, Terbrugge K, Willinsky R, Lasjaunias P, Chalres D (1994) Angiographic embolization for the treatment of epistaxis: a review of 108 cases. *Otolaryngol Head Neck Surg* 111: 44–50
6. Lang J (1988). *Klinische Anatomie der Nase, Nasenhöhle und Nasennebenhöhlen*. Georg Thieme Verlag, Stuttgart, New York, pp 102–105
7. Lasjaunias P, Vignaud J, Hasso AN (1975) Maxillary artery blood supply to the orbit: normal and pathological aspects. *Neuroradiology* 9: 87–97
8. Mc Donald TJ, Pearson PW (1980) Follow-up on maxillary artery ligation for epistaxis. *Arch Otolaryngol* 106: 635–638
9. Merland JJ, Melki JP, Chiras J (1982) Place of embolization in the treatment of severe epistaxis. *J Otolaryngol* 11: 271–274
10. Metson R, Hanson DG (1983) Bilateral facial nerve paralysis following arterial embolization for epistaxis. *Otolaryngol Head Neck Surg* 91: 299–303
11. Montgomery WW, Reardon EJ (1980) Early vessel ligation for control of severe epistaxis. In: Snow JB Jr (ed) *Controversies in otolaryngology*. WB Saunders, Philadelphia, pp 315–319
12. O'Flynn PE, Shadaba A (2000) Management of posterior epistaxis by endoscopic clipping of the sphenopalatine artery. *Clin Otolaryngol* 25: 374–377
13. Parnes LS, Heeneman H, Vinuela F (1987) Percutaneous embolization for control of nasal blood circulation. *Laryngoscope* 97: 1312–1315
14. Prades J (1976) Abord endonasal de la fosse pterygo-maxillaire. *LXXIII Cong Franc Compt Rendus des Seance*: 290–296
15. Rockey JG, Anand R (2002) A critical audit of the surgical management of intractable epistaxis using sphenopalatine artery ligation/diathermy. *Rhinology* 40: 147–149
16. Snyderman CH, Goldman SA, Carrau RL, Ferguson BJ Grandis JR (1999) Endoscopic sphenopalatine artery ligation is an effective method of treatment for posterior epistaxis. *Am J Rhinol* 13: 137–140
17. Sokoloff J, Wickbom I, McDonald D (1974) Therapeutic percutaneous embolization in intractable epistaxis. *Radiology* 111: 285–287
18. Strutz J Schumacher M (1990) Uncontrollable epistaxis. *Arch Otolaryngol Head Neck Surg* 116: 697–699
19. Valavanis A, Setton A (1993) Embolization of epistaxis. In: Valavanis A (ed) *Interventional neuroradiology*. Springer, Berlin, Heidelberg, New York, pp 55–61
20. Vitek JJ (1991) Idiopathic intractable epistaxis: endovascular therapy. *Radiology* 181: 113–116
21. Voegels RL, Thomé DC, Iturralde PPV, Butugan OB (2001) Endoscopic ligation of the sphenopalatine artery for severe posterior epistaxis. *Otolaryngol Head Neck Surg* 124: 464–467
22. Weaver EM, Chaloupka JC, Putman CM, Roth TC, Horky JK, Sasaki CT (1999) Effect of internal maxillary arterial occlusion on nasal blood flow in swine. *Laryngoscope* 109: 8–14
23. Welsh LW, Welsh JJ, Scogna JE, Gregor FA (1990) Role of angiography in the management of refractory epistaxis. *Ann Otol Rhinol Laryngol* 99: 69–73