

Surgical treatment of tentorial dural arteriovenous fistulae located around the tentorial incisura

Taketo Hatano · Oliver Bozinov · Jan-Karl Burkhardt · Helmut Bertalanffy

Received: 30 January 2012 / Revised: 10 August 2012 / Accepted: 6 October 2012 / Published online: 24 January 2013
© Springer-Verlag Berlin Heidelberg 2013

Abstract Tentorial dural arteriovenous fistulae (DAVF) are relatively uncommon and are the most dangerous type of DAVF. Because of a high incidence of hemorrhage and subsequent neurological deficits, treatment is mandatory. A consecutive series of nine surgically treated patients with symptomatic tentorial DAVF were analyzed in this study. All lesions were located around the tentorial incisura and were treated microsurgically using a subtemporal approach in eight cases and a supracerebellar approach in one case. The dural bases of the lesions were located adjacent to the tentorial edge in six patients and the tentorial apex in three patients. Complete obliteration was achieved in all treated tentorial DAVF. In one patient, the torcular fistula remained untreated without cortical venous reflux. Postoperative asymptomatic temporal lobe hemorrhage was diagnosed in one patient with a tentorial apex DAVF; however, no new neurological symptoms were present after surgical treatment. The subtemporal approach for unilateral tentorial DAVF is a favorable and direct approach for the highly skilled surgeon. Perimesencephalic venous dilatation or varix is an important finding on MRI to help localize tentorial DAVF in the tentorial edge or apex.

Keywords Dural arteriovenous fistulae (DAVF) · Microsurgery · Tentorial incisura · Treatment · Subtemporal approach

Introduction

Tentorial dural arteriovenous fistulae (DAVF) are relatively uncommon, accounting for 4 % to 8 % of intracranial DAVF, and represent the most dangerous type of arteriovenous fistulae [1–6]. The aggressive nature of tentorial DAVF can be largely attributed to retrograde leptomeningeal venous drainage [3]. Consequently, once diagnosed, tentorial DAVF are treated aggressively to arrest neurological deterioration and to prevent the risk of intracranial hemorrhage [4, 6–8].

Endovascular treatment has become the predominant therapy for intracranial DAVF [9]. However, the cure rate for tentorial DAVF by embolization alone is variable due to complicated feeding arteries and draining veins. Partial embolization, which leaves a fistula of Borden type II or III, cannot decrease the risk of hemorrhage or progression of the effects of venous hypertension [10, 11]. Therefore, residual tentorial DAVF Borden type II or higher require microsurgical intervention [3, 4, 6–8].

Controversy exists regarding the surgical strategy for tentorial DAVF due to a variety of presentations [4–8, 12, 13]. The optimal surgical strategy for tentorial DAVF depends on the anatomic location of the fistula and the specific characteristics of the arterial supply and venous drainage. Although the subtemporal approach was used in some reported DAVF around the tentorial incisura, to date, the details of the technique have not been described [4, 8].

Materials and methods

A consecutive series of nine patients with symptomatic tentorial DAVF were treated between 1998 and 2006. Retrospective

Taketo Hatano and Oliver Bozinov contributed equally

Electronic supplementary material The online version of this article (doi:10.1007/s10143-013-0448-z) contains supplementary material, which is available to authorized users.

T. Hatano

Department of Neurosurgery, University Hospital, Kyoto, Japan

O. Bozinov (✉) · J.-K. Burkhardt

Department of Neurosurgery, University Hospital Zürich,
Frauenklinikstrasse 10,
8091 Zürich, Switzerland
e-mail: oliver.bozinov@usz.ch

H. Bertalanffy

Department of Neurosurgery, International Neuroscience Institute,
Hannover, Germany

analysis of medical records and neuroimaging were performed. The mean patient age was 52.7 years (range 33–70 years). There was a strong male predominance, with eight male subjects and one female subject (Table 1).

Patients were selected for treatment on the basis of hemorrhage on clinical presentation or anatomic features associated with a high risk of hemorrhage. All patients underwent computed tomographic (CT) scanning, magnetic resonance imaging (MRI) of the brain, and cerebral angiography prior to treatment. Lesions were graded according to the classification system developed by Borden et al [3].

Presentation

Three patients (33 %) presented with intracranial hemorrhage. The hemorrhage was located in the subarachnoid space in one patient, in the brain parenchyma in the second patient, and in both locations in the third patient. All nine patients experienced a variety of symptoms, including headaches, tinnitus, vertigo, facial sensory disturbances, hearing disturbances, diplopia, hemiparesis, and gait disturbances (Table 1).

Angiographic characteristics

All treated DAVF in this study were Borden type III. The lesions drained exclusively into subarachnoid veins. The dural bases of the lesions were at the lateral tentorial edge in six patients and at the tentorial apex in three patients. One patient with tentorial apex DAVF also had an additional Borden type I torcular DAVF. Feeding arteries originated from tentorial arteries in eight patients, middle meningeal arteries in five, and superior cerebellar arteries or/and posterior cerebral arteries in five. Draining veins were basal veins or their tributaries in eight patients and the vein of Galen in one. The associated torcular DAVF drained directly into the torcular sinus without cortical venous drainage. All cases presented with apparent venous dilatation or varix in the perimesencephalic cistern on MRI and angiography.

Treatment protocol

A team of neurosurgeons and endovascular specialists evaluated all patients to assess optimal therapeutic options. Transarterial embolization was attempted in all patients and multiple (a minimum of three) endovascular interventions were performed in seven patients prior to surgery. Although initial occlusion of the DAVF was achieved, the effect did not last. Eventually, endovascular occlusion failed in all of our presented cases. All patients received final microsurgical treatment by the senior author. A subtemporal approach was used in eight patients, and an infratentorial-supracerebellar approach was used in one patient after preoperative evaluation of the neuroradiological images

(bilateral fistula). The torcular DAVF was not treated due to its benign angiographic characteristics.

Subtemporal approach

After induction of general endotracheal anesthesia, a lumbar drain was placed, and 30–40 ml of cerebrospinal fluid (CSF) was released before dural opening, to aide with brain relaxation. The patient was placed into semilateral position. To facilitate the approach, the patient's head was tilted below the horizontal position by 10° and rotated towards the opposite side with the sagittal midline parallel to the floor. Then, the head was fixed with a three-pin Mayfield clamp. A straight or sickle-shaped skin incision was made, starting at the root of the zygoma and extending superiorly to the supratemporal line. An anterior or middle subtemporal craniotomy was performed, and it was ensured that the inferior margin of the craniotomy was at the level of the floor of the middle fossa. The dura was opened with a linear incision parallel to the floor of the middle fossa. At the initial stage of the intradural subtemporal approach, the bridging veins of temporal base were carefully dissected and sufficiently loosened to retract the temporal lobe away from the temporal base. The perimesencephalic cistern was opened widely to observe the draining veins. The tentorium was coagulated well and divided towards the edge of the incisura. Intraoperative micro-Doppler sonography was very useful during this step of the surgery to identify the arterialized draining veins and check their flow direction, thereby localizing the fistula points. The tentorial incision was extended laterally to allow treatment as closely as possible on the arterial side of the fistula point. If necessary, an anterior petrosectomy was added. The responsible dilated vein was coagulated and cut or obliterated with aneurysm clips near the exit point in the tentorium.

Supracerebellar approach

This approach was performed with the patient in the sitting position. A midline skin incision was made, and a craniotomy was performed until both transverse sinuses as well as the torcula became visible. A Y-shaped incision was made in the dura. The venous complex in the vicinity of the tentorial apex was approached without using a retractor. After identification of arterialized veins with a micro-Doppler, the draining vein was cauterized and cut near the fistula point.

Results

Outcome

There was no operative mortality and no new permanent neurological deterioration. Within 24 h, asymptomatic

Table 1 Summary of tentorial DAVF patients surgically treated in this study

Patient	Sex	Age	Clinical presentation	Side	Dural base	Arterial supply	Intracerebral hemorrhage	Main venous drainage	Borden classification ³	Surgical approach	Initial postoperative clinical signs	Clinical Signs after 3 months	GOS
1	M	68	Headache	Right	Tentorial edge	TA, MMA	Yes	Basal vein	3	Subtemporal	None	NDS	4
2	M	70	Headache, hemiparesis	Right	Tentorial edge apex	TA, PCA/SCA	Yes	Vein of galen	3	Subtemporal	Hemiparesis	NDS	4
3	M	44	Gait disturbance, headache, double vision	Left	Tentorial edge	TA, MMA, SCA/PCA, OA	No	Basal vein	3	Subtemporal	None	ND	5
4	M	33	Gait disturbance, headache	Left	Tentorial edge	TA, It, MMA	No	Basal vein	3	Subtemporal	Gait disturbance doublevision	NDS	5
5	M	52	Headache	Right	Tentorial edge	TA, SCA/PCA	No	Basal vein	3	Subtemporal	None	NDS	5
6	F	45	Headache	Left	Tentorial edge	TA, MMA	No	Basal vein	3	Subtemporal	Doublevision, numbness right face	NDS	5
7	M	48	Bruit, memory disturbance	Right	Tentorial apex	TA, SCA/PCA	Yes	Vein of galen	3	Subtemporal	Anopsia	NDS	5
8	M	52	Headache, double vision	Left	Tentorial edge	TA, MMA	No	Basal vein	3	Subtemporal	Doublevision, dysphasia	ND	5
9	M	63	Vertigo	Left	Tentorial apex	PCA/SCA	No	Basal vein	3	Infratentorial-supracerebellar	None	ND	5

M indicates male, *F* female, *TA* tentorial artery, *MMA* middle meningeal artery, *SCA* superior cerebellar artery, *PCA* posterior cerebral artery, *OA* occipital artery, *NDS* No new deficits from surgery, *ND* no deficits, *DAVF* dural arteriovenous fistulae

temporal lobe hemorrhage was detected in one patient with tentorial apex DAVF on routine postoperative CT. All patients underwent postoperative angiography (complete obliteration rate 100 %). There was no operative mortality and no new permanent neurological deterioration at the last follow-up, with two patients lost to a late follow-up (after 6 months) (Table 1).

Illustrative cases

Patient 1

A 68-year-old man presented with severe headaches, nausea, and vertigo. CT imaging demonstrated subarachnoid hemorrhage and right intracerebellar hemorrhage. Multiple dilated abnormal vessels were also detected in the right perimesencephalic and peripontine cisterns (Fig. 1a–b). Angiography revealed a tentorial edge DAVF supplied by the tentorial artery and middle meningeal artery. The fistula drained into the basal vein of Rosenthal or its tributaries, which had varices, emptying into the vein of Galen (Fig. 1c).

A right preauricular straight skin incision was made (Video 1, Supplement Digital Video 1, which demonstrates the clipping of the DAVF draining vein), and a middle subtemporal craniotomy was performed. The dura was opened with a transverse linear incision. The tentorium was coagulated well and divided posterior to the fistula. A red enlarged vein was found in the ambient cistern. Following the vein, the tentorial incision was extended to the fistula point. After dissection of the draining vein and coagulation of the tentorium around the fistula point, a clip was applied to the vein.

Postoperatively, the patient's symptoms resolved. Complete occlusion of the DAVF was confirmed by angiography before discharge (Fig. 1d).

Patient 6

A 52-year-old female presented with chronic intractable headaches. MRI showed the presence of multiple dilated abnormal vessels, which were mainly located in the left perimesencephalic cistern (Fig. 1e). Angiography revealed a tentorial edge DAVF supplied by the tentorial artery and middle meningeal artery. The fistula drained into the basal vein of Rosenthal or its tributaries. Retrograde flow of the dilated internal cerebral vein and internal occipital vein was also demonstrated (Fig. 1f–g).

Skin incision, craniotomy, and dural incision were performed on the left side as presented above (Video 2, Supplement Digital Video 2, which demonstrates the clipping of the DAVF draining vein). The ambient cistern was widely opened. The tentorium was cut posterior to the fistula. Intraoperative micro-Doppler sonography indicated the flow direction of some dilated red veins. After dissection of the

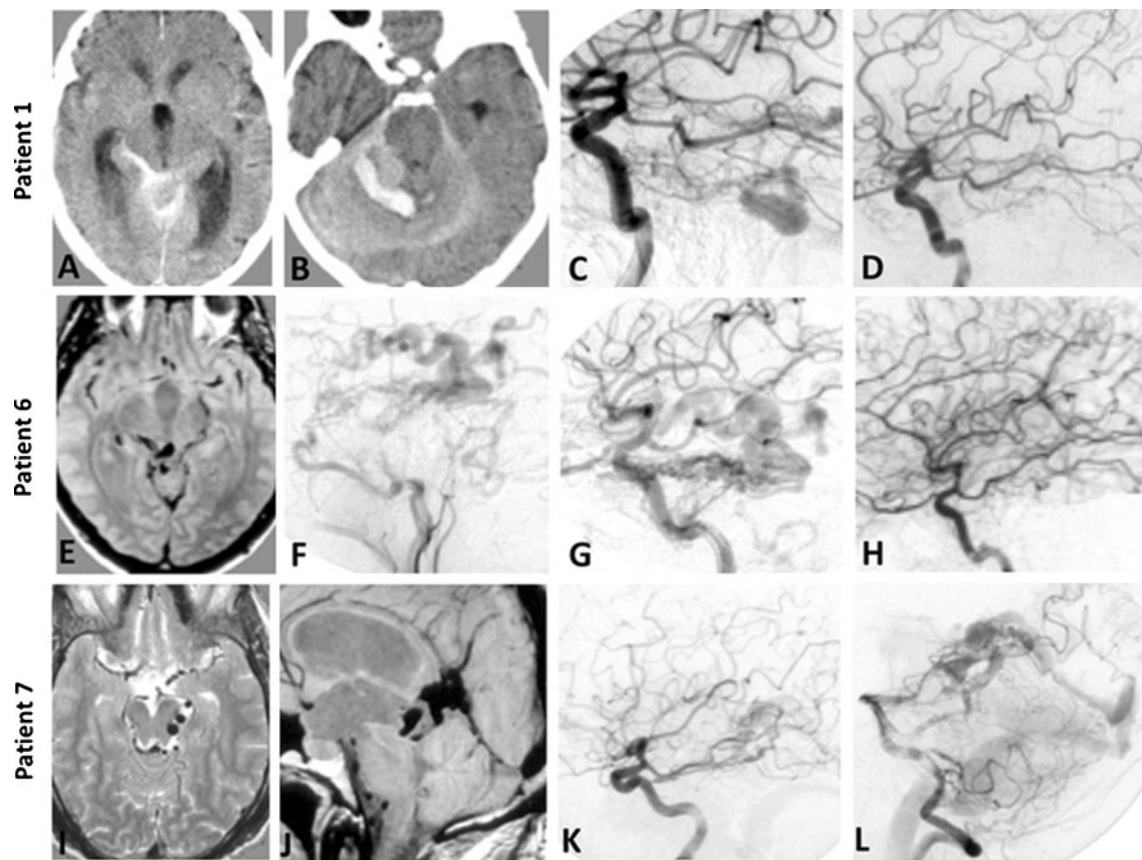


Fig. 1 Pre- and postoperative images of patient 1 (a–d), 6 (e–h) and 7 (i–l). Patient 1: Preoperative CT scan demonstrated subarachnoid hemorrhage, right intracerebellar hemorrhage, and multiple dilated abnormal vessels in the right perimesencephalic and peripontine cisterns (a–b), and digital subtracting angiography (DSA) of the internal carotid artery (ICA) showed the DAVF in a sagittal view (c). Postoperative DSA of the ICA confirmed successful occlusion of the DAVF (d). Patient 6: Preoperative MRI showed the presence of multiple dilated,

abnormal vessels mainly in left perimesencephalic cistern (e) and DSA of the external carotid artery (ECA) (f) and ICA (g) (both sagittal view) showed the DAVF. Postoperative DSA of the ICA (h) confirmed successful occlusion of the DAVF. Patient 7: Preoperative MRI showed the presence of multiple dilated abnormal vessels in the right perimesencephalic cistern in axial (i) and sagittal planes (j). DSA of the ICA (k) and left vertebral artery (VA) (l) (both in sagittal view) showed the DAVF

abnormal veins and extension of the tentorial incision posteriorly, an arterialized large vein continuing to the tentorium was identified. The wall of the arterialized vein was coagulated to shrink and strengthen. This procedure facilitated dissection and identification of the surrounding structures. An aneurysm clip was placed on the proximal portion of the vein. Pulsation of the tentorium around the fistula point did not disappear after clip placement; therefore, the surrounding tentorium was coagulated further and another clip was added. Postoperatively, the patient's headache resolved. Complete occlusion of DAVF was confirmed by angiography before discharge (Fig. 1h).

Patient 7

A 48-year-old male presented with tinnitus and memory disturbances. MRI showed multiple dilated abnormal vessels in the right perimesencephalic cistern (Fig. 1i–j). Angiography

revealed a tentorial apex DAVF supplied by the tentorial artery, posterior cerebral artery, and superior cerebellar artery. The fistula drained into the vein of Galen (Fig. 1k–l). A DAVF adjacent to the torcular, fed by the occipital artery, was also found (Borden type I). Surgery was performed via a right subtemporal approach because of the location of all draining veins on the right side of the perimesencephalic cistern.

Skin incision, craniotomy, and dural incision were performed as presented above (Video 3, Supplement Digital Video 3, which demonstrates the clipping of the DAVF draining vein). Multiple red shining veins were observed in the ambient cistern and blocked the approach to the tentorial apex, even after division of the tentorium. A tentorial edge DAVF was disclosed intraoperatively. The drainage vein of this DAVF was coagulated and cut at the initial stage of the operation. After dissection of the abnormal veins and extension of the tentorial incision posteriorly, an arterialized large vein continuing to the tentorial apex was identified. The

arterialized vein was coagulated as in case 6. The tentorium around the fistula point was well coagulated. A clip was placed on the vein near to the fistula point. Postoperatively, the patient's tinnitus disappeared. Complete occlusion of DAVF was confirmed by angiography.

Discussion

Tentorial DAVF are relatively rare and complex lesions located deep within the brain, with unusual vascular anatomy and surrounded by critical neuroanatomy. If tentorial DAVF cannot be completely occluded by embolization or at least converted to a fistula type higher than Borden type II, then surgery is recommended [11]. Lawton et al. [4] categorized tentorial DAVF into six subtypes (galenic, straight sinus, torcular, tentorial sinus, superior petrosal sinus, incisura) based on anatomic location, dural base, associated sinus, and direction of venous drainage. In their classification, incisural DAVFs are located along the free edge of the tentorium and are not clearly associated with the venous sinus, draining into venous tributaries of the basal vein of Rosenthal and lateral mesencephalic veins. Galenic DAVF is located in the midline at the posterior margin of the tentorial incisura, associated with the vein of Galen as it enters the anterior falcotentorial junction. The fistula usually drains into the basal vein of Rosenthal and precentral cerebellar vein. According to this classification, our cases 2, 7, and 9 are Galenic DAVF, and the other six cases are incisura DAVF. On MRI or CT imaging, all of our nine tentorial DAVF included some venous dilatation or varices in the perimesencephalic cistern as described in the tentorial edge DAVF series of Zhou et al. [8]. In contrast, other types of tentorial DAVF are rarely associated with the perimesencephalic venous drainage [4]. The perimesencephalic venous dilatation or varix observed on MRI is important in predicting tentorial DAVF located around the tentorial incisura. Lawton et al. [4] reported that tentorial edge DAVF had the lowest incidence and that it has not been well characterized in the literature. However, this type of tentorial DAVF was the most frequent in our series (6 patients; 67 %) and in the consecutive series of Zhou et al. [8] (3 out of 5). The incidence of this type of tentorial DAVF may be relatively common, if the fistula point of tentorial DAVF were more easily recognized.

Operative technique of tentorial edge DAVF

Most of the tentorial edge DAVF drain into the dilated perimesencephalic vein and empty into the vein of Galen and the straight sinus. However, when the vein of Galen and/or straight sinus are occluded, the venous outflow can be more complex and include supratentorial and infratentorial outflows as in case 6. Many approaches including the subtemporal,

pterial-transsylvian, orbitozygomatic-pterial, extradural transanteriopetrous, and extended retrosigmoid approach have been reported in this type of DAVF [4, 6–8, 13]. In our series, all unilateral tentorial edge DAVF were accessible through a subtemporal approach with transtentorial access to the fistula site. Only one patient needed an anterior petrosectomy to expose the fistula point sufficiently. Complete radiological obliteration of DAVF was accomplished without any complications or morbidity. The subtemporal approach has the advantage of a very short skin incision with a minimal craniotomy compared to other possible approaches. This will lead to excellent cosmetic results; however, it will not reflect the surgical results. We were able to reach the tentorial edge lesions at the shortest distance and visualized the widest horizontal field. The exposure can be widened by cutting the tentorium or with an anterior petrosectomy. The coagulation and division of the tentorium adjacent to the fistula point was effective not only to visualize the point but also to reduce the shunt flow and the tension of the dilated veins. This procedure facilitated interruption of the fistula. The primary goal of surgery is to occlude the venous outlet rather than excise the dural nidus or handle the ecstatic abnormal veins. However, sufficient coagulation of the tentorium may be necessary to confirm the success in the treating a high-flow DAVF as presented in case 6.

The pterional-transsylvian approach with or without orbitozygomatic addition is an alternative routine approach used for this type of tentorial DAVF. Karkarla et al. [7] recommend the orbitozygomatic approach when the fistula is located in the anterior third of the tentorium. Although almost all perimesencephalic cisterns can be exposed through a subtemporal approach, the exposure of the ambient and quadrigeminal cistern is highly elaborate through a transsylvian approach [14]. The transsylvian approach is only recommended for lesions in the anterior incisura space.

Operative technique of tentorial apex DAVF

Tentorial apex DAVF is the most complex tentorial DAVF. This type of DAVF has the deepest and highest location and is supplied by arteries originating from all directions (bilateral), and venous outflow can be difficult to decipher. Liu et al. [15] pointed out the importance of occluding venous outflow to obliterate intracranial DAVFs. Many authors have recently recommended the simple interruption of the draining vein as close to the fistula as possible, for most intracranial and spinal DAVF [4–8]. Some authors recommend skeletonization of the straight sinus with interruption of the draining vein for the tentorial apex DAVF only [4, 13]. We used the subtemporal approach in two patients with tentorial apex DAVF. Although we accomplished complete obliteration without any permanent morbidity in both cases, one patient experienced a

temporal hemorrhage, due to extensive retraction of the temporal lobe for tentorial apex exposure. Furthermore, the fistula point of tentorial apex DAVF are found predominantly behind many complex, dilated veins, and therefore increased exposure is necessary. Venous infarction and edema following retraction of temporal lobe and venous injury are also potential risks of this approach. The risk can be reduced by including a lumbar drainage, placing the lower margin of the craniotomy and carefully preserving the bridging veins as well as the vein of Labe. However, the subtemporal approach can only be recommended for highly skilled surgeons in this type of DAVF. We used the supracerebellar infratentorial approach in our third case with tentorial apex DAVF because of bilateral feeding arteries and draining veins, and we were able to interrupt the draining veins without any complications. Although, some complex cases may require skeletonization of the sinus, other cases can be treated less invasively with the subtemporal or supracerebellar infratentorial approaches. The overall experience in tentorial apex DAVF is relatively limited; therefore, multiple approaches are possible, and a gold standard has not been established yet. With the essential preoperative evaluation of the fistula point and venous anatomy, the decision for the optimal approach and minimal invasive surgery can be determined while maintaining high cure rates with low or no morbidity.

Conclusions

Using the appropriate preoperative evaluation, tentorial DAVF adjacent to the tentorial incisura can be successfully treated with optimal and minimally invasive microsurgery. The subtemporal approach for unilateral tentorial DAVF is a favorable and direct approach for the highly skilled surgeon.

Disclosure No funding or industrial financial support was received for this study.

References

- Cognard C, Gobin YP, Pierot L et al (1995) Cerebral dural arteriovenous fistulas: clinical and angiographic correlation with a revised classification of venous drainage. *Radiology* 194(3):671–680
- Awad IA, Little JR, Akarawi WP, Ahl J (1990) Intracranial dural arteriovenous malformations: factors predisposing to an aggressive neurological course. *J Neurosurg* 72(6):839–850
- Borden JA, Wu JK, Shucart WA (1995) A proposed classification for spinal and cranial dural arteriovenous fistulous malformations and implications for treatment. *J Neurosurg* 82(2):166–179
- Lawton MT, Sanchez-Mejia RO, Pham D, Tan J, Halbach VV (2008) Tentorial dural arteriovenous fistulae: operative strategies and microsurgical results for six types. *Neurosurgery* 62(3 Suppl 1):110–124, discussion 124–115

- Lewis AI, Rosenblatt SS, Tew JM Jr (1997) Surgical management of deep-seated dural arteriovenous malformations. *J Neurosurg* 87(2):198–206
- Tomak PR, Cloft HJ, Kaga A, Cawley CM, Dion J, Barrow DL (2003) Evolution of the management of tentorial dural arteriovenous malformations. *Neurosurgery* 52(4):750–760, discussion 760–752
- Kakarla UK, Deshmukh VR, Zabramski JM, Albuquerque FC, McDougall CG, Spetzler RF (2007) Surgical treatment of high-risk intracranial dural arteriovenous fistulae: clinical outcomes and avoidance of complications. *Neurosurgery* 61(3):447–457, discussion 457–449
- Zhou LF, Chen L, Song DL, Gu YX, Leng B (2007) Tentorial dural arteriovenous fistulas. *Surg Neurol* 67(5):472–481, discussion 481–472
- Jiang C, Lv X, Li Y, Zhang J, Wu Z (2009) Endovascular treatment of high-risk tentorial dural arteriovenous fistulas: clinical outcomes. *Neuroradiology* 51(2):103–111
- Lucas CP, Zabramski JM, Spetzler RF, Jacobowitz R (1997) Treatment for intracranial dural arteriovenous malformations: a meta-analysis from the English language literature. *Neurosurgery* 40(6):1119–1130, discussion 1130–1112
- Davies MA, TerBrugge K, Willinsky R, Coyne T, Saleh J, Wallace MC (1977) The natural history and management of intracranial dural arteriovenous fistulae, part 2: aggressive lesions. *Interv Neuroradiol* 3:303–311
- Collice M, D'Aliberti G, Arena O, Solaini C, Fontana RA, Talamonti G (2000) Surgical treatment of intracranial dural arteriovenous fistulae: role of venous drainage. *Neurosurgery* 47(1):56–66, discussion 66–57
- Lucas CP, De Oliveira E, Tedeschi H et al (1996) Sinus skeletonization: a treatment for dural arteriovenous malformations of the tentorial apex. Report of two cases. *J Neurosurg* 84(3):514–517
- Ulm AJ, Tanriover N, Kawashima M, Campero A, Bova FJ, Rhoton A Jr (2004) Microsurgical approaches to the perimesencephalic cisterns and related segments of the posterior cerebral artery: comparison using a novel application of image guidance. *Neurosurgery* 54(6):1313–1327, discussion 1327–1318
- Liu JK, Dogan A, Ellegala DB, Carlson J, Nesbit GM, Barnwell SL, Delashaw JB (2009) The role of surgery for high-grade intracranial dural arteriovenous fistulas: importance of obliteration of venous outflow. *J Neurosurg* 110(5):913–920

Comments

Alessandro Ducati, Torino, Italy

The topic of this paper (surgical treatment of incisural DAVF) is a very complex one, for several reasons:

(a) The incidence of these fistulas is so infrequent, that large series are not available in the literature, and consequently a well tested treatment strategy has not been set yet.

(b) Neuroradiological treatment techniques are evolving, and the recent introduction of Onyx into the neuroradiological armamentarium has changed the approach in these years. Nowadays, many DAVF, also in the peri-incisural region, are treated by means of transarterial Onyx. This seems to have increased the rate of cure as compared to transvenous embolization. The Authors do not specify if the failed endovascular attempts to obliterate the DAVF had been carried out via a transarterial or transvenous approach. In any case, the patients reported underwent three unsuccessful endovascular procedures before being considered for surgery; this means that a subset of patients not amenable of endovascular treatment still exists, and needs surgery.

(c) The surgical approaches for patients presenting with peri-incisural DAVF may be extremely different, and the Authors discuss this point in their paper. Their arguments in favor of a subtemporal approach (for unilateral DAVF) are that it is the shortest way to reach the fistula, and that it allows a wider exposition of the tentorium, that must be cut and opened posterior to the fistula, for the need of an extensive coagulation. On the other hand, the subtemporal approach is a very delicate one (particularly on the left side), and it requires an absolute respect of the normal draining veins, especially the Labbé vein. Furthermore, the retraction of the temporal lobe must be minimized both in terms of quantity and of duration, to avoid postoperative complications (only one case of temporal hematoma in this series, without clinical consequences). For bilateral DAVF, the supracerebellar infratentorial approach has been used.

(d) The identification of the vein draining the fistula may not be so easy, particularly when operating among dilated veins in narrow spaces. The suggestion to use a micro-Doppler sonograph to detect the direction of flow is a useful one and must be kept in mind; moreover, the indocyanine green angiography may also be very helpful, both to identify the fistula and to control the efficacy of the surgery.

In conclusion, even in this neuroradiological era, there is a residual number of patients with peri-incisural DAVF who are not amenable of endovascular obliteration and who require surgical treatment. The subtemporal transtentorial approach has been demonstrated by the authors to allow an effective, although delicate, access to the fistula.

Kazuhiro Hongo, Matsumoto, Japan

This is a paper describing the surgical treatment of tentorial dural arteriovenous fistulae (dAVF) located at around the tentorial incisura. The authors nicely documented the operative techniques as well as the results of their cases. Congratulations on their good results: the dAVF of this region is deep, and via either approach complete obliteration needs high surgical skills, the dilated draining veins might interfere the surgical approach. As the authors described, lumbar drainage is needed to lessen the temporal retraction. Approaching from the posterior side rather than from the anterior side might be closer and easier to reach the tentorial edge with less temporal retraction.

I. Erol Sandalcioglu, Essen, Germany

Dural arteriovenous fistulas (DAVF) of the tentorium and its medial edge leading to early cortical venous drainage are at an increased risk for bleeding and thereby, bleeding related morbidity. Treatment options must be balanced in an interdisciplinary concept regarding the efficacy

and risks of endovascular and microsurgical methods. The goal must be complete elimination of the fistulous complex at the venous site, which requires exact analysis and identification of the DAVF point.

The authors present their experience of a series of surgically treated DAVF of the tentorial incisura using mainly the subtemporal approach. This approach provides an excellent exposure of the temporo-mesial structures and the lateral surface of the brainstem including important arterial and venous vessels. They point out important variants of this approach in order to achieve optimal exposure of the fistulous point.

In my opinion, in most cases, such lesions can be approached by standard craniotomies as the subtemporal, retromastoidal retrosigmoidal, or suboccipital supracerebellar approach with incision of the tentorium, if necessary. In the past, time-consuming combined supra- and infratentorial transpetrosal craniotomies were used to access tentorial DAVF; however, these complex approaches were abandoned towards standard procedures, not least based on a better understanding of the pathomorphological pattern.

Similarly to the observations by Hatano and colleagues, the efficacy of endovascular procedures is less compared to microsurgery, thus, their report provide an important contribution to improve the results in the treatment of tentorial DAVF.

Miguel Arraez, Malaga, Spain

This article from Taketo Hatano and cols. deserves special interest. They review the surgical treatment of nine arteriovenous dural tentorial malformations, specifically near the tentorial incisura. All the described cases are type III according to the Borden classification. Due to the anatomical configuration of the lesions in that particular area there is clear indication for treatment due to high risk of bleeding. As the initial endovascular approach had failed in all patients, surgery was undertaken. No morbidity or mortality was observed after surgical treatment. The key point of the article is the surgical treatment of this kind of lesions through subtemporal approach, done in all cases but one in which the obliteration of the fistula was carried out through a supracerebellar infratentorial approach. It is noteworthy that this simple and easy temporal craniotomy and subtemporal route can solve almost all the tentorial dural arteriovenous malformations. The surgical approach and details of the technique has also been nicely described step by step giving more value to this article. The good results of the surgical treatment in this series of patients would contribute to encourage neurosurgeons to avoid leaving surgically untreated this condition when the less invasive endovascular treatment is not feasible.