

VZV retinal vasculitis without systemic infection: diagnosis and monitoring with quantitative polymerase chain reaction

Yves Wimmersberger · A. Gervais · Edoardo Baglivo

Received: 24 December 2007 / Accepted: 22 September 2008 / Published online: 14 October 2008
© Springer Science+Business Media B.V. 2008

Abstract To report a case of unilateral varicella zoster virus (VZV) retinal vasculitis aspect in an immunocompetent child without systemic infection. Clinically, no signs of retinal necrosis or frosted branch vasculitis were present. This is an observational case report. Quantitative PCR was performed on the aqueous humor (AH) using primers specific for herpes virus (cytomegalovirus, Epstein-Barr virus, herpes simplex virus 1–2, and VZV). The patient was treated with intravenous acyclovir, intravitreal ganciclovir, and oral valacyclovir. A positive quantitative PCR result was found for VZV DNA (1.72×10^6 viral copies/ml) in the AH. After 6 months, PCR of the AH was negative. Herpes viruses are involved in the pathogenesis of isolated retinal vasculitis. This case demonstrates that quantitative PCR is useful to detect viral DNA in AH and to monitor the viral activity and the therapeutic response.

Keywords Varicella zoster virus · Vasculitis · Uveitis · Acyclovir · Infection · Polymerase chain reaction

Introduction

Retinal vasculitis rarely occurs as an isolated disorder, but is usually associated with systemic disease manifestations. Herpes simplex virus (HSV) and varicella zoster virus (VZV) belong to the herpesviridae family and affect many ocular tissues (blepharitis, conjunctivitis, scleritis, keratitis, anterior uveitis, and retinitis). Usually infections of the posterior segment are associated with a retinal involvement, leading to severe ocular morbidity and visual impairment. Isolated herpetic ocular vasculitis is rare [1, 2]. We describe a patient with unilateral retinal vasculitis caused by VZV without systemic infection.

Case report

An 11-year-old girl presented after 4 days of progressive visual loss and photophobia affecting her right eye (RE). Her past medical history was unremarkable.

Ophthalmic examination revealed a visual acuity of 20/50 RE and 20/20 in her left eye (LE) without correction. A mild granulomatous inflammation was present in the right anterior segment. Intraocular pressure was 22 mmHg in the RE and 15 mmHg in the LE. The right fundus examination revealed vitritis (2+ cells), a diffuse retinal edema and enlarged vessels (Fig. 1). The left fundus examination was unremarkable (Fig. 2). Fluorescein angiography (FA) disclosed a massive staining of the retinal vessels and

Y. Wimmersberger · E. Baglivo (✉)
Clinique d'Ophtalmologie—Uveitis Department,
Hôpitaux Universitaires de Genève, rue Alcide-Jentzer,
22, 1205 Geneva, Switzerland
e-mail: Edoardo.Baglivo@hcuge.ch

A. Gervais
Department of Pediatrics, University Hospitals of Geneva,
Geneva, Switzerland

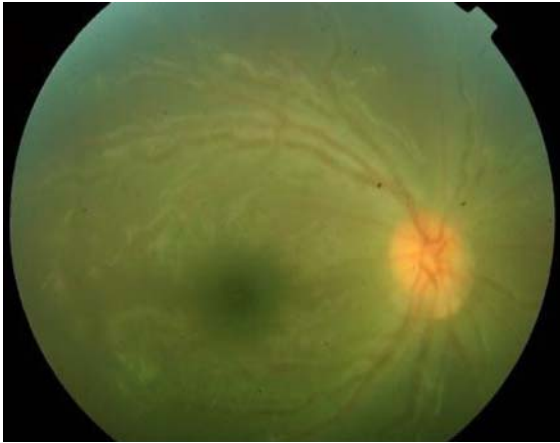


Fig. 1 Fundus photography of the right eye showing perivascular sheathing and vitritis

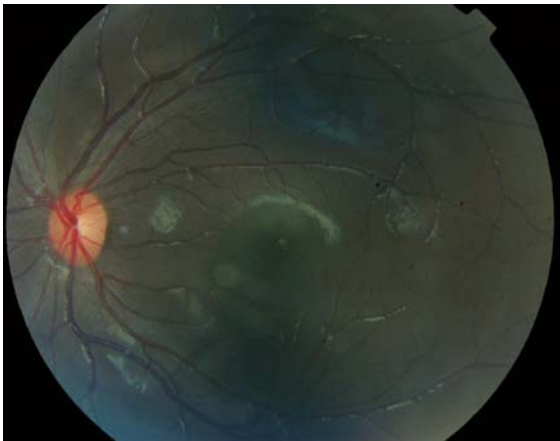

Fig. 2 Fundus photography of the left eye with normal posterior pole findings

optic disc with a diffusion of the dye on the late frames (Fig. 3). The clinical picture led us to suspect a viral infection, and the patient was hospitalized.

The day of admission, we performed an anterior chamber tap with PCR for HSV1, HSV2, VZV, CMV, EBV, and toxoplasmosis. The patient was treated with intravenous (iv) acyclovir (3×10 mg/kg/8 h), and a single intravitreal ganciclovir injection (2,000 μ g) was administered. Topical steroids and mydriatics were prescribed, too.

A workup revealed an ESR of 7 mm/h ($N = 1$ –12) and a normal white blood count. Immunoglobulin electrophoresis, quantitative immunoglobulin levels, and tests for connective tissue disorders and sarcoidosis were negative.

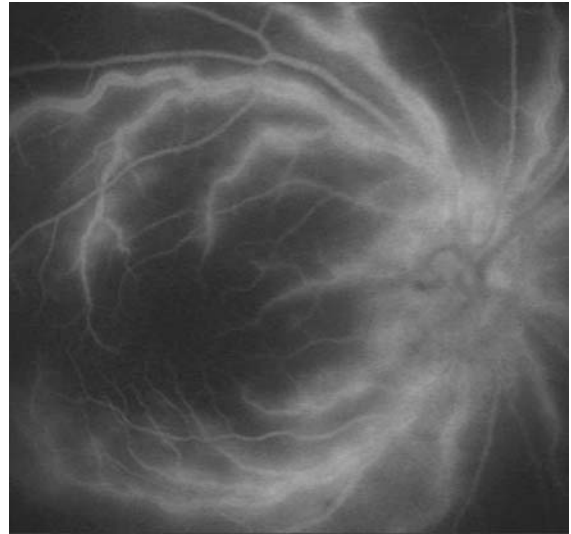


Fig. 3 Fluorescein angiography of the right eye showing vascular leakage and vessel staining

Infectious serologies (*Borrelia burgdorferi*, *Treponema pallidum*, HIV, leptospirosis, rickettsiosis, brucellosis, and toxoplasmosis) were negative. Serologies for herpes virus revealed a past exposition to herpes virus (HSV IgG 1.82, $N < 0.2$ and IgM 0, $N < 0.2$ – VZV IgG 3.42, $N < 0.2$ and IgM 0.52, $N < 0.2$).

After 1 week, quantitative PCR analysis of the AH was reported positive for VZV DNA 1.72×10^6 viral copies/ml.

Acyclovir treatment was continued for 10 days iv, then orally for 3 months. Oral steroids (prednisone 1 mg/kg) were prescribed at tapering doses for 1 month. No systemic (blood count, renal function) or local adverse effects were observed. Progressively, complete regression of the vitreous inflammation was observed. After 6 weeks, FA revealed a complete resolution of the vascular inflammation (Fig. 4). In September 2006, another anterior chamber tap was performed showing a negative PCR for all herpes viruses. Final visual acuity was 20/20 in both eyes. The patient was followed for 24 months. No ocular complications were recorded, and no bilateralization of the infection was observed.

Discussion and conclusion

Chickenpox and herpes zoster are caused by VZV and can be associated with cutaneous and non-

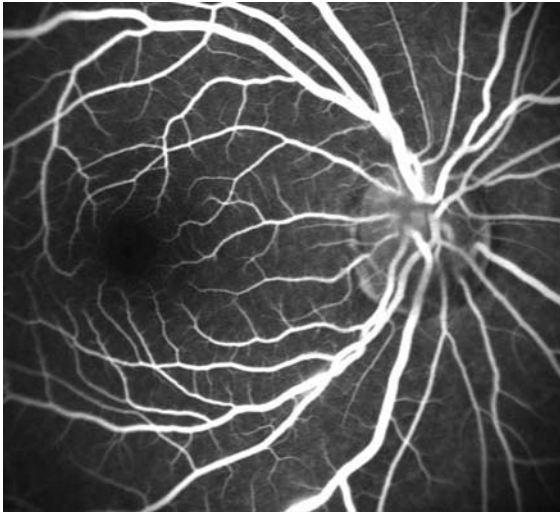


Fig. 4 Fluorescein angiography of the right eye at the last follow-up

cutaneous complications, including encephalitis, pneumonitis, and intraocular inflammation. Primary VZV infection can cause corneal lesions, uveitis, optic neuritis, and chorioretinitis, which usually induces a necrosis of the neuroretina (acute retinal necrosis, progressive outer retinal necrosis). Non-necrotic viral vasculites have been described in patients with either systemic HSV1 or HSV2 infection or with chickenpox [3–6] in patients with clinical features resembling frosted branch angiitis (FBA) [7]. In this case of primary VZV infection (young age, elevated VZV IgM and VZV IgG), there were no signs and history of acute or post-acute chickenpox, and the inflammation affected only the RE. Clinically, the vascular involvement did not resemble FBA, and retinal necrosis was absent.

We are unaware of previous reports of isolated retinal vasculitis without retinal necrosis from VZV. In this case, the diagnosis was made by analyzing the AH by PCR. While a positive PCR result cannot differentiate between an acute or past infection and thus cannot by itself give a definitive diagnosis of a causative viral agent, the fact that the retinal vasculitis resolved after antiviral therapy provides strong

evidence of the correlation of the clinical features with the PCR results (VZV vasculitis).

Recently, Rothova et al. demonstrated the usefulness of AH analysis for diagnosing posterior uveitis, revealing an infectious cause in 29% of patients [8]. In this paper, PCR was negative for virus in retinal vasculitis (0/10 cases); their results support the rarity of the present reported case.

This case shows that AH-PCR in suspected atypical viral retinal vasculitis without systemic involvement and without retinal necrosis can be helpful in the diagnosis and management of the disease, preventing severe sequelae and leading to good visual outcome.

References

1. Culbertson WW, Dix RD (1996) Varicella-zoster virus diseases: posterior segment of the eye. In: Pepose J, Holland GN, Wilhelmus KE (eds) *Ocular infection and immunity*. Mosby, St. Louis, pp 1131–1153
2. Walton RC, Ashmore ED (2003) Retinal vasculitis. *Curr Opin Ophthalmol* 14:413–419. doi:10.1097/00055735-200312000-00015
3. Miyazaki H, Kitarah K, Anazawa K, Noji J, Yamaguchi M, Imai Y (1982) A case of retinal vasculitis and uveitis as the complications of chickenpox. *Ganka* 24:1451–1454
4. Kuo YH, Yip Y, Chen SN (2001) Retinal vasculitis associated with chickenpox. *Am J Ophthalmol* 132:584–585. doi:10.1016/S0002-9394(01)01058-3
5. Markomichelakis NN, Barampouti F, Zafirakis P, Chalkiadakis I, Kouris T, Ekonomopoulos N (1999) Retinal vasculitis with a frosted branch angiitis-like response due to herpes simplex virus type 2. *Retina* 19(5):455–457. doi:10.1097/00006982-199919050-00019
6. Chatzoulis DM, Theodosiadis PG, Apostolopoulos MN, Drakoulis N, Markomichelakis NN (1997) Retinal perivasculitis in an immunocompetent patient with systemic herpes simplex virus infection. *Am J Ophthalmol* 123:699–702
7. Ito Y, Nakano M, Kyu N, Takeuchi M (1976) Frosted branch angiitis in a child. *Rinsho Ganka. Jpn J Clin Ophthalmol* 30:797–803
8. Rothova A, de Boer JH, Ten Dam-van Loon NH, Postma G, de Visser L, Zuurveen SJ et al (2008) Usefulness of aqueous humor analysis for the diagnosis of posterior uveitis. *Ophthalmology* 115(2):306–311. doi:10.1016/j.ophtha.2007.05.014