

# New approaches to the study of human brain networks underlying spatial attention and related processes

Jon Driver · Felix Blankenburg · Sven Bestmann ·  
Christian C. Ruff

Received: 2 February 2010 / Accepted: 18 February 2010 / Published online: 31 March 2010  
© The Author(s) 2010. This article is published with open access at Springerlink.com

**Abstract** Cognitive processes, such as spatial attention, are thought to rely on extended networks in the human brain. Both clinical data from lesioned patients and fMRI data acquired when healthy subjects perform particular cognitive tasks typically implicate a wide expanse of potentially contributing areas, rather than just a single brain area. Conversely, evidence from more targeted interventions, such as transcranial magnetic stimulation (TMS) or invasive microstimulation of the brain, or selective study of patients with highly focal brain damage, can sometimes indicate that a single brain area may make a key contribution to a particular cognitive process. But this in turn raises questions about how such a brain area may interface with other interconnected areas within a more extended network to support cognitive processes. Here, we provide a brief overview of new approaches that seek to characterise the causal role of particular brain areas within networks of several interacting areas, by measuring the effects of

manipulations for a targeted area on function in remote interconnected areas. In human participants, these approaches include concurrent TMS-fMRI and TMS-EEG, as well as combination of the focal lesion method in selected patients with fMRI and/or EEG measures of the functional impact from the lesion on interconnected intact brain areas. Such approaches shed new light on how frontal cortex and parietal cortex modulate sensory areas in the service of attention and cognition, for the normal and damaged human brain.

**Keywords** Attention · fMRI · Lesion · TMS-fMRI · TMS · Neglect · Extinction · Parietal · FEF

## Introduction

Observations on neurological patients exhibiting the spatial neglect syndrome after brain damage, as studied for instance by Pizzamiglio and his colleagues (e.g., Bisiach et al. 1996; Guariglia et al. 1993; Robertson et al. 1997), have provided crucial lines of evidence on the brain basis of spatial cognition and attention. Understanding and treating the disabling deficits of such patients (e.g., Pizzamiglio et al. 1990, 1992, 1998) is of major importance in its own right, as considered by some of the other contributions in this special issue (e.g., Cappa and Perani, this volume). Studies of neglect patients have also shed light on the network of brain areas that may be implicated in *normal* spatial cognition and attention, based on the typical (and often extensive) lesions in neglect. Lesion evidence implicates an extensive network of brain areas in neglect. The regions typically affected include frontal, parietal and superior temporal cortex, primarily in the right-hemisphere, plus underlying and interconnecting white-matter (e.g., Karnath et al. 2001, 2004;

---

J. Driver · C. C. Ruff  
Wellcome Trust Centre for Neuroimaging and UCL Institute of Cognitive Neuroscience, University College London, 12 Queen Square, London WC1N 3BG, UK

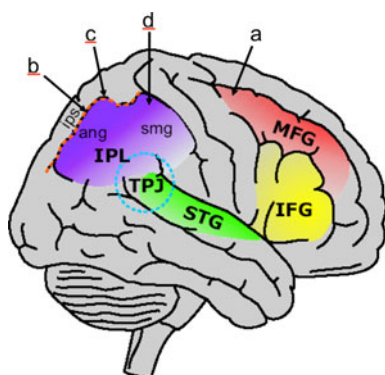
F. Blankenburg  
Department of Neurology and Bernstein Center for Computational Neuroscience, Charité Universitätsmedizin Berlin, Berlin, Germany

S. Bestmann  
Sobell Department of Motor Neuroscience and Motor Disorders, UCL Institute of Neurology, University College London, London, UK

C. C. Ruff (✉)  
Laboratory for Social and Neural Systems Research, IEW, University of Zurich, Zurich, Switzerland  
e-mail: ruff@iew.uzh.ch; c.ruff@ucl.ac.uk

Mort et al. 2003; Vallar 2001; Verdon et al. 2009). See Fig. 1 for a schematic illustration.

A second line of evidence, in which Pizzamiglio and colleagues have also long been active (e.g., see Vallar et al. 1999; Galati et al. 2000), concerns functional neuroimaging data, typically PET or fMRI data, from neurologically healthy subjects as they carry out specific cognitive tasks. This very different type of evidence has also often suggested that extensive brain networks may underlie spatial cognition (e.g., Vallar et al. 1999) and spatial attention (e.g., Corbetta and Shulman 2002; Driver et al. 2004). Moreover, there has often been considerable overlap between those brain networks found in fMRI studies of spatial cognition and attention in healthy participants, with those implicated by the extensive brain lesions of typical neglect patients (e.g., Husain and Rorden 2003; Driver et al. 2004); see again the schematic in Fig. 1. Taken together, such lines of evidence from lesioned patients or functional neuroimaging in neurologically intact subjects have led to the emerging view that rather than single brain areas being identified with single cognitive functions, cognition may be subserved by extended networks of



**Fig. 1** Schematic lateral view of the right-hemisphere of the human brain (adapted from Vuilleumier and Driver 2007, with authors' permission), highlighting some of the many cortical brain regions that have been implicated for possible roles in the unilateral neglect syndrome, based on patients' lesions. Similar regions have also been implicated in attention-related networks, as based on functional neuroimaging in neurologically intact subjects. Indeed, as noted in our main text, the extensive networks implicated by both types of evidence often show considerable overlap. Important subcortical structures and white-matter connections are omitted for simplicity. The *four arrows* at top point schematically to some of the sites targeted in the recent concurrent TMS-fMRI studies that we review in the main text. Here, **a** indicates the right frontal eye fields TMS site of Ruff et al. (2006); **b** indicates the right intra-parietal TMS site of Ruff et al. (2008); **c** indicates the right posterior parietal TMS site of Blankenburg et al. (2010) and **d** indicates the more anterior parietal site of Blankenburg et al. (2008) that was selected to closely match Seyal et al. (1995). We note in passing that these sites all represent fairly 'dorsal' sites within the extensive network that we schematically depict here. Future studies by our own group and others will extend the concurrent TMS-fMRI approach to other potential TMS sites, including more inferior regions

interconnected brain areas (e.g., see Corbetta and Shulman 2002; Driver et al. 2009; Ruff et al. 2009a).

On the other hand, studies that target specific brain areas more selectively have led to suggestions that a given area may play an essential role in a specific cognitive process. In research with human participants, transcranial magnetic stimulation (TMS) has often been used to target specific brain areas (provided they are near enough to the surface to be approached by TMS) in order to test such hypotheses (e.g., for reviews, see Walsh and Pascual-Leone 2005; Wassermann et al. 2008). In rare cases where invasive electrodes were available for surgical reasons, targeted invasive stimulations have also been possible in a few human patients (e.g., Thiebaut de Schotten et al. 2005), somewhat analogous to microstimulation work in non-human primates (e.g., see Cohen and Newsome 2004). Such interventional approaches have also been supplemented with conventional focal lesion work, either by selecting human patients with unusually focal damage (e.g., Husain et al. 2003), or by experimental (often reversible) lesions in animals (e.g., Lomber and Galuske 2002). These more targeted approaches have led to hypotheses that specific single brain areas may make unique contributions to particular cognitive processes, such as for those aspects of spatial cognition and attention that we consider here. But given the coexisting evidence for more extensive networks of interconnected brain areas (see above and Fig. 1), this then raises the question of how an implicated specific brain area may interact with closely interconnected regions within the same network, as a function of the current task requirements.

In this context, several sophisticated analysis approaches have been developed for application to standard fMRI, EEG or MEG data, which seek to uncover patterns of functional influences or 'effective connectivity' between interconnected brain regions. Such patterns of effective connectivity may relate to particular cognitive processes and may even change dynamically in a task-dependent manner (e.g., Friston et al. 2003; Goebel et al. 2003; Schnitzler and Gross 2005; Valdés-Sosa et al. 2005). But here we focus instead on more *interventional* approaches that target a particular brain area with a causal intervention (e.g., TMS, or microstimulation or even a permanent lesion), while studying the impact on brain function in remote but interconnected areas within a more extended brain network.

### Combining TMS with concurrent fMRI to study causal influences in the brain networks subserving attention and spatial cognition

TMS has been combined with PET (e.g., Fox et al. 1997; Paus et al. 1997; Siebner et al. 1999), but this does not

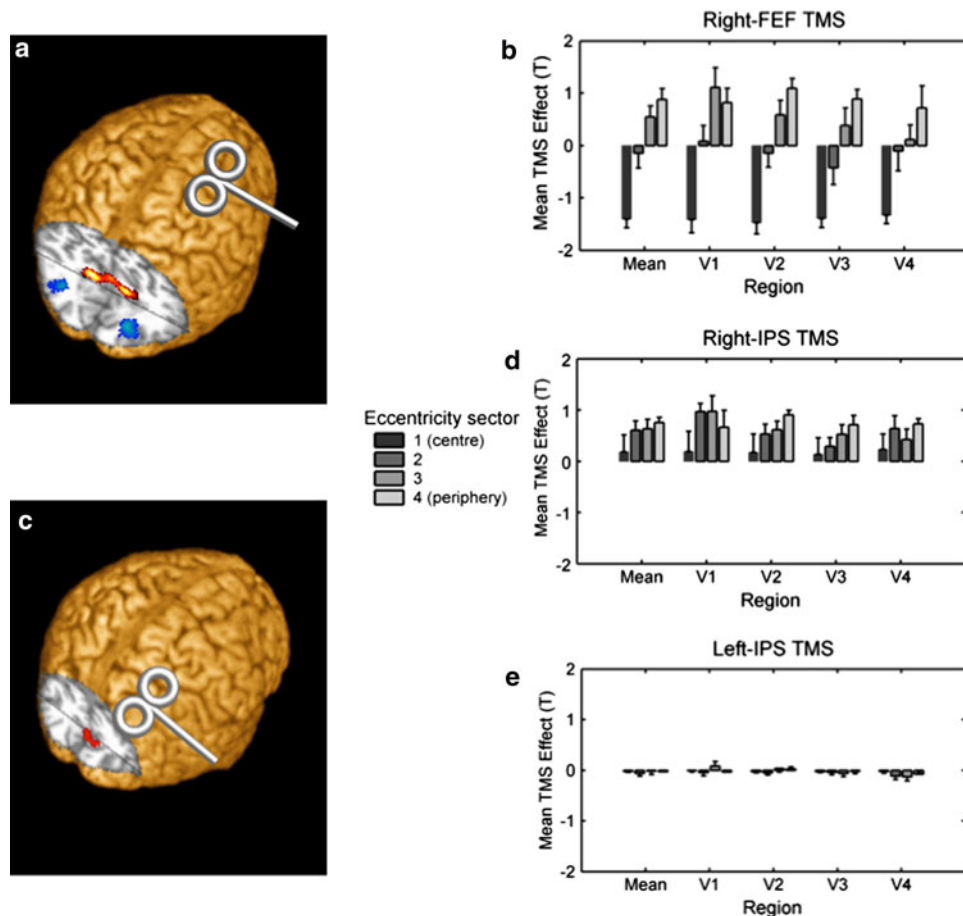
allow the same temporal or anatomical resolution as fMRI. Pioneering studies established the feasibility of combining TMS with fMRI about 10 years ago (e.g., see Bohning et al. 1999). The technical challenges for successfully combining TMS with concurrent fMRI are considerable and are reviewed elsewhere (e.g., Bestmann et al. 2008; Bohning et al. 2003; Siebner et al. 2009; Weiskopf et al. 2009). While the BOLD signals revealed by fMRI may not index all forms of neural activity (Logothetis 2008) and may be insensitive to lower intensity TMS (Bohning et al. 1999), concurrent TMS-fMRI offers the advantage of potentially tracking the causal impact on many brain areas of TMS applied to one or other targeted site. Space constraints preclude an exhaustive review of all concurrent TMS-fMRI studies here. Instead we focus on use of concurrent TMS-fMRI to study the brain basis of spatial attention and spatial cognition, initially describing our own work and then expanding the focus to include potentially related studies.

The frontal eye fields (FEF) have long been implicated as an important node in the so-called ‘dorsal attention network’ (e.g., Corbetta and Shulman 2002), based on converging evidence from patients (e.g., Henik et al. 1994), and from experimental lesions and inactivation in non-human primates (e.g., Lattin and Cowey 1971; Wardak et al. 2006); plus single-cell recordings (e.g., Juan et al. 2004) and purely behavioural TMS work in humans (Grosbras and Paus 2002; Müri and Nyffeler 2008; Neggers et al. 2007; Silvanto et al. 2006). Such work had led to many suggestions that the FEF might play a causal role in modulating selective visual processing. Ruff et al. (2006) set out to test this by combining TMS over right human FEF with concurrent fMRI of retinotopic visual cortex. They found (see Fig. 2a, b) that as the intensity of TMS over right FEF was increased, this affected BOLD signal in occipital visual cortex, for retinotopic areas V1–V4. Specifically, this increased BOLD signal there for representations of the peripheral retinotopic visual field, while having the opposite effect (of decreasing BOLD instead) for retinotopic representations of the central visual field (see Fig. 2b). This might accord with the FEF over-representing the peripheral visual field (due to the role of the FEF in controlling eye-movements and directing covert attention into the visual periphery), leading to an excitatory impact for the peripheral visual field in interconnected early visual cortex when the FEF are stimulated, but a converse effect for central vision. Ruff et al. (2006) went on to show a psychophysical analogue of the remote BOLD effects on visual cortex due to right FEF TMS. Specifically, such TMS increased the perceived contrast of peripheral visual stimuli, relative to central visual stimuli, paralleling the BOLD findings for human visual cortex. Conceptually similar effects have been observed in the non-human

primate brain, as related pioneering work has shown that microstimulation of macaque FEF can lead to corresponding increases in visual responses for single-cells recorded concurrently in V4 (Armstrong and Moore 2007); while more recently FEF microstimulation has been combined with concurrent fMRI in awake monkeys, to reveal modulation of responses in visual cortex (Ekstrom et al. 2008), as well as interconnected parietal cortex.

In follow-up studies, Ruff and colleagues went on to show that stimulating human intraparietal cortex, rather than FEF, led to a distinct pattern of influence upon visual cortex (Ruff et al. 2008); see Fig. 2c, d. Moreover, they subsequently found some right-hemisphere predominance for these remote functional effects in humans (Ruff et al. 2009b); compare Fig. 2d, e. Notably, left-intraparietal TMS had no impact on BOLD signals in visual cortex, quite unlike the robust effects due to right-intraparietal TMS. Right FEF TMS also had more substantial effects on visual cortex than left-FEF TMS. Such lateralisation appears broadly consistent with that found for purely behavioural TMS effects in several visual tasks with humans (e.g., see Grosbras and Paus 2002; O’Shea et al. 2004; Silvanto et al. 2006). It also accords with the extensive clinical evidence from neglect patients for some right-hemisphere predominance in the networks subserving spatial cognition and attention (e.g., see Karnath et al. 2001, 2004; Mort et al. 2003; Vallar 2001; Verdon et al. 2009). Thus, Ruff et al.’s findings with concurrent TMS-fMRI are consistent with the emerging view that parietal cortex has undergone particular hemispheric specialisation in humans (e.g., see Milner and Goodale 1996).

The concurrent TMS-fMRI studies by Ruff and colleagues demonstrate that human FEF, and human parietal cortex, are capable of modulating the response of early visual cortex, in accord with a potential role for these nodes within the proposed ‘attention network’ (see Corbetta and Shulman 2002; Driver et al. 2004) in gating the response of visual cortex. However, in these initial studies, the top-down attentional state of participants was not manipulated during the concurrent TMS-fMRI. Instead, participants in Ruff et al. (2006, 2008, 2009b) merely had to hold central fixation. More recently, Blankenburg et al. (2010) applied TMS over right posterior parietal cortex (PPC) while varying the attentional state of their participants. These participants always viewed equivalent bilateral stimuli, but either maintained covert spatial attention to the left visual field in order to judge stimuli there; or attended covertly to the right visual field in order to judge stimuli there instead; or attended neutrally by simply pressing a button whenever the stimuli appeared. As shown in Fig. 3, the impact of the right PPC TMS on remote brain activations depended strongly on the current attentional state. It increased the BOLD response of right ventral visual cortex (probable V4) when attending



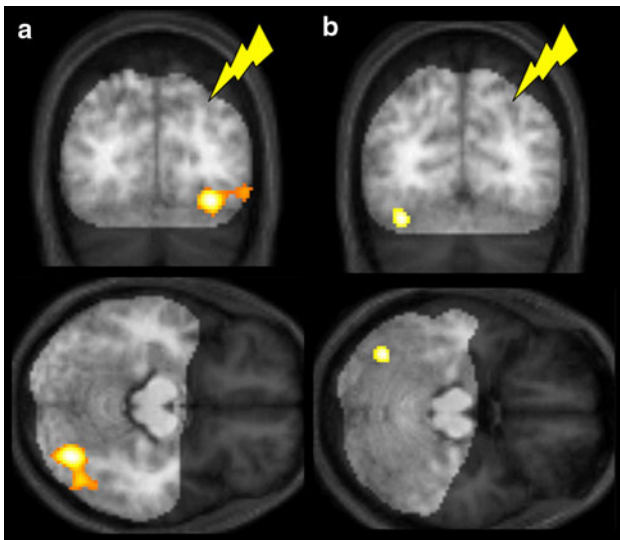
**Fig. 2** **a** and **b** TMS over human right FEF induces a characteristic pattern of BOLD changes in visual areas V1–V4, with BOLD increases for representations of the visual periphery and BOLD decreases for the central visual field. **a** shows a 3D rendering of one illustrative participant's brain, with a schematic TMS coil indicating the approximate TMS site over right FEF (see also Fig. 1a). The cutout slices in occipital cortex show overlays of statistical parametric maps (SPMs) for BOLD changes related to FEF-TMS intensity. Significant activity increases due to increased TMS intensity are marked in *red/yellow*, significant activity decreases in *blue*; these two opposite effects correspond to representations of the peripheral versus central visual field, respectively. **b** shows estimates of right-FEF-TMS effects ( $T$ -values coding correlation of BOLD and TMS intensity) on representations of more central or more peripheral representations of the visual field ('eccentricity sectors') for visual areas V1–V4, as defined by separate individual retinotopic mapping. Activity increases for the more peripheral visual field, but activity decreases for the

central visual field, are found for all retinotopic areas. Note that right FEF TMS had this impact on both right and left visual cortex. **c** 3D rendering of one illustrative participant's brain, with a schematic TMS coil indicating the approximate TMS site over right intraparietal cortex in Ruff et al. (2008). The cutout slices in occipital cortex show overlays of statistical parametric maps (SPMs) for BOLD changes related to FEF-TMS intensity. Significant activity increases due to increased TMS intensity are marked in *red*. **d** Estimates of right-IPS-TMS effects (coded as for **b**) on representations of the more central or more peripheral visual field for visual areas V1–V4, showing increased BOLD signal. Note the different pattern of results to that found with right FEF TMS (compare with **b**); there is no longer a reduced BOLD signal for representations of the central visual field after right-intraparietal TMS. **e** Left intra-parietal TMS had no impact on BOLD signals in retinotopic visual cortex. Data for Fig. 2 taken from Ruff et al. (2006, 2008, 2009b), with authors' permission

left (see Fig. 3a) yet decreased response in the same region when attending right; while having the opposite impact on (opposite-hemisphere) left ventral visual cortex (see Fig. 3b). By contrast, there was no such remote impact of the right PPC TMS during neutral attention. These results show that TMS-fMRI can reveal remote influences between brain areas that change dynamically with purely top-down attentional factors. We attribute the observed pattern of remote TMS effects to the 'effective connectivity' between right PPC and visual cortex changing as a function of the

*current attentional state*, such that stimulation applied over right PPC propagate differentially to interconnected visual cortex, in a manner that changes for different attentional conditions. This evidently can even include inter-hemispheric influences of the right PPC TMS, as for left visual cortex in Fig. 3b.

A further concurrent TMS-fMRI study by Blankenburg et al. (2008) also examined the possible inter-hemispheric impact of right parietal TMS, but now for somatosensory rather than visual responses. Seyal et al. (1995) had



**Fig. 3** In the concurrent TMS-fMRI study by Blankenburg et al. (2010), TMS was applied over right posterior parietal cortex PPC (as indicated schematically by lightning-flash symbols in the coronal views here), while subjects directed covert attention to the left hemifield, or to the right hemifield instead, or attended neutrally (see main text). fMRI data were acquired concurrently, with a posterior MR coil to maximise sensitive for visual cortex (hence we did not acquire BOLD data for more anterior brain regions, e.g., in frontal cortex; the imaged posterior volume is indicated with higher contrast here). High- minus low-intensity right PPC TMS increased BOLD signals in a manner that significantly depended on the currently attended side, as shown in the interaction SPMs superimposed on the image volumes here. When attending left versus right, high minus low-intensity right PPC TMS increased BOLD in right extrastriate visual cortex (**a**), as shown in the coronal and transverse images on the left of the figure here. When attending right versus left, high-versus low-intensity right PPC TMS now increased BOLD in left extrastriate visual cortex instead (**b**), as shown in the images on the right of the figure here. Thus, which visual hemisphere showed increased BOLD signal for higher intensity TMS reversed, depending on the currently attended side. Adapted with authors' permission from Blankenburg et al. (2010)

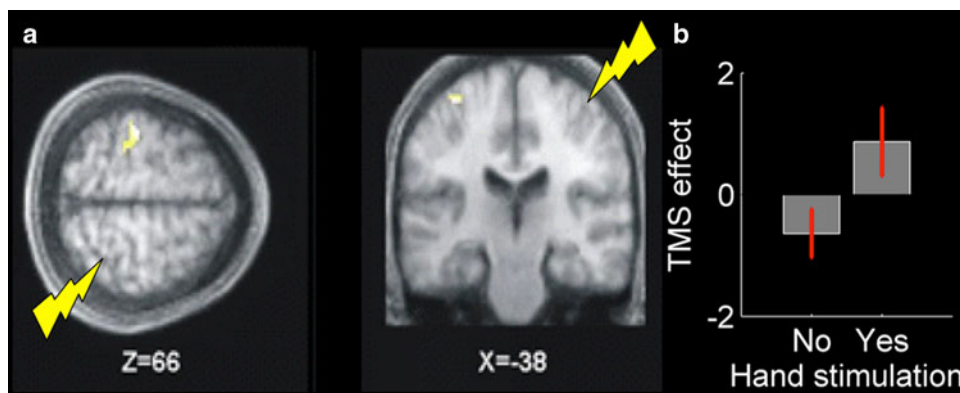
conducted an earlier pioneering behavioural TMS study in relation to possible 'hemispheric rivalry'. Such rivalry is a traditional proposal from behavioural neurology, in relation to phenomena such as the neglect syndrome and unilateral extinction (e.g., see Kinsbourne 1977). Seyal et al. reported that right parietal TMS in neurologically healthy subjects could lead to behavioural enhancement of somatosensory detection on the ipsilateral right hand. They tentatively attributed that result to a remote effect from right parietal TMS upon the (opposite) left-hemisphere response to incoming somatosensory stimulation from the right hand. But since they had used no neural measures, they were unable to demonstrate directly the proposed impact on neural responses in the opposite hemisphere. Blankenburg et al. (2008) used concurrent TMS-fMRI to show that right parietal TMS does indeed enhance the response of left somatosensory cortex (including left S1) to the presence

versus absence of right-hand (electrical) somatosensory input; see Fig. 4. This study further illustrates that concurrent TMS-fMRI can be used to study *inter-hemispheric* influences between interconnected brain regions, addressing issues for the normal brain that can also relate to clinical issues concerning neglect and extinction arising from the study of brain-damaged patients, a topic we return to at the end of this paper.

Several other groups have also combined TMS with fMRI in potentially related work (see e.g., Baudewig et al. 2001; Bohning et al. 2003; Denslow et al. 2005; Kemna and Gembris 2003; Sack et al. 2007 for other concurrent TMS-fMRI examples; and Hubl et al. 2008; O'Shea et al. 2007 for examples of fMRI utilised before and after an intervening off-line, repetitive TMS intervention that was intended to produce a relatively long-lasting disruption). In one illustrative example of concurrent TMS-fMRI, Sack et al. (2007) applied TMS over left or right parietal cortex, during a spatial cognition task (angle judgements, somewhat reminiscent of some of the 'clock' tasks often used with neglect patients) or during a non-spatial control task. Right but not left parietal TMS disrupted spatial performance. Concurrent fMRI revealed effects of right but not left parietal TMS for BOLD signals in right parietal and interconnected right frontal cortex that correlated with the behavioural effects.

### Combining TMS with concurrent EEG to study the possible causal impact of a targeted brain region upon others

TMS can also be combined with concurrent EEG, which can provide a much finer temporal resolution than fMRI, at the expense of spatial anatomical resolution. Again there are technical issues to overcome (such as the instantaneous electrical artefact during each TMS pulse, plus the ERPs triggered by the associated click-sound and scalp-sensation, etc). These technical challenges are all surmountable (e.g., see Thut and Pascual-Leone 2010; Ilmoniemi and Kicic 2010). Several recent studies have used concurrent TMS-EEG to study possible attention-related effects of TMS over (or near) human FEF, in the context of visual attention paradigms. Taylor et al. (2007) reported that posterior negativities, within ~200 ms of visual target onset, could be modulated by right FEF TMS, in a Posner-like (Posner et al. 1980) spatial precuing paradigm. This was taken to indicate a remote attention-dependent influence on sources in visual cortex. Morishima et al. (2009) reported that TMS over electrode position FC2 (argued by those authors to fall close to human FEF) altered ERPs at occipital electrodes, when participants were forewarned by an early precue that they would have to attend to a face



**Fig. 4** In the concurrent TMS-fMRI study by Blankenburg et al. (2008), TMS was applied over right anterior parietal cortex (as indicated schematically by lightning-flash symbols), in the presence or absence of electrical somatosensory stimulation for the right hand, during concurrent whole-brain fMRI. The fMRI data revealed an inter-hemispheric effect of the right parietal TMS. Specifically, the BOLD signal for left S1 (as indicated on the transverse and coronal views here, for slices taken through the MNI coordinate shown) in response to right-hand somatosensory input was enhanced when

stimulus or a motion stimulus in a composite visual display. These findings were again interpreted as indicating remote attention-dependent influences on sources in visual cortex. Most recently, Capotosto et al. (2009) applied TMS to right frontal eye fields or right intra-parietal sulcus during presentation of a precue that directed attention to a peripheral spatial location, where a target could be presented some seconds later. Concurrent EEG measurements showed that TMS at either cortical site affected anticipatory alpha desynchronisation as measured at parieto-occipital electrodes. Moreover, these effects correlated with response-time slowing for the subsequently presented target. Based on these findings, Capotosto et al. (2009) suggest that FEF and IPS may exert top-down influences on visual processing via neural (de)synchronisation of brain oscillations.

The functional significance of such fairly rapid oscillatory brain phenomena (e.g., from the delta and alpha bands through to beta, gamma and above) can be directly studied with combinations of TMS and EEG, due to the excellent temporal resolution of both techniques. Thut and Miniussi (2009) recently reviewed the possibility of interfering with, or driving, specific brain oscillatory phenomena by using rhythmic TMS at specific frequencies for targeted sites. This remains an exciting direction for future research. Although fMRI data are acquired at a much slower timescale, BOLD signals can also show some (correspondingly slower) oscillatory phenomena (e.g., Fox and Raichle 2007) that might potentially relate to states of communication among networks of interconnected brain regions (e.g., see Mantini et al. 2007). In the longer-term, TMS might thus be combined not only with EEG but also with

combined with high intensity (versus low) TMS. See plot on right for the differential TMS effect (high minus low) as a function of the presence or absence of concurrent right-hand somatosensory input. See main text for discussion of how this relates to the previous purely behavioural TMS findings of Seyal et al. (1995) concerning inter-hemispheric effects of right parietal cortex on left-hemisphere somatosensory processing that might potentially relate to clinical somatosensory extinction or neglect after pathological right-parietal disruption

fMRI to study the possible causal role of oscillatory neural phenomena (at faster or slower timescales, for EEG or fMRI, respectively) in supporting specific processes such as spatial attention and spatial cognition.

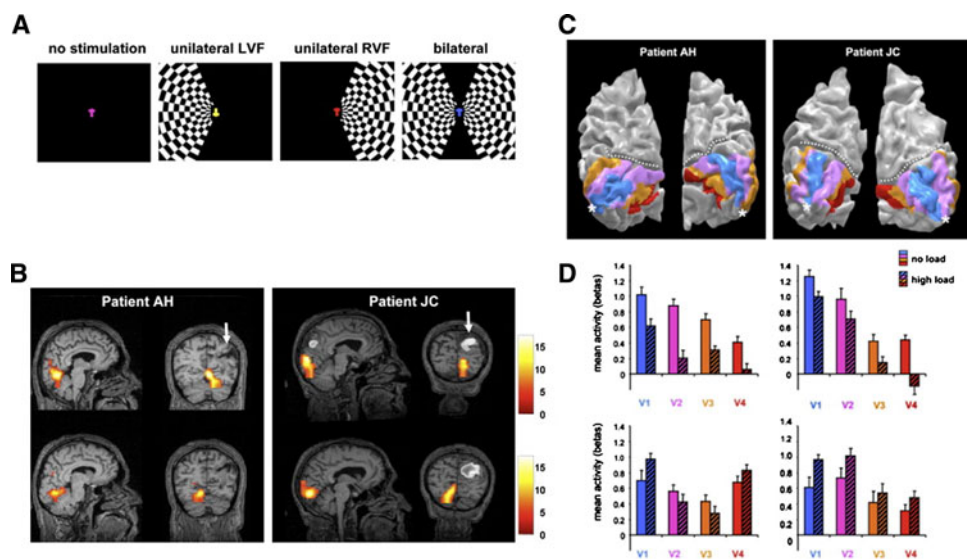
#### Applying fMRI and/or EEG in focally lesioned patients, to study the possible causal impact of the lesioned brain region upon others

fMRI and EEG can also be applied to brain-damaged patients exhibiting particular neuropsychological symptoms, as in cases of spatial neglect or unilateral extinction. The intention in doing so is not to seek a response from the dead or absent tissue. Rather the aim is to study the possible impact of the lesion upon function in remote surviving regions that might normally interact with the damaged area(s), but then function abnormally when the lesion removes some of the usual influences upon surviving regions. Thus, although chronic brain lesions differ in many respects from application of TMS in healthy participants (as was reviewed above), there is the abstract similarity of being able to look for the remote functional consequences of local brain disruption. Pizzamiglio et al. were among the first to apply functional neuroimaging to neglect patients (e.g., Pizzamiglio et al. 1998). In London, we have used fMRI to study the response of visual cortex to contralateral visual stimuli, in neglect and/or unilateral extinction patients, during unilateral or bilateral visual stimuli. Rees et al. (2000, 2002) reported residual unconscious activation in early right visual cortex for extinguished and/or neglected visual stimuli in the left visual

field, together with enhanced responses in surviving parietal and frontal cortex for the same stimuli when consciously detected, in a single case (see also Vuilleumier et al. 2001, 2002; plus Vuilleumier and Driver 2007, for review). Sarri et al. (in press) recently replicated and extended these results to a series of multiple cases of neglect/extinction after right-parietal damage. Marzi et al. (e.g., Marzi et al. 2000, 2001) have made related observations, by using EEG to study ERPs in response to visual stimuli in neglect and/or extinction patients (see also Spinelli et al. 1994). Knight and colleagues have further shown that frontal lesions impact upon visual responses to task-related stimuli, as assessed with ERPs (e.g., Barceló et al. 2000; Yago et al. 2004).

In a recent fMRI study, Vuilleumier et al. (2008) studied two patients with enduring left neglect and extinction after relatively focal right-parietal injury. They varied the ‘attentional load’ of a task at fixation, while studying the possible impact of this on the BOLD response of retinotopic visual cortex to task-irrelevant but salient peripheral checkerboards in either visual hemifield (see Fig. 5a). In healthy participants, increased attentional load at fixation

slightly reduces the BOLD response of visual cortex to the peripheral checkerboards (Schwartz et al. 2005) but does so symmetrically for the response of either visual hemisphere to a contralateral checkerboard. By contrast, in the two right-parietal neglect patients, the visual hemispheres responded normally and symmetrically under low attentional load at fixation (see Fig. 5b), but a pathological asymmetry emerged when attentional load at fixation was increased. For retinotopically mapped visual areas (see Fig. 5c), the BOLD response of (intact) right visual cortex in the damaged hemisphere to left hemifield checkerboards was now pathologically reduced (even eliminated for V4, see Fig. 5d upper two plots); while there was (abnormally) no impact of attentional load at fixation on the BOLD response of left visual cortex to a right hemifield checkerboard (see Fig. 5d, lower two plots). As discussed by Vuilleumier et al. (2008), the emergence of a pathological asymmetry in visual cortex function after right-parietal injury, specifically when attentional demand at current fixation is increased, can explain several otherwise paradoxical aspects of the unilateral visual neglect syndrome, including its apparently labile nature. Vuilleumier et al.



**Fig. 5** Schematic paradigm and neuroimaging results from the patient fMRI study of Vuilleumier et al. (2008) that found an attention-dependent impact of right-parietal lesions on function in remote visual cortex, for two neglect patients. Paradigm shown in (a): The patients performed a low- or high-load task at central fixation, for a successive stream of coloured characters there. Task-irrelevant checkerboards could appear in left or right visual field (LVF/RVF), as illustrated. Under low-load at fixation, patients show preserved response of visual cortex to contralateral checkerboards (see whole-brain SPMs in panel B for two different patients, with the upper row showing preserved response of right visual cortex to LVF, and the lower row showing the symmetric response of left visual cortex to RVF). Note also the right-parietal lesion of each patient (arrowed). Retinotopic regions V1–V4 were functionally mapped separately in each patient (see panel C). Despite the evident preservation of

functional retinotopic visual cortex in both visual hemispheres for both patients, the right-parietal lesions imposed an attention-dependent abnormality upon the responses of visual cortex, as follows. While visual cortex functioned normally under low-load at fixation in the patients, when attentional load at fixation was increased, a pathological asymmetry emerged (see histograms in panel D). Increased attentional load at fixation drastically reduced the contralateral response to LVF checkerboards in right V1–V4 even eliminating this response for right V4, as if that now became blind (see upper row of histograms in panel D), one for each illustrated patient). But increased attentional load at fixation had no impact on left V1–V4 [see lower row of histograms in (D)]. These results reveal an attention-dependent abnormal asymmetry in visual cortex function, after right-parietal damage. See main text for discussion. Adapted with authors’ permission from Vuilleumier et al. (2008)

(2008) went on to identify a behavioural analogue of their BOLD results. But for present purposes, the key point of this study lies in demonstrating a remote functional abnormality in intact visual cortex, after right-parietal disruption, that depended specifically on the current attentional state. In this sense, their patients' results have some abstract parallels with the results of Blankenburg et al. (2010), who demonstrated with TMS-fMRI in healthy people that remote influences of right parietal cortex on visual cortex can depend on the current attentional state (cf. Fig. 3 here).

Other groups have also applied fMRI to neglect and/or extinction patients. For instance, Corbetta et al. (2005) and He et al. (2007) reported in a group of neglect patients that task-evoked BOLD responses (Corbetta et al. 2005), or functional connectivity between regions within attention-related extended brain networks as measured with fMRI (He et al. 2007), showed systematic abnormalities within surviving intact regions remote from the lesion. These related to performance in a spatial precuing attention task, and also to the clinical severity/recovery of individual patients. Hyperactivity within left parietal and frontal cortex, contralateral to the damaged hemisphere, contributed to this pattern. Such contralesional hyper-activity in neglect had long been hypothesised on clinical and theoretical grounds (e.g., Kinsbourne 1977) but had rarely if ever been demonstrated directly hitherto (though see Koch et al. 2008).

Pizzamiglio et al. have expanded considerable effort on possible rehabilitation strategies for neglect over many years (e.g., see Pizzamiglio et al. 1990, 1992; Antonucci et al. 1995). One possible strategy follows up on the possibility of hyper-excitability within the undamaged (usually left) hemisphere, as mentioned above. This can be approached using repetitive TMS protocols over the intact hemisphere that aim to reduce such hyper-excitability. The rationale here is that if such hyper-excitability can be returned to normal levels, some of the neglect and/or extinction symptoms might be alleviated. After some initial positive demonstrations for extinction (e.g., Oliveri et al. 1999), there have been further recent developments in the application of TMS as a potential therapy for neglect. These include a recent (Koch et al. 2008) direct demonstration, with twin-coil TMS, of hyper-excitability within parietal-motor networks for the intact left-hemisphere of neglect patients. Moreover, this same study observed that repetitive TMS applied over that intact hemisphere reduced this hyper-excitability back to the normal range and led in parallel to corresponding improvements in neglect symptom (e.g., see Koch et al. 2008).

TMS can now be combined with fMRI and with EEG, as we have reviewed above, to reveal the impact of interventions targeting a specific brain area for function in remote interconnected areas. These combined approaches

are now sufficiently well established that they can also begin to be applied to brain-damaged patients. Moreover, TMS already shows exciting possibilities for remediation of neglect and extinction (e.g., Koch et al. 2008; Oliveri et al. 1999); while the available TMS interventions should increasingly be informed by the emerging literature on how rhythmic TMS may affect ongoing brain oscillations (e.g., see Thut and Miniussi 2009). Taking all of these points together, we anticipate that the various different strands of research that we have briefly summarised above are likely to converge in the future, to allow further advances on the topics that Pizzamiglio has studied and highlighted throughout his career. The new methodological combinations allow a distinct approach to enduring questions, while also raising many new questions about how separate but connected brain areas may interact within the normal and damaged human brain.

**Acknowledgments** JD is supported by the Wellcome Trust, the Medical Research Council UK, by EU FP7 200728 (Brain-Synch) and by a Royal Society Anniversary Professorship; FB by the Federal Ministry of Education and Research (BMBF); SB by the Biotechnology and Biological Sciences Research Council; CCR by the University Research Priority Program "Foundations of Human Social Behaviour" at the University of Zurich and by his collaboration with the Brain-Synch network.

**Open Access** This article is distributed under the terms of the Creative Commons Attribution Noncommercial License which permits any noncommercial use, distribution, and reproduction in any medium, provided the original author(s) and source are credited.

## References

- Antonucci G, Guariglia C, Judica A, Magnotti L, Paolucci S et al (1995) Effectiveness of neglect rehabilitation in a randomized group study. *J Clin Exp Neuropsychol* 17:383–389
- Armstrong KM, Moore T (2007) Rapid enhancement of visual cortical response discriminability by microstimulation of the frontal eye field. *Proc Natl Acad Sci USA* 104:9499–9504
- Barceló F, Suwazono S, Knight RT (2000) Prefrontal modulation of visual processing in humans. *Nat Neurosci* 3:399–403
- Baudewig J, Siebner HR, Bestmann S, Tergau F, Tings T et al (2001) Functional MRI of cortical activations induced by transcranial magnetic stimulation (TMS). *Neuroreport* 12:3543–3548
- Bestmann S, Ruff CC, Blankenburg F, Weiskopf N, Driver J et al (2008) Mapping causal interregional influences with concurrent TMS-fMRI. *Exp Brain Res* 191:383–402
- Bisiach E, Pizzamiglio L, Nico D, Antonucci G (1996) Beyond unilateral neglect. *Brain* 119(Pt 3):851–857
- Blankenburg F, Ruff CC, Bestmann S, Bjoertomt O, Eshel N et al (2008) Interhemispheric effect of parietal TMS on somatosensory response confirmed directly with concurrent TMS-fMRI. *J Neurosci* 28:13202–13208
- Blankenburg F, Bestmann S, Bjoertomt O, Josephs O, Deichmann R et al (2010) Studying the role of human parietal cortex in visuospatial attention with concurrent TMS-fMRI. *Cereb Cortex* [Epub ahead of print]



- Bohning DE, Shastri A, McConnell KA, Nahas Z, Lorberbaum JP et al (1999) A combined TMS/fMRI study of intensity-dependent TMS over motor cortex. *Biol Psychiatry* 45:385–394
- Bohning DE, Denslow S, Bohning PA, Walker JA, George MS (2003) A TMS coil positioning/holding system for MR image-guided TMS interleaved with fMRI. *Clin Neurophysiol* 114:2210–2219
- Capotosto P, Babiloni C, Romani GL, Corbetta M (2009) Frontoparietal cortex controls spatial attention through modulation of anticipatory alpha rhythms. *J Neurosci* 29:5863–5872
- Cohen MR, Newsome WT (2004) What electrical microstimulation has revealed about the neural basis of cognition. *Curr Opin Neurobiol* 14:169–177
- Corbetta M, Shulman GL (2002) Control of goal-directed and stimulus-driven attention in the brain. *Nat Rev Neurosci* 3:201–215
- Corbetta M, Kincade MJ, Lewis C, Snyder AZ, Sapir A (2005) Neural basis and recovery of spatial attention deficits in spatial neglect. *Nat Neurosci* 8:1603–1610
- Denslow S, Lomarev M, George MS, Bohning DE (2005) Cortical and subcortical brain effects of transcranial magnetic stimulation (TMS)-induced movement: an interleaved TMS/functional magnetic resonance imaging study. *Biol Psychiatry* 57:752–760
- Driver J, Eimer M, Macaluso E, Van Velzen J (2004) The neurobiology of human spatial attention. In: Kanwisher N, Duncan J (eds) *Imaging visual cognition: attention and performance XX*. OUP, Oxford, pp 267–300
- Driver J, Blankenburg F, Bestmann S, Vanduffel W, Ruff CC (2009) Concurrent brain-stimulation and neuroimaging for studies of cognition. *Trends Cogn Sci* 13:319–327
- Ekstrom LB, Roelfsema PR, Arsenault JT, Bonmassar G, Vanduffel W (2008) Bottom-up dependent gating of frontal signals in early visual cortex. *Science* 321:414–417
- Fox MD, Raichle ME (2007) Spontaneous fluctuations in brain activity observed with functional magnetic resonance imaging. *Nat Rev Neurosci* 8:700–711
- Fox P, Ingham R, George MS, Mayberg H, Ingham J et al (1997) Imaging human intra-cerebral connectivity by PET during TMS. *Neuroreport* 8:2787–2791
- Friston KJ, Harrison L, Penny W (2003) Dynamic causal modelling. *Neuroimage* 19:1273–1302
- Galati G, Lobel E, Vallar G, Berthoz A, Pizzamiglio L et al (2000) The neural basis of egocentric and allocentric coding of space in humans: a functional magnetic resonance study. *Exp Brain Res* 133:156–164
- Goebel R, Roebroeck A, Kim D, Formisano E (2003) Investigating directed cortical interactions in time-resolved fMRI data using vector autoregressive modeling and Granger causality mapping. *Magn Reson Imaging* 21:1251–1261
- Grosbras M, Paus T (2002) Transcranial magnetic stimulation of the human frontal eye field: effects on visual perception and attention. *J Cogn Neurosci* 14:1109–1120
- Guariglia C, Padovani A, Pantano P, Pizzamiglio L (1993) Unilateral neglect restricted to visual imagery. *Nature* 364:235–237
- He BJ, Snyder AZ, Vincent JL, Epstein A, Shulman GL et al (2007) Breakdown of functional connectivity in frontoparietal networks underlies behavioral deficits in spatial neglect. *Neuron* 53:905–918
- Henik A, Rafal R, Rhodes D (1994) Endogenously generated and visually guided saccades after lesions of the human frontal eye fields. *J Cogn Neurosci* 6:400–411
- Hubl D, Nyffeler T, Wurtz P, Chaves S, Pflugshaupt T et al (2008) Time course of blood oxygenation level-dependent signal response after theta burst transcranial magnetic stimulation of the frontal eye field. *Neuroscience* 151:921–928
- Husain M, Rorden C (2003) Non-spatially lateralized mechanisms in hemispatial neglect. *Nat Rev Neurosci* 4:26–36
- Husain M, Parton A, Hodgson TL, Mort D, Rees G (2003) Self-control during response conflict by human supplementary eye field. *Nat Neurosci* 6:117–118
- Ilmoniemi RJ, Kicić D (2010) Methodology for combined TMS and EEG. *Brain Topogr* 22:233–248
- Juan C, Shorter-Jacobi SM, Schall JD (2004) Dissociation of spatial attention and saccade preparation. *Proc Natl Acad Sci USA* 101:15541–15544
- Karnath HO, Ferber S, Himmelbach M (2001) Spatial awareness is a function of the temporal not the posterior parietal lobe. *Nature* 411:950–953
- Karnath H, Fruhmann Berger M, Küker W, Rorden C (2004) The anatomy of spatial neglect based on voxelwise statistical analysis: a study of 140 patients. *Cereb Cortex* 14:1164–1172
- Kemna LJ, Gembris D (2003) Repetitive transcranial magnetic stimulation induces different responses in different cortical areas: a functional magnetic resonance study in humans. *Neurosci Lett* 336:85–88
- Kinsbourne M (1977) Hemi-neglect and hemisphere rivalry. *Adv Neurol* 18:41–49
- Koch G, Oliveri M, Cheeran B, Ruge D, Lo Gerfo E et al (2008) Hyperexcitability of parietal-motor functional connections in the intact left-hemisphere of patients with neglect. *Brain* 131:3147–3155
- Latto R, Cowey A (1971) Visual field defects after frontal eye-field lesions in monkeys. *Brain Res* 30:1–24
- Logothetis NK (2008) What we can do and what we cannot do with fMRI. *Nature* 453:869–878
- Lomber F, Galuske R (2002) *Virtual lesions: examining cortical function with reversible deactivation*. OUP, Oxford
- Mantini D, Perrucci MG, Del Gratta C, Romani GL, Corbetta M (2007) Electrophysiological signatures of resting state networks in the human brain. *Proc Natl Acad Sci USA* 104:13170–13175
- Marzi CA, Girelli M, Miniussi C, Smania N, Maravita A (2000) Electrophysiological correlates of conscious vision: evidence from unilateral extinction. *J Cogn Neurosci* 12:869–877
- Marzi CA, Girelli M, Natale E, Miniussi C (2001) What exactly is extinguished in unilateral visual extinction? Neurophysiological evidence. *Neuropsychologia* 39:1354–1366
- Milner AD, Goodale MA (1996) *The visual brain in action*. Oxford University Press, USA
- Morishima Y, Akaishi R, Yamada Y, Okuda J, Toma K et al (2009) Task-specific signal transmission from prefrontal cortex in visual selective attention. *Nat Neurosci* 12:85–91
- Mort DJ, Malhotra P, Mannan SK, Rorden C, Pambakian A et al (2003) The anatomy of visual neglect. *Brain* 126:1986–1997
- Müri RM, Nyffeler T (2008) Neurophysiology and neuroanatomy of reflexive and volitional saccades as revealed by lesion studies with neurological patients and transcranial magnetic stimulation (TMS). *Brain Cogn* 68:284–292
- Neggers SFW, Huijbers W, Vrijlandt CM, Vlaskamp BNS, Schutter DJLG et al (2007) TMS pulses on the frontal eye fields break coupling between visuospatial attention and eye movements. *J Neurophysiol* 98:2765–2778
- O’Shea J, Muggleton NG, Cowey A, Walsh V (2004) Timing of target discrimination in human frontal eye fields. *J Cogn Neurosci* 16:1060–1067
- O’Shea J, Johansen-Berg H, Trief D, Göbel S, Rushworth MFS (2007) Functionally specific reorganization in human premotor cortex. *Neuron* 54:479–490
- Oliveri M, Rossini PM, Traversa R, Cicinelli P, Filippi MM et al (1999) Left frontal transcranial magnetic stimulation reduces contralesional extinction in patients with unilateral right brain damage. *Brain* 122(Pt 9):1731–1739
- Paus T, Jech R, Thompson CJ, Comeau R, Peters T et al (1997) Transcranial magnetic stimulation during positron emission

- tomography: a new method for studying connectivity of the human cerebral cortex. *J Neurosci* 17:3178–3184
- Pizzamiglio L, Frasca R, Guariglia C, Incoccia C, Antonucci G (1990) Effect of optokinetic stimulation in patients with visual neglect. *Cortex* 26:535–540
- Pizzamiglio L, Antonucci G, Judica A, Montenero P, Razzano C et al (1992) Cognitive rehabilitation of the hemineglect disorder in chronic patients with unilateral right brain damage. *J Clin Exp Neuropsychol* 14:901–923
- Pizzamiglio L, Perani D, Cappa SF, Vallar G, Paolucci S et al (1998) Recovery of neglect after right hemispheric damage: H2(15)O positron emission tomographic activation study. *Arch Neurol* 55:561–568
- Posner MI, Snyder CR, Davidson BJ (1980) Attention and the detection of signals. *J Exp Psychol* 109:160–174
- Rees G, Wojciulik E, Clarke K, Husain M, Frith C et al (2000) Unconscious activation of visual cortex in the damaged right hemisphere of a parietal patient with extinction. *Brain* 123(Pt 8):1624–1633
- Rees G, Wojciulik E, Clarke K, Husain M, Frith C et al (2002) Neural correlates of conscious and unconscious vision in parietal extinction. *Neurocase* 8:387–393
- Robertson IH, Manly T, Beschin N, Daini R, Haeske-Dewick H et al (1997) Auditory sustained attention is a marker of unilateral spatial neglect. *Neuropsychologia* 35:1527–1532
- Ruff CC, Blankenburg F, Bjoertomt O, Bestmann S, Freeman E et al (2006) Concurrent TMS-fMRI and psychophysics reveal frontal influences on human retinotopic visual cortex. *Curr Biol* 16:1479–1488
- Ruff CC, Bestmann S, Blankenburg F, Bjoertomt O, Josephs O et al (2008) Distinct causal influences of parietal versus frontal areas on human visual cortex: evidence from concurrent TMS-fMRI. *Cereb Cortex* 18:817–827
- Ruff CC, Blankenburg F, Bjoertomt O, Bestmann S, Weiskopf N et al (2009a) Hemispheric differences in frontal and parietal influences on human occipital cortex: direct confirmation with concurrent TMS-fMRI. *J Cogn Neurosci* 21:1146–1161
- Ruff CC, Driver J, Bestmann S (2009b) Combining TMS and fMRI: from ‘virtual lesions’ to functional-network accounts of cognition. *Cortex* 45:1043–1049
- Sack AT, Kohler A, Bestmann S, Linden DEJ, Dechent P et al (2007) Imaging the brain activity changes underlying impaired visuospatial judgments: simultaneous fMRI, TMS, and behavioral studies. *Cereb Cortex* 17:2841–2852
- Sarri M, Ruff CC, Rees G, Driver J Neural correlates of visual extinction or awareness in a series of patients with right temporo-parietal damage. *Cogn Neurosci* (in press)
- Schnitzler A, Gross J (2005) Normal and pathological oscillatory communication in the brain. *Nat Rev Neurosci* 6:285–296
- Schwartz S, Vuilleumier P, Hutton C, Maravita A, Dolan RJ et al (2005) Attentional load and sensory competition in human vision: modulation of fMRI responses by load at fixation during task-irrelevant stimulation in the peripheral visual field. *Cereb Cortex* 15:770–786
- Seyal M, Ro T, Rafal R (1995) Increased sensitivity to ipsilateral cutaneous stimuli following transcranial magnetic stimulation of the parietal lobe. *Ann Neurol* 38:264–267
- Siebner HR, Peller M, Willloch F, Auer C, Bartenstein P et al (1999) Imaging functional activation of the auditory cortex during focal repetitive transcranial magnetic stimulation of the primary motor cortex in normal subjects. *Neurosci Lett* 270:37–40
- Siebner HR, Bergmann TO, Bestmann S, Massimini M, Johansen-Berg H et al (2009) Consensus paper: combining transcranial stimulation with neuroimaging. *Brain Stimul* 2:58–80
- Silvanto J, Lavie N, Walsh V (2006) Stimulation of the human frontal eye fields modulates sensitivity of extrastriate visual cortex. *J Neurophysiol* 96:941–945
- Spinelli D, Burr DC, Morrone MC (1994) Spatial neglect is associated with increased latencies of visual evoked potentials. *Vis Neurosci* 11:909–918
- Taylor PCJ, Nobre AC, Rushworth MFS (2007) FEF TMS affects visual cortical activity. *Cereb Cortex* 17:391–399
- Thiebaut de Schotten M, Urbanski M, Duffau H, Volle E, Lévy R et al (2005) Direct evidence for a parietal-frontal pathway subserving spatial awareness in humans. *Science* 309:2226–2228
- Thut G, Miniussi C (2009) New insights into rhythmic brain activity from TMS-EEG studies. *Trends Cogn Sci (Regul. Ed.)* 13:182–189
- Thut G, Pascual-Leone A (2010) Integrating TMS with EEG: how and what for? *Brain Topogr* 22:215–218
- Valdés-Sosa PA, Kötter R, Friston KJ (2005) Introduction: multimodal neuroimaging of brain connectivity. *Philos Trans R Soc Lond B Biol Sci* 360:865–867
- Vallar G (2001) Extrapersonal visual unilateral spatial neglect and its neuroanatomy. *Neuroimage* 14:S52–58
- Vallar G, Lobel E, Galati G, Berthoz A, Pizzamiglio L et al (1999) A fronto-parietal system for computing the egocentric spatial frame of reference in humans. *Exp Brain Res* 124:281–286
- Verdon V, Schwartz S, Lovblad K, Hauert C, Vuilleumier P (2009) Neuroanatomy of hemispatial neglect and its functional components: a study using voxel-based lesion-symptom mapping. *Brain* Available at: <http://www.ncbi.nlm.nih.gov/pubmed/20028714>. Accessed 28 January 2010
- Vuilleumier P, Driver J (2007) Modulation of visual processing by attention and emotion: windows on causal interactions between human brain regions. *Philos Trans R Soc Lond B Biol Sci* 362:837–855
- Vuilleumier P, Sagiv N, Hazeltine E, Poldrack RA, Swick D et al (2001) Neural fate of seen and unseen faces in visuospatial neglect: a combined event-related functional MRI and event-related potential study. *Proc Natl Acad Sci USA* 98:3495–3500
- Vuilleumier P, Armony JL, Clarke K, Husain M, Driver J et al (2002) Neural response to emotional faces with and without awareness: event-related fMRI in a parietal patient with visual extinction and spatial neglect. *Neuropsychologia* 40:2156–2166
- Vuilleumier P, Schwartz S, Verdon V, Maravita A, Hutton C et al (2008) Abnormal attentional modulation of retinotopic cortex in parietal patients with spatial neglect. *Curr Biol* 18:1525–1529
- Walsh V, Pascual-Leone A (2005) Transcranial magnetic stimulation: a neurochronometrics of mind. The MIT Press, Cambridge
- Wardak C, Ibos G, Duhamel J, Olivier E (2006) Contribution of the monkey frontal eye field to covert visual attention. *J Neurosci* 26:4228–4235
- Wassermann EM, Epstein CM, Ziemann U (2008) The oxford handbook of transcranial stimulation, 1st edn. Oxford University Press, Oxford
- Weiskopf N, Josephs O, Ruff CC, Blankenburg F, Featherstone E et al (2009) Image artifacts in concurrent transcranial magnetic stimulation (TMS) and fMRI caused by leakage currents: modeling and compensation. *J Magn Reson Imaging* 29:1211–1217
- Yago E, Duarte A, Wong T, Barceló F, Knight RT (2004) Temporal kinetics of prefrontal modulation of the extrastriate cortex during visual attention. *Cogn Affect Behav Neurosci* 4:609–617