

Benign fibrous histiocytoma of bone in a paediatric population: a report of 6 cases

D. Ceroni · R. Dayer · G. De Coulon ·
A. Kaelin

Received: 21 May 2010 / Accepted: 1 March 2011 / Published online: 16 March 2011
© Springer-Verlag 2011

Abstract Case records and radiological investigations of six children with benign fibrous histiocytoma were studied retrospectively. BFH occurred in the femur ($n = 2$), tibia ($n = 2$) and fibula ($n = 2$). Clinically, patients reported pain from the lesion lasting several months (mean 6 months). The pain was not associated with pathological fracture in any patient. On X-rays, the lesions appeared as lytic and sharply demarcated with a sclerotic rim and fine trabeculations. The reported cases were located in the metaphysis and the diaphysis of the long bones. The tumour was restricted to bone, without periosteal or soft tissue reaction. Treatment consisted of careful intralesional curettage of the lesion; the defect was thereafter filled with bone bank graft or injectable phosphocalcic cement. The length of follow-up ranged from 24 months to 4.75 years (mean 35.2 months). One case presented with recurrence of the disease and required successful repeat intralesional curettage. Benign fibrous histiocytoma is probably underestimated among patients less than 20 years of age. This diagnosis should be considered in any child or teenager who presents with a non-ossifying fibroma accompanied by unexplainable pain or a rapid growing. Surgery restricted to the osteolytic lesion seems sufficient to achieve bone healing.

Keywords Benign fibrous histiocytoma · Children · Bone tumour · Surgical treatment · Phosphocalcic cement

Introduction

Benign fibrous histiocytoma (BFH) is a rare skeletal tumour accounting for approximately 1% of all surgically managed benign bone tumours [1]. This tumour is also known as fibrous histiocytoma, xanthofibroma, fibroxanthoma of bone or primary xanthoma of bone [2–5]. Clinically, patients report pain ranging in duration from months to several years [3, 6, 7]. It is generally considered that BFH occurs in patients after the age of 20 years [6–9]. Differentiation from non-ossifying fibroma is on purely clinical grounds, since the histological features are identical [6, 8, 10]. In fact, BFH is composed of fibroblasts and histiocytes that are arranged in a storiform pattern, similar to non-ossifying fibroma and metaphyseal fibrous defects [6, 8, 10]. Because the diagnostic criteria are very restrictive with regard to the age of the patient, BFH is seldom diagnosed in patients under 20 years of age [6–9]. Because of this fact, there are only 7 reports on BFH that have been described in children and adolescents [2, 9, 11–15]. The purpose of this study is to highlight BFH in a paediatric population and discuss their clinical, radiological and therapeutic features.

Materials and methods

After approval from the Children's Hospital Review Board (06-265R, Mat-Ped 06-048R), a retrospective review of medical charts was performed to identify all children and adolescents who have been surgically managed for suspected benign fibrous histiocytoma at our institution from January 1995 until December 2005. Based on clinical records, demographics (age and sex), symptom duration, laterality, and bone localization of BFH, treatment

D. Ceroni (✉) · R. Dayer · G. De Coulon · A. Kaelin
Pediatric Orthopedics Department, Children's Hospital,
6, rue Willy Donzé, 1211 Geneva, Switzerland
e-mail: dimitri.ceroni@hcuge.ch

protocols and follow-up examinations were analysed. Radiographic studies of the lesion were available for review for each patient. Radiographic imaging included plain radiographs, technetium bone scans, computed tomography scans and MRI. Immediate postoperative and final follow-up radiographs were reviewed to determine recurrence of the lesion, if any. Intralesional curettage was performed for every patient; the content of all lesions was examined histologically. Thereafter, the patients were assessed clinically and radiographically in regular follow-up sessions.

Cases reports

Case 1

A 14.7-year-old boy presented with pain of his left ankle for more than 3 months. On physical examination, there was no evidence of swelling or limitation of motion. Plain radiographs demonstrated an eccentrically located and radiolucent lesion with a ground-glass appearance in the metaphysis of the distal end of the tibia. The lesion was expansile, the cortex was thinned, and it had a prominent marginal sclerosis. Intralesional curettage was performed and phosphocalcic cement was employed for filling the osseous defect. Thirty-three months after the intralesional excision and filling of the lesion, bone healing was achieved with phosphocalcic cement incorporation and no evidence of disease (Figs. 1, 2, 3, 4, 5).

Case 2

A 13.75-year-old girl was seen after having pain in the left ankle for more than 6 weeks. Physical examination was negative. Plain radiographs demonstrated a well-defined radiolucent lesion in the lower metaphyseal part of the tibia with surrounding sclerosis. Forty months after intralesional excision and bank bone grafting, bone healing was achieved.

Case 3

A 9.5-year-old girl presented to our hospital complaining of increasing right knee pain of 3 months duration. The physical examination was unremarkable. On plain radiography study, the right proximal fibula was totally involved by lytic bone destruction. Thinning of the cortex and cortical expansion were prominent. There was neither periosteal reaction nor soft tissue invasion. The lesion quickly increased in volume. Intralesional curettage was performed, followed by insertion of phosphocalcic cement. Twenty-five months after the operation, there was no evidence of disease.

Case 4

A 12.2-year-old girl came to our clinic for evaluation a painless lesion in the right lower femur discovered on a radiograph due to pain around her right knee of 6 weeks duration. Plain radiograph of the right distal femur showed lytic bone destruction with surrounding sclerosis. No calcification or periosteal reaction was observed. Intralesional excision was performed with the insertion of phosphocalcic cement, and there was no evidence of disease after 24 months of follow-up.

Case 5

A 10.75-year-old girl presented with 3 months of pain and swelling around her right knee. Physical examination disclosed a hard painful mass in the distal part of the right thigh. Plain radiograph showed a radiolucent lesion in the metaphyseal part of the femur, with a soap-bubble appearance. The lesion was expansile, the cortex was thinned, and it had a prominent marginal sclerosis. Intralesional curettage was performed, followed by filling of the cavity by bank bone graft. The diagnosis of non-ossifying fibroma was evoked on a histologically basis. However, 18 months after the operation, the patient presented with small, lytic, recurrent foci in the lower part of the old lesion. The lytic lesion grew progressively and was suspected to be a giant cell tumour. Repeat intralesional curettage was performed 2 years after the initial surgery. Filling of the osseous cavity was performed with phosphocalcic cement; 39 months after the second surgical procedure, the situation appeared to stabilize. Histologically, the tumour was composed of loose spindle cell proliferation intermixed with foam cells. The diagnosis of BFH was made based on clinical presentation, the radiological features and recurrence of the lesion after the initial surgery (Figs. 6, 7, 8, 9, 10, 11, 12, 13).

Case 6

A 14.3-year-old-girl was seen in our hospital complaining of increasing right ankle pain of 2 years duration. The pain resolved partially with the use of anti-inflammatory drugs. X-rays demonstrated a well-defined, central radiolucent lesion of the distal part of the peroneal diaphysis. The lytic lesion grew progressively, was expansile and the cortex was thinned. Intralesional excision of the lesion with prophylactic osteosynthesis of the fibula was performed in order to avoid pathological fracture after tumour resection. Phosphocalcic cement was employed for filling the osseous defect. Thirty-two months after the surgical procedure, bone healing was achieved without evidence of recurrence (Table 1).

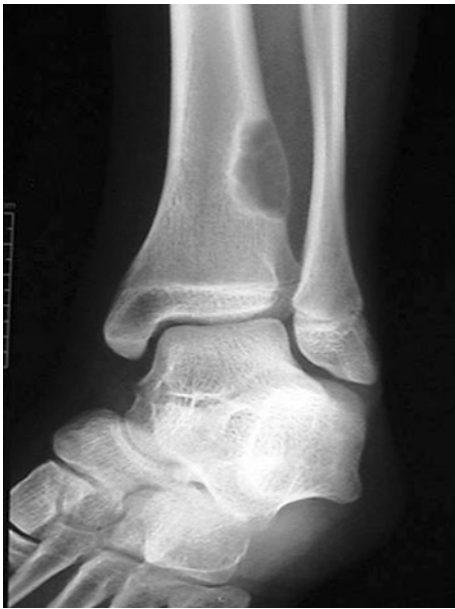

Fig. 1 A 14.7-year-old boy presented with pain of his left ankle for more than 3 months. Plain radiographs demonstrated an eccentrically located and expansile radiolucent lesion in the metaphyseal of the distal end of the tibia. The cortex was thinned and the lesion had a prominent marginal sclerosis with a ground-glass appearance

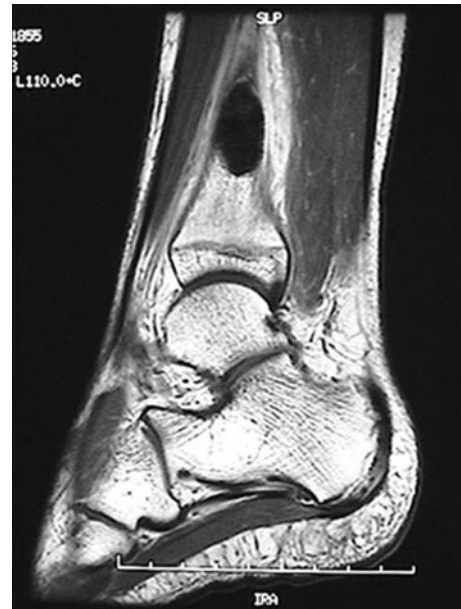

Fig. 3 On T1-weighted MR, the mass appeared hypointense, but the surrounding rim of the lesion was of high signal intensity

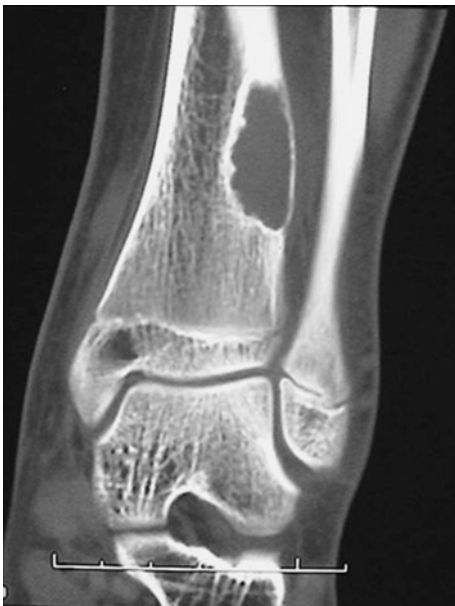

Fig. 2 CT scans showed an irregular lytic area with well-defined surrounding sclerotic bone

Histological features

The histological features of the six cases were similar, even if the relative proportions of the various elements differed. The tumour consisted of spindle cells, fibroblasts and histiocytic

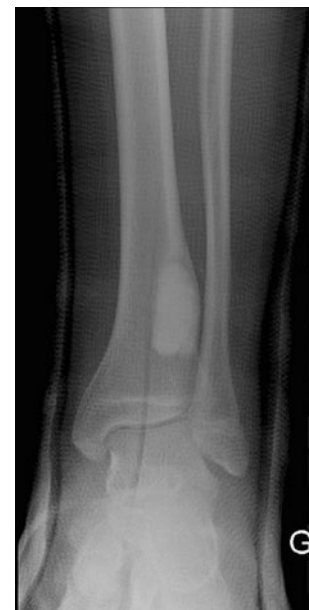

Fig. 4 Intralesional curettage was performed and phosphocalcic cement was employed for filling the osseous defect

mononucleated or multinucleated benign cells that were intermixed with fibrous tissue. Spindle cells were arranged in an interlacing and whorled pattern, frequently justifying the designation “storiform”. The tumour contained large areas of “foam cells” and lipid-filled cells with abundant vacuolated cytoplasm interspaced with small fibrovascular septations. No cellular atypia or pleomorphism was present;

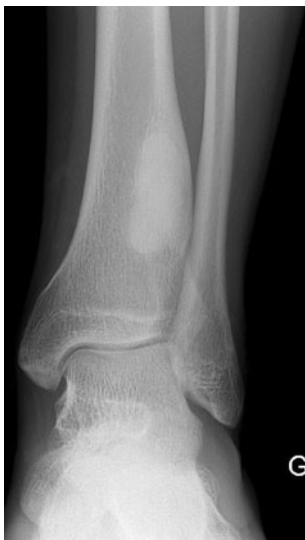

Fig. 5 Thirty-three months after surgery, bone healing was achieved with advanced phosphocalcic cement incorporation and no evidence of disease

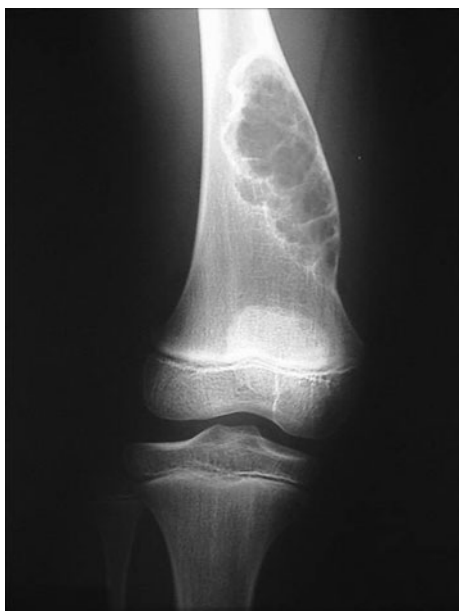

Fig. 6 A 10.75-year-old girl presented with pain and swelling around her right knee lasting 3 months. Physical examination disclosed a hard painful mass in the distal part of the *right thigh*. Plain radiograph showed a radiolucent lesion in the metaphyseal part of the femur with a soap-bubble appearance. The lesion was expansile, the cortex was thinned and showed prominent marginal sclerosis

mitoses were scarce. Cholesterol clefts and haemosiderin deposits were seen in some cases, and reparative new bone formation was occasionally present. In all cases, the histological characteristics did not make it possible to make the distinction between non-ossifying fibroma and benign fibrous histiocytoma.

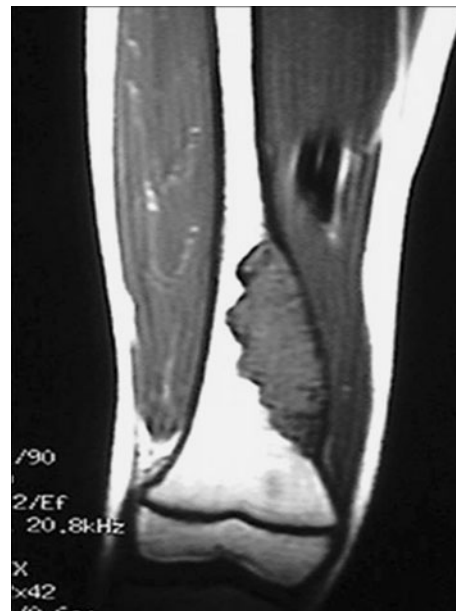

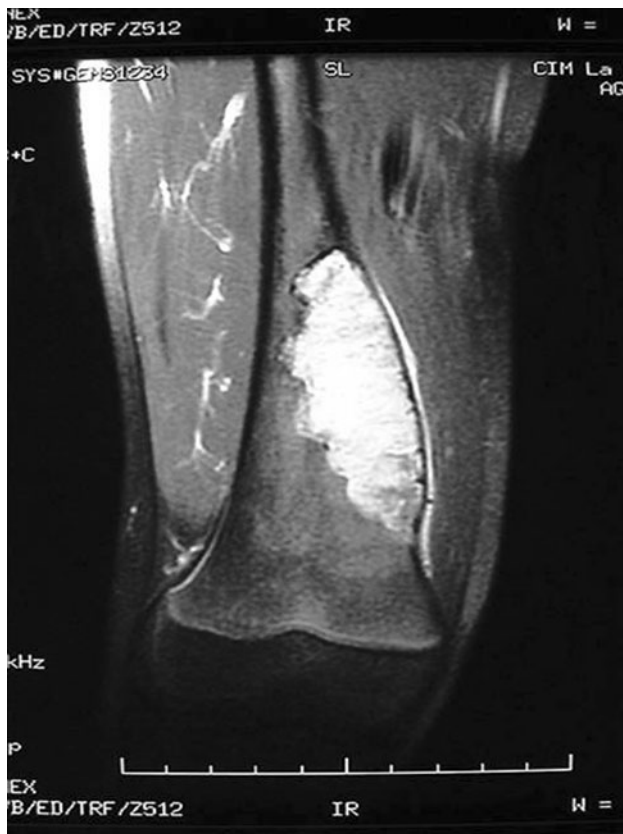Fig. 7 On T1-weighted MR, the mass appeared hypointense but the surrounding rim of the lesion was of high signal intensity. The lesions had the same signal intensity as skeletal muscle

Discussion

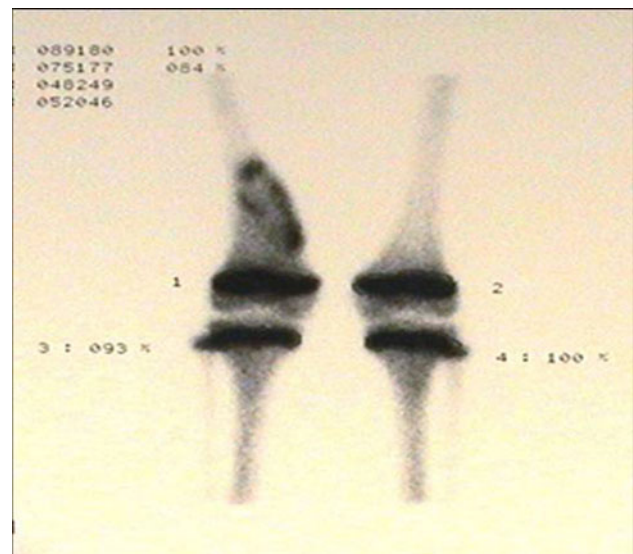
Benign fibrous histiocytoma (BFH) constitutes a well-recognized tumour arising in the somatic soft tissue. Few cases of this tumour have been reported in bone compared with those in soft tissue [5, 6, 8]. BFH occurring in the bone still raises controversy as many authors believe that it should be considered as a separate entity [3]. A portion of the confusion arises from the lack of agreement between pathologists as to what exactly defines this lesion [3]. In fact, there is no consensus as to whether this tumour represents a true neoplasm, a developmental defect or a reactive process [3]. BFH is thought to have self-limited processes and does not undergo malignant change or metastasis [8]. However, BFH can be locally aggressive and may recur after curettage [16]. Clinically, patients usually report pain ranging in duration from months to several years [3, 6, 7]. Pain may also be associated with pathological fractures, but most of the time questioning elicits a history of pain several weeks preceding the fracture [8]. There may be local tenderness, but no mass or swelling is noted as would be present with functional impairment of the nearby joint. Radiologically, benign fibrous histiocytomas are generally well-defined lytic lesions, sometimes with sclerotic margins or cortical expansion; they also have the appearance of a slow-growing process [5–9, 17]. The lesion may have a loculated appearance with septa or ridges or a soap-bubble appearance [5, 6, 9]. The lesion occurs commonly in the spine, ribs, pelvis [1, 5, 6, 8, 12, 15, 16, 18–22] or in the epiphysis

Table 1 Recapitulative table

Case	Age	Sex	Length of pain (months)	Site	Treatment		Length of follow-up months
					Initial	Further	
1	14.7	M	3	Lower metaphysis left tibia	Intralesional curettage, phosphocalcic cement	–	33
2	13.75	F	1.5	Lower metaphysis left tibia	Intralesional curettage, bank bone allograft	–	40
3	9.5	F	3	Upper diaphysis right peroneus	Intralesional curettage, phosphocalcic cement	–	25
4	12.2	F	1.5	Lower metaphysis right femur	Intralesional curettage, phosphocalcic cement	–	24
5	10.75	F	3	Lower metaphysis right femur	Intralesional curettage, bank bone allograft	Intralesional curettage, phosphocalcic cement	57
6	14.3	F	24	Lower diaphysis right peroneus	Intralesional curettage, phosphocalcic cement	–	32

**Fig. 8** The lesion turned hyperintense on T2-weighted images, with the surrounding sclerotic bone having low signal intensity

or diaphysis of tubular bones [5, 6, 8, 9, 11, 13, 17, 18]. In another reports, this tumour occurred particularly around the knee [6, 8, 9, 17]. There is neither periosteal reaction nor matrix mineralization [5–8, 10]. On conventional X-rays, the tumour may resemble non-ossifying fibroma, but BFH may have more prominent marginal sclerosis

**Fig. 9** On bone scintigraphy, the lesion had moderate increased uptake, but there was no scintigraphic argument for a pathological fracture

which may have the appearance of periosteal reaction in juxtacortical lesions [3]. Many authors suggest that BFH should not be distinguished from non-ossifying fibroma solely on the basis of histological characteristics, which are identical for the two lesions, but rather on clinical and radiographic grounds [6, 8, 10, 17]. Pain has to be considered as the cardinal symptom and a median age over 20 years are considered factors that may differentiate benign fibrous histiocytoma from other metaphyseal fibrous lesions such as the non-ossifying fibroma [6–8, 10, 18]. Non-ossifying fibromas (NOF) almost always develop in patients who are less than 20 years old and are considered to be developmental defects and self-limited processes

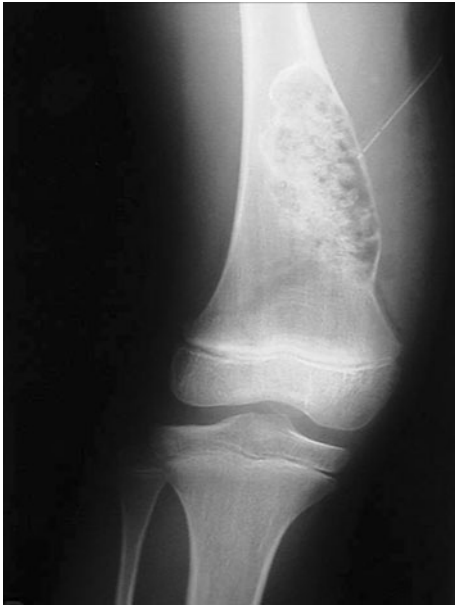

Fig. 10 Intralesional curettage was performed, followed by filling of the cavity with bank bone graft; the diagnosis of non-ossifying fibroma was evoked

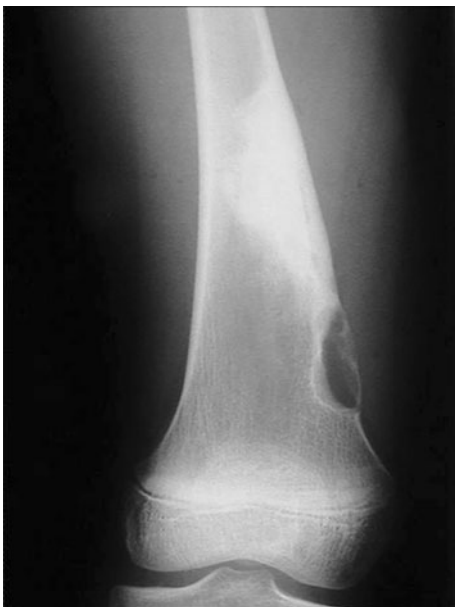

Fig. 11 However, 18 months after the operation, the patient presented with small, lytic, recurrent foci in the lower part of the old lesion

[6, 8, 10]. Clinically, non-ossifying fibroma is most of the time asymptomatic except in the case of pathological fracture [6, 8, 9], whereas benign fibrous histiocytomas frequently come to notice because of pain, usually of some months duration [3, 6, 7]. As non-ossifying fibromas spontaneously regress with skeletal maturity, surgical

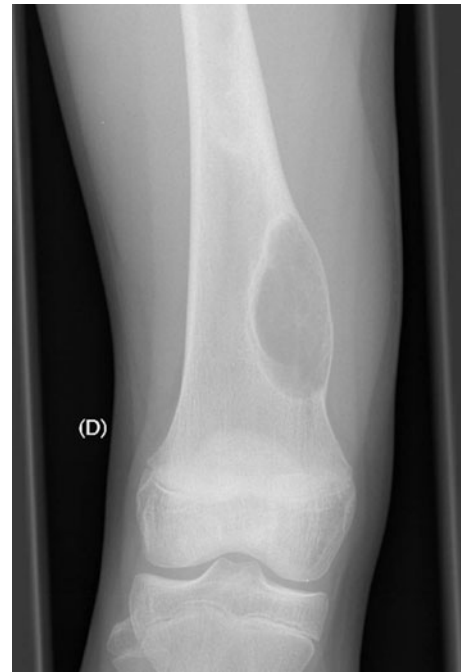

Fig. 12 The lytic lesion grew progressively and was suspected to be a giant cell tumour. Repeated intralesional curettage 2 years after the initial surgery was performed. As GCT was excluded by peri-operative biopsy, filling of the osseous cavity was carried out with phosphocalcic cement. Histologically, the tumour was composed of loose spindle cell proliferation intermixed with foam cells. The diagnosis of BFH was given because of the clinical presentation, the radiological features noted and recurrence of the lesion after the initial surgery

treatment is reserved for the large lesions, usually after a pathological fracture has occurred [23]. Moreover, these two lesions are different clinically, and BFH possesses a much more aggressive nature clinical than non-ossifying fibroma [9, 10].

We do not agree with the opinion that the diagnostic criteria of BFH must be so very restrictive with regard to the age of the patient. In fact, the series of cases here presented occurred in children and adolescents who were symptomatic for a long time in the absence of pathological fracture. Pain was most of the time described as a poorly localized deep ache without relationship to the effort and not prevailing during the night. The majority of the children qualified the pain as awkward but nobody described it as handicapping. In addition, pain due to the tumoral lesion was likely to respond well to classic painkillers such as anti-inflammatory drugs. In every case, the pain disappeared or changed in quality immediately after the resection of the BFH lesion. As the pain disappeared suddenly after the surgery, it is difficult to charge it to a hypothetical infra-radiological pathological fracture. Moreover, most of the lesions we treated presented a prominent marginal sclerosis, which constitutes a radiological difference

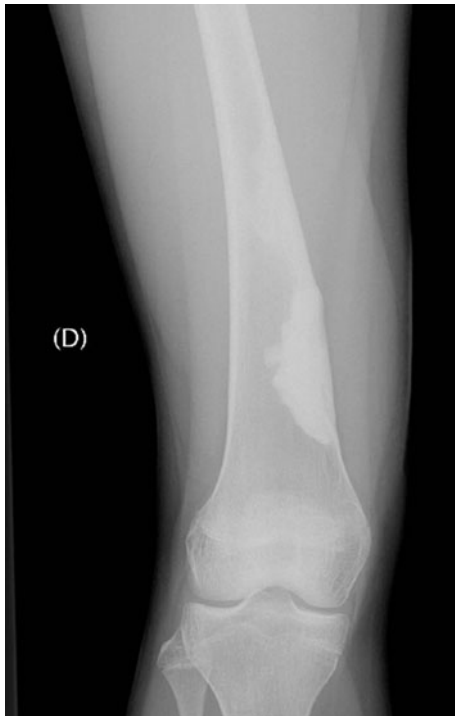

Fig. 13 Thirty-nine months after the second surgical procedure, the situation appeared stabilized

between BFH and non-ossifying fibroma. At our opinion, the diagnosis of BFH is probably underestimated among patients less than 20 years old. Therefore, this diagnosis should be considered, in our opinion, for any child or teenager who presents radiologically a non-ossifying fibroma accompanied by unexplainable pain or when the lesion grows quickly. The differential diagnosis of this lesion includes other clinical and pathological entities such as fibrous dysplasia, chondromyxoid fibroma, giant cell tumour of bone, eosinophilic granuloma, malignant fibrous histiocytoma, metastatic renal cell carcinoma, Erdheim-Chester disease or hyperparathyroidism. In adolescents and young adults, one of the most difficult differential diagnoses of BFH of metaphyseal-epiphyseal origin is giant cell tumour [9]. The starting point of GCT is always metaphyseal, and the lesion seldom extends to the epiphysis before osseous maturity. GCT is rare in children and adolescents less than 15 years old, in particular when the cartilage is still active. GCT may have histological features which are identical to those of benign fibrous histiocytoma; in these cases, the diagnosis is usually established only on the presence of small foci of typical histological patterns of giant cell tumour of the bone [6, 9]. Therefore, one should always keep in mind the small possibility of GCT of bone if the lesion arises at the end of long tubular bone, even if the patient is younger than 20 years of age.

Treatment consists of careful and complete curettage and filling of the defect with graft material, bone cement or other suitable bone void filler [3, 5, 6, 8, 9, 18]. The treatments we have chosen for our patients consisted of careful and complete curettage and filling of the defect with bone bank allograft or phosphocalcic cement. In our opinion, use of bone allograft can advantageously take the place of autogenous bone graft as it gives the same results and decreases postoperative morbidity. Currently, we use more and more often phosphocalcic cement to fill the lesion after excision of the tumour. The use of phosphocalcic cement allows for better filling of the cavity compared to bone grafts. Its greatest advantage compared to conventional cement is that it can be reabsorbed and incorporated in the bone and therefore does not constitute a foreign body. The risk of recurrence is variable depending on which series is consulted. One series [3, 8] of 8 cases recurred locally and two required amputation. In the Bertoni series, none of the 21 cases reported as xanthomas recurred [5]. In another series, Bertoni et al. described 7 cases of BFH surgically treated without local recurrence, just as in the Grohs publication where all the patients were regarded as cured after prophylactic curettage and bone grafting [6, 18]. As recurrence does not seem to be correlated with the surgical margin achieved, surgery restricted to the osteolytic lesion seems sufficient to achieve bone healing [5, 6, 9, 18]. Therefore, it is stated that intralesional curettage is sufficient to prevent recurrence. However, recurrence may be due to an incomplete removal of the pathological tissue [24]. So it appears important to carry out the most complete removal of the tumoral tissue as is possible. Milling the margins of the lytic lesion probably allows for better excision of the pathological tissue and would thus decrease the risk of recurrence.

Conclusion

Benign fibrous histiocytoma is probably underestimated among patients less than 20 years of age. In our opinion, the diagnostic criteria of BFH should not be so restrictive with regard to the age of the patient, and this diagnosis should be considered in any child or teenager who presents radiologically with a non-ossifying fibroma accompanied by unexplainable pain. Surgery restricted to the osteolytic lesion seems sufficient to achieve bone healing. Recurrence does not seem correlated with the surgical margin achieved, but rather with an incomplete removal of the tumoral tissue.

Conflict of interest None.

References

1. Kuruvath S, O'Donovan DG, Aspoas AR, David KM (2006) Benign fibrous histiocytoma of the thoracic spine: case report and review of the literature. *J Neurosurg Spine* 4–3:260–264
2. Sanatkumar S, Rajagopalan N, Mallikarjunaswamy B, Srinivasalu S, Sudhir NP, Usha K (2005) Benign fibrous histiocytoma of the distal radius with congenital dislocation of the radial head: a case report. *J Orthop Surg (Hong Kong)* 13–1:83–87
3. de Grooth H (2005) Benign fibrous histiocytoma. <http://www.bonetumor.org>. Accessed Mar 2011
4. Boisgard S, Bringer O, Aufauvre B, Joudet T, Kemeny JL, Michel JL, Levai JP (2000) Intraosseous xanthoma without lipid disorders. Case-report and literature review. *Joint Bone Spine* 67–1:71–74
5. Bertoni F, Unni KK, McLeod RA, Sim FH (1988) Xanthoma of bone. *Am J Clin Pathol* 90–4:377–384
6. Bertoni F, Calderoni P, Bacchini P, Sudanese A, Baldini N, Present D, Campanacci M (1986) Benign fibrous histiocytoma of bone. *J Bone Joint Surg Am* 68–8:1225–1230
7. Campanacci M, Enneking WF (1999) Benign fibrous histiocytoma. In: Campanacci M (ed) *Bone and Soft Tissue tumors: clinical features, imaging, pathology and treatment*, 2nd edn. Springer, Wien New York, pp 93–98
8. Clarke BE, Xipell JM, Thomas DP (1985) Benign fibrous histiocytoma of bone. *Am J Surg Pathol* 9–11:806–815
9. Matsuno T (1990) Benign fibrous histiocytoma involving the ends of long bone. *Skeletal Radiol* 19–8:561–566
10. Dahlin D (1978) General aspects and data on 6221 cases. In: Thomas CC (ed) *Bone tumors*, 3rd edn. Springfield, pp 116–36
11. Azouz EM (1995) Benign fibrous histiocytoma of the proximal tibial epiphysis in a 12-year-old girl. *Skeletal Radiol* 24–5:375–378
12. Balasubramanian C, Rajaraman G, Singh CS, Baliga DK (2005) Benign fibrous histiocytoma of the sacrum—diagnostic difficulties facing this rare bone tumor. *Pediatr Neurosurg* 41–5:253–257
13. Exner GU, von Hochstetter AR, Uehlinger K (1990) Benign fibrous histiocytoma of the distal femoral metaphysis. Differential diagnosis between neoplasm and growth disorder with identical morphology. *Z Orthop Ihre Grenzgeb* 128–3:308–312
14. Szeifert GT, Nemes Z, Thomazy V, Modis L (1986) Inflammatory fibrous histiocytoma of bone. *Acta Morphol Hung* 34–1(-2):95–105
15. van Giffen NH, van Rhijn LW, van Ooij A, Cornips E, Robben SG, Vermeulen A, Maza E (2003) Benign fibrous histiocytoma of the posterior arch of C1 in a 6-year-old boy: a case report. *Spine (Phila Pa 1976)*;28-18:E359-63
16. Destouet JM, Kyriakos M, Gilula LA (1980) Fibrous histiocytoma (fibroxanthoma) of a cervical vertebra. A report with a review of the literature. *Skeletal Radiol* 5–4:241–246
17. Hamada T, Ito H, Araki Y, Fujii K, Inoue M, Ishida O (1996) Benign fibrous histiocytoma of the femur: review of three cases. *Skeletal Radiol* 25–1:25–29
18. Grohs JG, Nicolakis M, Kainberger F, Lang S, Kotz R (2002) Benign fibrous histiocytoma of bone: a report of ten cases and review of literature. *Wien Klin Wochenschr* 114–1(-2):56–63
19. Lee JY, Pozderac RV, Domanowski A, Torres A (1986) Benign histiocytoma (xanthoma) of the rib. *Clin Nucl Med* 11–11:769–770
20. Macdonald D, Fornasier V, Holtby R (2002) Benign fibrohistiocytoma (xanthomatous variant) of the acromion. A case report and review of the literature. *Arch Pathol Lab Med* 126–5:599–601
21. Niemeyer P, Ludwig K, Werner M, Bernd L, Parsch D (2004) Reconstruction of the pelvic ring using an autologous free non-vascularized fibula graft in a patient with benign fibrous histiocytoma. *World J Surg Oncol* 2:38
22. Zia SA, Raza SH (2001) Benign fibrous histiocytoma of the rib. *J Pak Med Assoc* 51–4:162–163
23. Arata MA, Peterson HA, Dahlin DC (1981) Pathological fractures through non-ossifying fibromas. Review of the Mayo Clinic experience. *J Bone Joint Surg Am* 63–6:980–988
24. Kurzen H, Hartschuh W (2003) Benign cellular fibrous histiocytoma with erosion of the phalanx. *Hautarzt* 54–5:453–456