

# Meningioma

Ali-Reza Fathi · Ulrich Roelcke

Published online: 6 March 2013  
© Springer Science+Business Media New York 2013

**Abstract** Meningiomas represent the most common primary brain tumor and comprise 3 World Health Organization (WHO) grades, the most frequent being WHO grade I (90 %). Surgery is mandatory to establish the diagnosis and to remove the tumor; however, complete resection can be achieved in only <50 % of patients. Depending on the extent of resection, tumor location and the WHO grade radiation therapy can be applied. The issue of systemic treatment such as chemotherapy or targeted therapy (eg, somatostatin receptors, antiangiogenic agents) is yet not solved, particularly as current data are derived from small uncontrolled series in patients with long-standing disease and after several pretreatments. A more thorough understanding of molecular genetics, signaling pathways and prognostic factors in meningiomas should lead to the design of studies which stratify according to these factors. These studies have to be conducted in newly diagnosed patients after incomplete resection and in tumors of WHO grade II and III.

**Keywords** Meningioma · Benign brain tumor · Skull base · Neurofibromatosis · Diagnosis · Imaging · Pathology · Molecular genetics · Neurosurgery · Surgery · Radiation therapy · Radiosurgery · Somatostatin receptors · Chemotherapy · Targeted therapy

---

This article is part of the Topical Collection on *Neuro-Oncology*

A.-R. Fathi  
Department of Neurosurgery, Cantonal Hospital,  
5001 Aarau, Switzerland  
e-mail: Ali-Reza.Fathi@ksa.ch

U. Roelcke (✉)  
Department of Neurology & Brain Tumor Center,  
Cantonal Hospital, 5001 Aarau, Switzerland  
e-mail: roelcke@ksa.ch

U. Roelcke  
University of Basel, School of Medicine, 4031 Basel, Switzerland

## Introduction

Meningiomas represent the most common intracranial extra-axial neoplasia. In adults they account for approximately 30 % of central nervous system (CNS) tumors, whereas they are rare in children and adolescents (0.4 %–4.6 %) [1••]. The incidence increases with age and shows a remarkable predominance in females particularly in the 3rd to 6th decade (female:male ratio 2:1) [2]. Meningiomas are frequently detected by chance (“incidentaloma”) and show no or only minor growth particularly when tumor calcification is present in the elderly [3]. They are found in up to 3 % of autopsy reports [4] in patients over 60 years old. Meningiomas can arise anywhere within the CNS, and multiple manifestations are not uncommon. Distant metastasis is very rare. The spontaneous rate of tumor growth varies [5]. Considering the aging population, improvements in treatment safety as well as the availability and performance of imaging, we are expecting an increased incidence in future daily practice [3]. This fact requires interdisciplinary networks in specialized centers to optimize the patient’s management. Special risk and benefit considerations are required upon diagnosis of smaller asymptomatic lesions. This article’s focus is on intracranial meningiomas (98 % of all meningiomas) which in up to 60 % are located in parasagittal regions, in the convexity, at the tuberculum sellae, and sphenoid ridge. Less common locations comprise the olfactory groove, falx, lateral ventricle, tentorium, middle fossa, and orbita [6].

## Histopathology, Molecular Genetics

Meningioma cells arise from the arachnoid cap cells which form the outer layer of the arachnoid mater. According to the World Health Organization (WHO) [7] meningiomas are categorized into 3 grades. Criteria include cell type, mitotic activity, cellularity, necrosis, and brain invasion. *Benign meningiomas* (WHO grade I) represent approximately

90 % of all meningiomas and show several histologic variants: meningothelial, fibrous (fibroblastic), transitional (mixed), psammomatous, angiomatous, microcystic, secretory, lymphoplasmacyte-rich, metaplastic meningioma. They lack criteria of atypical or anaplastic meningioma. *Atypical meningiomas* (WHO grade II) represent approximately 5 %–7 % of all meningiomas and comprise clear-cell or chordoid variants. They show a mitotic index of  $\geq 4$  mitoses per 10 high-power fields (HPF), increased cellularity, a high nucleus: cytoplasm ratio ('small cells'), sheet-like growth, and foci of spontaneous necrosis which are not induced by embolization or radiation therapy. Even in the absence of the cellular criteria of WHO grade II also brain invasion (Fig. 1) qualifies for WHO grade II because of recurrence and mortality rates similar to atypical meningiomas. *Anaplastic meningiomas* (WHO grade III, 3 % of all meningiomas) include papillary and rhabdoid variants, and show a mitotic index of  $\geq 20$  mitoses per 10 HPF and larger zones of spontaneous necrosis. On microscopy they can resemble carcinoma, sarcoma, or melanoma. Immunohistochemistry eg, with staining against vimentin or epithelial membrane antigen may assist in the differentiation of meningioma from these tumors [8].

Meningiomas can originate spontaneously or be part of hereditary syndromes such as neurofibromatosis type 2 (NF2), Li-Fraumeni, Turcot, Gardner, von Hippel-Lindau, Cowden, Gorlin, and multiple endocrine neoplasia type I [9]. For most of these syndromes the exact genetic relationship to meningiomas has not been unraveled yet. The most frequent genetic abnormality in meningiomas is genetic loss of chromosome 22.q12.2. This chromosome band harbors the NF2 gene. Its product, the Merlin protein, is considered to participate in the regulation of cell-to-cell contact and motility [10]. The majority of NF2-associated meningiomas and approximately one half of sporadic meningiomas show mutations of the NF2 gene. As the frequency of NF2 mutations is similar in meningiomas of WHO grade I-III this suggests that NF2 is rather involved in meningiomas initiation than in progression. Meningioma progression is associated with a plethora of molecular and genetic alterations (eg, loss of tumor suppressor genes, hypermethylation of CpG island) as well as changes of signal transduction. The latter includes cell membrane receptors such as sex hormone and somatostatin receptors. Within autocrine loops several

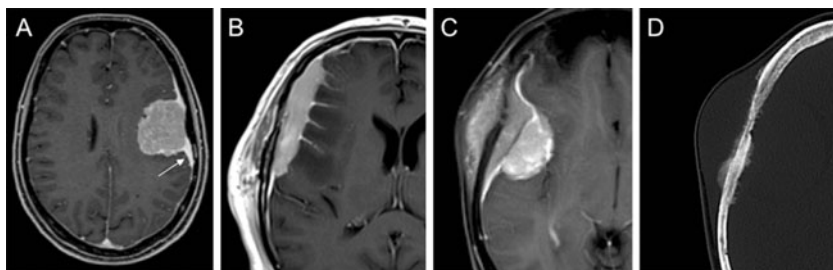
growth factors and their receptors are expressed, eg, epidermal growth factor (EGFR), EGF-like domain-containing protein 6 (EGFL6) [11], platelet derived growth factor (PDGFR), insulin-like growth factor II (IGF-II), transforming growth factor- $\alpha$  (TGF- $\alpha$ , which binds to EGFR) [12]. Among intracellular signaling pathways the activation of PI3K/Akt proteins reflects poor clinical course and brain invasion. Mutations in the hedgehog transmembrane receptor and activation of Notch receptors results in meningioma development and chromosomal instability. The role of all these factors (ie, whether they contribute to progression or represent secondary events) is yet unclear [12, 13].

### Prognostic Factors

The term 'prognostic factor' is differently used across the literature on meningiomas and includes the 'risk' for incidence and events such as tumor development eg, due to radiation exposure as well as the risk for recurrence. The latter depends on factors associated with the individual tumor presentation (genetics, tumor grade) and with treatment modalities. Most studies present data on prognostic factors which show significant correlation with the WHO tumor grade. Only a few studies have addressed the variability of the clinical course or treatment response eg, within a given tumor grade. Identification of such factors would allow stratifying patients into distinct molecular or biochemical subgroups with particular regard to post-operative therapy response.

Meningiomas which present with brain or bone invasion show poorer outcomes compared with noninvading tumors [14]. Also the status of sex hormone receptors impacts prognosis: whereas meningiomas with progesterone receptors show median recurrence rates of 5 %, meningiomas with estrogen receptors or tumors lacking sex hormone receptors present with recurrence rates of up to 30 % [15]. However, the extent of resection as classified by Simpson [16] and the WHO tumor grade [7] are among the most strong prognostic factors. Relapse rates in WHO grade I/II/III of 7 %/40 %/80 % have been reported, and median survival in these studies was >10/11.5/2.7 years, respectively [17, 18]. Although many patients with completely resected grade I meningiomas can be considered

**Fig. 1** Newly diagnosed meningioma. **a–c**, Axial gadolinium enhanced MRI showing dural tail (**a**), invasion of brain (**b**), invasion of bone (**c**). **d**, Axial CT corresponding to (**c**).



as cured, late recurrences are observed even after 20 years (11 %–56 %) [19].

The risk for ‘early’ recurrence within WHO grade I meningiomas was studied by investigating the expression of the osteopontin protein [20•]. This integrin-binding protein is involved in proliferation, adhesion, migration, and angiogenesis. In a series of 32 operated patients with WHO grade I meningiomas 28 % recurrences were observed at a mean follow up of 34 months. In patients with ‘early’ recurrences the osteopontin staining score from immunohistochemistry was approximately 6 times higher compared with nonrecurrent tumors [20•]. This type of study signifies the importance to assess the biological variability within distinct histologic subgroups. Results may prompt prospective trials which address the role eg, of antiangiogenic treatment in osteopontin positive meningioma.

## Diagnosis

As with other brain tumors the clinical signs of meningiomas relate to their location. Personality changes, neuropsychological deficits, sensory-motor, or visual symptoms, aphasia as well as seizures frequently occur. Skull base meningiomas present with cranial nerve dysfunction in the majority of cases. Depending on location and size hydrocephalus may evolve. Computed tomography (CT) and magnetic resonance imaging (MRI) are the tools to suspect meningioma as described below. Despite the fact that MRI has advantages over CT in assessing soft tissue characteristics, the combination with CT gives additional information regarding bone infiltration and therefore allows optimization of surgery and radiation therapy planning [21, 22].

## MRI

The characteristic signal alterations in T1- and T2- weighted MRI together with anatomical extension towards adjacent structures aids to confine the differentiation from other tumors and nonmalignant lesions [23]. Due to the absence of a blood–brain barrier meningiomas usually exhibit strong enhancement of contrast medium on CT and T1-weighted MRI (Fig. 1). The extent of brain edema is well illustrated in T2-weighted and FLAIR MRI, and is thought to be particularly extensive in WHO grade I meningiomas [24, 25]. MRI can depict arachnoid layer to predict brain adhesion and facilitates to plan the surgical dissection of tumor from brain tissue. Since the prognosis highly correlates with the extent of resection of infiltrated dura, pathologic changes of the dura can be interpreted by evaluating the dural tail sign on MRI (Fig. 1a). This information helps to choose the correct size of craniotomy to achieve the maximal distance of 2.5 cm from the tumor base in convexity meningiomas

[26]. Diffusion tensor imaging (DTI) helps in preoperative identification of displaced fibers, which is particularly helpful in planning surgical access to intraventricular meningiomas [27]. Assessment of tumor growth which may aid in treatment decisions was, so far, mainly based on the measurement of cross sectional tumor diameters. With the advance of automated volumetric and 3D reconstruction analysis a superior tool is provided for early detection of tumor growth [28].

## CT

CT provides information on hyperostosis, bone destruction, and infiltration which is of utmost importance for planning surgical and radiation strategies [22, 29]. CT also detects tumor calcification, which is a hint for slow tumor growth particularly in elderly patients [3, 30]. In addition, CT aids to clarify the spatial relationship between skull base tumors, paranasal sinuses, and pneumatization of the anterior clinoid process.

## Cerebral Angiography (CAG)

Most meningiomas harbor a very dense vascularization, which in case of large tumors carries the risk of intense intraoperative bleeding. Preoperative embolization can reduce surgical morbidity in selected cases [31]. Embolization might rarely be applied prior to radiation or as standalone therapy. Careful interdisciplinary decision making is required before the indication of embolization is made, since risks of embolization such as hemorrhage, extensive edema formation, or vascular infarctions can have negative impact on functional outcome [32]. CAG also unravels the degree of proximity between skull-base meningiomas and vascular structures with exact depiction of stenosis, occlusion, and incidental aneurysms. Vessel wall irregularities on CAG are a more sensitive hint to tumor-invasion into the vessel wall compared with MRI.

## SPECT and PET

Single Photon Emission Computed Tomography (SPECT) and Positron Emission Tomography (PET) provide information about cellular processes and biological characteristics of tumors. In meningiomas the clinically most relevant issue is the search for the presence of somatostatin receptors (SSR) [33]. The presence of SSR favors the diagnosis of meningioma in a patient not amenable for surgery. It aids in the target volume delineation for radiation therapy planning [34], and in the differentiation between residual or recurrent tumor from scar tissue [35]. The presence of SSR also allows targeted therapy with receptor binding ligands (see below). However, future well-designed clinical studies are

warranted to demonstrate the feasibility and value of PET for clinical routine.

Ongoing research in all imaging modalities is focusing on the prediction of histologic grade and improving differential diagnosis, eg, dural metastasis, hemangiopericytoma vs meningioma. So far none of these modalities are reliable enough to substitute the histopathologic analysis of tumor tissue.

## Treatment

Despite the lack of class I evidence based guidelines, correct decision making in patients with newly diagnosed intracranial mass suspicious for meningioma is crucial for achieving optimal clinical outcome and patient survival [36, 37]. Complete tumor resection is associated with the longest progression-free and overall survival, and Simpson grade I resection should continue to be the goal for convexity meningiomas [16]. However, total resection cannot be achieved in more than 50 % of newly diagnosed meningiomas. Therefore partial tumor removal followed by observation, radiation therapy, or in rare cases, systemic chemotherapy has to be discussed in an interdisciplinary approach. Based on the natural history patients younger than 60 to 70 years of age and those with meningiomas characterized by surrounding brain hyperintensity on T2-weighted MRI (edema), absence of calcification, and tumor diameter > 25–30 mm exhibit a higher risk for early recurrence [3, 17, 30, 38]. Special awareness of detecting genetic disorders is crucial to respect the course of natural history and act accordingly, especially in patients with NF2 associated tumors which frequently demonstrate a saltatory growth pattern [39]. Because new tumors can develop in NF2 patients over their lifetime and because radiographic and symptomatic progression are unpredictable, resection may be best reserved for symptom-producing tumors, de novo, and brain edema-associated meningiomas in NF2 patients [39, 40].

## Surgery

Indications for surgery in general include symptomatic tumors with the option for total resection, subtotal resection followed by radiation therapy of remnants, or growth of asymptomatic tumors on serial images. Surgical risks have to be discussed with the patient, and the patient's preference has to be respected based on this discussion [41, 42]. Surgical strategies have significantly improved outcomes within the past 30 years [17, 43]. The introduction of the surgical microscope in neurosurgery was a major step in improving safety with extension of surgical tumor removal [44]. Additional technological progress enhanced surgical safety and extent of resection in the past years. This includes tools such as neuro-navigation [17], intraoperative electrophysiology, indocyanine angiography [45], 5-ALA [46, 47], intraoperative MRI [48], and intraoperative

sonography [49]. With the adoption of these utilities Simpson grade I resection is achieved in the majority of convexity meningiomas with minimal morbidity [17]. In case of tumor-invasion into to skull, bone removal and intraoperative molded cranioplasty [29, 50] has to be considered to prevent tumor recurrence originating from skull.

## Endoscopy

Advanced knowledge in the endoscopic anatomy of the skull base delivered new surgical corridors to minimize morbidity related to the surgical access and cosmetic issues. However, compared with traditional craniotomies, the major limitation of the endoscopic approach is the restricted surgical corridor, challenging cranial base repair, and limited hemostasis in hypervascularized tumors. Over the same period of time, new open surgical trans-cranial approaches have challenged the traditional operative corridors to the anterior skull base. Neither of the techniques exclude each other and the future direction will be a combined approach to provide the benefits of all techniques and to maximize resection with minimized morbidity and mortality [17, 51–54].

## Radiation Therapy

Radiation therapy (RT) evolved as a standard in the treatment of meningiomas. Indications for RT depend on tumor size, stage of disease, WHO grade, and include residual or non-resectable meningioma at the time of first diagnosis, recurrent or progressive nonresectable meningioma, and meningioma of WHO grade II and III. The RT modalities comprise fractionated external beam radiation, stereotactic radiosurgery, and particle therapy (mainly proton therapy). Stereotactic radiosurgery harbors a growing list of names depending of the manufacturer's naming (eg, linear accelerator (Linac), CyberKnife® (Accuray Inc., Sunnyvale, CA, USA), Gamma Knife® (Elekta Instruments, Stockholm, Sweden), Novalis® (BrainLAB, Heimstetten, Germany) etc.). In large tumors the side effects and limited tumor control outweigh the benefits of RT compared with surgery [55]. Complications of RT include alopecia, tooth loss, new onset of seizures, neurologic deficits, cranial nerve palsy, headache, edema, and radio-necrosis or delayed hydrocephalus. On the other hand tumor control rates for stereotactic radiosurgery are equivalent to sub-total resection with lower morbidity than surgery of skull base tumors [56, 57].

The goals of RT are prolongation of progression-free survival with preservation of neurologic function. Complete tumor eradication is not possible with RT modalities to date, however, partial tumor shrinkage has been observed in different series [58–60]. The assessment of RT effects is in general difficult because of the different RT modalities used in meningioma treatment and limited data of randomized

**Table 1** Systemic therapies in meningioma patients

| Therapy   | Ref. | Number of patients (WHO I/II/III) | Results  |
|---|------|-----------------------------------|--|
| Hydroxyurea   | [71] | 20 (16/3/1)                       | 1 patient with minor response; 93 % PFS-12 in WHO I; progression within 3 to 10 months in WHO II and III     |
| Hydroxyurea   | [72] | 35 (0/22/13)                      | no radiographic response; 3 % PFS-6; PFS 2 months  |
| Temozolomide  | [73] | 16 (16/0/0)                       | no radiographic response; TTP 5 months; OS 7.5 months  |
| Estrogen receptor; tamoxifen  | [74] | 19 (not reported)                 | 3 patients with minor responses (CT or MRI), 6 patients stable for 31 months, TTP 15.1 months                |
| Progesteron receptor; mifepristone  | [75] | 28 (*)                            | minor responses in 8 patients (men, premenopausal women)   |
| SSR; octreotide   | [76] | 16 (8/3/5)                        | 31 % partial response, 31 % stable disease; TTP 5 months   |
| SSR; octreotide   | [77] | 11 (4/2/5)                        | no radiographic response; TTP 17 weeks; OS 2.7 years   |
| SSR; <sup>90</sup> Y-DOTATOC  | [69] | 29 (14/9/6)                       | 33 % stable disease at 12 months; TTP WHO I 61 months, TTP WHO II,III 13 months                              |
| SSR; <sup>177</sup> Lu-DOTATOC, -DOTATATE immediately followed by radiation therapy | [70] | 9 (7/2/0)                         | each 1 patient with complete and partial remission; other patients stable at median follow-up of 13.4 months |
| VEGF  | [78] | 15 (0/6/9)                        | 43.8 % PFS-6; PFS 26 weeks   |
| VEGF alone or plus etoposide  | [79] | 13 (5/5/3)                        | 1 partial response, 11 stable disease; PFS 15.8 months   |
| PDGF-R; imatinib  | [80] | 9 (1/2/6)                         | 66.7 % PFS-6; OS 16 months   |
| EGFR; gefitinib; erlotinib  | [81] | 25 (8/9/8)                        | 32 % stable disease; 13 % PFS-12 and 50 % OS-12 in WHO I; 18 % PFS-12 and 65 % OS-12 in WHO II and III       |

*EGFR* epidermal growth factor receptor, *PDGF-R* platelet derived growth factor receptor, *PFS*, *OS*, median progression-free or overall survival, *PFS-6*, *PFS-12*, *OS-6*, *OS-12*, percentage of patients free of progression or alive at 6 and 12 months, *SSR* somatostatin receptor, *TTP* median time to progression, *VEGF* vascular endothelial growth factor

\*22 benign, 2 malignant meningioma, 4 patients without biopsy

trials in comparison with surgery [61]. Future studies are required to elaborate the optimal radiation dosage and to prevent treatment failures [62, 63].

RT has to be considered as an alternative to surgery in elderly patients with high surgical risk. One of the largest series with gamma knife treatment of benign meningiomas (5300 treated tumors) reported on 5- and 10-year progression-free survival rates of 95.2 % and 88.6 %, respectively [64••].

### Systemic Therapy

Systemic treatment has been administered as either cytotoxic or as targeted therapy. As both strategies are not considered standard treatment at the time of first diagnosis they have been given in patients with advanced or nonresectable tumors, which in many cases were heavily pretreated with various courses of surgery and radiation therapy. This led to reports on noncontrolled case studies which included small numbers of patients, and patients with various WHO grades and stages of disease. Examples are presented in the Table 1.

Targeted therapies aim at the inhibition of hormonal receptors, angiogenesis, or growth factor signaling. Overall, at best modest responses were observed yet. Somatostatin receptors (SSR) in meningiomas are of particular interest as they can be visualized with SPECT and PET [65]. SSR are

present in up to 70 % of meningiomas [66]. They are categorized into 5 subtypes, where subtype 2A (sst<sub>2A</sub>) is involved in direct (eg, cytostatic, apoptosis) and indirect (eg, antiangiogenic) effects [67]. Octreotide and pasireotide represent synthetic SSR ligands which modify the receptor activity. Pasireotide exhibits higher sst<sub>2A</sub> affinity (1.0 nmol/L) compared with octreotide (0.4) and somatostatin itself (0.2) [68]. With regard to treatment the visualization of SSR using PET has 2 major applications: (1) the PET radiotracer (eg, <sup>68</sup>Ga-DOTATOC) uptake allows delineation of the tumor volume for radiation therapy planning [34]; (2) the noninvasive detection of SSR particularly in nonoperated progressive or recurrent tumors allows meningioma treatment with either the nonradioactive labeled somatostatin (sandostatin LAR), or with octreotide charged with the therapeutic nuclide Yttrium-90 [69] or Lutetium-177 [70•] (Table 1). Two studies using pasireotide are posted on [www.clinicaltrials.gov](http://www.clinicaltrials.gov). They are denoted as active but not recruiting (NCT00859040, NCT00813592, accessed January 2013).

### Conclusions

Long-term tumor control or even cure can be achieved in many WHO I meningiomas with modern surgical and radiotherapy techniques. In the elderly asymptomatic meningiomas

(‘incidentalomas’) can be managed with a wait-and-see strategy without surgery. Meningiomas WHO I not amenable to total resection, and meningiomas of grade II and III represent the major therapeutic challenges. Whereas surgery and radiotherapy are well established at the time of tumor diagnosis and recurrence the role for systemic therapies remains unclear. Several reasons account for the latter: (1) systemic therapies have been largely administered to patients which were heavily pretreated by surgery and radiotherapy; (2) most reports are based upon retrospective, heterogeneous, and small patient series and included meningiomas with various tumor grades; (3) molecular markers or prognostic factors linked to tumor behavior were not used for stratification or randomization; (4) response criteria are not available. Given the high frequency of meningiomas prospective studies which implement these issues are strongly requested and should be feasible.

**Disclosure** Ali-Reza Fathi declares no conflict of interest. Ulrich Roelcke declares no conflict of interest.

## References

Papers of particular interest, published recently, have been highlighted as:

- Of importance
  - Of major importance
1. •• Kotecha RS, Pascoe EM, Rushing EJ, Rorke-Adams LB, Zwerdling T, Gao X, et al. Meningiomas in children and adolescents: a meta-analysis of individual patient data. *Lancet Oncol*. 2011;12(13):1229–39. *Comprehensive review on epidemiologic and outcome data for meningiomas in children and adults*.
  2. Wiemels J, Wrensch M, Claus EB. Epidemiology and etiology of meningioma. *J Neurooncol*. 2010;99(3):307–14.
  3. Oya S, Kim SH, Sade B, Lee JH. The natural history of intracranial meningiomas. *J Neurosurg*. 2011;114(5):1250–6.
  4. Nakasu S, Hirano A, Shimura T, Llana JF. Incidental meningiomas in autopsy study. *Surg Neurol*. 1987;27(4):319–22.
  5. Zeidman LA, Ankenbrandt WJ, Du H, Paleologos N, Vick NA. Growth rate of non-operated meningiomas. *J Neurol*. 2008;255(6):891–5.
  6. Greenberg M. *Handbook of Neurosurgery*. 6th ed. New York: Thieme; 2006.
  7. Louis DN, Ohgaki H, Wiestler OD, Cavenee WK, Burger PC, Jouvet A, et al. The 2007 WHO classification of tumours of the central nervous system. *Acta Neuropathol*. 2007;114(2):97–109.
  8. Artlich A, Schmidt D. Immunohistochemical profile of meningiomas and their histological subtypes. *Hum Pathol*. 1990;21(8):843–9.
  9. Hottinger AF, Khakoo Y. Neurooncology of familial cancer syndromes. *J Child Neurol*. 2009;24(12):1526–35.
  10. Zhou L, Hanemann CO, Merlin, a multi-suppressor from cell membrane to the nucleus. *FEBS Lett*. 2012;586(10):1403–8.
  11. Wang X, Gong Y, Wang D, Xie Q, Zheng M, Zhou Y, et al. Analysis of gene expression profiling in meningioma: deregulated signaling pathways associated with meningioma and egfl6 over-expression in benign meningioma tissue and serum. *PLoS One*. 2012;7(12):e52707.
  12. Ragel BT, Jensen RL. Aberrant signaling pathways in meningiomas. *J Neurooncol*. 2010;99(3):315–24.
  13. Mawrin C, Perry A. Pathological classification and molecular genetics of meningiomas. *J Neurooncol*. 2010;99(3):379–91.
  14. Gabeau-Lacet D, Aghi M, Betensky RA, Barker FG, Loeffler JS, Louis DN. Bone involvement predicts poor outcome in atypical meningioma. *J Neurosurg*. 2009;111(3):464–71.
  15. Pravdenkova S, Al-Mefty O, Sawyer J, Husain M. Progesterone and estrogen receptors: opposing prognostic indicators in meningiomas. *J Neurosurg*. 2006;105(2):163–73.
  16. Haseleid BF, Meling TR, Ronning P, Scheie D, Helseth E. Surgery for convexity meningioma: Simpson Grade I resection as the goal. *J Neurosurg*. 2012;117(6):999–1006.
  17. Black PM, Morokoff AP, Zauberman J. Surgery for extra-axial tumors of the cerebral convexity and midline. *Neurosurgery*. 2008;62(6 Suppl 3):1115–21. discussion 21–3.
  18. Yang SY, Park CK, Park SH, Kim DG, Chung YS, Jung HW. Atypical and anaplastic meningiomas: prognostic implications of clinicopathological features. *J Neurol Neurosurg Psychiatry*. 2008;79(5):574–80.
  19. Jaaskelainen J. Seemingly complete removal of histologically benign intracranial meningioma: late recurrence rate and factors predicting recurrence in 657 patients. A multivariate analysis. *Surg Neurol*. 1986;26(5):461–9.
  20. • Tseng KY, Chung MH, Sytwu HK, Lee HM, Chen KY, Chang C, et al. Osteopontin expression is a valuable marker for prediction of short-term recurrence in WHO grade I benign meningiomas. *J Neurooncol*. 2010;100(2):217–23. *Osteopontin represents an integrin-binding protein and constitutes a prognostic factor which relates to progression-free survival within the histopathologic ‘entity’ of WHO I meningiomas*.
  21. Saloner D, Uzelac A, Hettis S, Martin A, Dillon W. Modern meningioma imaging techniques. *J Neurooncol*. 2010;99(3):333–40.
  22. Omay SB, Barnett GH. Surgical navigation for meningioma surgery. *J Neurooncol*. 2010;99(3):357–64.
  23. Hoover JM, Morris JM, Meyer FB. Use of preoperative magnetic resonance imaging T1 and T2 sequences to determine intraoperative meningioma consistency. *Surg Neurol Int*. 2011;2:142.
  24. Osawa T, Tosaka M, Nagaishi M, Yoshimoto Y. Factors affecting peritumoral brain edema in meningioma: special histological subtypes with prominently extensive edema. *J Neurooncol*. 2012;111:49–57.
  25. Regelsberger J, Hagel C, Emami P, Ries T, Heese O, Westphal M. Secretory meningiomas: a benign subgroup causing life-threatening complications. *Neuro Oncol*. 2009;11(6):819–24.
  26. Qi ST, Liu Y, Pan J, Chotai S, Fang LX. A radiopathological classification of dural tail sign of meningiomas. *J Neurosurg*. 2012;117(4):645–53.
  27. Jolapara M, Kesavadas C, Radhakrishnan VV, Thomas B, Gupta AK, Bodhey N, et al. Role of diffusion tensor imaging in differentiating subtypes of meningiomas. *J Neuroradiol*. 2010;37(5):277–83.
  28. Chang V, Narang J, Schultz L, Issawi A, Jain R, Rock J, et al. Computeraided volumetric analysis as a sensitive tool for the management of incidental meningiomas. *Acta Neurochir (Wien)*. 2012;154(4):589–97. discussion 97.
  29. Fathi AR, Marbacher S, Lukes A. Cost-effective patient-specific intraoperative molded cranioplasty. *J Craniofac Surg*. 2008;19(3):777–81.
  30. Rubin G, Herscovici Z, Laviv Y, Jackson S, Rappaport ZH. Outcome of untreated meningiomas. *Isr Med Assoc J*. 2011;13(3):157–60.

31. Quinones-Hinojosa A, Kaprelian T, Chaichana KL, Sanai N, Parsa AT, Berger MS, et al. Pre-operative factors affecting resectability of giant intracranial meningiomas. *Can J Neurol Sci.* 2009;36(5):623–30.
32. Carli DF, Sluzewski M, Beute GN, van Rooij WJ. Complications of particle embolization of meningiomas: frequency, risk factors, and outcome. *AJNR Am J Neuroradiol.* 2010;31(1):152–4.
33. Afshar-Oromieh A, Giesel FL, Linhart HG, Haberkorn U, Haufe S, Combs SE, et al. Detection of cranial meningiomas: comparison of (6)(8)Ga-DOTATOC PET/CT and contrast-enhanced MRI. *Eur J Nucl Med Mol Imaging.* 2012;39(9):1409–15.
34. Gehler B, Paulsen F, Oksuz MO, Hauser TK, Eschmann SM, Bares R, et al. [68Ga]-DOTATOC-PET/CT for meningioma IMRT treatment planning. *Radiat Oncol.* 2009;4:56.
35. Thorwarth D, Muller AC, Pfannenbergs C, Beyer T. Combined PET/MR imaging using (68)Ga-DOTATOC for radiotherapy treatment planning in meningioma patients. *Recent Results Cancer Res.* 2012;194:425–39.
36. Sughrue ME, Rutkowski MJ, Aranda D, Barani IJ, McDermott MW, Parsa AT. Treatment decision making based on the published natural history and growth rate of small meningiomas. *J Neurosurg.* 2010;113(5):1036–42.
37. Yano S, Kuratsu J. Indications for surgery in patients with asymptomatic meningiomas based on an extensive experience. *J Neurosurg.* 2006;105(4):538–43.
38. Chamoun R, Krisht KM, Coldwell WT. Incidental meningiomas. *Neurosurg Focus.* 2011;31(6):E19.
39. Dirks MS, Butman JA, Kim HJ, Wu T, Morgan K, Tran AP, et al. Long-term natural history of neurofibromatosis Type 2-associated intracranial tumors. *J Neurosurg.* 2012;117(1):109–17.
40. Goutagny S, Bah AB, Henin D, Parfait B, Grayeli AB, Sterkers O, et al. Longterm follow-up of 287 meningiomas in neurofibromatosis type 2 patients: clinical, radiological, and molecular features. *Neuro Oncol.* 2012;14(8):1090–6.
41. Adachi K, Kawase T, Yoshida K, Yazaki T, Onozuka S. ABC Surgical Risk Scale for skull base meningioma: a new scoring system for predicting the extent of tumor removal and neurological outcome. *Clinical article. J Neurosurg.* 2009;111(5):1053–61.
42. Gerlach R, Raabe A, Scharer I, Meixensberger J, Seifert V. Post-operative hematoma after surgery for intracranial meningiomas: causes, avoidable risk factors and clinical outcome. *Neurol Res.* 2004;26(1):61–6.
43. • Strassner C, Buhl R, Mehdorn HM. Recurrence of intracranial meningiomas: did better methods of diagnosis and surgical treatment change the outcome in the last 30 years? *Neurol Res.* 2009;31(5):478–82. *With better operating modalities and additional treatment with radiation and gamma knife, the mortality decreased significantly from 12 % to 3 % and the outcome of the patients is still improving, so that even elderly patients can undergo surgical treatment with minor risks.*
44. Al-Mefty O, Holoubi A, Rifai A, Fox JL. Microsurgical removal of suprasellar meningiomas. *Neurosurgery.* 1985;16(3):364–72.
45. Kim EH, Cho JM, Chang JH, Kim SH, Lee KS. Application of intraoperative indocyanine green videoangiography to brain tumor surgery. *Acta Neurochir (Wien).* 2011;153(7):1487–95. discussion 94–5.
46. Coluccia D, Fandino J, Fujioka M, Cordovi S, Muroi C, Landolt H. Intraoperative 5-aminolevulinic-acid-induced fluorescence in meningiomas. *Acta Neurochir (Wien).* 2010;152(10):1711–9.
47. Bekelis K, Valdes PA, Erkmen K, Leblond F, Kim A, Wilson BC, et al. Quantitative and qualitative 5-aminolevulinic acid-induced protoporphyrin IX fluorescence in skull base meningiomas. *Neurosurg Focus.* 2011;30(5):E8.
48. Soleman J, Fathi AR, Marbacher S, Fandino J. The role of intraoperative magnetic resonance imaging in complex meningioma surgery magnetic resonance imaging. *Magnetic Resonance Imaging.* 2012;In Press [accepted].
49. Solheim O, Selbekk T, Lindseth F, Unsgard G. Navigated resection of giant intracranial meningiomas based on intraoperative 3D ultrasound. *Acta Neurochir (Wien).* 2009;151(9):1143–51.
50. Marbacher S, Coluccia D, Fathi AR, Anderegg L, Beck J, Fandino J. Intraoperative patient-specific reconstruction of partial bone flap defects after convexity meningioma resection. *World Neurosurg.* 2013;79(1):124–30.
51. Dehdashti AR, Ganna A, Witterick I, Gentili F. Expanded endoscopic endonasal approach for anterior cranial base and suprasellar lesions: indications and limitations. *Neurosurgery.* 2009;64(4):677–87. discussion 87–9.
52. Fatemi N, Dusick JR, de Paiva Neto MA, Malkasian D, Kelly DF. Endonasal versus supraorbital keyhole removal of craniopharyngiomas and tuberculoma sellae meningiomas. *Neurosurgery.* 2009;64(5 Suppl 2):269–84. discussion 84–6.
53. Komotar RJ, Starke RM, Raper DM, Anand VK, Schwartz TH. Endoscopic endonasal versus open transcranial resection of anterior midline skull base meningiomas. *World Neurosurg.* 2012;77(5–6):713–24.
54. Schroeder HW, Hickmann AK, Baldauf J. Endoscope-assisted microsurgical resection of skull base meningiomas. *Neurosurg Rev.* 2011;34(4):441–55.
55. Bledsoe JM, Link MJ, Stafford SL, Park PJ, Pollock BE. Radiosurgery for large-volume (> 10 cm<sup>3</sup>) benign meningiomas. *J Neurosurg.* 2010;112(5):951–6.
56. Bloch O, Kaur G, Jian BJ, Parsa AT, Barani IJ. Stereotactic radiosurgery for benign meningiomas. *J Neurooncol.* 2012;107(1):13–20.
57. Flannery TJ, Kano H, Lunsford LD, Sirin S, Tormenti M, Niranjana A, et al. Long-term control of petroclival meningiomas through radiosurgery. *J Neurosurg.* 2010;112(5):957–64.
58. Astner ST, Theodorou M, Dobrei-Ciuchendea M, Auer F, Kopp C, Molls M, et al. Tumor shrinkage assessed by volumetric MRI in the long-term follow-up after stereotactic radiotherapy of meningiomas. *Strahlenther Onkol.* 2010;186(8):423–9.
59. Kondziolka D, Madhok R, Lunsford LD, Mathieu D, Martin JJ, Niranjana A, et al. Stereotactic radiosurgery for convexity meningiomas. *J Neurosurg.* 2009;111(3):458–63.
60. Kondziolka D, Mathieu D, Lunsford LD, Martin JJ, Madhok R, Niranjana A, et al. Radiosurgery as definitive management of intracranial meningiomas. *Neurosurgery.* 2008;62(1):53–8. discussion 8–60.
61. Stessin AM, Schwartz A, Judanin G, Pannullo SC, Boockvar JA, Schwartz TH, et al. Does adjuvant external-beam radiotherapy improve outcomes for nonbenign meningiomas? A Surveillance, Epidemiology, and End Results (SEER)-based analysis. *J Neurosurg.* 2012;117(4):669–75.
62. Askoxyllakis V, Zabel-du Bois A, Schlegel W, Debus J, Huber P, Milker-Zabel S. Patterns of failure after stereotactic radiotherapy of intracranial meningioma. *J Neurooncol.* 2010;98(3):367–72.
63. Attia A, Chan MD, Mott RT, Russell GB, Seif D, Daniel Bourland J, et al. Patterns of failure after treatment of atypical meningioma with gamma knife radiosurgery. *J Neurooncol.* 2012;108(1):179–85.
64. •• Santacrose A, Walier M, Regis J, Liscak R, Motti E, Lindquist C, et al. Longterm tumor control of benign intracranial meningiomas after radiosurgery in a series of 4565 patients. *Neurosurgery.* 2012;70(1):32–9. discussion 9. *One of the largest series with gamma knife treatment of benign meningiomas (5300 treated tumors) reported on 5- and 10-year progression-free survival rates of 95.2 % and 88.6 %, respectively.*
65. Henze M, Dimitrakopoulou-Strauss A, Milker-Zabel S, Schuhmacher J, Strauss LG, Doll J, et al. Characterization of 68Ga-DOTA-

- D-Phe1-Tyr3-octreotide kinetics in patients with meningiomas. *J Nucl Med.* 2005;46(5):763–9.
66. Schulz S, Pauli SU, Handel M, Dietzmann K, Firsching R, Holtt V. Immunohistochemical determination of five somatostatin receptors in meningioma reveals frequent overexpression of somatostatin receptor subtype sst2A. *Clin Cancer Res.* 2000;6(5):1865–74.
67. Florio T. Molecular mechanisms of the antiproliferative activity of somatostatin receptors (SSTRs) in neuroendocrine tumors. *Front Biosci.* 2008;13(1):822–40.
68. Bruns C, Lewis I, Briner U, Meno-Tetang G, Weckbecker G. SOM230: a novel somatostatin peptidomimetic with broad somatotropin release inhibiting factor (SRIF) receptor binding and a unique antisecretory profile. *Eur J Endocrinol.* 2002;146(5):707–16.
69. Bartolomei M, Bodei L, De Cicco C, Grana CM, Cremonesi M, Botteri E, et al. Peptide receptor radionuclide therapy with (90)Y-DOTATOC in recurrent meningioma. *Eur J Nucl Med Mol Imaging.* 2009;36(9):1407–16.
70. Kreissl MC, Hanscheid H, Lohr M, Verburg FA, Schiller M, Lassmann M, et al. Combination of peptide receptor radionuclide therapy with fractionated external beam radiotherapy for treatment of advanced symptomatic meningioma. *Radiat Oncol.* 2012;7:99. 'Upfront' use of <sup>177</sup>Lu-DOTATOC in newly diagnosed meningioma WHO I.
71. Mason WP, Gentili F, Macdonald DR, Hariharan S, Cruz CR, Abrey LE. Stabilization of disease progression by hydroxyurea in patients with recurrent or unresectable meningioma. *J Neurosurg.* 2002;97(2):341–6.
72. Chamberlain MC. Hydroxyurea for recurrent surgery and radiation refractory high-grade meningioma. *J Neurooncol.* 2012;107(2):315–21.
73. Chamberlain MC, Tsao-Wei DD, Groshen S. Temozolomide for treatment-resistant recurrent meningioma. *Neurology.* 2004;62(7):1210–2.
74. Goodwin JW, Crowley J, Eyre HJ, Stafford B, Jaeckle KA, Townsend JJ. A phase II evaluation of tamoxifen in unresectable or refractory meningiomas: a Southwest Oncology Group study. *J Neurooncol.* 1993;15(1):75–7.
75. Grunberg SM, Weiss MH, Russell CA, Spitz IM, Ahmadi J, Sadun A, et al. Long-term administration of mifepristone (RU486): clinical tolerance during extended treatment of meningioma. *Cancer Invest.* 2006;24(8):727–33.
76. Chamberlain MC, Glantz MJ, Fadul CE. Recurrent meningioma: salvage therapy with long-acting somatostatin analogue. *Neurology.* 2007;69(10):969–73.
77. Johnson DR, Kimmel DW, Burch PA, Cascino TL, Giannini C, Wu W, et al. Phase II study of subcutaneous octreotide in adults with recurrent or progressive meningioma and meningeal hemangiopericytoma. *Neuro Oncol.* 2011;13(5):530–5.
78. Nayak L, Iwamoto FM, Rudnick JD, Norden AD, Lee EQ, Drappatz J, et al. Atypical and anaplastic meningiomas treated with bevacizumab. *J Neurooncol.* 2012;109(1):187–93.
79. Lou E, Sumrall AL, Turner S, Peters KB, Desjardins A, Vredenburgh JJ, et al. Bevacizumab therapy for adults with recurrent/progressive meningioma: a retrospective series. *J Neurooncol.* 2012;109(1):63–70.
80. Horak P, Wohrer A, Hassler M, Hainfellner J, Preusser M, Marosi C. Imatinib mesylate treatment of recurrent meningiomas in preselected patients: a retrospective analysis. *J Neurooncol.* 2012;109(2):323–30.
81. Norden AD, Raizer JJ, Abrey LE, Lamborn KR, Lassman AB, Chang SM, et al. Phase II trials of erlotinib or gefitinib in patients with recurrent meningioma. *J Neurooncol.* 2010;96(2):211–7.