

Monoenergetic computed tomography reconstructions reduce beam hardening artifacts from dental restorations

Paul Stolzmann · Sebastian Winklhofer ·
Nicole Schwendener · Hatem Alkadhi ·
Michael J. Thali · Thomas D. Ruder

Accepted: 6 February 2013 / Published online: 20 March 2013
© Springer Science+Business Media New York 2013

Abstract The aim of this study was to assess the potential of monoenergetic computed tomography (CT) images to reduce beam hardening artifacts in comparison to standard CT images of dental restoration on dental post-mortem CT (PMCT). Thirty human decedents (15 male, 58 ± 22 years) with dental restorations were examined using standard single-energy CT (SECT) and dual-energy CT (DECT). DECT data were used to generate monoenergetic CT images, reflecting the X-ray attenuation at energy levels of 64, 69, 88 keV, and at an individually adjusted optimal energy level called OPTkeV. Artifact reduction and image quality of SECT and monoenergetic CT were assessed objectively and subjectively by two blinded readers. Subjectively, beam artifacts decreased visibly in 28/30 cases after monoenergetic CT reconstruction. Inter- and intra-reader agreement was good ($k = 0.72$, and $k = 0.73$ respectively). Beam hardening artifacts decreased significantly with increasing monoenergies

(repeated-measures ANOVA $p < 0.001$). Artifact reduction was greatest on monoenergetic CT images at OPTkeV. Mean OPTkeV was 108 ± 17 keV. OPTkeV yielded the lowest difference between CT numbers of streak artifacts and reference tissues (-163 HU). Monoenergetic CT reconstructions significantly reduce beam hardening artifacts from dental restorations and improve image quality of post-mortem dental CT.

Keywords Forensic radiology · Post-mortem CT · Dental CT · Dual-energy CT · Monoenergetic CT · Artifact reduction

Introduction

The identification of a decedent is an integral part of any post-mortem forensic investigation [1]. Dental X-ray images are often used for this purpose and the comparison of ante-mortem to post-mortem dental images represents a secure and established method of identification [2]. The implementation of post-mortem computed tomography (PMCT) in forensic medicine spurred investigators to assess the potential of dental PMCT in recent years [3, 4]. Dental PMCT holds several advantages over conventional radiographs, most notably three-dimensional image reconstruction and in situ, non-invasive documentation [3, 4]. Three-dimensional reconstructions of teeth, root channels, or dental restorations, may be beneficial for identification purposes.

However, dental CT datasets often feature tissues and materials with a wide range of CT numbers, such as cavities (200 HU), bones (1,200–1,800 HU), teeth (2,000 HU) and dental fillings (temporary fillings: 6,000–8,500 HU, composite fillings: 4,500–1,7000 HU, amalgam/gold

P. Stolzmann · S. Winklhofer · N. Schwendener ·
M. J. Thali · T. D. Ruder (✉)
Department of Forensic Medicine and Imaging, Institute
of Forensic Medicine, University of Zurich, Winterthurerstrasse
190/52, 8057 Zurich, Switzerland
e-mail: thomas.ruder@irm.uzh.ch; thomas_ruder@hotmail.com

P. Stolzmann · S. Winklhofer · H. Alkadhi
Institute of Diagnostic and Interventional Radiology, University
Hospital Zurich, Raemistrasse 100, 8091 Zurich, Switzerland

N. Schwendener
Institute of Forensic Medicine, University of Bern, Buehlstrasse
20, 3012 Bern, Switzerland

T. D. Ruder
Institute of Diagnostic, Interventional, and Pediatric Radiology,
University Hospital Bern, Freiburgstrasse, 3010 Bern,
Switzerland

>30,700 HU) [5]. High attenuation objects such as metals can induce artifacts resulting in hypodense or hyperdense streaks or radially emerging dark and bright bands on CT images [6]. Such streak artifacts are a common finding on standard dental CT images and may negatively affect the radiologic assessment of the detail of restoration morphology and surrounding structures such as the alveolar bone of the maxilla and mandible [7]. These artifacts are caused by two effects, namely photon starvation and beam hardening.

Photon starvation occurs when an X-ray beam is completely absorbed by an object and the number of photons reaching the X-ray detector is insufficient for correct image reconstruction [6, 8]. The result of photon starvation is linear horizontal streak artifacts in the path of the X-ray beam and/or increased image noise. Its occurrence can be reduced by increasing the output of photons at the X-ray tube (i.e., increasing the tube current). Beam hardening on the other hand is caused by a different mechanism. A standard X-ray beam consists of photons that have a wide spectrum of energies. During the transmission through a dense object, low energy photons are absorbed to a greater extent than high energy photons. Upon reaching the detector plate, the X-ray beam therefore consists primarily of high energy photons. This increase of mean beam energy is called “beam hardening.” Two effective methods to reduce beam hardening are iterative image reconstruction algorithms and X-ray beam pre-hardening by filtering out low energy photons [9, 10].

A novel approach to reduce beam hardening artifacts on computed tomography (CT) images is based on the reconstruction of monoenergetic CT images from dual-energy CT (DECT) datasets. This method has shown promising results in the reduction of artifacts caused by prosthetic joints and osteosynthetic devices in musculoskeletal imaging [8, 11].

In DECT an object is scanned with two different X-ray beams simultaneously [12]. Each beam has a different peak energy level [usually 80 and 140 kilovolt peak (kVp)] [12]. This means that during a DECT, the X-ray attenuation of an object is measured with two different X-ray spectrums. Based on this information, monoenergetic CT images can be extrapolated, which reflect the CT numbers of the scanned object at one specific energy level [8, 11]. These calculated monoenergetic CT images are immune to beam artifacts.

To date the benefit of monoenergetic CT images had only been assessed in relation to larger objects, such as orthopedic devices and prosthesis [8, 11]. The aim of this study was to assess the potential of monoenergetic CT images to reduce beam hardening artifacts when compared to standard CT images of dental restoration on dental PMCT.

Materials and methods

Materials

The study was approved by both our institutional review board and the public prosecution department. Post-mortem dental CT datasets from 35 adult human cadavers who had been delivered to our institute for forensic evaluation were randomly and retrospectively selected from our digital picture archiving and communication system. Inclusion criterion was prior restorative dental treatment ($n = 35$). Exclusion criterion was presence of full dentures ($n = 5$). This resulted in a final study population of 30 human cadavers with dental restorations ($n = 30$) and bridges ($n = 7$) in 15 females and 15 males (mean age 58 ± 22 years, range 19–95 years). None of the decedents carried implants.

CT data acquisition

All examinations were performed on a second generation dual-source CT scanner (Somatom Definition Flash VA40A, Siemens Healthcare, Forchheim, Germany). All scans were obtained using the following parameters: detector collimation 64×0.6 mm, slice acquisition $2 \times 128 \times 0.6$ mm, pitch and rotation time 0.7 and 0.33 s, tube current time products with DECT 330 mAs/rot for tube A and 110 mAs/rot for tube B. Tube voltages were set at 80 and 140 kVp for tube A and tube B respectively. The 140 kVp spectrum was modified using a tin filter to pre-harden the X-ray beam and minimize the overlap of high and low energy spectrums as described by Stolzmann et al. [10]. All image data was reconstructed at a slice thickness of 1.0 mm with an increment of 0.5 mm. The image reconstruction kernel was D30 for the high and low energy DECT acquisitions as well as for the standard single-energy images single-energy CT (SECT) [13]. Raw data were acquired using a standard CT scale as an extended CT scale is currently not available on DECT [5].

CT data analysis

Images were evaluated using DECT post-processing software (syngo, software VA31, monoenergetic application) installed on a Leonardo workstation (Siemens HealthCare, Forchheim, Germany). This software separates the DECT data in two datasets based on the X-ray attenuation of the scanned materials at 80 and 140 kVp. The X-ray attenuation of a material is primarily caused by two different types of energy absorption, namely the Compton scatter and the photoelectric effect [14]. At energy levels over 100 kV, attenuation is mainly the result of Compton scatter [15]. It is related to the electron density of an object, but not to

number of protons in the atomic nucleus. At X-ray energy levels below 100 kV, absorption primarily depends on the photoelectric effect, which is strongly related to the number of protons in the atomic nucleus (i.e., the atomic number Z) but not to the electron density [15]. This difference is the fundament of material decomposition with DECT. Based on DECT material decomposition, the software is able to extrapolate CT images reflecting the X-ray attenuation of an object at any specific energy level: a so-called monoenergetic CT image [8, 11].

Monoenergetic CT images were calculated at three standard energy levels (64, 69, and 88 keV) and one subjectively selected energy level, called optimal energy level (OPTkeV). The standard energy levels represent the mean energy of a standard spectral X-ray beam at 120 kVp (64 keV) and 140 kVp (69 keV), and of a pre-hardened, tin-filtered spectral X-ray beam at 140 kVp (88 keV) [8]. OPTkeV was selected manually and for each case individually through visual reduction of streak artifacts by both observers who were involved in the read-out of the study. Default display window width and level settings were 2,500 and 800 HU, respectively.

The study supervisor (who was not involved in the data read-out) selected one single slice with significant artifacts from each SECT dataset. The same slice was also selected from all four monoenergetic CT datasets. These five images of all 30 cases were used for both qualitative and quantitative assessment of image artifacts. Qualitative assessment was performed by two blinded observers who evaluated the extent of artifacts on all five images of every case. They rated the effect of the artifacts on image quality using a 4-point Likert scale: (1) excellent image quality (no artifacts, image suitable for diagnostic purposes); (2) good image quality (minor artifacts, image suitable for diagnostic purposes); (3) limited image quality (significant artifacts but delineation of adjacent structures possible, image still suitable for diagnostic purposes); and (4) poor image quality (extensive streaking artifacts hindering the delineation of adjacent structures, image not suitable for diagnostic purposes). Final decisions were arrived at by consensus. Images at 69 keV were evaluated twice to determine inter-reader reliability. Additionally, one reader repeated the evaluation after 4 months to determine intra-reader agreement. To determine the extent of artifacts quantitatively the CT number within the most pronounced streak artifact was measured on all monoenergetic CT images. A second measurement was performed in an equivalent tissue that was not affected by streak artifacts. The CT numbers were measured using an electronic caliper tool (region of interest) provided by the software. During measurements the rims of an object were carefully avoided to prevent to ensure reliable measurements.

Statistical analysis

Data analysis was performed using commercially available software (PASW Statistics 18, release 18.0.0, Chicago, IL, USA). Continuous variables were expressed as means \pm standard deviations. Categorical variables and qualitative parameters were expressed as frequencies (%). Inter- and intra-reader agreement regarding the classification of image quality (i.e., the Likert scale) and quantitative parameters (i.e., CT number of streaking artifacts) was analyzed by using weighted kappa statistics and Spearman's rank correlation coefficient. A kappa value >0.81 corresponded to an excellent agreement and a kappa value of 0.61–0.80 corresponded to a good agreement. The Mantel–Haenszel χ^2 test was used to compare image quality between SECT images and monoenergetic CT reconstructions. Cramer's V correlation coefficient was utilized for evaluating associations between image quality and dataset.

The inter-reader agreements regarding OPTkeV were analyzed by using intra-class correlation coefficients (ICC). According to Landis and Koch, ICC values of 0.61–0.80 were interpreted as substantial, and 0.81–1.00 as excellent agreement [16]. Comparison of streaking artifact densities on standard SECT and monoenergetic CT reconstructions was carried out using analysis of variances (ANOVA) for repeated-measures. Mean differences between OPTkeV and monoenergies of 64, 69, and 88 keV were assessed by using one sample t tests. Receiver operating characteristic (ROC) analyses for the prediction of studies with poor image quality were applied to CT numbers of streaking artifacts. Point estimates, 95 % confidence intervals, and the area under the curve (AUC), were calculated. A p value <0.05 indicates statistical significance.

Results

Qualitative assessment of image artifacts

Inter-reader agreement regarding the classification of image artifacts with the 4-point Likert-scale was good ($k = 0.72$, $p < 0.001$). The same was noted for intra-reader agreement ($k = 0.73$, $p < 0.001$). Based on the 4-point Likert-score, the quality of the CT images was rated suitable for diagnostic purposes (i.e., all images with Likert-scores 1–3) in 28/30 cases (93 %) of both the standard SECT images and the monoenergetic CT reconstructions. Image quality was rated to be not suitable for diagnostic purposes (i.e., Likert-score of 4) in only 2/30 cases (7 %) on SECT and monoenergetic CT (Fig. 1). Overall, the extent of artifacts decreased as the energy level on monoenergetic CT images increased (Fig. 2). However, in

cases with extensive streaking artifacts on standard SECT images, the image quality did not improve after monoenergetic CT reconstruction.

Quantitative assessment of image artifacts

Mean CT numbers of streaking artifacts are shown in Fig. 3. The mean CT number measured in the most pronounced streak was strongly negative. The corresponding reference CT number was consistent soft tissue (average HU: -111 ± 176 and 52 ± 35 HU, respectively). Streaking artifacts decreased significantly (repeated-measures ANOVA $p < 0.0001$) as the level of monoenergy increased. OPTkeV yielded the lowest mean difference of -163 HU between CT numbers of streaking artifacts and those of the reference tissues. Mean OPTkeV was 108 ± 17 keV (72–141 keV) (Fig. 3). There was a good inter-reader agreement regarding the setting of the individual OPTkeV energy level (ICC = 0.79, $p < 0.001$). The energy level of OPTkeV differed significantly ($p < 0.001$) from the energy levels of the standard monoenergy levels (i.e., 64, 69, and 88 keV). There was a high correlation between the measured CT numbers of streaking artifacts during individual read-out sessions ($\rho = 0.96$, $p < 0.001$). ROC analyses revealed that the CT numbers of streaking artifacts had a significant effect on of image quality on both standard SECT and monoenergetic CT at OPTkeV (both, AUC = 0.93; 95 %CI 0.80–1.00, $p < 0.05$).

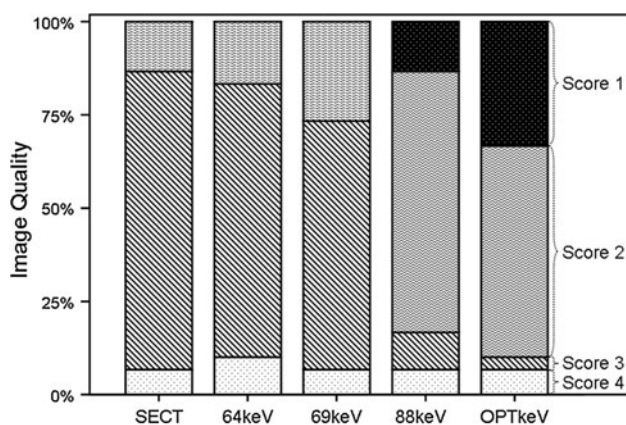


Fig. 1 Image quality on standard single-energy CT (SECT) and monoenergetic CT reconstructions at different energy levels (64, 69, 88 keV) and at a subjectively adjusted optimal energy level (OPTkeV). Image quality was assessed using a 4-point Likert scale (score 1 excellent image quality, score 2 good image quality, score 3 limited image quality, score 4 poor image quality). Image quality improved with increasing energies of monoenergetic reconstructions at 64, 69, 88 keV, and was best at OPTkeV

Discussion

This study shows that the use of monoenergetic CT reconstruction reduces the amount of artifacts caused by dental restorations on dental PMCT. Image artifacts were lower on monoenergetic CT images than on standard SECT images. In addition, the extent of artifacts decreased as the energy level of monoenergetic CT images increased and were lowest on the OPTkeV images. The findings from the qualitative evaluations were confirmed by quantitative evaluations.

The results of this study indicate that monoenergetic CT has the potential to reduce one of the major limitations of dental CT. The reduction of beam hardening artifacts on dental CT has been the focus of several previous studies [3, 5, 17]. Previous methods to reduce artifacts on dental CT include maximum intensity projections, multiplanar reformation, and volume rendering [3, 5, 17]. There is one principal difference between these earlier attempts and the approach presented here: previous methods tried to reduce the artifacts on the CT image itself through different means of data reformation. Monoenergetic CT reconstructions eliminate beam hardening artifacts from the raw data prior to image generation. Monoenergetic CT therefore offers a different approach to artifact reduction on dental CT.

Today, dental PMCT is still rarely used for forensic identification. The presence of artifacts on CT images may be one reason for this. In addition, limited access to CT scanners, insufficient training in forensic cross-sectional imaging, and the lack of systematic studies on accuracy and reliability of dental PMCT are other possible reasons for the slow adoption of dental PMCT for forensic identification.

Monoenergetic CT image reconstruction is a relatively novel method in diagnostic radiology. In clinical imaging, initial studies evaluated the potential of monoenergetic CT to reduce image artifacts caused by osteosynthetic plates, screws and other surgical implants [8, 11]. The authors report a significant reduction of artifacts, coupled with a marked improvement of the diagnostic image quality in both studies. One study reports an improvement of image quality on over two-thirds of all patients involved [8]. These findings stand in general agreement with our findings. As in our study, artifacts could not be completely eliminated in spite of monoenergetic image reconstruction.

These remaining artifacts are most likely caused by photon starvation. Monoenergetic CT images are immune to beam hardening and eliminate artifacts related to this phenomenon. Photon starvation however is not influenced by this reconstruction algorithm. Photon starvation can be reduced by increasing the tube current, but understandably the tube current cannot be increased indefinitely. It is conceivable that very dense materials used for certain

Fig. 2 Comparison of image artifacts from high attenuating dental restoration in a *right* maxillary molar (15) on standard single energy CT (a) and monoenergetic CT at 64 keV (b), 69 keV (c), 88 keV (d), and OPTkev (e). Beam hardening artifacts decrease as energy levels of monoenergetic CT reconstructions increase

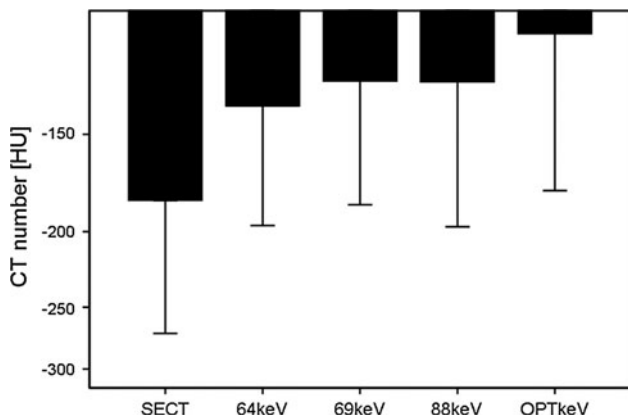
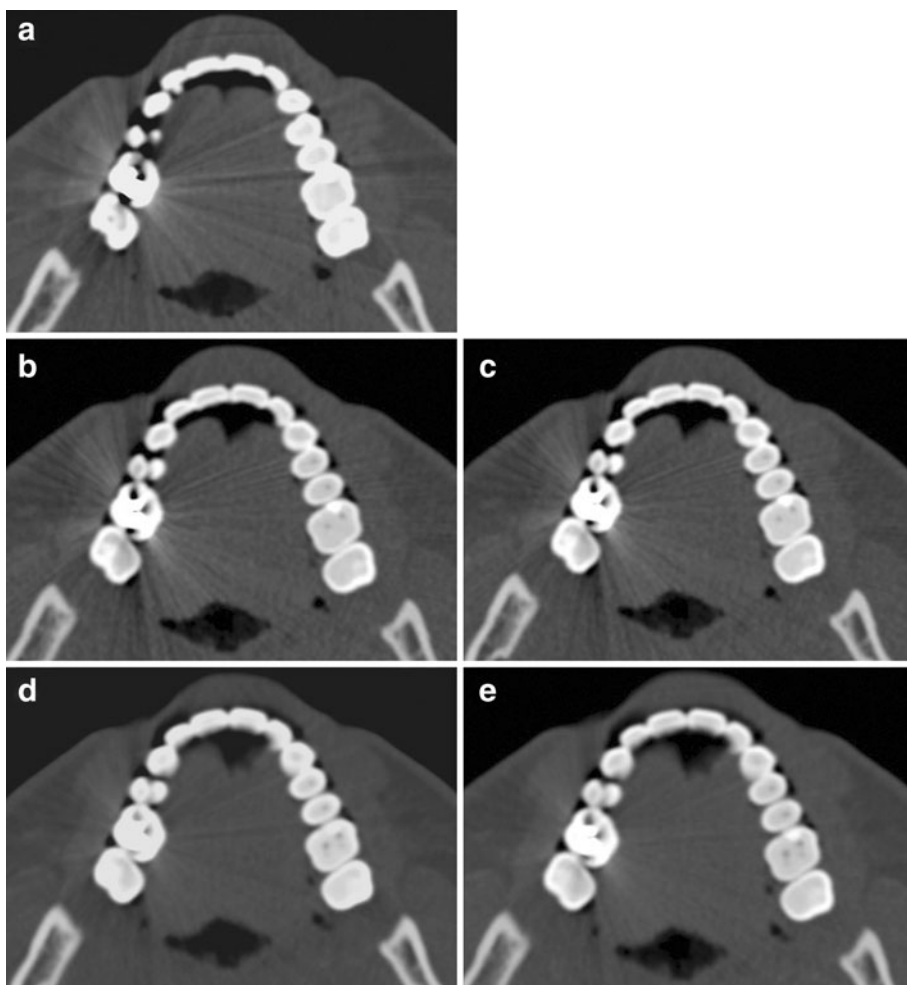


Fig. 3 Bar chart demonstrates mean CT numbers of streaking artifacts with corresponding 95 % confidence intervals. Artifacts caused by dental restorations decreased significantly (repeated-measures ANOVA $p < 0.0001$) as energy levels of monoenergetic CT reconstructions increased

dental restorations, e.g., gold or amalgam, do have the potential to cause photon starvation.

In spite of photon starvation both readers reported a marked reduction of metal artifacts and an improvement of

image quality on monoenergetic CT images as the energy level was raised from 69 to 88 keV. At energy levels ≤ 69 keV, image quality of a majority of the cases was rated with a score of 3. In other words, the image quality was limited and suffered from significant artifacts. At levels ≥ 88 keV the score was raised to 2 (i.e., good image quality with minor artifacts). This shift from limited image quality to good image quality at high energy levels on monoenergetic CT images is one of the most relevant findings of the study. It indicates that monoenergetic image reconstruction visibly improves the image quality of dental CT images through artifact reduction. Nevertheless, it is important to remember that this finding does not necessarily mean that dental identification based on monoenergetic CT images is more reliable or accurate than dental identification with standard PMCT images. However, the improved image quality might allow for faster identification in the setting of a mass disaster, or provide a higher level of security in ambiguous cases.

This study had a number of limitations. This research has not addressed other factors influencing the degree of artifacts such as reconstruction algorithms (iterative vs. filtered back

reconstruction algorithms), kernels, dentition thickness, or filling materials [6]. In addition, we did not compare the effectiveness of monoenergetic CT to other previously described techniques for metal artifact reduction [5, 18]. It may also be criticized that the relationship between different materials for dental restoration and image quality improvement was not assessed for individual materials separately; however, this was beyond the goal of this study. The same applies to the assessment of the impact of monoenergetic CT reconstructions on the reliability and accuracy of dental identification with dental CT. The authors hope to investigate these questions in the future. Finally, limited access to DECT scanners for PMCT is a limiting factor regarding a widespread application of monoenergetic CT image reconstruction. However, DECT is also feasible with standard single energy CT scanners [19], although one should bear in mind that current software packages for DECT data post-processing are not yet capable of handling dual-energy datasets from standard SECT.

In conclusion, monoenergetic CT reconstructions significantly reduce beam hardening artifacts from dental restorations and improve image quality of post-mortem dental CT. The image quality of monoenergetic CT images is superior to standard CT images. This superior image quality might facilitate the comparison of dental CT images for identification.

Key points

1. Post-mortem dental CT images often suffer from low image quality because dental restorations create image artifacts, such as beam hardening artifacts and photon starvation.
2. In dual-energy CT, objects are scanned with two spectral X-ray beams simultaneously. This information is the fundament of monoenergetic CT image reconstruction.
3. Monoenergetic CT images are calculated, or reconstructed images, reflecting the X-ray attenuation of an object at one specific energy level, and are therefore immune to beam hardening artifacts.
4. Monoenergetic CT reconstructions significantly reduce image artifacts from dental restorations on dental CT and improve image quality compared to standard dental CT images.
5. This superior image quality might facilitate the comparison of dental CT images for identification.

References

1. Saukko P, Knight B. The forensic autopsy. In: Saukko P, Knight B, editors. *Knight's forensic pathology*. London: Edward Arnold; 2004. p. 1–51.
2. Sweet D. INTERPOL DVI best-practice standards—an overview. *Forensic Sci Int*. 2010;201:18–21.
3. Thali MJ, Markwalder T, Jackowski C, Sonnenschein M, Dirnhofer R. Dental CT imaging as a screening tool for dental profiling: advantages and limitations. *J Forensic Sci*. 2006;51:113–9.
4. Dedouit F, Telmon N, Costagliola R, Otal P, Florence LL, Joffre F, Rougé D. New identification possibilities with postmortem multi-slice computed tomography. *Int J Legal Med*. 2007;121:507–10.
5. Jackowski C, Lussi A, Classens M, Kilchoer T, Bolliger S, Aghayev E, Criste A, Dirnhofer R, Thali MJ. Extended CT scale overcomes restoration caused streak artifacts for dental identification in CT–3D color encoded automatic discrimination of dental restorations. *J Comput Assist Tomogr*. 2006;30:510–3.
6. Barrett JF, Keat N. Artifacts in CT: recognition and avoidance. *Radiographics*. 2004;24:1679–91.
7. Naranjo V, Llorens R, Alcaniz M, Lopez-Mir F. Metal artifact reduction in dental CT images using polar mathematical morphology. *Comput Methods Program Biomed*. 2011;102:64–74.
8. Bamberg F, Dierks A, Nikolaou K, Reiser MF, Becker CR, Johnson TR. Metal artifact reduction by dual energy computed tomography using monoenergetic extrapolation. *Eur Radiol*. 2011;21:1424–9.
9. Wang G, Snyder DL, O'Sullivan JA, Vannier MW. Iterative deblurring for CT metal artifact reduction. *IEEE Trans Med Imaging*. 1996;15:657–64.
10. Stolzmann P, Leschka S, Scheffel H, Rentsch K, Baumüller S, Desbiolles L, Schmidt B, Marincek B, Alkadhi H. Characterization of urinary stones with dual-energy CT: improved differentiation using a tin filter. *Invest Radiol*. 2010;45:1–6.
11. Zhou C, Zhao YE, Luo S, Shi H, Li L, Zheng L, Zhang LJ, Lu G. Monoenergetic imaging of dual-energy CT reduces artifacts from implanted metal orthopedic devices in patients with fractures. *Acad Radiol*. 2011;18:1252–7.
12. Flohr TG, McCollough CH, Bruder H, Petersilka M, Gruber K, Süß C, Grasruck M, Stierstorfer K, Krauss B, Raupach R, Primak AN, Küttner A, Achenbach S, Becker C, Kopp A, Ohnesorge BM. First performance evaluation of a dual-source CT (DSCT) system. *Eur Radiol*. 2006;16:256–68.
13. Graser A, Johnson TR, Hecht EM, Becker CR, Leidecker C, Staehler M, Stief CG, Hildebrandt H, Godoy MC, Finn ME, Stepanky F, Reiser MF, Macari M. Dual-energy CT in patients suspected of having renal masses: can virtual nonenhanced images replace true nonenhanced images? *Radiology*. 2009;252:433–40.
14. Johnson TR, Krauss B, Sedlmair M, Grasruck M, Bruder H, Morhard D, Fink C, Weckbach S, Lenhard M, Schmidt B, Flohr T, Reiser MF, Becker CR. Material differentiation by dual energy CT: initial experience. *Eur Radiol*. 2007;17:1510–7.
15. Johnson TRC, Fink C, Schönberg SO, Reiser MF. *Dual energy CT in clinical practice*. 1st ed. Berlin: Springer; 2011.
16. Landis JR, Koch GG. The measurement of observer agreement for categorical data. *Biometrics*. 1977;33:159–74.
17. Jackowski C, Aghayev E, Sonnenschein M, Dirnhofer R, Thali MJ. Maximum intensity projection of cranial computed tomography data for dental identification. *Int J Legal Med*. 2006;120:165–7.
18. Lee MJ, Kim S, Lee SA, Song HT, Huh YM, Kim DH, Han SH, Suh JS. Overcoming artifacts from metallic orthopedic implants at high-field-strength MR imaging and multi-detector CT. *Radiographics*. 2007;27:791–803.
19. Ruder TD, Thali Y, Bolliger SA, Somaini-Mathier S, Thali MJ, Hatch GM, Schindera ST. Material differentiation in forensic radiology with single-source dual-energy computed tomography. *Forensic Sci Med Pathol*. 2012; doi:10.1007/s12024-012-9398-y.