

CASE REPORT

Preoperative Embolization of Hypervascular Castleman's Disease of the Mediastinum

John Henri Robert,¹ Georgios Sgourdos,² Neoklis Kritikos,¹ Dominique Didier,² Sylvain Terraz²

¹Department of Surgery, Geneva University Hospital, 1211 Geneva 14, Switzerland

²Department of Radiology, Geneva University Hospital, 1211 Geneva 14, Switzerland

Abstract

We report the case of a 31-year-old woman with mediastinal Castleman's disease of the hyaline vascular type. This large tumor was safely resected after arterial embolization. We describe the steps of this interventional procedure and discuss related necessary precautions.

Key words: Castleman's disease—Hypervascular tumors—Mediastinum—Arterial embolization

Castleman's disease (CD) is a rare form of lymph node hyperplasia, most commonly presenting as a solitary mediastinal mass. Computed tomography (CT) and angiographic features of CD are nonspecific [1] and a definite diagnosis is only based on histology findings. The surgical approach is usually curative when the disease is unicentric [2], but it is frequently associated with profuse bleeding. Only a few previous reports have suggested arterial embolization in the preoperative management of CD [3, 4]. We report a case of localized CD presenting as a voluminous mass in the posterior mediastinum. Preoperative arterial embolization of this tumor minimized intraoperative bleeding.

Case Report

A 31-year-old nonsmoking Asian woman with no medical history presented with a dry cough for 6 months without any other symptoms. An abnormal opacity in the posterior mediastinum was found on chest X-ray (Figs. 1A and 1B). CT confirmed the presence of a 12-cm homogeneous, well-delineated hypervascular right paravertebral mass of the posterior mediastinum (Fig. 1C). There was no evidence of pleural fluid or bone invasion. Laboratory investigations were within the normal range. Fine-needle aspiration or needle-core biopsy was not performed considering the risk of bleeding from this hypervascular mass and because of its location.

A preoperative descending thoracic aortogram was obtained by means of a 5F pigtail catheter (Cordis, Roden, The Netherlands), in order to visualize the origin of the bronchial and extrabronchial arteries from the aorta. A selective bronchial arteriography by means of a 5F steam-modified Cobra catheter (Cordis, Roden, The Netherlands) supported the presence of a hypervascular mediastinal mass. The lesion was exclusively supplied by two arterial branches of a broncho-intercostal trunk originating from the

descending thoracic aorta; it drained into large uphill inferior esophageal varices (Fig. 2). In a second step, embolization of these two feeding arteries was performed, in order to minimize intraoperative bleeding. The superior arterial branch, which supplied the superior and lateral portions of the mass, was selectively catheterized with a 2.5F microcatheter (Tracker 18; Boston Scientific, Cork, Ireland) and embolized by means of gelatin cross-linked tris-acryl microspheres 500–750 µm in diameter (Embospheres; Biosphere Medical, Roissy-Charles-de-Gaulle, France). Occlusion of the proximal segment was completed by three 3-0 silk threads (Silkam; Aesculap, Tuttlingen, Germany). The second arterial branch, which supplied the inferior and medial portions of the mass, was superselectively catheterized beyond the left bronchial artery and embolized in the same manner. Final postembolization angiography showed complete occlusion of these feeding arteries and the absence of vascularization of the mass (Fig. 2). After this procedure, no adverse effects were observed.

A right anterior thoracotomy was performed 7 days after embolization. Despite tight adhesions with the lung, the esophagus, and the subcarinal area, the tumor could be completely removed. Blood loss during surgery did not exceed 200 mL. A single chest tube was placed and removed on the third postoperative day. The postoperative course was uneventful and the patient was discharged on the fifth postoperative day. Thirty-six months after surgery, she is doing well without any sign of recurrence of her disease. The definite histological diagnosis was Castleman's disease of the hyaline vascular type. Macroscopically, the tumor was surrounded by a fibrous capsule and its internal organization was similar to that of a lymph node.

Discussion

Hypervascular mediastinal tumors are rare entities, benign or malignant, occasionally found in children [5]. They include hemangiopericytomas [6], hemangioendothelioma [7], soft-tissue angiosarcomas [8], pheochromocytomas [9], and some benign tumors [10]; for practical purposes, arteriovenous malformations [11] can also be included in this group. CD is another type of these hypervascular tumors. First described in the mid-1950's [12], this rare entity still causes diagnostic and therapeutic dilemmas and its etiology is poorly understood (viruses and autoimmunity and immunodeficiency states have been suggested). There are three histological variants of CD: the hyaline vascular type, which accounts for approximately 90% of cases, the plasma cell type, and an intermediary "mixed" type. However, clinical significance is determined by another classification, based on the distribution of the disease. The localized form is generally benign and is cured by surgical resection, whereas the multicentric form is more aggres-

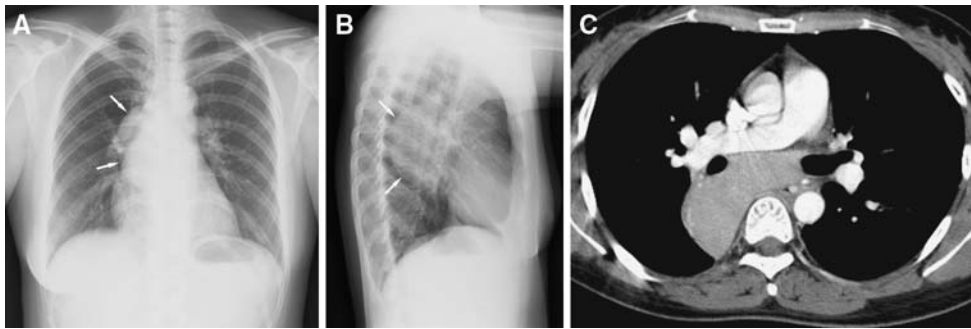


Fig. 1. Chest X-ray and CT of a 31-year-old woman presenting a dry cough for 6 months. **(A)** Posteroanterior chest radiograph shows a large, homogeneous, and well-margined opacity (white arrows) that causes mediastinal widening, but does not blur the right border of the heart. **(B)** Lateral chest radiograph confirms its posterior location in the mediastinum. **(C)** Contrast-enhanced chest CT

(mediastinal window) at the level of the right pulmonary artery shows a homogeneous and hypervascular mass with regard to soft tissues. The close relationship with the mass effect on the esophagus, right main bronchus and right pulmonary artery is particularly well demonstrated.

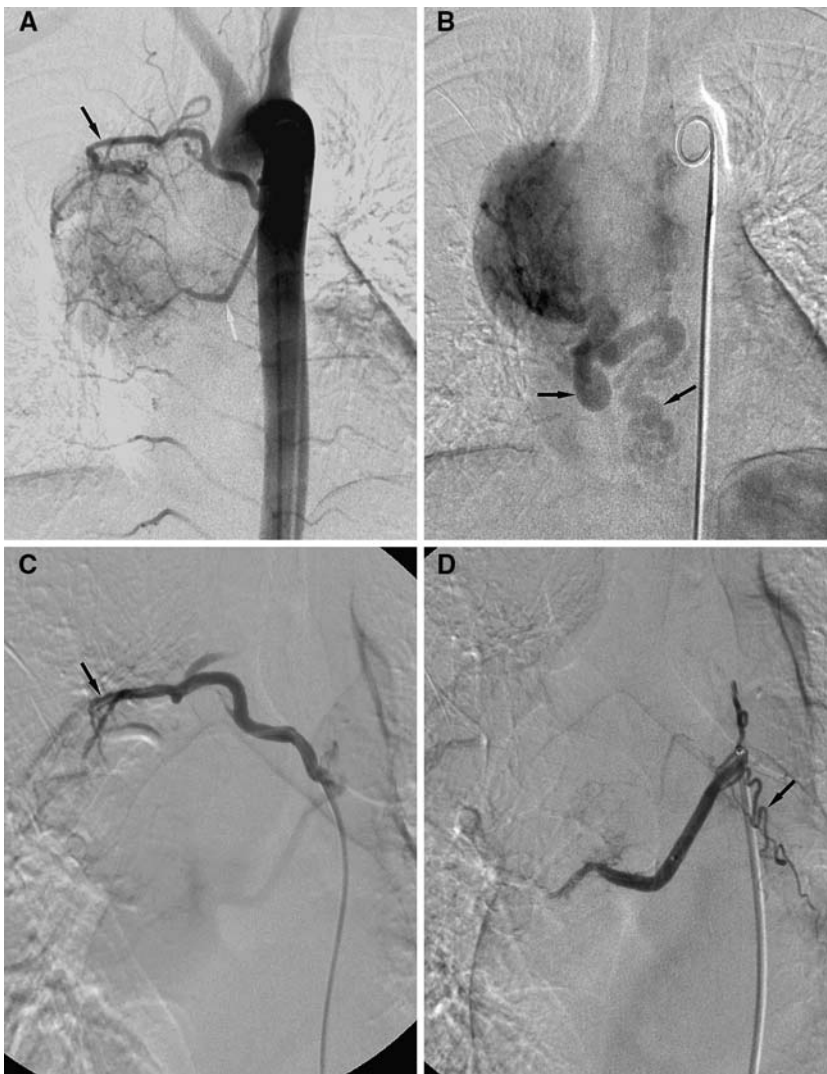

Fig. 2. Angiography prior to and following embolization. **(A)** Arterial phase of aortography shows the hypervascular mediastinal mass with two feeding arteries coming from a broncho-intercostal trunk: a superior and lateral branch (black arrow) and an inferior and medial branch (white arrow). **(B)** Venous phase of aortography shows the hypervascular mass draining in large uphill varices (black arrows). **(C)** Selective arteriography of the superior branch after embolization shows an occlusion of this vessel with small intraluminal defects (black arrow) corresponding to silk threads. **(D)** Selective arteriography of the inferior branch after embolization shows an occlusion of this vessel with preservation of mediastinal branches (black arrow). After embolization, the mediastinal mass is completely devascularized.

sive and tends to be accompanied by various immunologic abnormalities and systemic constitutional symptoms. CD is usually seen in the chest, but it has also been reported in the neck, retroperitoneum, pelvis, and wherever lymph nodes are present [2].

Hypervascularity of these tumors entails the propensity to bleed and accounts for the difficulty in managing them from the start [13]. Spontaneous hemothoraces have been described [6]; biopsies, so commonly resorted to in other solid thoracic tumors, are rightly

feared and avoided [14]. Needless to say, the risk of bleeding is even greater when surgery is contemplated. Although occasionally reported successful [15, 16], thoracoscopy should be avoided in CD. One case of hemangiopericytoma, in which diagnosis was not known preoperatively, had to be operated on twice. Intractable hemorrhage (2.1 L blood loss) occurred during the first operation, which was only exploratory. Arterial embolization was successful before the second surgical attempt—curative this time [17]. Indeed, in all cases of tumors known or suspected to be hypervascular, preoperative arteriography with embolization, which was first reported in the 1970's [3], has made their management safer, particularly when surgery is warranted. This sophisticated technique, however, is not devoid of risks and implies certain precautions.

Nonabsorbable microspheres might prevent the recurrence of tumor hypervascularity due to recanalization of the embolized artery, as frequently observed with absorbable gelatin sponges. It is essential to avoid material smaller than 325 μm in diameter, as it can pass through bronchopulmonary anastomoses and lead to pulmonary infarction or systemic arterial embolism (via anastomoses between bronchial arteries and pulmonary artery or vein, respectively) [18]. By the same token, it is as important to avoid embolic agents that cause distal occlusion to such an extent that normal peripheral branches supplying the bronchi, esophagus, aorta, and pulmonary artery might be equally occluded, leading to obviously catastrophic complications [19]. For all of these reasons, when bronchial artery embolization is contemplated, we recommend the use of microparticles ranging in diameter from 350 to 700 μm [20]. Proximal vessel occlusion might preclude repeat embolization after bronchial artery embolization for hemoptysis [21]. In the case described, proximal embolization with inexpensive silk threads was added to the procedure. This was done to decrease the risk of new collateral vessels prior to surgery.

The most disastrous complication after bronchial artery embolization is spinal cord ischemia due to the occlusion of spinal arteries, which has been reported in 0–6.5% of cases [20–23]. Visualization of radicular branches on bronchial or intercostal angiograms is not an absolute contraindication to embolization. However, when the anterior spinal artery (artery of Adamkiewicz) is identified at arteriography, embolization should not be performed. Consequently, in order to decrease the risk of this dreaded complication, it is of utmost importance to visualize all bronchial and nonbronchial arteries prior to embolization.

References

1. McAdams HP, Rosado-de-Christenson M, Fishback NF, et al. (1998) Castleman disease of the thorax: radiologic features with clinical and histopathologic correlation. *Radiology* 209:221–228
2. Bowne WB, Lewis JJ, Filippa DA, et al. (1999) The management of unicentric and multicentric Castleman's disease: A report of 16 cases and a review of the literature. *Cancer* 85:706–717
3. Walter JF, Rottenberg RW, Cannon WB, et al. (1978) Giant mediastinal lymph node hyperplasia (Castleman's disease): angiographic and clinical features. *Am J Roentgenol* 130:447–450
4. Safford SD, Lagoo AS, Mahaffey SA (2003) Preoperative embolization as an adjunct to the operative management of mediastinal Castleman disease. *J Pediatr Surg* 38:1–3
5. Parez N, Bader-Meunier B, Roy CC, et al. (1999) Paediatric Castleman disease: Report of seven cases and review of the literature. *Eur J Pediatr* 158:631–637
6. Mori M, Nakanishio N, Furuya K (1999) Hemangiopericytoma of the mediastinum causing spontaneous hemothorax. *Ann Thorac Surg* 598:1525–1527
7. Rehring TF, Deutchman A, Cross JS (1999) Polymorphous hemangiopericytoma. *Ann Thorac Surg* 68:1396–1397
8. Meis-Kindblom JM, Kindblom LG (1998) Angiosarcoma of soft tissue: A study of 80 cases. *Am J Surg Pathol* 22:683–697
9. Montana E, Montana X, Morera R, et al. (1990) Functioning paraganglioma (pheochromocytoma) of the thorax: preoperative embolization (letter). *J Cardiothorac Surg* 100:626–627
10. Mineo TC, Biancari F, Cristino B, et al. (1995) Benign vascular tumours of the mediastinum: Presentation of 3 cases and review of the literature. *Thorac Cardiovasc Surg* 43:361–364
11. Cheng SL, Wang HC, Yang PC (2003) Posterior mediastinal arteriovenous malformation with atypical color Doppler sonographic findings. *J Clin Ultrasound* 31:44–47
12. Castleman B, Iverson L, Menendez VP (1956) Localized mediastinal lymph-node hyperplasia resembling thymoma. *Cancer* 9:822–830
13. Iyoda A, Yusa T, Hiroshima K, et al. (2000) Castleman's disease in the posterior mediastinum: Report of a case. *Surg Today* 30:473–476
14. Kim JH, Jun TG, Sung SW, et al. (1995) Giant lymph node hyperplasia (Castleman's disease) in the chest. *Ann Thorac Surg* 59:1162–1165
15. Sica GS, Di Lorenzo N, Sileri PP, et al. (1999) Thoracoscopic approach to giant lymph node hyperplasia (Castleman's disease). *Surg Laparosc Endosc Percutan Tech* 55:519–522
16. Seirafi PA, Ferguson E, Edwards FH (2003) Thoracoscopic resection of Castleman's disease: Case report and review. *Chest* 123:280–282
17. Morandi U, Stefani A, De Santis M, et al. (2000) Preoperative embolization in surgical treatment of mediastinal hemangiopericytoma. *Ann Thorac Surg* 69:937–939
18. Pump K (1972) Distribution of bronchial arteries in human lung. *Chest* 62:447–551
19. Marshall TJ, Jackson JE (1997) Vascular intervention in the thorax: bronchial artery embolization for hemoptysis. *Eur Radiol* 7:1221–1227
20. Corr PD (2005) Bronchial artery embolization for life-threatening hemoptysis using tris-acryl microspheres: short-term result. *Cardiovasc Intervent Radiol* 28:439–441
21. Kato A, Kudo S, Matsumoto K, et al. (2000) Bronchial artery embolization for hemoptysis due to benign diseases: Immediate and long-term results. *Cardiovasc Intervent Radiol* 23:351–357
22. Mal H, Rullon I, Mellot F, et al. (1999) Immediate and long-term results of bronchial artery embolization for life-threatening hemoptysis. *Chest* 115:996–1001
23. Wong ML, Szkup P, Hopley MJ (2002) Percutaneous embolotherapy for life-threatening hemoptysis. *Chest* 121:95–102