

# Virtopsy

## Working on the future of forensic medicine

In recent times, few fields have witnessed such impressive progress as imaging methods and radiology: digital data acquisition and post-processing of images have revolutionized the practice of imaging and radiology and have determined a growing interest in this field on the part of other medical professions. The application of imaging methods for non-invasive documentation and analysis of relevant forensic findings in living and deceased persons has lagged behind the enormous technical development of imaging methods. There are only a few textbooks dealing with forensic imaging and radiology and most concentrate on classical photography and roentgenographic methods and hardly cover the newer three-dimensional (3D) imaging techniques. Forensic 3D imaging and radiology, including all techniques and their many uses for forensic purposes, is now a rapidly growing sub-discipline of forensic medicine. Virtopsy became the scientific umbrella, including technical tools which can be used to document forensically relevant findings in 3D.

The most important tools for daily routine use are:

- 3D photogrammetry-based optical surface scanning
- Computed tomography and magnetic resonance imaging
- Postmortem biopsy
- Postmortem angiography

### 3D Photogrammetry-based optical scanning

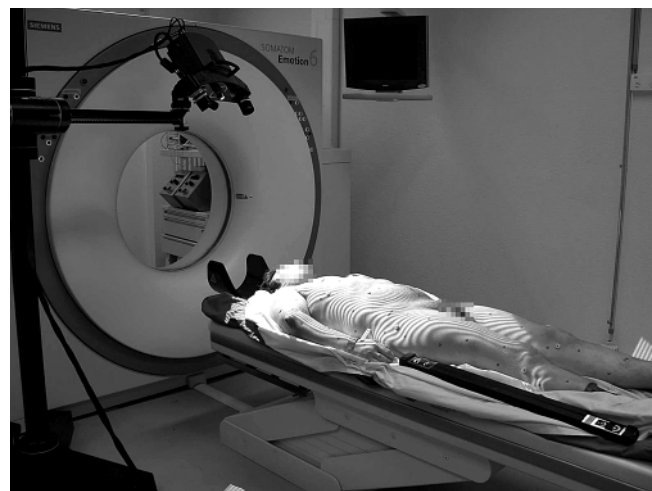The standard for the documentation of injuries in forensic medicine is still photography with exact measurements. However, the photographic process reduces a 3D wound to a 2D level in the same way as classical x-ray documentation.

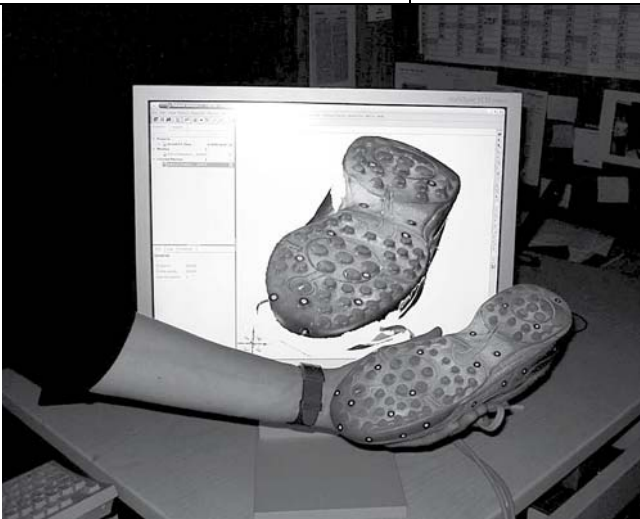
Using the TRITOP/ATOS III (GOM, Braunschweig, Germany) system the colored 3D surface can be documented via detection of the distortion of light beams, projected onto the region of interest (■ Fig. 1) and the system can then recalculate the 3D surface that caused the distortion. This system is usually used when high precision is required as it has an accuracy of measurement below 20 µm.

This allows for a more detailed surface documentation compared to 3D reconstructions based on high resolution CT data.

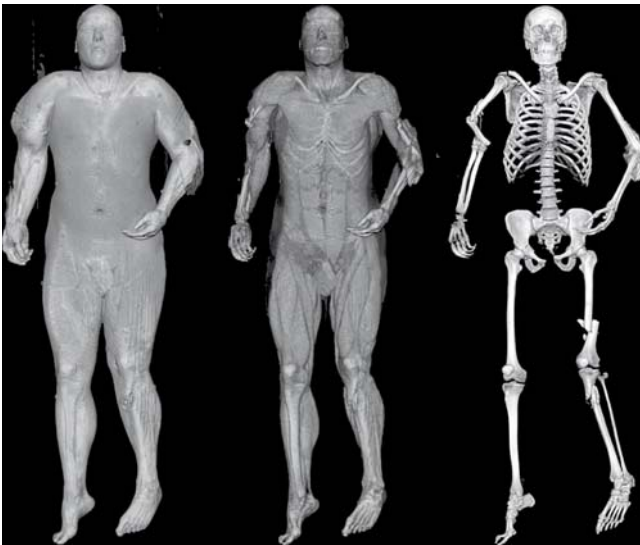
The color information is acquired using the Tritop software that combines digital photography of the surface from many different angles into 3D color information of the object that can be correctly matched on the digital 3D surface model using coded and uncoded markers placed on the object. Using this technology, documentation ranging from fine detailed structures (skin lesions or fine object structure) to overview documentation (whole body or objects such as an entire motor vehicle) is possible. By documenting an injury pattern and an instrument suspected of causing the injury (■ Fig. 2), a digital 3D geo-

**Fig. 1** ▶ 3D surface scanner ATOS III and 6-row multislice CT scanner, used by the Virtopsy group in Bern. Notice the wave pattern, projected onto the corpse by a projector unit and captured by two CCD cameras mounted beside the projector

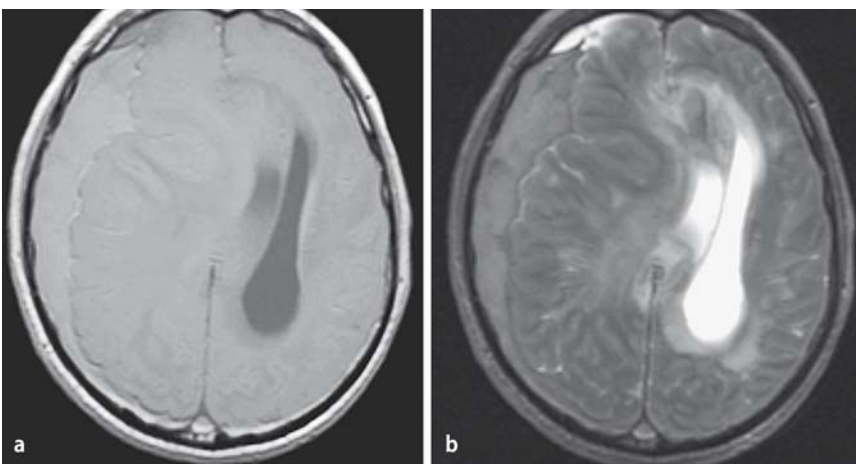




**Fig. 2** ◀ Surface scan of the sole of a shoe used to cause an injury



**Fig. 3** ◀ Reconstruction in volume rendering technique (VRT) of a whole body MSCT with different voxel opacities for skin, muscle and bone. Multiple fractures of the upper and lower extremities, open book fracture of the pelvis



**Fig. 4** ▲ Cranial MRI of an accident victim using T1 (a) and T2 (b) weighted imaging. Extensive subdural hematoma on the right with shifting of the midline structures and compression of the right lateral ventricle

metric match analysis of the previously acquired data is possible, even when the injury of a living person is already healed or the dead body is buried.

### Computed tomography and magnetic resonance imaging

Computed tomography (CT) was introduced in the early seventies by Hounsfield and Cormack, for which they won the Nobel Prize in 1979. CT was also called computed axial tomography and the examinations were thus named CAT scans. CT uses the same technique as radiography uses to produce X-rays. However, to obtain transverse (axial) images of body sections, the tube rotates around the longitudinal (z) axis of the body, transmitting radiation from many angular positions through the body. X-rays are attenuated according to the radiographic density of tissues; these attenuated X-rays reach the detector system beyond the patient, contributing to the attenuation profile of one specific tube angle. The many profiles measured during one rotation are used by the computer to calculate a density map of the scanned slice with discrete absolute density values of all image elements (pixels). Radiodensity is expressed in Hounsfield units (HU) whereby the radiodensity of distilled water at standard pressure and temperature (STP) is defined as zero HU and air at STP is defined as -1000 HU. The above standards were chosen as they are universally available references and suited to the key application for which computed axial tomography was developed: imaging the internal anatomy of humans. Common tissues have defined radiodensities such as fat (-120 HU), muscle (+40 HU) or bone (+1000 HU). Metal objects can reach very high densities of far more than +1000 HU and will then cause streak artifacts. The first CT scanner was specifically engineered to image the brain and the total scan time was then approximately 25 min. These CT scanners, now referred to as conventional CT scanners, acquired a set of discrete cross-sections by moving the patient step-by-step through the scanner. A major advance in CT technology occurred with the development and implementation of helical or spiral CT in 1989.

In a helical CT scanner the X-ray source and the detector array are mounted on a permanently rotating gantry while the patient is moved axially through the scanner at a uniform speed. This technique allows the acquisition of a complete seamless volume data set of a body region. This data set consists of volume elements called voxels (a portmanteau of the words volumetric and pixel). The most recent advance in CT technology has been multidetector row helical CT. Current multislice scanners are able to acquire up to 64 slices in 1 tube rotation. In combination with faster rotation times, a modern 64-slice scanner is up to 192 times faster than a single-slice spiral CT from the early 1990s. As a result, CT data can be obtained much faster, with thinner slice collimation and with better contrast utilization than with single-slice helical CT. With the development of multislice CT (MSCT) and current imaging workstations, the examiner is no longer restricted to the axial slice view. Isotropic (cuboid) voxels are an ideal prerequisite for image post-processing using multiplanar reformation to obtain images in sagittal, coronal or oblique planes or even detailed 3D presentation methods (■ Fig. 3).

MSCT offers many advantages over single-slice CT and is clearly the future of helical CT imaging. The newest CT generation has a dual radiation source, which makes it possible to visualize and examine tissues with different X-ray attenuation profiles during one scan.

Introduced in the early 1980s, MRI is well established in the clinical routine but in contrast to CT where X-rays are used for imaging, MRI uses strong magnetic fields to gather information from the inside of the body.

While CT provides good spatial resolution but inferior contrast resolution, MRI provides an excellent contrast resolution of soft tissues with a comparable spatial resolution in up-to-date high field scanners (1.5 or 3 Tesla). Medical MRI most frequently relies on the relaxation properties of excited hydrogen nuclei ( $^1\text{H}$ ) in water and fat. Tissues with a relatively low concentration of hydrogen nuclei, such as bone, are therefore not visualized well in MRI (as long as they do not contain water, like in a bone bruise). In a simplified way,

Rechtsmedizin 2006 · 17:7–12 DOI 10.1007/s00194-006-0419-6  
© Springer Medizin Verlag 2006

M.J. Thali · S. Ross · L. Oesterhelweg · S. Grabherr · U. Buck · S. Naether · C. Jackowski · S.A. Bolliger · P. Vock · A. Christe · R. Dirnhofer

### Virtopsy. Zukunftsträchtige Forschung in der Rechtsmedizin

#### Zusammenfassung

„Computed-tomography-Verfahren“ sind während der letzten 10 Jahre weiterentwickelt worden und haben verschiedene Anwendungen im rechtsmedizinischen Fachgebiet gefunden. Die neueste Entwicklung besteht in der „multislice computed tomography“, kombiniert mit „photogrammetry-based surface optical scanning“ und „Image-rendering-Techniken“. Diese Kombination kann für die 3-dimensionale Darstellung von Verletzungsmustern zum Vergleich mit infrage kommenden Tatwaffen sowie zum Screening nach pathologischen Befunden in lebenden oder ver-

storbenen Personen eingesetzt werden. Es handelt sich um ein minimal-invasives Verfahren, mit dem forensisch relevante Bilder erfasst werden können, die auch im Gerichtssaal vorgeführt werden können. Die rasche Weiterentwicklung der Imaging-Technik könnte in der Zukunft eine Alternative zu konventionellen Obduktionen darstellen.

#### Schlüsselwörter

3D-bildgebene Verfahren · Leichnam · Verletzungsmuster · Minimal-invasives Verfahren · „Multislice computed tomography“

### Virtopsy. Working on the future of forensic medicine

#### Abstract

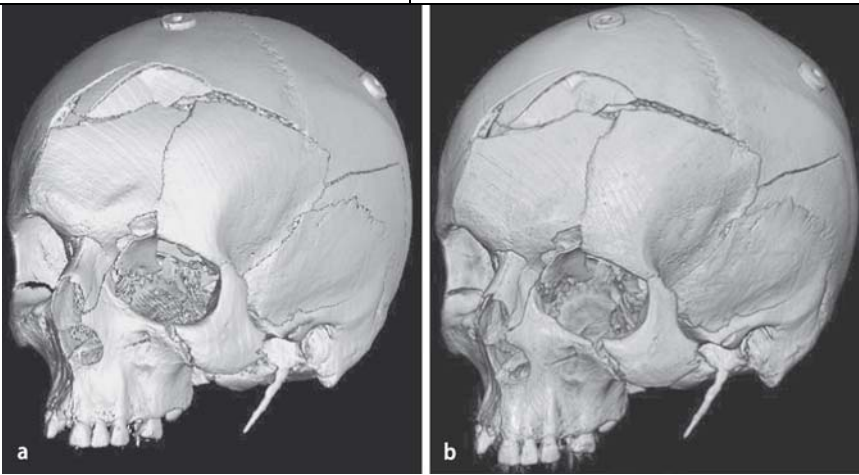
Computed tomography techniques have been developed over the last 10 years and have found various applications in the forensic field. The most recent development is multislice computed tomography combined with photogrammetry-based surface optical scanning and image rendering techniques. This combination of techniques can be used to produce 3-dimensional images of injury patterns for comparison with suspect weapons and also to screen for pathological conditions in the living or deceased. This technol-

ogy provides a minimally invasive procedure for capturing forensically relevant images which can be produced in the courtroom. The rapid developments in imaging techniques could provide an alternative to conventional autopsy procedures in the future.

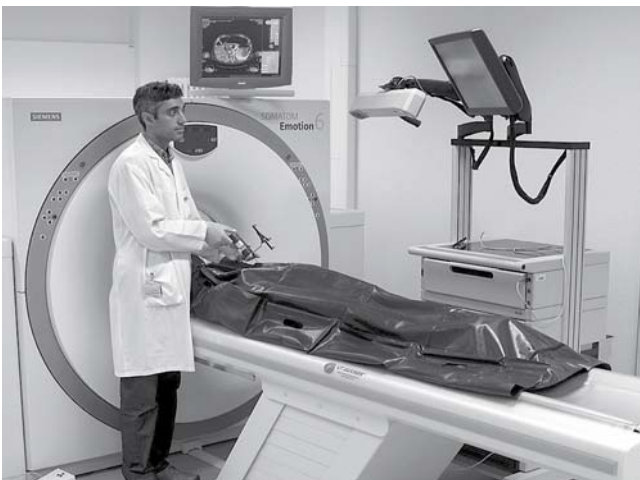#### Keywords

3D imaging techniques · Corpse · Injury pattern · Minimally invasive technique · Multislice computed tomography

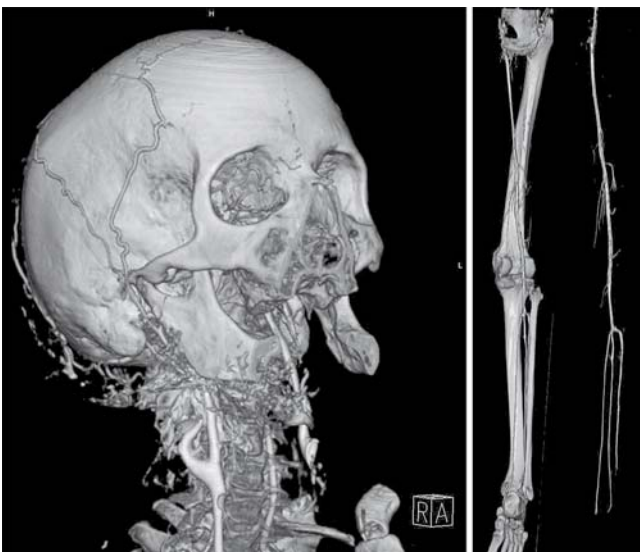




**Fig. 5 ▲** a) SSD of a skull with a frontal impression fracture due to blunt trauma b) VR of the same dataset from nearly the same perspective



**Fig. 6 ◀** Postmortem image-guided biopsy with real-time tracking of the needle tip



**Fig. 7 ◀** Postmortem angiography with visualization of the carotid arteries (a) and the arterial flow path of the right leg. Interactive volume editing was used in both cases to remove bony structures in order to improve the visibility of the vessels

inside an MR scanner the body acts with its hydrogen nuclei as its own radio station and the coils in the scanner are playing the role of receivers, collecting the signals from the excited hydrogen nuclei. The signal intensity of a certain tissue is strong-

ly dependent on the design of the MR sequence. Water for instance is hyperintense (bright) in so-called T<sub>2</sub>-weighted images and hypointense (dark) in T<sub>1</sub>-weighted images (■ Fig. 4).

The unique advantage of MRI is its flexibility in producing a variable contrast, reflecting different tissue characteristics by just modifying the sequence (this term means the specific combination of magnetic field gradients and radiofrequency waves used to acquire a number of usually parallel images). For example, MRI can produce separate images of the protons bound to water and of those chemically bound to lipids of the same plane. In routine practice, most of the MR imaging techniques now in use produce 2D images, for which only two spatial dimensions have to be encoded. The techniques which spatially encode the whole volume are known as 3D imaging. In a clinical setup 1.5 or more and more 3 Tesla systems are used.

In many cases, the resolution of clinical scanners is not yet sufficient to answer all questions on a tissue level relevant to forensic medicine. This favors the idea of using micro-imaging methods with their much higher resolution to visualize forensic specimens.

Our research group at the University of Bern used micro-CT of a knife blade inside cortical and trabecular bone to determine the injury pattern and the weapon involved. In forensic soft tissue injuries, retinal hemorrhage and electrical injury to the skin were studied by micro-MR (MR microscopy). We expect these new radiological cross-section micro-imaging methods to have a comparable impact on (forensic) histopathology leading to virtual histology.

### Post-processing: 2D and 3D visualization

In particular, post-processing and 3D reconstruction of images not only satisfy an esthetic requirement, they have become a necessary tool for the representation of complex structures and for the understanding of forensically relevant traumatic findings and pathologic changes. Surface rendering display (SSD) and volume rendering (VR) represent the most important techniques applied for 3D visualization (■ Fig. 5).

SSD represents a visualization technique which is well established for 3D imaging of skin and bone surfaces. The key

idea of surface-based rendering methods is to extract an intermediate surface description of the relevant objects from the volume data.

The SSD method basically involves constructing polygonal surfaces in the data sets and rendering these surfaces.

On the other hand there is VR, which involves assigning a color and opacity value to each data element and projecting the elements directly onto the image plane without the use of polygons. VR is a popular technique used to represent and analyze volume data whereby the object of interest is sampled into many cubic building blocks, called voxels (volume elements). In VR images are created directly from the volume data and no intermediate geometry is extracted.

### Postmortem biopsy

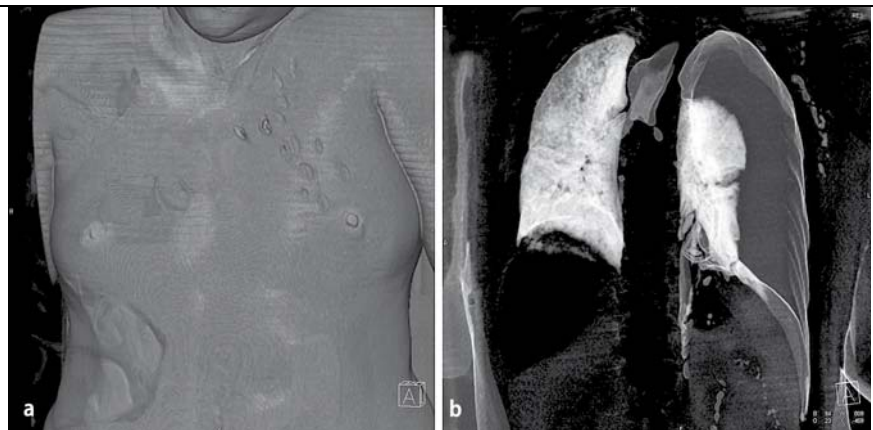
Similar to the clinical set-up, postmortem biopsies can be used to collect tissue samples for histological evaluation in a minimally invasive way (■ Fig. 6). Postmortem biopsy is still necessary in the current VIRTOPSY set-up, because the resolution of modern clinical scanners is still limited.

### Postmortem angiography

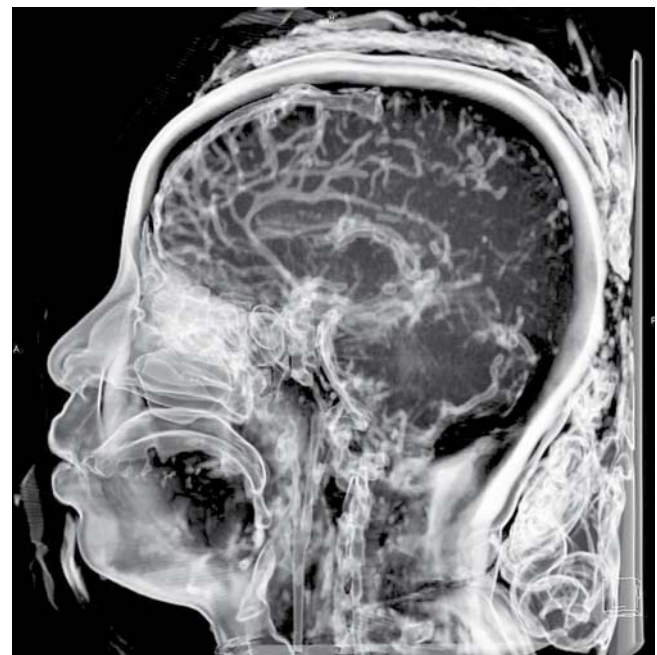At our institute, different methods for postmortem angiography have been developed (■ Abb. 7). The goal of postmortem angiography is the detection of small vessel injuries, which are in some cases not visible in non-contrast enhanced imaging or are almost impossible to display during autopsy.

### The Virtopsy project in Switzerland

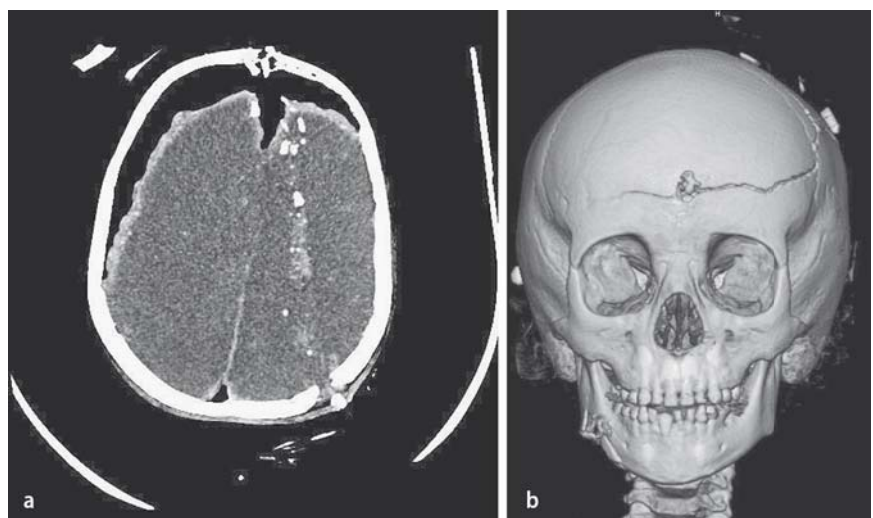
In the mid-1990s, the Institute of Forensic Medicine started projects together with the Scientific Service of the City Police in Zurich, which had the goal to document body and object surfaces in 3D. In Switzerland the so-called morphometric report, which gives information on whether an instrument suspected of causing an injury can be linked to an injury pattern, is already accepted in the court system.



**Fig. 8** ▲ MSCT VRT reconstruction of a stabbing victim with multiple thoracic wounds (a) and a left-sided pneumothorax (b)



**Fig. 9** ► VRT reconstruction of a stabbing victim with extensive gas embolism in the cerebral arteries



**Fig. 10** ▲ Gunshot wound to the head with visualization of the path of the bullet in an axial cross-section (a) and VRT reconstruction with demonstration of the bullet entrance wound

Later the Institutes of Forensic Medicine and of Diagnostic Radiology of the University of Bern, Switzerland, started a research project hypothesizing that non-invasive imaging might predict autopsy findings and maybe give additional information. The results of CT and MRI always correlated with the findings of the autopsy. The result of this basic study was that MSCT is superior for 2D and 3D documentation and analysis of fracture systems, pathologic gas collection (e.g. air embolism, subcutaneous emphysema after trauma, hyperbaric trauma or decomposition effects; ■ Fig. 8, 9, 10) and also reveals gross tissue injury. The scan times are short, around 5–10 mins depending on the slice thickness and the volume to be covered. Post-processing with 3D SSD and VRT can provide useful visualization for a court trial. Therefore, in forensic cases CT can be used as a triage scanning tool. Compared to CT, MRI clearly has a higher sensitivity, specificity and accuracy in demonstrating soft tissue injury, neurological and non-neurological organ trauma and non-traumatic pathology. Both methods can be used for identification purposes. Postmortem biopsy and postmortem angiography are useful additions to the scanning and documentation process.

## Outlook

Based on 10 -years experience in 3D forensic imaging the question arises, what is coming next?

In our opinion the forthcoming major topics in 3D forensic imaging are:

- Using radiological methods (MRI) in clinical forensic medicine, the first steps have already been undertaken in survivors of attempted strangulation
- Implementation of so-called total imaging matrix (TIM) systems, which make a whole body MRI documentation in 30 mins and in high resolution possible
- Haptic devices which give a tactile feedback from the virtual data to the examiner
- Stereo 3D visualization
- Automated body surface scanning and biopsy procedures using robotic systems

## Summary

Today, imaging techniques are excellent evidential tools for forensic medicine. Similar to inspection and photography but in contrast to other methods, they are able to capture the findings at the moment of investigation without causing any damage. Capturing means permanent (analogue or digital) preservation as a document of proof, regardless of whether the victim is dead and undergoing postmortem decay or surviving and losing evidence due to healing. Causing no damage is an essential prerequisite in a living person that is indisputably fulfilled. Even in dead persons, non-destructive documentation is important for two reasons: first, it provides information without precluding any other conservative or destructive forensic investigation. Second, it can be used in cultures and situations where autopsy is not tolerated by religion or rejected by family members. Whether and to what degree radiological minimally invasive „virtual autopsy“ will in defined situations replace the classical dissection technique will be decided in the near future.

An additional forensic documentation step is the aim to combine radiological imaging with surface documentation methods, such as photogrammetry and 3D optical scanning. Another issue is the combination of non-invasive imaging with minimally invasive image-guided tissue sampling from any body location. On the other side, radiological virtual autopsy brings new advantages, such as easy examination of bodies contaminated by infection, toxic substances, radionuclides or other biohazards. 2D and 3D post-processing help to visualize the findings for people not present during the examination, e.g. in court. Complete, easily retrievable digital archives will support the process of quality improvement. Imaging technology is developing fast and new technical solutions will be introduced soon. The cost of high-tech imaging systems, although currently often a hurdle that is slowing their routine forensic application, will decrease in the near future.

In conclusion, imaging has already proved to be a reliable tool in modern forensic medicine for a number of applications. Further technical development in

radiology is working for the forensic field of applications.

## Corresponding author

**Prof. Dr. M. J. Thali**

Center of Forensic Imaging, Institute of Forensic Medicine, University of Bern  
Bühlstrasse 20, CH-3012 Bern  
michael.thali@irm.unibe.ch

**Acknowledgements.** This study was supported by the Virtopsy Foundation.

**Conflict of interest.** There is no conflict of interest. The corresponding author affirms that he/she has no connection with any company whose product is mentioned in this article or any company that markets a competing product. The presentation of the findings is free of bias and product-neutral.

## References

1. <http://www.virtopsy.com>