



Laparoscopic gastric banding

Beyond the learning curve

M. Suter,¹ V. Giusti,² E. Héraief,² F. Zysset,² J.-M. Calmes¹

¹ Department of Surgery, Centre Hospitalier Universitaire Vaudois (CHUV), Lausanne, Switzerland

² Department of Internal Medicine, Centre Hospitalier Universitaire Vaudois (CHUV), Lausanne, Switzerland

Received: 10 December 2002/Accepted: 17 December 2002/Online publication: 17 June 2003

Abstract

Introduction: Laparoscopic gastric banding (LGB) is currently the most popular purely restrictive bariatric operation in Europe and many other countries. It has a low operative morbidity, but is associated with a substantial late complication rate. Many late complications have been attributed to technical errors or to the learning curve. The aim of this paper is to present our results with gastric banding after the learning curve in order to disclose the true incidence of long-term complications.

Methods: LGB was introduced in our department in December 1995. Thirty patients were operated on until June 1997 using the early banding technique (band within the lesser sac), at which time the surgical technique was slightly modified in order to place the band above the lesser sac. Then another 300 patients underwent LGB using either the Lapband or the SAGB system. This report focuses on the latter patients. All the data were collected prospectively.

Results: The series includes 300 patients (257 women and 43 men) with a mean age of 38.3 years (19–64). The mean initial weight was 119.2 kg (57–179), initial body mass index (BMI) was 43.3 kg/m² (21–64), and initial excess weight was 96.5% (0–191). The mean duration of surgery was 90 min, decreasing over time to a mean of 75 min for the last 50 cases. Early overall morbidity was 6.6%. Major complications occurred in 7 patients (2.3%). Excess weight loss (EWL) was at least 50% in 66% of the patients after 2 years, averaging 60%, with no substantial change until 4 years, and the BMI stabilized between 30 and 31 kg/m². Forty-nine patients developed a total of 52 long-term complications, of which 23 (7.6%) were related only to the port or catheter. Band erosion occurred in 17 (5.6%), pouch dilatation with slippage in 8 (2.6%), and infection in 4 (1.3%) patients. Fifty-five reoperations were necessary. Twenty-five of these were related only to the port. The band was re-

moved from 26 (9%) patients, of whom 17 were converted to Roux-en-Y gastric bypass.

Conclusions: LGB gives satisfactory results in terms of weight loss in about two-thirds of the patients. Even beyond the learning curve, the long-term morbidity is not negligible, but is acceptable compared to other procedures such as vertical banded gastroplasty. Conversion to gastric bypass is possible when complications occur and can be performed when the band is removed in most cases.

Key words: Gastric banding — Morbid obesity — Laparoscopy

The prevalence of excess weight and obesity is increasing in most Western countries. Hence, the demand for bariatric surgery, the only efficient treatment for morbid obesity currently available, is rapidly expanding. Whereas Roux-en-Y gastric bypass remains the gold standard, and despite the fact that the method is relatively new, many authors consider laparoscopic gastric banding as the treatment of choice for morbidly obese patients [2, 11, 13, 15, 17, 18, 20, 30]. Others consider gastric banding as an inappropriate method because it yields insufficient weight loss or because it is associated with an exceedingly high rate of complications [9, 31].

Very varying results regarding excess weight loss and complication rates have been reported in the literature. Some explanations for these conflicting results are that most series include patients operated on during the learning curve, and that the follow-up is usually limited and incomplete. The aim of this paper is to assess the results of a large series of laparoscopic gastric banding from a single institution, deliberately excluding 30 patients operated on during the first 18 months of introduction of the procedure in our department (learning curve). Special efforts were made to provide as complete a follow-up as possible.

Materials and methods

Patients with a body mass index (BMI) in excess of 40 kg/m², or > 35 kg/m² with at least one severe comorbidity, were selected for gastric banding after failure of conservative therapy and complete evaluation by a multidisciplinary team. This included an endocrinologist, a psychiatrist, a dietician, an anesthesiologist, and a bariatric surgeon. Other specialists were consulted as required. Contraindications were according to the consensus development conference panel of the National Institute of Health and to the consensus on obesity treatment in Switzerland [6, 7].

Laparoscopic gastric banding was introduced in our department in December 1995. At this time, we already had some experience with laparoscopic surgery of the upper stomach, having performed about 40 funduplications. Initially, we used the Lapband (Bioenterics, Carpinteria, CA, USA) device and placed it according to the technique described by Cadière and co-workers [3]. The band lay therefore within the lesser omental sac on the posterior part of the stomach. After experience with some 30 cases, and after reports showing that the aforementioned technique induced a high risk of band slippage and pouch dilatation [10], we began in May 1997 to place the band above the bursa omentalis. At this time we had become very familiar with the procedure and the area, and felt no difficulty in making this technical change. In April 1998, we also started to use the Swedish Adjustable Gastric Band (SAGB, Obtech Medical, 6301 Zug, Switzerland) and always placed it above the lesser omental sac, using the so-called pars flaccida technique. The operative technique for both devices has been described in detail elsewhere [27]. The only subsequent modification was made in October 1998: to prevent rupture of the Lapband catheter at the edge of the metallic connecting piece, close to the port, we fashioned a loop with the catheter, including the connecting piece, and secured it to the fascia with two additional sutures. In this way, the connecting piece does not lie where the tubing penetrates through the abdominal wall, and therefore is not submitted to shearing forces due to movements of the latter. After November 1998, the patients undergoing gastric banding were included in a prospective randomized study comparing the Lapband and the SAGB. All the patients operated since the first technical change (band above the lesser sac) were included in the present series.

All the patients were given a single dose of prophylactic antibiotics (amoxicillin clavulanate 2.2 g or cefuroxime 1.5 g) at the induction of anesthesia. Prophylaxis against thrombosis included low-molecular-weight heparin, which started at the induction of anesthesia and was pursued until the end of the 4th postoperative week. The band was left deflated at the end of the procedure, and the patients were instructed to remain on a semiliquid diet during the first postoperative month. At the end of this period, the position of the band was controlled under fluoroscopy, and the band was adjusted for the first time using Isovist 300 (Schering AG, Schlieren, Switzerland). Further adjustments were mostly performed during office visits, according to weight loss and eating capacities. Fluoroscopic controls were usually performed about 1 year postoperatively, during the third postoperative year, or if clinically required. Upper GI endoscopy was performed only if mandated by the patient's condition or, for some 30 patients, as part of an ongoing study focused on the influence of gastric banding on gastroesophageal reflux disease.

A prospective computerized database has been created since the introduction of laparoscopic bariatric surgery in our department. Included in the database are demographic and anthropometric data, comorbidities, operative data, and follow-up data. Early complications were defined as occurring within the first 30 days of operation, and early reoperations as those required for early complications. Late complications arose after the 30th postoperative day, and late reoperations were defined as those required to deal with late complications. Major early complications were defined as complications leading to death or early reoperation. Late complications were considered major if they lead to dismantling of the gastric banding (band removal with or without conversion to another procedure). Minor late complications required no further surgery, only minor procedures (usually for leaks of the port/catheter system), or were managed with laparoscopic band repositioning or band change. Major reoperations were those required to treat major late complications.

Follow-up visits were scheduled monthly during the first postoperative semester, every 2 months during the second semester, quarterly during the second year, and biannually thereafter. Follow-up was

Table 1. Postoperative complications (+, postoperative death)

Type of complication	Number	%
Gastric perforation/leak	2	0.6
Band infection	2	0.6
Port infection	2	0.6
Hemorrhage	1	0.3
Wound infection (after laparotomy)	2	0.6
Wound hematoma	1	0.3
Wound seroma (after abdominoplasty)	2	0.6
Respiratory arrest	1 (+)	0.3
Thromboembolism	1	0.3
Pneumonia	2	0.6
Thigh meralgia	2	0.6
Fever of undetermined origin	3	1
Total patients with complications	21	7
Total patients with major complications	7	2.3

performed by the surgical as well as by the medical team. During follow-up, all complications and reoperations were carefully recorded. When the band had to be removed for pouch dilatation/slippage or band erosion, beginning in April 1999, the patients were offered the possibility to undergo a gastric bypass at the same time in order to prevent weight regain. This option was not offered to patients with port or band infection. Patients in whom a major reoperation was necessary (band removal, conversion to gastric bypass) were excluded from follow-up after reoperation.

Results were evaluated with respect to weight loss, complications, quality-of-life improvement, and correction of comorbidities. The percentage of excess body weight loss (EWL) and the BMI were used to assess weight loss. According to the criteria developed by Reinhold [23], the outcome was considered as excellent if the EWL was > 75%, good between 50 and 75%, fair between 25 and 50%, and poor below 25%. Quality-of-life improvement was assessed using the Moorehead-Ardelt score [21], which evaluates self-esteem, physical activities, social life, work, and sexual activity.

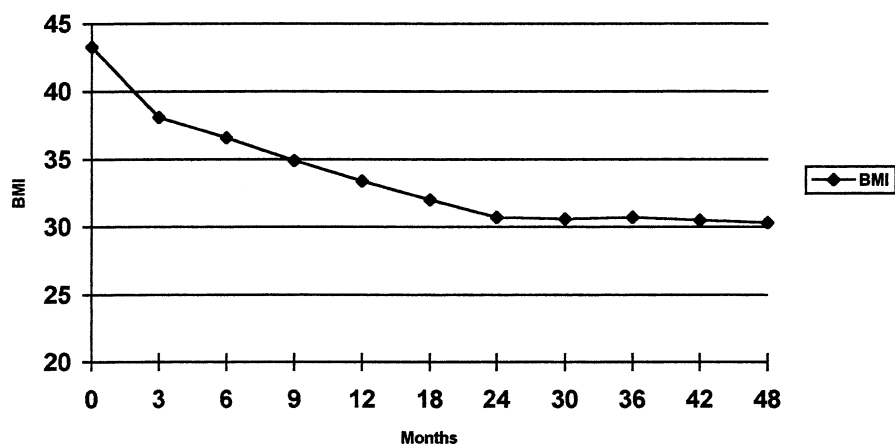
Results

A total of 300 patients were included in this series. There were 43 men and 257 women, with a mean age of 38.3 years (19–64). The mean initial weight was 119.2 kg (57–179), the mean initial BMI was 43.3 kg/m² (21–64.1), and the mean initial percentage of excess body weight was 96.5% (0–191.4). Gastric banding was a reoperation in three patients who had undergone a previous bariatric procedure, which explains the low inferior limit of the preoperative weight and BMI. Of the patients, 240 (80%) had at least one comorbidity, the most frequent being hypertension, glucose intolerance or diabetes, dyslipidemia, and gastroesophageal reflux disease with mild esophagitis.

Three patients had undergone a prior bariatric procedure (vertical banded gastroplasty) and were reoperated because of recurrence of staple line disruption (two cases) or severe food intolerance due to stenosis (one case). At the time of reoperation, these patients had BMIs of 31.2, 21, and 22.5 kg/m², respectively. The operation was initiated laparoscopically in all but two patients, who underwent a laparotomy because they both had two previous bariatric procedure on the upper stomach. Conversion was necessary in four patients (1.3%), who had multiple intraabdominal adhesions secondary to previous surgery, preventing creation of the pneumoperitoneum or safe intraabdominal dissec-

Table 2. Early reoperations

Type of reoperation	Cause	Time (POD)	Approach	Number
Band removal, suture	Gastric leak	10	Laparoscopy	1
Band removal, suture	Gastric perforation	7	Laparotomy	1
Band removal	Infection	20	Laparoscopy	1
Band removal	Infection	43	Laparoscopy	1
Port removal	Infection	10	Direct	1
Hemostasis	Bleeding (gallbladder)	3	Laparoscopy	1

**Fig. 1.** Evolution of BMI over time (months).

tion. One patient developed a severe bronchospasm at the induction of anesthesia, related to a drug allergy. No other intraoperative complication occurred. The mean duration of surgery was 90 min (40–270), decreasing over time to a mean of 75 min for the last 50 cases. Gastric banding was done with a Lapband in 152 and with a SAGB in 148 patients. Postoperative complications were noted in 21 patients (7%, Table 1). Overall, there were more early complications with the SAGB than with the Lapband (10% versus 3.9%, $\chi^2 = 4.27$, $p = 0.03$). One patient died on postoperative day 7 from a respiratory arrest. Early reoperation was necessary in 6 patients (2%, Table 2). Long-term follow-up varied between 6 weeks and 56 months. Follow-up is not complete, because some patients, who failed to attend follow-up visits despite repeated invitations to do so had moved and could therefore not be contacted by phone. Of the patients, respectively 96%, 92%, 87%, and 80% were available for follow-up after 1, 2, 3, and 4 years. The evolution of the mean BMI and mean excess weight loss are depicted in Figs. 1 and 2. Both curves reach a plateau after 2 years, with a mean EWL between 60 and 65% and a mean BMI between 30 and 31 kg/m². Figure 3 shows the outcome according to the extent of excess weight loss. As of 2 years after gastric banding, 60–70% of the patients had a good or very good result according to Reinhold's criteria. Weight loss was considered only fair or even insufficient in the remaining 30–40% of the patients. Comorbidities improved with weight loss, and the corresponding preoperative medications could either be stopped or reduced in all the patients but one. In the latter, antihypertensive therapy had to be started 9 months postoperatively despite a 13-kg loss. The incidence of fasting hyperglycemia, dyslipidemia, and

hyperuricemia was significantly reduced after 12 months, with a further improvement after 18–24 months (Fig. 4). Total cholesterol did not change very much and even increased in some patients. There was, however, an increase of the HDL-cholesterol fraction, and therefore a significant improvement of the total cholesterol/HDL cholesterol ratio. The Moorehead–Ardelt quality-of-life questionnaire showed a very significant improvement ($p < 0.001$) at all time points.

A total of 52 long-term complications developed in 49 (16.3%) patients (Table 3). Long-term complications were more prevalent with the Lapband than with the SAGB (21% versus 11.5%, $\chi^2 = 4.99$, $p = 0.02$). Major long-term complications occurred in 26 (8.6%) patients, band erosion being the most frequent (5.6%). Of the four patients who developed a port infection, three were found to have band erosion a few months later. Twenty-three (7.6%) patients had minor complications. A total of 55 reoperations were performed in 48 (16%) patients (Table 4). Major reoperations were necessary in 26 patients (8.6%). Thirteen of these could be performed laparoscopically.

Discussion

In the 1980s, and early 1990s, gastric banding was not a very popular bariatric procedure. Hence, it was performed only by a very limited number of surgeons. Since the mid-1990s, after the introduction of adjustable bands and laparoscopic techniques, it has been used more extensively and has even become the most popular bariatric procedure in many European countries and in Central and South America, as well as in Australia.

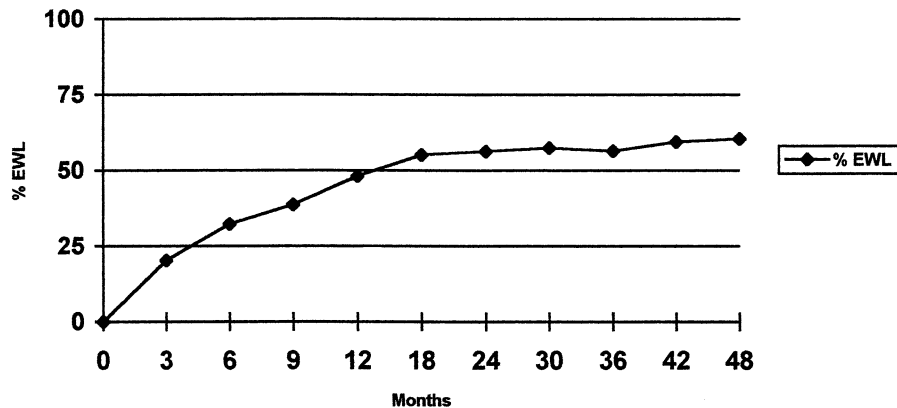


Fig. 2. Evolution of the % of excess weight loss (% EWL) over time.

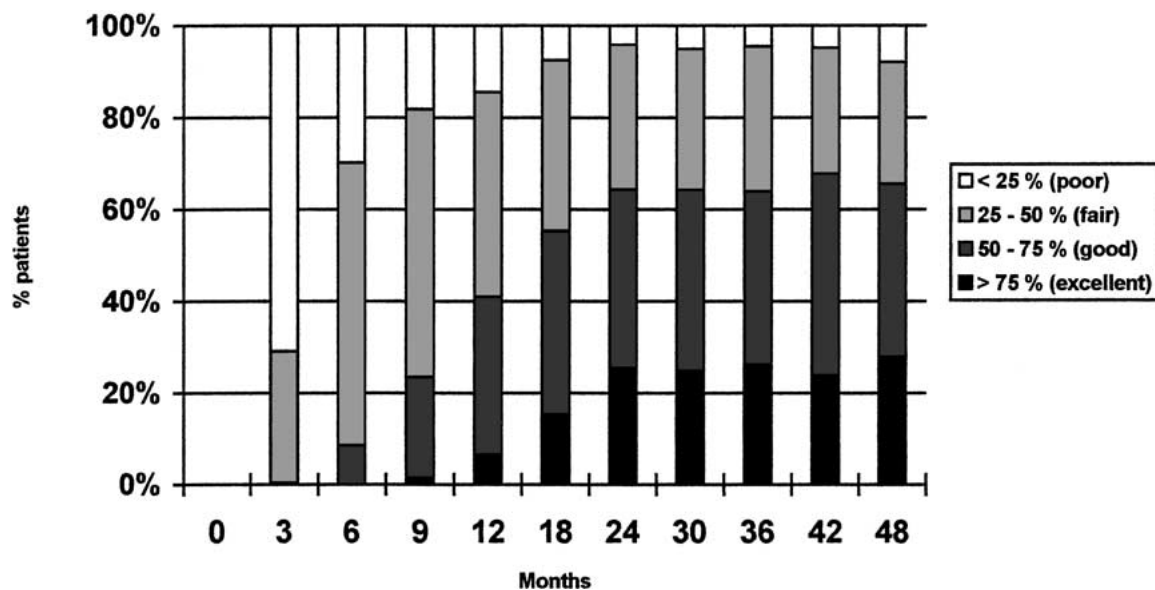


Fig. 3. Outcome according to Reinhold's criteria.

Some advantages of gastric banding over other bariatric operations such as vertical banded gastroplasty or Roux-en-Y gastric bypass are its adjustability, and the fact that the procedure involves no division of the stomach or bowel, and therefore no suture line or anastomoses with their inherent complications.

Recently, several series of patients having undergone laparoscopic gastric banding have been published. The early results in most European and Australian reports have generally been relatively good, with a low perioperative morbidity, a very low mortality, and a satisfying average excess weight loss [2, 8, 11, 15, 16, 17, 20, 25, 27, 30]. Others have reported less favorable results with insufficient weight loss and/or high long-term complications rates [9, 31]. Some of these have been attributed to technical errors in the placement of the band [5, 10], to overfilling of the band [12, 31], to the inexperience of bariatric surgeons with laparoscopic surgery, to the inexperience of laparoscopic surgeons with bariatric surgery, or simply to the learning curve.

Technical changes have been made since the first description of laparoscopic gastric banding. Initially, the band (Lapband) was placed relatively low on the pos-

terior aspect of the proximal stomach, within the lesser omental sac. Despite the placement of sutures to secure the band posteriorly, this technique was followed by a high rate of band dislocations and pouch dilatations, related to slippage of the posterior stomach wall through the band. Some slippages occurred also anteriorly, probably related to insufficient anterior fixation of the band. Technical modifications with the Lapband included minimal dissection and higher placement of the band, above the lesser sac, in order to form a very small 10–15 mL proximal gastric pouch, and placement of at least four sutures on the anterior aspect of the stomach to secure the band [10]. The technique for the placement of the SAGB was developed before the introduction of laparoscopy and involves placement of the band through the pars flaccida of the lesser omentum, above the bursa omentalis [13]. This technique has not been modified recently.

The bands, the tubing, and the connecting ports have also been submitted to slight modifications over time, in order to improve their handling, to facilitate their placement through the laparoscope, and to prevent leaks. Many series include patients operated on using

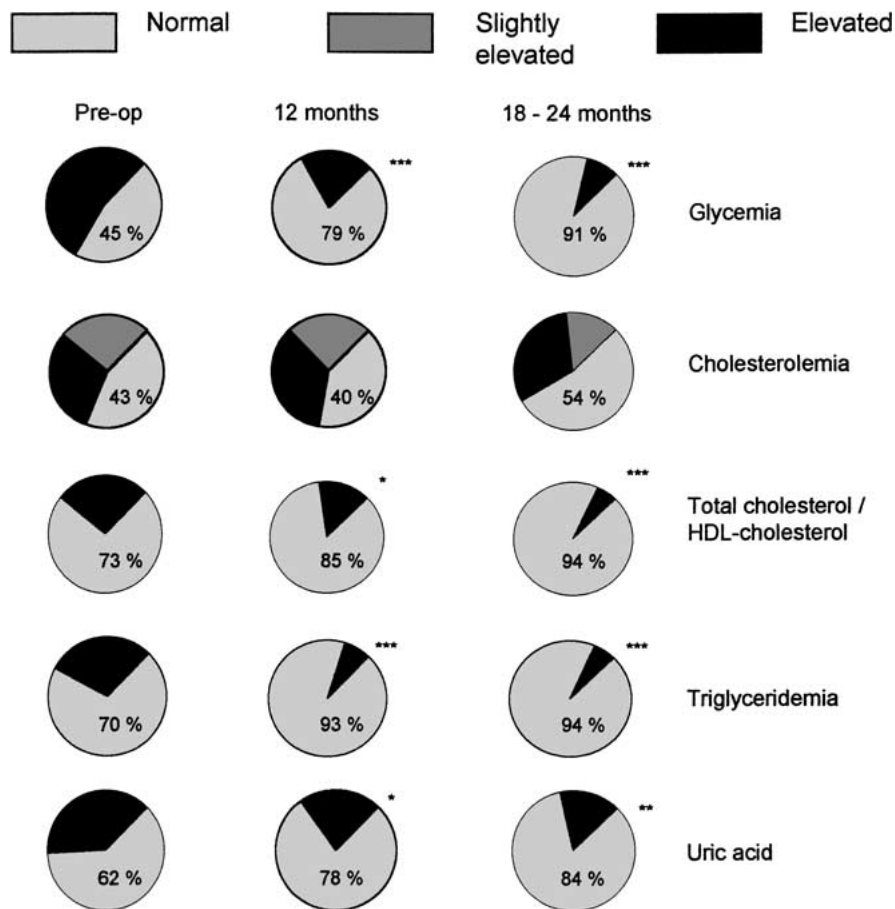


Fig. 4. Evolution of the prevalence of fasting hyperglycemia, hypercholesterolemia, hypertriglyceridemia, and hyperuricemia over time. (* $p < 0.05$, ** $p < 0.01$, *** $p < 0.001$ compared to the preoperative values).

Table 3. Long-term complications

Complication	Number
Leak	16 (5.3%)
Port-related problems	5 (1.7%)
Band erosion	17 (5.6%)
Pouch dilatation/slippage	8 (2.6%)
Port infection	3 (1%)
Psychological intolerance	1 (0.3%)
Band infection	1 (0.3%)
Insufficient weight loss	1 (0.3%)

Table 4. Long-term reoperations

Type of reoperation	Number
Band removal	9 (3%)
Port removal	3 (1%)
Conversion to Roux-en-Y gastric bypass	17 (5.7%)
Repair of leak (16 patients)	17 (5.3%)
Band repositioning	2 (0.7%)
Port repositioning	4 (1.3%)
Band change	2 (0.6%)
Drainage of abscess	1 (0.3%)
Major reoperations	26 (8.6%)

different techniques, and their results must therefore be interpreted with caution.

In this series, we deliberately excluded the patients operated during our learning curve and with an inappropriate surgical technique. The results presented herein are those of a surgical technique which is currently used by a team experienced with bariatric surgery, laparoscopic surgery, and laparoscopic bariatric surgery.

Our overall operative morbidity (6.6%), the major early complication rate (2.3%), and the operative mortality (0.3%) compare well with the literature on gastric banding [8, 10, 11, 15, 17, 24, 30] and with the recent literature on other laparoscopic bariatric procedures [1, 14, 19]. The 1.2% total infection rate (without perfora-

tion) despite prophylactic antibiotics is in line with infection rates reported after implantation of other prosthetic materials such as total hip prosthesis [29]. One gastric perforation was diagnosed using a water-soluble esophagogram on the 10th postoperative day and was attributed to a thermal injury due to monopolar cautery. The other perforation occurred after 1 week, with sudden onset of epigastric pain when the patient swallowed a paracetamol pill. At laparotomy, the perforation was found to be located on the anteromedial side of the pouch, above the band. Hyperpressure within the pouch and/or tearing from a gastrogastic suture could be the causative factors. There was no other complication related directly to the

band. Some postoperative complications in this series were related to associated procedures (seroma after abdominoplasty, hemorrhage from the cystic artery). The purely gastric-banding-related major complication rate is therefore 2%.

Our average results regarding weight loss are very satisfactory. A mean excess weight loss of about 60% is achieved after 2 years and maintained at least up to 4 years. This corresponds to the loss of 12–13 BMI units, and the BMI stabilizes around 30–31 kg/m². This average weight loss corresponds to a significant improvement of the comorbidities, especially glucose tolerance, sleep apnea syndrome, and dyslipidemia, even in patients with an excess weight loss of less than 50%. We must, however, keep in mind that, according to the criteria developed by Reinhold [23], weight loss is only fair or insufficient in 30–40% of the patients. Some patients failed to lose enough weight despite repeated band adjustments. Failure to initially lose weight cannot always be explained. Some patients reported only a very small restriction of their eating capacities even when the band looked very tight on a barium swallow. Others could not adjust to the eating restrictions and switched to a semiliquid diet and/or continued to snack. Physically handicapped patients, who were unable to increase their physical activity, lost less weight than their healthy counterparts. Four of our patients fell into this category, and none achieved a 50% excess weight loss. Patients who deliberately did not increase their physical activity (no interest, no time) also did worse.

Some patients initially did well, with a satisfying excess weight loss, but slowly regained weight. Weight regain after an initial satisfactory weight loss should prompt investigations (barium swallow, endoscopy) aimed at finding a complication (leak, band dislocation, pouch dilatation, band erosion). If the latter can be ruled out, a maladaptive eating behavior (replacement of solid food with a liquid or semiliquid diet) must be suspected. This is often associated with very poor tolerance to solid food when the band is too tight. Deflation of the band and proper counseling can be effective, but some patients will not return to solid food even with a completely deflated band, and the total amount of ingested food increases. Furthermore, the pouch empties more rapidly, and the satiety associated with pouch distention disappears earlier. Conversion to another bariatric procedure should be considered in these cases.

Late complications unfortunately can develop after any bariatric procedure. The most common late complications after gastric banding are pouch dilatation and/or slippage, band erosion, leaks, and infection. There is a considerable variation in the complication and reoperation rates reported in the literature after gastric banding, which vary from very low to 41% [8–11, 15–17, 20, 25, 30, 31]. This is probably due, at least in part, to the duration and completeness of the follow-up. Many authors fail to mention these parameters, and studies with complete information usually provide only a small percentage of patients with a follow-up exceeding 2 years. Some data from the literature therefore need to be interpreted with caution and probably underestimate the true complication rate of gastric banding. On

the other hand, reporting on patients operated on early in the author's experience will probably include complications related to technical errors during the learning curve and overestimate the morbidity. Our series includes 300 patients operated on after the learning curve. The follow-up rate is respectively 96%, 92%, 87%, and 80% after 1, 2, 3, and 4 years, and 134 patients have been followed up for at least 3 years.

We confirm that, provided the band is placed correctly above the bursa omentalis, the pouch dilatation/slippage rate is low (2.6%). In the past, we have managed this complication with laparoscopic band repositioning, but the results have been poor [26]. Another option is to change the band and place it within a new retrogastric tunnel. We now prefer laparoscopic band removal and conversion to gastric bypass. This has been accomplished successfully in the last five patients with pouch dilatation.

Band erosion occurred in 5.6% and was our most frequent major complication. It was asymptomatic in two patients, in which it was diagnosed during upper GI endoscopy performed in the context of a clinical study on reflux after gastric banding. The other patients all reported some epigastric pain, sometimes irradiating to the back, or weight regain, and one patient presented with diffuse peritonitis. Others have reported band erosion rates varying from 0 to 10.6% [12, 17, 18, 20, 24, 31]. Possible causes for band erosion such as overfilling, *Helicobacter pylori* infection, and band infection have been postulated [12, 24]. Forsell et al. have shown that the rate of band erosion is related to the type of follow-up [12]. Of the 17 patients with band erosion in this series, two experienced unexplained postoperative fever after gastric banding, and three developed a port infection (one postoperatively, two after several months). Twenty-nine percent of our band erosions might therefore be due to infection. No other cause could be detected in the remaining patients. *Helicobacter* infection was not detected systematically, and we strictly respected the maximum filling volumes of 5, respectively 9 mL for the Lapband and SAGB systems. Treatment of band erosion mandates band removal, because of the risk of intragastric lesion due to the band and severe hemorrhage (Walder J, personal communication). This can be performed laparoscopically or even endoscopically. Weight regain will inevitably follow. Later placement of a new band is possible, but carries a significant risk of further complication. Another bariatric procedure can also be performed after a few months. In order to avoid repeated procedures and maintain weight loss, we now offer the patients the option to perform a laparotomy, remove the band, and perform a gastric bypass in one session. This has proved possible in nine out of 10 patients in whom it was attempted, so far with satisfying results.

Leaks also represent a relatively frequent complication, with an overall incidence of 5% in this series. In most cases, there was a leak or a rupture of the Lapband catheter at the level of the metallic connecting piece between the port and the catheter. In one patient with an old Lap-band port, breakage occurred close to the port. In another, the leak was due to accidental puncture of

the catheter during adjustment by the surgeon. Repair was easily performed. The leaking port had to be changed. General anesthesia was necessary in five patients because the ruptured catheter had fallen back into the abdominal cavity. Since we fashion a loop with the tube to prevent shearing forces at the connecting piece, we have seen only four leaks (3.2% versus 15.2%, $\chi^2 = 9.76$, $p = 0.001$). Also we have not seen any leak from the port with the new Lap-band port.

Late port or band infection is relatively uncommon. Port infection can be caused by insufficient sterility during puncture. This was probably the cause in one of our patients who developed infection within 15 days of the first adjustment. In the other two, no direct cause could be found, as infection developed several months after the last puncture. Band infection can result from port infection, or can be caused by bacteremia. One patient developed a severe band infection with splenoportal venous thrombosis as a complication of a middle-ear infection [4]. Infection mandates removal of the infected material and antibiotic therapy.

Esophageal dilatation is considered by some authors to be a major concern [9]. As mentioned before, we perform routine barium swallows during follow-up. In our experience, five patients (1.6%) developed esophageal dilatation. Two were asymptomatic, and the other three reported increased regurgitation, heartburn, and nocturnal cough. The latter were relieved by band deflation and cisapride. In all cases, the control esophagogram performed 3 months later showed recovery of esophageal diameter and motility. A study on postoperative esophageal motility is currently underway in our department.

In conclusion, once the learning curve is over, with a proper surgical technique in experienced hands, and with a close specialized follow-up, laparoscopic gastric banding yields a very satisfactory weight loss in about two-thirds of the patients, which is comparable to the results of vertical banded gastroplasty [28]. The perioperative morbidity is lower than that of other common bariatric procedures such as vertical banded gastroplasty or Roux-en-Y gastric bypass. Severe long-term complications, leading to band removal with conversion to another bariatric procedure whenever possible, can be expected in about 10% of the patients. Another 5% of the patients are likely to develop minor complications responding to medical therapy or to limited revisional procedures, usually under local anesthesia.

The bariatric surgeon should be able to counsel his/her patients about all the possible types of obesity procedures, regarding both their efficacy in terms of weight loss and their possible complications and side effects. Provided the patient is fully informed, and there is no specific contraindication to gastric banding, the latter may be safely performed. However, adjustable gastric banding is a relatively recent procedure, the long-term tolerance of which is unknown. Roux-en-Y has proven to provide successful long-term weight loss in the majority of patients with an acceptable short- and long-term morbidity [22]. In our experience of more than 200 cases, an EWL in excess of 50% is

achieved in 88% of the patients after 2 years, which is superior to the 65% we report for gastric banding. Roux-en-Y gastric bypass remains the current gold standard in obesity surgery.

References

1. Azagra JS, Goergen M, Ansay J, De Simone P, Vanhaverbeek M, Devuyst L, Squelaert J (1999) Laparoscopic gastric reduction surgery. Preliminary results of a randomized, prospective trial of laparoscopic vs open vertical banded gastroplasty. *Surg Endosc* 13: 555–558
2. Belachew M, Legrand M, Vincent V, Lismonde M, LeDocte N, Deschamps V (1998) Laparoscopic adjustable gastric banding. *World J Surg* 22: 955–963
3. Cadière GB, Bruyns J, Himpens J, Favretti F (1994) Laparoscopic gastroplasty for morbid obesity. *Br J Surg* 81: 1524
4. Calmes JM, Bettschart V, Raffoul W, Suter M (2002) Band infection with splenoportal venous thrombosis: an unusual but severe complication of gastric banding. *Obes Surg* 12: 699–702
5. Chelala E, Cadière GB, Favretti F, Himpens J, Vertruyen M, Bruyns J, Maroquin L, Lise M (1997) Conversions and complications in 185 laparoscopic adjustable silicone gastric banding cases. *Surg Endosc* 11: 268–271
6. Consensus Development Conference Panel (1991) Gastrointestinal surgery for severe obesity: consensus development conference statement. *Ann Intern Med* 115: 956–961
7. Consensus Development Conference Panel (1999) Consensus sur le traitement de l'obésité en Suisse (1999) *Schweiz Med Wochenschr* 129 (suppl 114): 4S–20S
8. Dargent J (1999) Laparoscopic adjustable gastric banding: lessons from the first 500 patients in a single institution. *Obes Surg* 9: 446–452
9. Sugarman, Meador JG, Doty JM, Kellum JM, Wolfe L, Szucs RA, Turner MA (2001) High failure rate after laparoscopic adjustable silicone gastric banding for treatment of morbid obesity. *Ann Surg* 233: 809–818
10. Favretti F, Cadière GB, Segato G, Himpens J, Busetto L, De Marchi F, Vertruyen M, Enzi G, De Luca M, Lise M (1997) Laparoscopic adjustable silicone gastric banding (Lap-Band): How to avoid complications *Obes Surg* 7: 352–358
11. Fielding GA, Rhodes M, Nathanson LK (1999) Laparoscopic gastric banding for morbid obesity. Surgical outcome in 335 cases. *Surg Endosc* 13: 550–554
12. Forsell P, Hallerback B, Glise H, Hellers G (1999) Complications following Swedish adjustable gastric banding: a long-term follow-up. *Obes Surg* 9: 11–16
13. Forsell P, Heller G (1997) The Swedish adjustable gastric banding (SAGB) for morbid obesity: 9-year experience and a 4-year follow-up of patients operated with a new adjustable band. *Obes Surg* 7: 345–351
14. Higa KD, Boone KB, Teinchen H, Davies OG (2000) Laparoscopic Roux-en-Y gastric bypass for morbid obesity. Technique and preliminary results of our first 400 patients. *Arch Surg* 135: 1029–1034
15. Klaiber C, Metzger A, Forsell P (2000) Laparoskopisches gastric banding. *Chirurgie* 71: 146–151
16. Kunath U, Susewind M, Klein S, Hofmann T (1998) Erfolg und Misserfolg beim laparoskopischen "Gastric Banding". *Chirurgie* 69: 180–185
17. Miller K, Hell E (1999) Laparoscopic adjustable gastric banding: a prospective 4-year follow-up study. *Obes Surg* 9: 183–187
18. Nehoda H, Weiss H, Labeck B, Hourmont K, Lanthaler M, Oberwalder M, Aigner F (2001) Results and complications after adjustable gastric banding in a series of 250 patients. *Am J Surg* 181: 12–15
19. Nguyen TN, Goldman C, Rosenquist J, Arango A, Cole CJ, Lee SJ, Wolfe BM (2001) Laparoscopic versus open gastric bypass: a randomized study of outcomes, quality of life, and costs. *Ann Surg* 234: 279–291
20. O'Brien PE, Brown Smith WA, McMurrick PJ (1999) Prospective study of a laparoscopically placed adjustable gastric band in the treatment of morbid obesity. *Br J Surg* 85: 113–118

21. Oria HE, Moorehead MK (1998) Bariatric analysis and reporting outcome system. *Obes Surg* 8: 487–499
22. Pories WJ, Swanson MS, MacDonald KJ, Long SB, Morris PG, Brown BM, Barakat HA, deRamon RA, Israel G, Dolezal JM, Dohm L (1995) Who would have thought it? An operation proves to be the most effective therapy for adult-onset diabetes mellitus. *Ann Surg* 222: 339–352
23. Reinhold RB (1982) Critical analysis of long-term weight loss following gastric bypass. *Surg Gynecol Obstet* 155: 385–394
24. Silecchia G, Restuccia A, Elmore U, Polito D, Perrotta N, Genco A, Bacci V, Basso N (2001) Laparoscopic adjustable silicone gastric banding. Prospective evaluation of intragastric migration of the Lap-band. *Surg Laparosc Endosc* 11: 229–234
25. Stieger R, Thurnheer M, Lange J (1998) Morbide Obesitas: Ergebnisse des “laparoscopic gastric banding” bei 130 konsekutiven Patienten. *Schweiz Med Wochenschr* 128: 1239–1246
26. Suter M (2001) Laparoscopic band repositioning for pouch dilatation/slippage after gastric banding: disappointing results. *Obes Surg* 11: 507–512
27. Suter M, Bettschart V, Giusti V, Heraief E, Jayet A (2000) A 3-year experience with laparoscopic gastric banding for obesity. *Surg Endosc* 14: 532–536
28. Suter M, Jayet C, Jayet A (2000) Vertical banded gastroplasty. Long-term results comparing three different techniques. *Obes Surg* 10: 41–46
29. Urban J, Garvin K (2001) Infection after total hip arthroplasty. *Curr Opin Othop* 12: 64–70
30. Weiner R, Wagner D, Bockhorn H (1999) Laparoscopic gastric banding for morbid obesity. *J Laparoendosc Adv Surg Tech* 9: 23–30
31. Westling A, Bjurling K, Ohrvall M, Gustavsson S (1998) Silicone-adjustable gastric banding: disappointing results. *Obes Surg* 8: 467–474