

## Chronic middle foot pain in a patient with a swollen leg

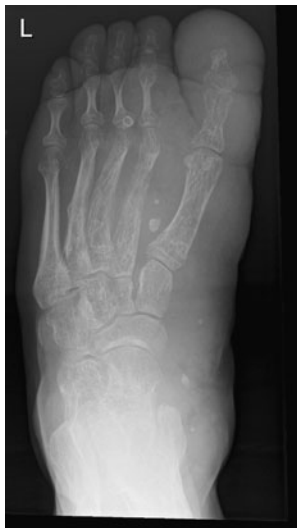Grzegorz Marek Karwacki · Ueli Studler ·  
Tilo Niemann

Received: 10 May 2011 / Revised: 29 June 2011 / Accepted: 4 July 2011 / Published online: 29 July 2011

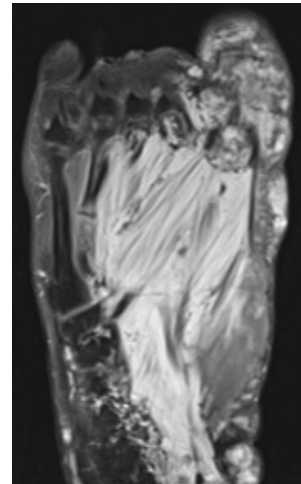
© ISS 2011

### Question

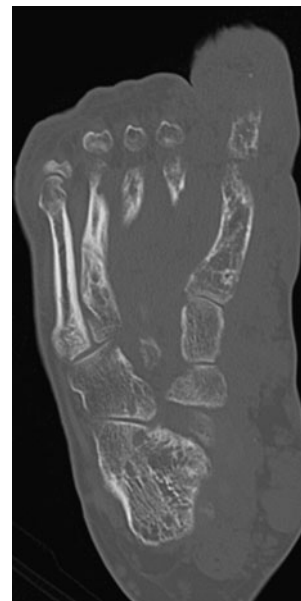A 32-year-old male patient with a known congenital syndrome was referred to our radiology department for work-up of persistent worsening foot pain over 4 weeks. No history of previous trauma was identified. Radiography and (for further work-up) MRI and CT examinations were performed (Figs. 1, 2, 3).



**Fig. 1** DP radiograph of the left foot



**Fig. 2** Axial MR T1-weighted fat-saturated post contrast image of the left foot



**Fig. 3** CT, axial reformation of the left foot

The diagnosis can be found at [doi:10.1007/s00256-011-1238-8](https://doi.org/10.1007/s00256-011-1238-8)

G. M. Karwacki (✉) · U. Studler · T. Niemann  
Department of Radiology, University Hospital Basel,  
Petersgraben 4,  
4031 Basel, Switzerland  
e-mail: karwackig@uhbs.ch