

TAP deficiency syndrome: chronic rhinosinusitis and conductive hearing loss

Marco Caversaccio · Harald Marcel Bonél ·
Rachel Carter · Anthony P. Williams ·
Stephan D. Gadola

Received: 27 July 2007 / Accepted: 7 February 2008 / Published online: 19 February 2008
© Springer-Verlag 2008

Abstract Nose–ear–throat manifestations of immunodeficiency disorders represent a diagnostic challenge for clinicians as these diseases often constitute the initial sign for connective disorders or autoimmune disease. The history of chronic rhinosinusitis and conductive hearing loss is often non specific. Therefore attention to an HLA class I deficiency must be considered if the disease has not been diagnosed on routine examination. One of the syndromes is due to a defective TAP complex, the peptide transporter complex associated with antigen presentation. Herein, we report two sisters with TAP-deficiency. The treatment of choice for TAP-deficient patients is conservative.

Keywords Immunodeficiency · TAP-deficiency · Chronic rhinosinusitis · Ear

M. Caversaccio (✉)
Department of ENT, Head and Neck Surgery, Inselspital,
University of Berne, Freiburgstrasse, 3010 Berne, Switzerland
e-mail: marco.caversaccio@insel.ch

H. M. Bonél
Institute of Diagnostic, Interventional and Pediatric Radiology,
Inselspital, University of Berne, Berne, Switzerland

S. D. Gadola
Department of Rheumatology and Clinical Immunology,
Inselspital, University of Berne, Berne, Switzerland

Present Address:
S. D. Gadola
Division of Infection, Inflammation and Repair,
Southampton University School of Medicine,
Southampton SO16 6YD, UK

R. Carter · A. P. Williams
Division of Cancer Sciences,
Southampton University School of Medicine,
Southampton SO16 6YD, UK

Introduction

Human primary immunodeficiency syndromes (PID) in adult patients often present the clinician with a diagnostic challenge. The upper airways are commonly initially involved in PID, but the history, clinical and histopathological findings are usually non-specific. TAP-deficiency syndrome is a recently described human PID, which clinically can resemble Wegener's granulomatosis (WG). Early diagnosis of TAP-deficiency is important, since inappropriate immunosuppressive treatment of such patients results in irreversible structural organ damage.

Antigen presentation via HLA class I molecules is an essential function of the mammalian adaptive immune system. HLA class I molecules have the dual role of presenting intracellular antigenic peptides to T lymphocytes and modulating the activity of cells bearing HLA class I binding receptors, such as natural killer cells and gamma-delta T cells [1, 2]. Primary human immunodeficiencies resulting from defects in the HLA class I presentation pathway segregate into three subgroups. TAP deficiency syndrome is the most common of these syndromes, and it is compatible with survival into adulthood [3]. The transporter associated with antigen presentation (TAP) is essential for the stabilisation and surface expression of HLA class I molecules [4]. TAP deficiency syndrome usually manifests itself in early childhood with chronic rhinosinusitis and otitis. The lower airways often get involved during adolescence with spastic bronchitis, pneumonia and bronchiectasis. In addition, most patients described to date suffered from necrotizing granulomatous skin lesions, typically appearing in adulthood [3, 5].

We present a family with two TAP-deficient sisters, in whom a chronic rhinosinusitis and conductive hearing loss were the dominant clinical manifestations. We discuss

the diagnostic workup and treatment guidelines of these patients.

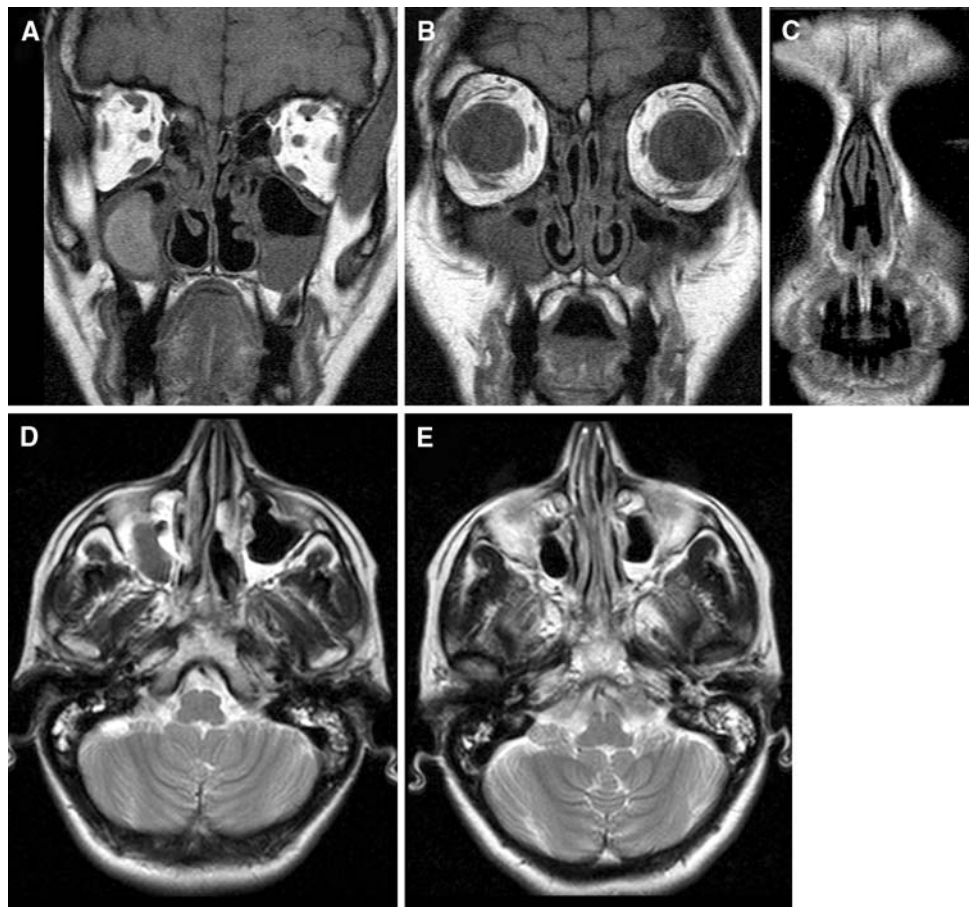
Report of two cases

Two sisters (SAB, 31, and GAB, 40 years old at the time of this report) in a southern Italian family have been suffering purulent rhinosinusitis and recurrent middle ear effusion since early childhood. One older sister and both parents have remained free of disease to the present day. The parents were not first degree cousins.

In both patients, pharyngitis and bronchitis appeared in later childhood. In the older sister (GAB), removal of nasal polyps during adolescence, as well as nasal septal corrective surgery with infundibulotomy at the age of 20 were carried out, but did not prevent recurrence of rhinosinusitis. In addition, bronchiectasis and necrotizing granulomatous skin lesions developed in the older sister during adulthood. A sinus biopsy showed moderate chronic lymphocytic and histiocytic inflammation in the submucosa and arterioles and venules surrounded by histiocytes and lymphocytes. Necrotizing granulomatous inflammation containing multinucleated giant cells and epithelioid cells were present.

Cultures, acid fast stains as well as PCR all failed to demonstrate *M. tuberculosis*, and tuberculostatic drug treatment had no effect on the progression of the lesions. One year before they presented to our clinic, both patients had been given high-dose steroid treatment. However, symptoms worsened in both patients, and pneumonia and bronchiectasis developed in the older sister. At the first presentation to our hospital in December 2003, dried nasal mucosae with crusts, and extensive septal perforation with near total destruction of the lamina quadrangularis were visible in the older sister. In the younger sister, secretion in the middle meatus of the nose and edematous mucosa were present with a rhinolalia. Swab cultures of the nose in both sisters repeatedly grew *Staphylococcus epidermidis* and *Pseudomonas aeruginosa*. Otoloscopic findings showed bilateral tympanosclerosis in both sisters. Imaging analyses, including Magnetic Resonance of the sinuses and mastoids, revealed chronic rhinosinusitis and mastoiditis (Fig. 1). Hearing was immediately improved after bilateral installation of grommets. (Fig. 2). Consequently, both patients were consistently treated with oral antibiotics according to the results of swab cultures. In addition, daily irrigation of the nose with saline solution and nose ointment were instituted. Under this treatment regimen, the disease has been

Fig. 1 MR imaging [left side SAB (a, d), right side GAB (b, c, e)] shows mucus retention in the maxillary sinuses as well as in the ethmoid cells (T1 weighted spin echo images) in coronal scans (a, b) and an anterior septal perforation (c). Bilateral mastoid fluid retention in both sisters was observed in T2 weighted spin echo images [visible on axial scans (d, e)]



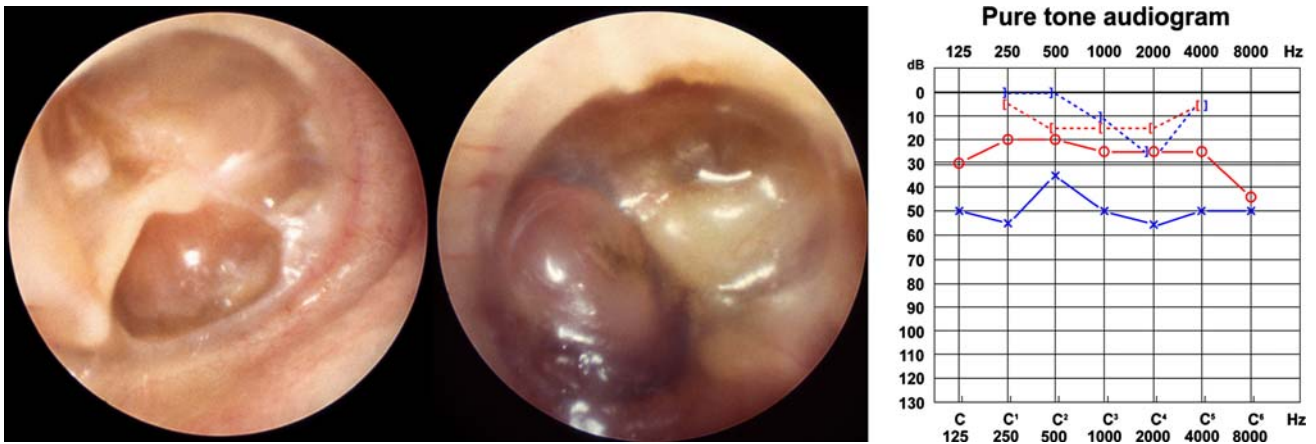


Fig. 2 Bilateral tympanosclerosis (right and left ear) with consequently conductive hearing loss visible in the pure tone audiogram (SAB)

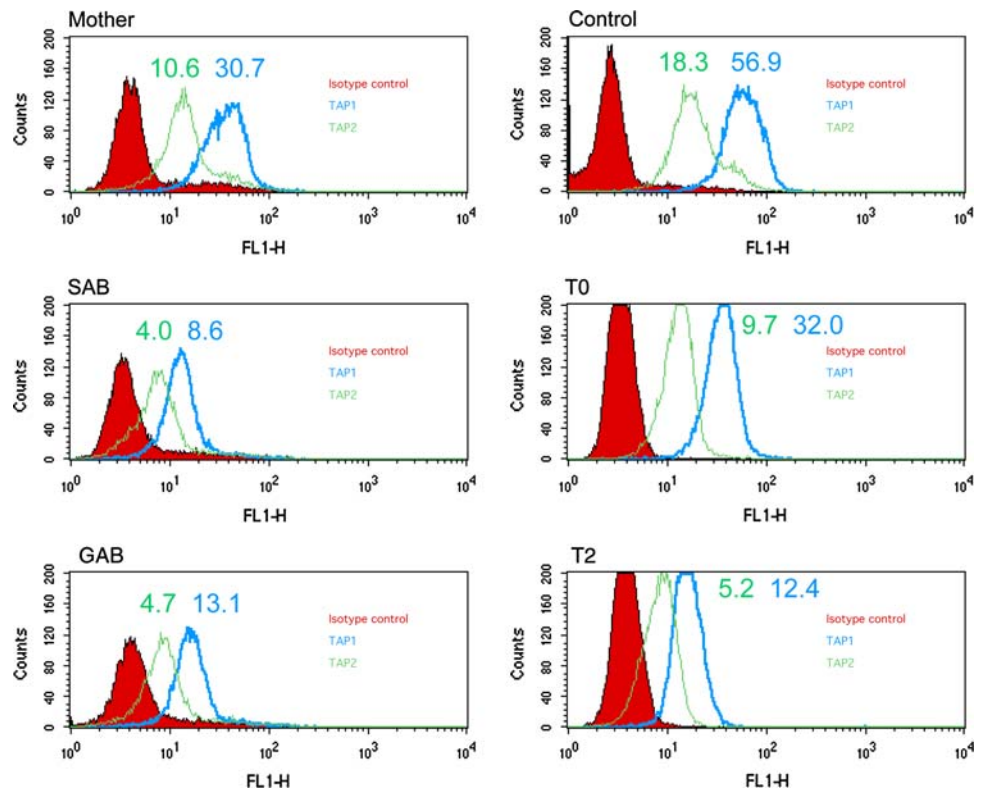
stable in both sisters without progression but with residual moderate mucosal inflammation.

Diagnosis of TAP-deficiency

TAP-deficiency syndrome is an autosomal recessive disease. Consistent with this diagnosis, tissue typing of the two patients revealed homozygous HLA class I and class II haplotypes (HLA-A*2601, B*4901, C*0701, DRB1*1302, DRB3*0301, DQB1*0604, DPB1*1501) [3]. Intracellular levels of TAP1 and TAP2 proteins were determined by

fluorescent activated cell sorter (FACS) analysis using anti-TAP1 and anti-TAP2 antibodies. TAP1/2 protein levels of the two sisters were compared to the mother and an unrelated healthy donor. The lymphoblast cell lines T0 (TAP competent) and T2 (TAP deficient) and were used as positive and negative controls respectively. The results of these experiments confirmed markedly reduced levels of TAP 1 and 2 proteins in both patients, while the TAP1/2 protein levels in the mother were in intermediary, consistent with a heterozygote carrier (Fig. 3). Sequencing of the TAP 1 gene revealed a deletion of one cytosine in exon 2, at nucleotide

Fig. 3 Intracellular FACS staining of TAP1 and TAP2 proteins in two TAP1-deficient patients, their mother, an unrelated healthy control patient, and the TAP competent and incompetent B-lymphoblast lines T0 and T2 respectively. Mean fluorescence intensities and the isotype control background staining are displayed (y-axis counts). Lymphocyte gated analysis (x-axis FL1-H)



819 of the coding sequence causing a frame shift and premature stop codon. The mutation was confirmed by sequencing genomic DNA.

Discussion

TAP deficiency syndrome should be included in the differential diagnosis of patients with early childhood onset of purulent ENT symptoms. Granulomatous skin lesions can appear during adolescence, as was the case in the older sister. Progressive destruction of the inner and outer nose, chronic recurrent rhinosinusitis, mastoiditis and pharyngolaryngitis are also features of this syndrome. The disease course is often complicated by recurrent bacterial bronchitis and pneumonia, with development of bronchiectasis, as was the case in the older sister. Immune suppressive therapy is absolutely contraindicated and can cause severe worsening of the disease course, e.g. progression of bronchiectasis and cerebral abscess per continuitatem [3, 5].

In fact, progression of chronic ENT lesions under immunosuppressive treatment points to the underlying immunodeficiency and should call into question autoinflammatory diagnoses such as WG [6]. Mycobacterial infection was ruled out in both patients and tuberculostatic treatment had no effect on the ENT lesions. In both sisters, acute infectious episodes of the upper and lower respiratory tract responded well to antibiotics.

The differential diagnoses of chronic rhinosinusitis and hearing disturbances in TAP deficiency include WG, Churg-Strauss syndrome, systemic lupus erythematosus, relapsing polychondritis, midline granuloma (T/NK-cell lymphoma), polyarteritis nodosa, Cogan's syndrome, microscopic polyangiitis, Behcet's syndrome and sarcoidosis [3, 7]. Serous otitis media results from inflammation and irritation from nasal secretions of the orifice of the Eustachian tube. In particular, TAP deficiency should be ruled out in patients with ANCA negative WG, childhood WG and familial WG [3, 5].

Initial laboratory assessment in a patient with suspected TAP deficiency syndrome should include an HLA haplotype and flow cytometric (FACS) quantitation of HLA class I cell surface expression on leukocytes. TAP deficiency is an autosomal recessive disorder, and most patients are children of consanguineous parents. The parents of our patients were not first degree cousins. However, the families of both parents had been resident for generations in a small village in southern Italy, which possibly explains the occurrence of haplotype homozygosity in the patients. Interestingly, a

male patient from northern Italy with TAP1 deficiency with an identical HLA haplotype and TAP1 mutation has been previously reported [8]. The family history of this patient revealed that his parents had previously migrated from the same area in southern Italy as our two patients. The primary objective of therapy for patients with TAP deficiency syndrome is tight control of infections in order to prevent the development or progression of bronchiectasis and ultimately respiratory failure [3]. In cases of extensive nasal mucosal involvement in TAP deficiency syndrome, endoscopic sinus surgery could be performed with caution in order not to add to the destruction potential of the disease with resulting increase of the nasal space and crust formation. Usually, patients manage locally with various forms of saline nasal irrigation frequently combined with a nasal ointment to soften the crusts.

In conclusion, patients with chronic rhinosinusitis and conductive hearing loss of unknown aetiology should be screened for HLA class I deficiency, and in particular, for TAP-deficiency, e.g. using the methods outlined in this article. The treatment of choice for TAP-deficient patients is conservative.

References

1. Pamer E, Cresswell P (1998) Mechanisms of MHC class I-restricted antigen processing. *Annu Rev Immunol* 16:323–358
2. Colonna M (1997) Specificity and function of immunoglobulin superfamily NK cell inhibitory and stimulatory receptors. *Immunol Rev* 155:127–133
3. Gadola SD, Moins-Teisserenc HT, Trowsdale J, Gross WL, Cerundolo V (2000) TAP deficiency syndrome. *Clin Exp Immunol* 121:173–178
4. Townsend A, Ohlen C, Bastin J, Ljunggren HG, Foster L, Karre K (1989) Association of class I major histocompatibility heavy and light chains induced by viral peptides. *Nature* 340:443–448
5. Moins-Teisserenc HT, Gadola SD, Cella M, Dunbar PR, Exley A, Blake N, Baycal C, Lambert J, Bigliardi P, Willemsen M, Jones M, Buechner S, Colonna M, Gross WL, Cerundolo V (1999) Association of a syndrome resembling Wegener's granulomatosis with low surface expression of HLA class-I molecules. *Lancet* 354:1598–1603
6. Rasmussen N (2001) Management of the ear, nose, and throat manifestations of Wegener granulomatosis: an otorhinolaryngologist's perspective. *Curr Opin Rheumatol* 13:3–11
7. Papadimitraki ED, Kymizakis DE, Kritikos I, Boumpas DT (2004) Ear-nose-throat manifestations of autoimmune rheumatic diseases. *Clin Exp Rheumatol* 22:485–494
8. De la Salle H, Zimmer J, Fricker D, Urlacher A, Kelly A, Salamero J, Powis SH, Donato L, Bausinger H, Laforet M, Jeras M, Spehner D, Bieber T, Falkenrodt A, Cazenave JP, Trowsdale J, Tongio MM (1999) HLA class I deficiencies due to mutations in subunit 1 of peptide transporter TAP1. *J Clin Invest* 103:9–13