

ORIGINAL PAPER

T. Sulser · W. Jochum · P. U. Heitz · D. Hauri

Histomorphological changes after neodymium: YAG laser-coagulation of the human prostate with the Side Focus fiber**Effect of power setting and time**

Abstract The objective of our study was to determine optimal treatment parameters and appropriate methods of examination for neodymium:yttrium-aluminum-garnet (Nd:YAG) high-power laser coagulation of the human prostate in relation to power setting and time. Transurethral free-beam laser coagulation was performed with the Side-Focus side-firing laser fiber in ten patients prior to planned radical surgery, of whom six underwent transperitoneal laparoscopic lymphadenectomy and laser coagulation 4–9 days prior to open surgery. Depth and volume of coagulated prostatic tissue were measured at power setting/time combinations of 40 W/90 s and 60 W/60 s, respectively, while holding total energy delivery constant. Microscopic examination in the early phase showed that epithelial cells had become loose from the basal-cell membrane. By 4–9 days there was evidence of conspicuous squamous epithelial metaplasia with a high proliferation rate as a sign of re-epithelialization. Using the Side Focus side-firing laser fiber, both treatment modalities showed comparable volume coagulation. In contrast there was a significant difference between those prostates removed at 4–9 days and those removed at 60–210 min after laser coagulation. We conclude that laser-induced changes in the human prostate are conclusively discernible only after 4 days.

Key words Prostate · Benign prostatic hyperplasia · Lasers · Laser surgery · Histomorphology

Introduction

Benign prostatic hyperplasia (BPH), which is a common disease affecting men, leads to micturition difficulties in

50% of 50-year-old men with the disease. At present two to four out of every ten males over 60 years of age are operated on for BPH [3]. For many years standard treatment has been transurethral resection of the prostate (TURP) and occasionally in the case of large adenomas open prostatectomy. Both treatments, although they have proved effective, are associated with a significant morbidity rate [8, 20]. Therefore minimally invasive procedures for the treatment of BPH are currently under debate among urologists. Visual laser ablation of the prostate (VLAP) using neodymium:yttrium-aluminum-garnet (Nd:YAG) laser is the main procedure in use at present. Many publications have considered the question of laser dosimetry and the extent of laser-induced coagulation using various fibers of different treatment modalities [2, 9–14, 17, 21]. So far the impact and extension of visual laser ablation in humans have rarely been subject to examination. In 1993 Bolton and Costello [4] first presented histological results from human prostate after Nd:YAG laser ablation. In the following years further studies were published dealing in particular with the extension of the laser-induced changes and the establishment of fiber-specific optimal treatment modalities for some special light guides with respect to time and energy used and method of application [5, 16, 18, 19, 23, 26, 29].

In this study we examined the histomorphological changes in human prostates following laser application with a specific fiber as well as carefully evaluated the extent of coagulation in relation to the power setting and time used. Based on an empirical optimal energy delivery of 3600 J for each setting [2, 9–11, 14], we assessed the effect of the energy (40 W/90 s vs 60 W/60 s) and time used on morphological changes.

Materials and methods

From September 1994 to June 1995 a group of ten patients with a mean age of 60.8 (range 55–70 years) was accepted for the study after their written personal consent was obtained and approval obtained from the Ethics Committee. A transperitoneal laparoscopic lymphadenectomy was performed in six patients with bioptically verified

T. Sulser (✉) · D. Hauri
Department of Urology, University Hospital Zurich,
CH-8091 Zurich, Switzerland

W. Jochum · P. U. Heitz
Department of Pathology, Institute of Clinical Pathology,
University Hospital Zurich, CH-8091 Zurich, Switzerland

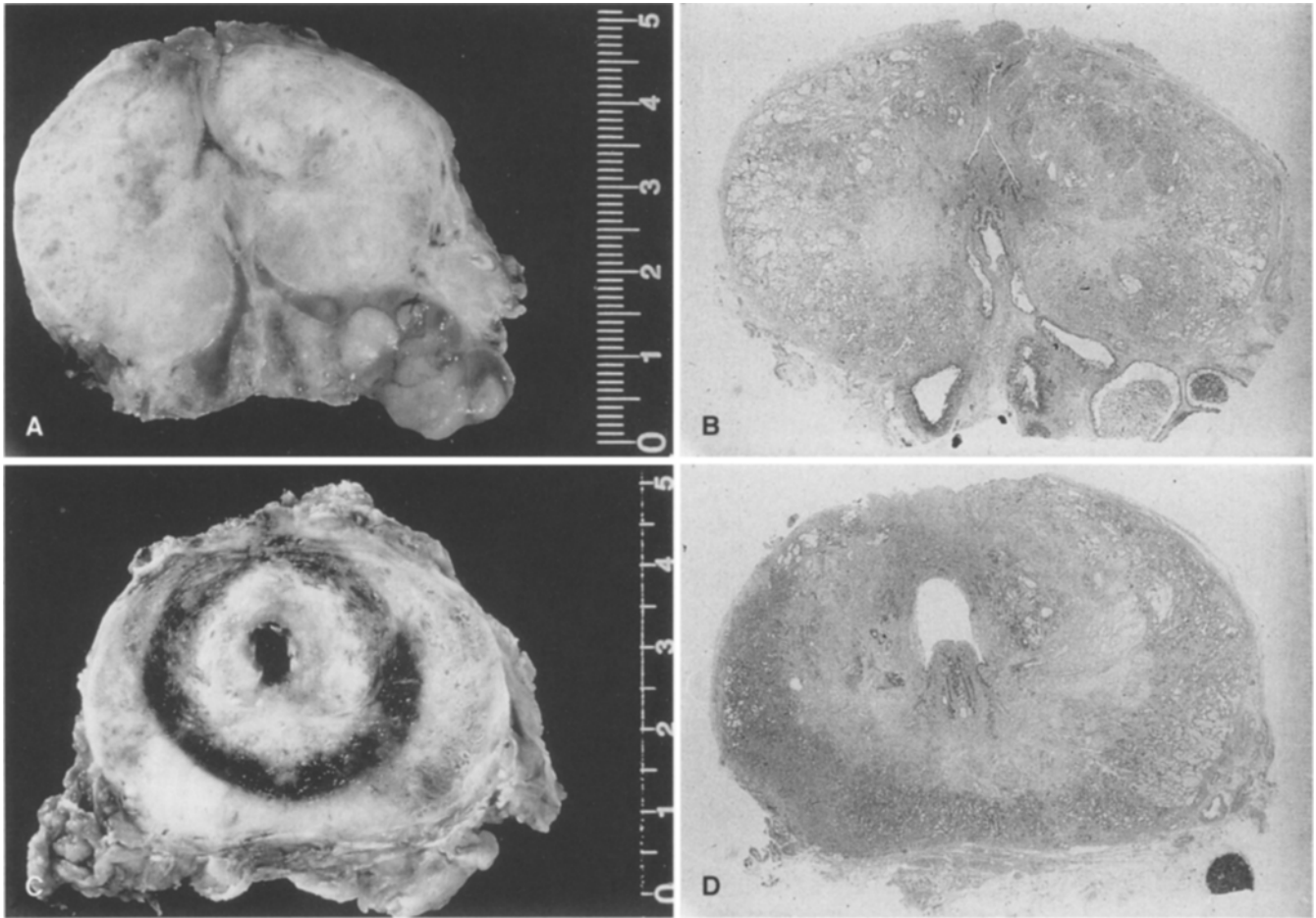


Fig. 1A–D Macroscopic view of human prostate after VLAP procedure (horizontal section, native and H & E-stained) at 210 min (A, B) and at 4 days (C, D) following a 40-W/90-s power setting

adenocarcinoma of the prostate, which was identified from the enlarged staging, after laser treatment and with the patient under the same anesthetic. Following histological examination of lymphadenectomy six patients underwent radical prostatectomy 4–9 days later. Another three patients in whom carcinoma of the prostate was located were primarily treated with radical cancer surgery. Another patient with urothelial carcinoma underwent radical cystoprostatectomy. In the latter four patients laser treatment was applied immediately prior to the planned surgery and with the patient under the same anesthetic. The specimen was taken at 60–210 min following laser treatment.

We used a 100-W cw-Nd:YAG laser (Dornier Medilas 4100) for energy delivery and the high-energy-density SideFocus fiber (Dornier), 600 μm in diameter, as the light guide. Laser treatment took place with the patient under insufflation anesthetic in the dorsal lithotomy position. It was performed under direct vision using a 23-Fr. flow-laser cystoscope (Circon, ACMI) under continuous irrigation with a new fiber for the settings of 40 W at 90 s and 60 W at 60 s, respectively. It was aimed close to the verumontanum in the 2, 4, 8 and 10 o'clock positions and with a total energy delivery of 14400 J.

After fixation in phosphate-buffered formalin (PBS, 10%), the prostatovesicectomy specimens were sectioned horizontally into slides 5 mm in width, macroscopically classified and recorded numerically. Subsequently the organ slices were embedded in paraffin and the cut surface of the sections stained with hematoxylin and eosin and examined under a light microscope. Laser-induced changes in the organ were analyzed as to their quality and extension.

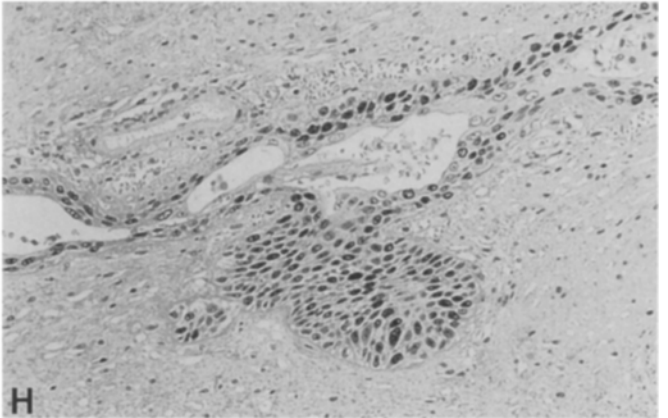
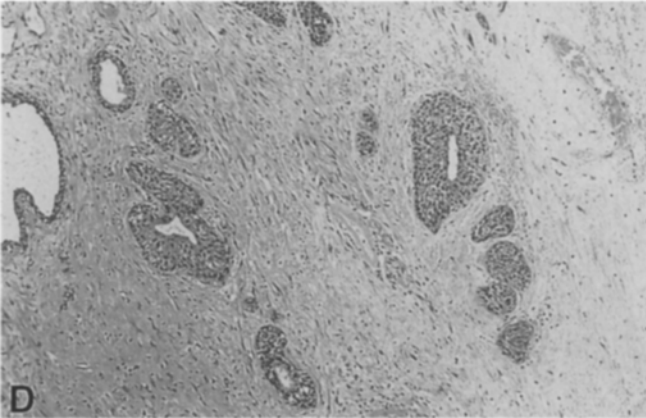
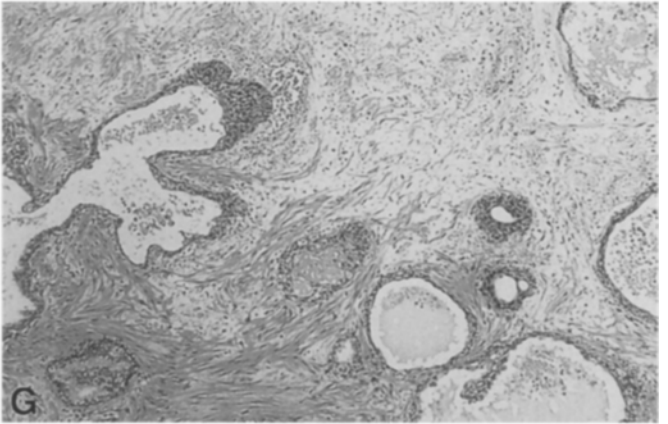
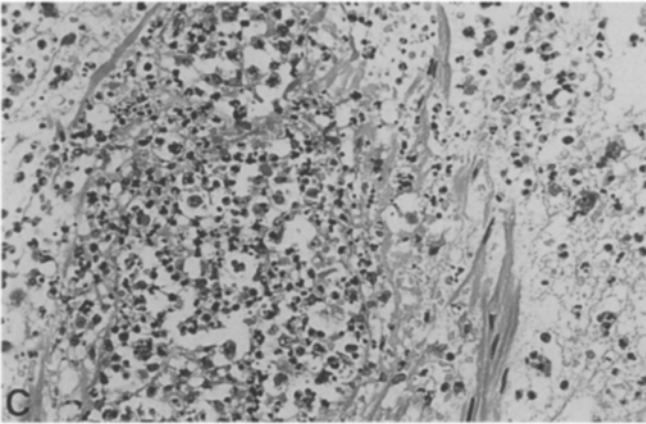
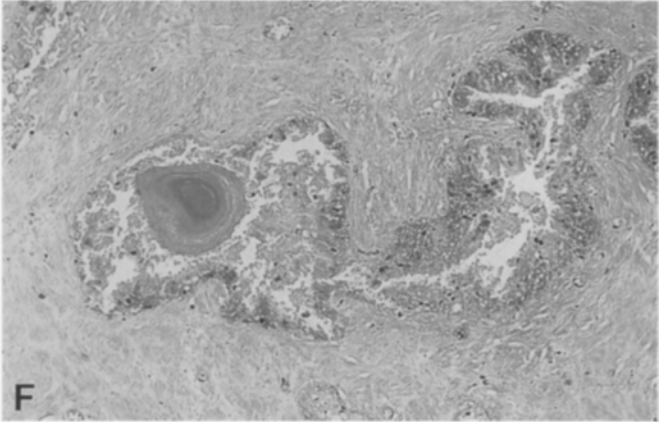
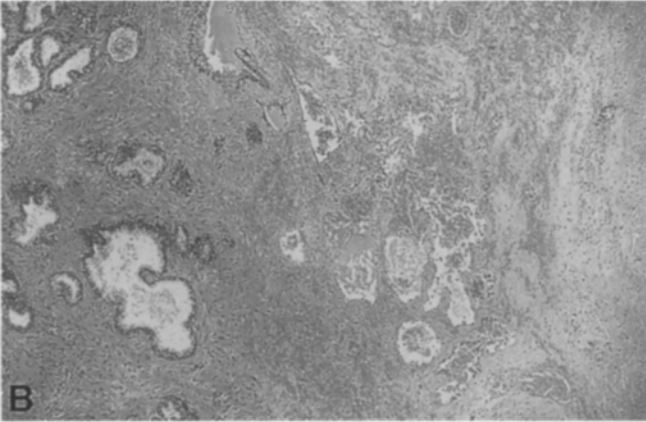
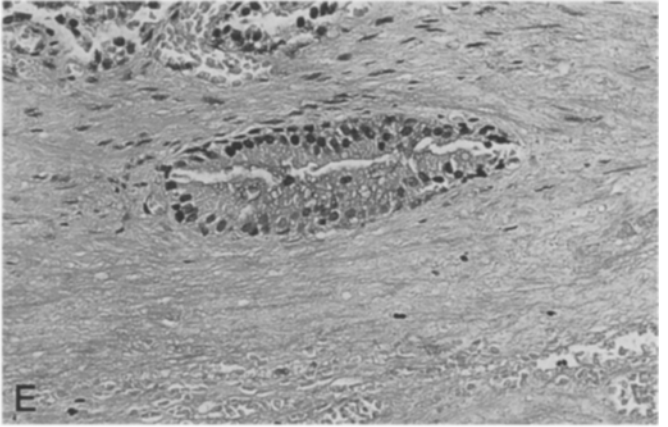
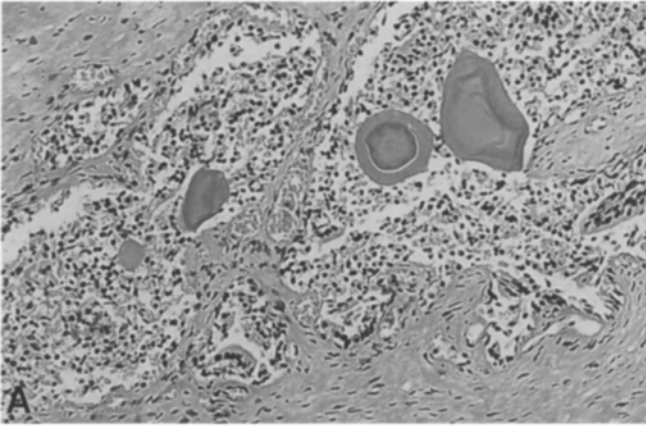
Results

Radical prostatovesicectomy was performed at an interval of 1 h to 9 days following transurethral laser ablation.

Early changes

On gross examination acutely harvested human prostates showed a zone of coagulation necrosis extending from the urethral lumen but with no sharp and well-defined margin. No clear hemorrhagic ring was observed in these specimens removed at an early stage, with only slight peeling and swelling visible (Fig. 1A, B). Microscopic examination showed that epithelial cells of the prostate glands had loos-

Fig. 2A–H Histology of earlier (A, E) and later (B, C, E, F, G, H) VLAP-induced changes in human prostate: Desquamation of damaged epithelial cells into glandular lumen (A, $\times 160$), margin of periurethral necrotic zone with extensive hemorrhage (B, $\times 40$), granular and histiocytic inflammation infiltration (C, $\times 260$), squamous epithelial metaplasia of glandular epithelium (D, $\times 70$), myxoid swelling and partial loss of stromal cell detail (E, $\times 160$), coagulation necrosis of epithelial as well as stromal cell elements (F, $\times 125$), pseudocystic resorption of cell dentritus (G, $\times 70$), marked proliferative activity of the regenerating glandular epithelium (H, $\times 160$, Mib-1 immunohistochemistry)



ened from the basal-cell membrane and showed desquamation in the glandular lumina (Fig. 2A). Solidified chromatinic nuclei and vacuolated cytoplasm were noted. Stroma was found to be edematous and numerous stromal cells lacked nuclei (Fig. 2E). With both treatment modalities the laser application sites could not be identified either by carbonization or by tissue disruption.

Delayed changes

By 4 days after laser application a demarcated spherical lesion was identified periurethrally with a rim of hemorrhage surrounding it (Fig. 1C, D). Microscopic examination revealed coagulative necrosis of epithelial and stromal cells with a nearly complete loss of cell and tissue detail. Cell nuclei were rare (Fig. 2F). Peripheral to the necrotic area, ectatic and in part thrombosed vessels with homogeneous eosinophilic walls alternating with zonal hemorrhage were prominent (Fig. 2B). Subsequently neutrophil granulocytes and macrophages were responsible for the gradual clearing away of detritus to the point of leaving behind absorbent cavities of small size (Fig. 2G). In the prostate tissue adjacent to the necrotic region, there was evidence of a conspicuous squamous epithelial metaplasia of the glandular epithelium (Fig. 2D). The proliferative ratio of this epithelium was 50–80% as seen in the immunohistochemical staining for the proliferation-associated antigen Ki-67 (Fig. 2H).

The discernible changes at 6 or 9 days following laser ablation were the same as those at 4 days. Particularly notable, however, were the absorbent and regenerative processes which had occurred by the later date. For both applied treatment settings no differences were noted in the quality of the morphological findings.

A confluent, periurethral necrotic area of variable dimensions was found in all six cases independent of the power setting at which prostate specimens were taken between 4 and 9 days after laser treatment. Necrotic areas showed a homogeneous character, thus not influencing extension by the variable tissue structure. Lesions were limited to the transition zones and they were confined to the organ in all specimens (Fig. 1A, B).

The dimension of the necrotic zones showed no major differences between modalities (Fig. 3). In the histological examination the necrosis showed a diameter of between 2.5 and 3.3 cm transversely after application of 40 W and 60 W, respectively, with a depth of between 2.5 and 3.1 cm. The coagulated volume for the 40-W group was between 6.2 and 16.4 cm³ and between 8.4 and 11 cm³ for the 60-W group, respectively. Both the largest and smallest coagulated volumes were found in the 40-W group (Table 1). Macroscopically laser-induced changes were not distinctly demarcated in specimens taken at an early stage 60–210 min after laser treatment (Fig. 1C, D). Microscopic changes were recorded in four cases, taking into consideration that the obtained values were significantly lower than those in specimens taken 4–9 days following laser irradiation (Fig. 4).

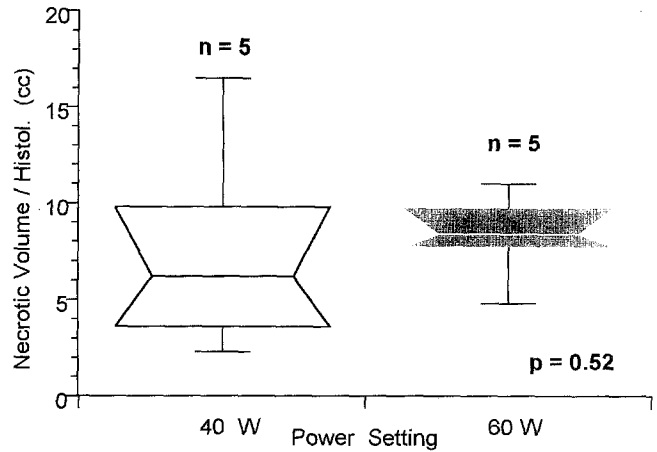


Fig. 3 Necrotic volume after VLAP on two different initial power settings. There is no significant difference

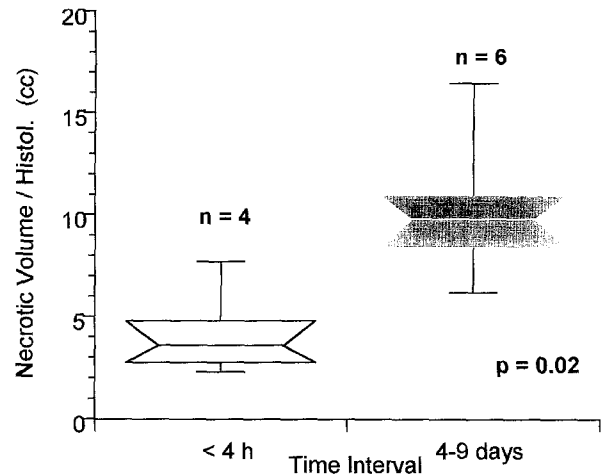


Fig. 4 Significant difference in necrotic volume of the removed prostate at two time intervals after VLAP

Table 1 Histological results of the four-quadrant laser procedure (2, 4, 8, 10 o'clock) with both modalities (40 W//90 s vs 60 W/60 s) with a total energy delivery of 14 400 J for each setting. (t transverse, a axial, s sagittal)

Patient	Modality	Interval	Necrotic extension (t×s×a) (cm)	Coagulated volume (t×s×a×π/6) (cm ³)
1	40 W/90 s	4 days	3.3×3.2×3.0	16.5
2	40 W/90 s	7 days	2.5×3.0×2.5	9.8
3	40 W/90 s	9 days	2.7×2.2×2.0	6.2
4	60 W/60 s	7 days	3.1×2.6×2.0	8.4
5	60 W/60 s	7 days	2.5×2.5×3.0	9.8
6	60 W/60 s	8 days	2.8×2.7×2.8	11
7	40 W/90 s	210 min	2.7×1.7×1.5	3.6
8	40 W/90 s	120 min	1.5×1.5×2.0	2.3
9	60 W/60 s	180 min	2.4×2.2×2.8	7.7
10	60 W/60 s	60 min	2.2×2.0×2.1	4.8

Discussion

Since the first report by Johnson's et al. [10] on visual laser application for the treatment of BPH, further experimental animal reports and dosimetry studies have been published [2, 9, 13, 14, 19, 21, 23]. So far data from clinical trials have shown very promising results [1, 6, 7, 15, 22]. Apart from optimal laser energy delivery and laser treatment time there are the different physical properties of the diverse light guides to be taken into consideration [25, 27, 30]. Not many more than a dozen fibers are currently available, and a number of reliable studies have looked at their impact on human tissue [13, 16, 18, 19, 23, 26, 29]; however, we have only three 3 light guides at our disposal (Urolase, Prolase II and Ultraline). In this paper we present the results of thermal coagulation in human prostates following laser treatment using a SideFocus fiber with subsequent systematic histopathological examination. In addition to comparing the two procedure modes, we also evaluated laser-induced changes in relation to treatment time.

Visual prostate laser application in four quadrants independent of power setting produces a confluent periurethral necrotic area of variable extent. Upon examination there were no substantial differences between irradiation power used as to the extent of necrotic zone; on the contrary we found the largest and the smallest necrotic volumes following 40 W irradiation. The reasons for the different extensions are a matter for debate: the variable tissue structure of the prostate from person to person leads to variable thermal conductivity and thermal storage including variable dissipation of heat through the vascular system. Moreover, the changing qualities of the light guides during treatment must be taken into account [25, 27, 30]. Although no differences was found in necrotic volume between both laser treatment modalities, from our experience we suggest using the 40-W power setting for the SideFocus fiber; at this setting there is little danger of the fiber being damaged, and inadvertent carbonization effects can thus be avoided.

Laser treatment with the SideFocus fiber produces thermocoagulation as reported by several authors [4, 13, 16, 19, 23, 26]. The maximum extension in the transverse plane (1.65 cm in radius) is nearly identical to that (1.75 cm) noted by Shanberg et al. [26] upon irradiation with the Prolase II fiber [26]. To lase the lateral lobe, Shanberg et al. used a dose higher than 50 000 J, targeting the whole surface extensively. Thus he achieved satisfactory ablation. We, however, used only a dose of 7200 J delivered at two spots for each lateral lobe. There is some doubt whether by increasing the applied energy up to more than 7200 J for each lobe, the depth of penetration and necrotic volume increased significantly. Dosimetry studies by Kabalin et al. [13, 16, 19] show that from a certain energy dose onward the tissue effect plateaus irrespective of the fiber type. This is probably due to the thermic and optical qualities of the tissue (heat storage, thermal transfer, light scatter) being altered through thermocoagulation. Moreover, we have

to take into account that with high-energy doses over a long period the above-noted damage to the fiber top appears increasingly likely to occur [27, 30].

For thermoregulation effects to become evident a certain period of time is needed, but we require further details as to its length. The specimens taken between 1 and 3.5 h showed no macroscopically laser-induced lesions. Microscopic examination revealed distinctly smaller areas of discernible necrosis than in the group of specimens taken 4–9 days following treatment (Table 1). This confirms earlier statements by other authors that a period longer than only several hours is required for laser-induced changes to turn into discernible demarcated lesions [28]. The earliest interval for this to occur in our study was 4 days. With this specimen (Fig. 1A, B) the periurethral necrotic zone had reached its final state following laser treatment. Therefore we suggest that laser-induced changes in human prostates are not conclusively discernible until 1 or 2 days after treatment at the earliest.

Laser radiation of the prostate histologically showed a coagulative necrosis of epithelial and stromal cells with ectatic and in part thrombosed vessels peripheral to necrotic zones. A homogeneous necrotic area not influencing extension by a variable tissue structure was present in all specimens. Furthermore, the lesions were limited to the transition zone and were confined to the organ in all specimens. Gradual clearing of detritus by neutrophil granulocytes and macrophages commenced and led to resorptive cavities of small size. Conspicuous squamous epithelial metaplasia of the glandular epithelium with a high proliferation rate was sign of re-epithelialization was present as soon as 4 days after laser application with the resorptive and regenerative faculties in those specimens removed at 6 or 9 days being particularly notable, in accordance with the findings of other authors [5, 24].

We conclude that laser treatment with the SideFocus fiber in a four-quadrant procedure is a safe way of producing a spherical zone of periurethral coagulative necrosis. Although there were no differences between both power modalities and the fibers used, we recommend a 40-W/90-s combination to give slow heating and thus avoid carbonization and vaporization at the application site in the urethra. For further dosimetry studies in human prostates we suggest that evaluation of the laser-induced coagulative necrotic zone be carried out after an interval of only 4 days.

References

1. Anson K, Nawrocki J, Buckley J, Fowler C, Kirby R, Lawrence W, Paterson P, Watson G (1995) A multicenter, randomized, prospective study of endoscopic laser ablation versus transurethral resection of the prostate. *Urology* 46:305
2. Assimos DG, McCullough DL, Woodruff RD, Harrison LH, Hart LJ, Li WJ (1991) Canine transurethral laser-induced prostatectomy. *Endourology* 5:145
3. Barry MJ (1990) Epidemiology and natural history of benign prostatic hyperplasia. *Urol Clin North Am* 17:495

4. Bolton DM, Costello AJ (1993) Histological study of Nd:YAG laser energy on prostatic adenoma as demonstrated in the intact prostate gland. *Br J Urol* 71:757
5. Costello AJ, Bolton DM, Ellis D, Crowe H (1994) Histopathological changes in human prostatic adenoma following neodymium:YAG laser ablation therapy. *J Urol* 152:1526
6. Costello AJ, Lusaya DG, Crowe H (1995) Transurethral laser ablation of the prostate – long-term results. *World J Urol* 13:119
7. Cowles RS, Kabalin JN, Childs S, Lepor H, Dixon C, Stein B, Zabba A (1995) A prospective randomized comparison of transurethral resection to visual laser ablation of the prostate for treatment of benign prostatic hyperplasia. *Urology* 46:155
8. Doll HA, Black NA, McPherson K, Flood AB, Williams GB, Smith JC (1992) Mortality, morbidity and complications following transurethral resection of the prostate for benign prostatic hypertrophy. *J Urol* 147:1566
9. Gill HS, Kabalin JN, Mikus PW (1994) Characterization of tissue effects produced by the ProLase II lateral-firing neodymium:YAG laser fiber in the canine prostate. *Lasers Surg Med* 15:185
10. Johnson DE, Levinson AK, Greskovich FJ, Cromeens DM, Ro JY, Costello AJ, Wishnow KI (1991) Transurethral laser prostatectomy using a right angle laser delivery system. *SPIE Proc* 1421:36
11. Johnson DE, Price RE, Cromeens DM (1992) Pathologic changes occurring in the prostate following transurethral laser prostatectomy. *Lasers Surg Med* 12:254
12. Kabalin JN (1993) Laser prostatectomy performed with a right angle firing neodymium:YAG laser fiber at 40 Watts power setting. *J Urol* 150:95
13. Kabalin JN (1995) Laser dosimetry studies in the human prostate. In: Marberger M (ed) *Application of newer forms of therapeutic energy in urology*. Isis Medical Media, Oxford, p 143
14. Kabalin JN, Gill HS (1994) Dosimetry studies utilizing the Urolase right angle firing neodymium:YAG laser fiber. *Lasers Surg Med* 14:145
15. Kabalin JN, Doll S (1996) Neodymium:YAG laser coagulation prostatectomy: 3 years of experience with 227 patients. *J Urol* 155:181
16. Kabalin JN, Sellers R, Bite G (1995) Neodymium:yttrium-aluminium-garnet laser dosimetry for the ProLase II side-firing delivery system in the human prostate. *Urology* 45:248
17. Kabalin JN, Gill HS, Gunars B (1995) Laser prostatectomy performed with a right-angle firing neodymium:YAG laser fiber at 60 Watts power setting. *J Urol* 153:1502
18. Kabalin JN, Gong M, Issa M, Sellers R (1995) Insight into mechanism of neodymium:yttrium-aluminium-garnet laser prostatectomy utilizing the high-power contact-free beam technique. *Urology* 45:421
19. Kabalin JN, Terris MK, Mancianti ML, Fajardo LF (1996) Dosimetry studies utilizing the Urolase right-angle firing neodymium:YAG laser fiber in the human prostate. *Lasers Surg Med* 18:72
20. Mebust WK, Holtgrewe HL, Cockett ATK, Peters PC (1989) Transurethral prostatectomy – immediate and postoperative complications. A cooperative study of 13 participating institutions evaluating 3885 patients. *J Urol* 141:243
21. Motamedi M, Torres JH, Orihuela E, Pow-Sang M, Cowan DF, Warren MM (1995) Laser photocoagulation of prostate: Influence of dosimetry. *Lasers Surg Med* 17:49
22. Norris JP, Norris DM, Lee RD, Rubenstein MA (1993) Visual laser ablation of the prostate: clinical experience in 108 patients. *J Urol* 150:1612
23. Orihuela E, Motamedi M, Pow-Sang M, LaHaye M, Cowan DF, Warren MM (1995) Histopathological evaluation of laser thermocoagulation in the human prostate: Optimization of laser irradiation for benign prostatic hyperplasia. *J Urol* 153:1531
24. Pow-Sang M, Orihuela E, Motamedi M, Torres J, Adesokan A, Cowan D, Warren MM (1996) Healing response of the canine prostate to Nd:YAG laser radiation. *Prostate* 28:287
25. Protsenko D, Torres JH, Chakrabarti P, Bell B, Orihuela E, Motamedi M (1996) Optical characterization and coagulation performance of side-emitting fiber delivery systems for laser therapy of benign prostatic hyperplasia: A comparative study. *Urology* 47:845
26. Shanberg AM, Lee IS, Tansey LA, Sawyer DE, Rodgers LW, Ahlering T (1994) Depth of neodymium:yttrium-aluminium-garnet laser in the human prostate at various dosimetry. *Urology* 43:809
27. Slaa ET, Van Ettergem AF, Van't Hof CA, Debruyene FMJ, De la Rosette JJMCH (1995) Durability of laser fibers. *World J Urol* 13:83
28. Stein BS (1994) Laser-tissue interaction. In: Smith JA Jr, Stein BS, Benson RC (eds) *Lasers in urologic surgery*, 3rd edn. Mosby-Year Book, Chicago, p 10
29. Sulser T, Jochum W, Huch Böni RA, Briner J, Krestin GP, Hauri D (1995) Morphologische und MRT-Veränderungen nach visueller Laserablation der Prostata. *Akt Urol* 26:109
30. van Swol CFP, Slaa ET, Verdaasdonk RM, De La Rosette JJMCH, Boon TA (1996) Variation in output power of laser prostatectomy fibers: A need for power measurements. *Urology* 47:672