

## Single Port Access Laparoscopic Cholecystectomy (with Video): Reply

Pascal Bucher · Nicolas Buchs · François Pugin · Sandrine Ostermann · Philippe Morel

Published online: 26 February 2011  
© Société Internationale de Chirurgie 2011

We read with interest the letter of Papagoras et al. [1] which pointed out several important issues regarding single port access cholecystectomy as described in our article [2]. They raised a question about exposing the gallbladder and hepatoduodenal ligament during single access cholecystectomy, essentially referring to the presented video [2]. We first stress that we agree with them regarding the 3-year-old technique illustrated. It does not fulfill the requirements of the critical view of safety for laparoscopic cholecystectomy. The technique has since been modified based on our growing experience and by using different ports and instrumentation [3–5]. However, we do not want to discuss any specific instrumentation as we wish to avoid what could be seen as marketing and because many tools can be used instead others. Moreover, although the industry and others can argue about the need for new tools, many single access endoscopic surgeries can be performed using conventional laparoscopic, reusable, or “low cost” instruments.

Exposure is no longer achieved with transparietal stitches, which are static and, moreover, may be associated with accidental puncture of the gallbladder, with its associated oncological risk [6]. We now use either an intracorporeal grasper or additional instruments. The first approach implies use of a quite expensive instrument, but does safety have a cost? The second may be less expensive but invites increased conflict. Regardless, improvements in the armamentarium of laparoendoscopic single-site surgery are needed to allow safer, but mainly more reproducible,

techniques for cholecystectomy. Finally, before starting a single access endoscopic surgery program, one should attend training courses as proposed by surgical societies. Such attention can, if nothing else, help avoid repeating the mistakes that the pioneers in the field (and we) have made [7–9].

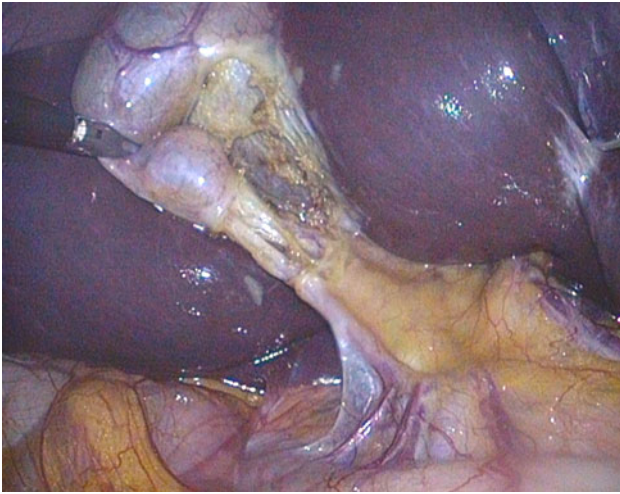
Regarding the critical need for safety during cholecystectomy, we completely agree that it should be achieved during all cases of minimally invasive cholecystectomy, including single access endoscopic surgery (SAES) [4, 10, 11], as we are now achieving with the progress made with SAES cholecystectomy (Fig. 1) [3, 10]. Although intraoperative cholangiography can certainly help avoid a common bile duct lesion, it also allows detection of an accessory or sectorial duct lesion; and eventually a bile duct stone can be mobilized during gallbladder manipulation. Thus, we believe that recommending cholangiography for SAES cholangiography is not untoward. It is a “low cost” quality and safety control that may decrease the dramatic consequences of a biliary tract accident [3, 12, 13].

Paragoras et al. commented on the introduction of this new technique with references to the laparoscopic revolution. As they probably know, the introduction of laparoscopy was driven by patient interest and industry marketing, followed by surgeons’ interest [14]. Thus, taking into account what could be patient perception and preference is now simply alerting surgeons to continue work in this area [8, 15]. In fact, the introduction of new technologies increases costs. However, as already noted, along with innovation being costly, safety too may be related to cost increases [16].

In conclusion, while running the risk of being viewed as “aficionados” of surgical innovation, we want to stress that through our work, in close collaboration with others, we try to foresee how future surgery innovation can offer less

---

P. Bucher (✉) · N. Buchs · F. Pugin · S. Ostermann · P. Morel  
Department of Surgery, Visceral and Transplantation Surgery,  
University Hospital Geneva, 24 Rue Micheli-du-Crest,  
1211 Geneva, Switzerland  
e-mail: pascal.bucher@hcuge.ch



**Fig. 1** Critical view of safety during laparoendoscopic single-site cholecystectomy. Note the anterior cystic artery originating from a right hepatic artery

traumatic surgery. In this regard, SAES, as “needlescopic” laparoscopy, or NOTES, are simply ways to explore the possibility of reduced port access surgery, which allows us to offer what our patients are seeking: a safe, curative, less mutilating solution to their problem [8, 17].

## References

- Papagoras D, Kanara M, Argiropoulos-Rakas C, Tsianos G (2011) Single port access laparoscopic cholecystectomy (with video). *World J Surg* 35(1):235–236
- Bucher P, Pugin F, Buchs N et al (2009) Single port access laparoscopic cholecystectomy (with video). *World J Surg* 33: 1015–1018
- Bucher P, Pugin F, Morel P (2010) From single-port access to laparoendoscopic single-site cholecystectomy. *Surg Endosc* 24:234–235
- Podolsky ER, Curcillo PG 2nd (2010) Reduced-port surgery: preservation of the critical view in single-port-access cholecystectomy. *Surg Endosc* 24:3038–3043
- Curcillo PG 2nd, Wu AS, Podolsky ER et al (2010) Single-port-access (SPA<sup>TM</sup>) cholecystectomy: a multi-institutional report of the first 297 cases. *Surg Endosc* 24:1854–1860
- Bucher P, Pugin F, Morel P (2010) Laparoscopic single-site cholecystectomy and occult gallbladder cancer. *Surg Endosc* 24:1701
- Gill IS, Advincula AP, Aron M et al (2010) Consensus statement of the consortium for laparoendoscopic single-site surgery. *Surg Endosc* 24:762–768
- Bucher P, Pugin F, Ostermann S et al (2010) Patient’s point of view on surgical innovations: for less traumatic surgery and enhanced recovery. *Rev Med Suisse* 5:1292–1297
- Neugebauer EA, Becker M, Buess GF et al (2010) EAES recommendations on methodology of innovation management in endoscopic surgery. *Surg Endosc* 24:1594–1615
- Wijsmuller AR, Leegwater M, Tseng L et al (2007) Optimizing the critical view of safety in laparoscopic cholecystectomy by clipping and transecting the cystic artery before the cystic duct. *Br J Surg* 94:473–474
- Emous M, Westertep M, Wind J et al (2010) Registering the critical view of safety: photo or video? *Surg Endosc* 24:2527–2530
- Sanjay P, Fulke JL, Exon DJ (2010) ‘Critical view of safety’ as an alternative to routine intraoperative cholangiography during laparoscopic cholecystectomy for acute biliary pathology. *J Gastrointest Surg* 14:1280–1284
- Gigot J (2007) Bile duct injury during laparoscopic cholecystectomy. *J Chir* 144:383–384
- Périssat J (1999) Laparoscopic surgery: a pioneer’s point of view. *World J Surg* 23:863–868
- Swanstrom L, Volkmann E, Hungness E et al (2009) Patient attitudes and expectations regarding natural orifice transluminal endoscopic surgery. *Surg Endosc* 23:1519–1525
- Winter D (2009) The cost of laparoscopic surgery is the price of progress. *Br J Surg* 96:327–328
- Bucher P, Pugin F, Ostermann S et al (2011) Population perception of surgical safety and body image trauma: a plea for scarless surgery? *Surg Endosc* 25:408–415