

# Fibrin versus polyethylene glycol sealant: an experimental study in rabbits

Gertrude M. Beer · Maria Schneller ·  
Heidi Cristina-Schmitz · Urs Hug ·  
Daniela Mihic-Probst

Received: 15 March 2008 / Accepted: 1 May 2008 / Published online: 10 June 2008  
© Springer-Verlag 2008

**Abstract** Fibrin glue has been applied universally in general surgery as an adhesive, hemostatic, or embolizing agent. In reconstructive surgery, fibrin has been used mainly for nerve and microvascular repair or as a substitute for sutures in skin closure and skin grafting. Another area of increasing use is in face-lift surgery, where the goal is to improve hemostasis on the raw surfaces and to discourage the occurrence of major hematomas. However, as most components of the fibrin glue are derived from human or bovine plasma, they may cause allergic reactions and transmit infectious agents such as hepatitis or AIDS virus, or prions such as the Creutzfeldt-Jakob disease agent. With these risks in mind, we tested polyethylene glycol (PEG) sealant, a recently introduced and purely synthetic vascular sealant, as an alternative to fibrin glue. A 2×2 cm subcutaneous pocket was created on the dorsal thighs of

ten New Zealand White rabbits by an incision medial to the sciatic vein. The pockets were randomly filled with either 0.2 ml of thawed fibrin glue or PEG sealant. After the operation, the thighs were inspected macroscopically for hematoma, seroma, or granuloma formation. Eleven weeks later, the animals were killed, and the fibrin and polyethylene glycol-filled pockets were harvested en bloc with the overlying skin and processed for histological examination. A swelling, viewed macroscopically, was visible at the experimental site in three thighs of the fibrin group, but in none of the PEG group. Only two specimens of the fibrin group and five specimens of the PEG group showed no signs of inflammation. All other specimens revealed signs of chronic or granulomatous inflammation, with no significant difference between the groups. This experimental study showed that 11 weeks after application of either fibrin or PEG sealant, signs of chronic or even granulomatous inflammation were detectable in 2/3 of the specimens in the fibrin group and in approximately 50% of the specimens in the PEG group. Beyond the comparable potential of both sealants to induce inflammatory tissue reactions, PEG sealant has some notable advantages as it is purely synthetic and therefore carries no risk of transmission of viral pathogens or prions. The combination of this safety profile, the ease of application, and the consistently good reported hemostatic results obtained with PEG sealant makes it an interesting alternative to fibrin glue in plastic surgery.

---

G. M. Beer · M. Schneller · U. Hug  
Division for Plastic, Hand and Reconstructive Surgery,  
Department of Surgery, University Hospital Zurich,  
Zurich, Switzerland

H. Cristina-Schmitz  
Institute for Laboratory Animal Science,  
Central Biological Laboratory, University Zurich,  
Zurich, Switzerland

D. Mihic-Probst  
Institute of Surgical Pathology, Department of Pathology,  
University Hospital Zurich,  
Zurich, Switzerland

G. M. Beer (✉)  
Division of Plastic and Aesthetic Surgery, Bodenseeklinik Swiss,  
Neuseeland 14,  
CH-9404, Rorschacherberg, Switzerland  
e-mail: gertrude.beer@access.uzh.ch

**Keywords** Fibrin glue · Polyethylene glycol · Hemostasis ·  
New Zealand white rabbit · Experimental surgery

## Abbreviations

PEG polyethylene glycol

## Introduction

Commercially available fibrin glue is a topical agent that initiates hemostasis by providing the components required to activate the final substrate of the coagulation cascade. It has been used in Europe for the past 40 years and is being increasingly used in the US after having received US Food and Drug Administration approval in 1998.

In the early fibrin glue era, researchers mixed their fibrin components themselves, which was a time-consuming and cumbersome procedure. Today, however, two simplified forms of fibrin glue are available in pre-packed delivery systems. The first system consists of four color-coded vials, each containing one of the four components of fibrin glue, where the preparation of the final glue first involves heating the first two vials (the sealer protein and the fibrinolysis inhibitor aprotinin) for 10 min and then mixing them. The two remaining vials (thrombin and calcium chloride) are also mixed and each of the two mixed components is filled in a separate syringe in a dual injection system that ensures simultaneous mixing and delivery to the tissues. The second pre-packed, more convenient form is a ready-to-use dual syringe system where the fibrin components are already filled in their mixed forms. These syringes, however, must be stored deeply frozen and thawed before use.

In general surgery, fibrin has been applied universally as an adhesive, hemostatic, or embolizing agent in countless numbers of procedures. In reconstructive surgery, fibrin has been used as a substitute for sutures in skin closure, for skin grafting, and for nerve and microvascular repair. Nerve repair has probably been the main clinical area where fibrin glue has been routinely applied [1].

Another application of fibrin has been its increasing use in face-lift surgery, with the goals of improving hemostasis on the raw surfaces and discouraging the occurrence of major hematomas [2]. As a result, fibrin may also decrease edema and ecchymosis by closer apposition of the dissected tissues, and may also eliminate postoperative wrinkling or rippling of the skin, thus accelerating healing and minimizing patient discomfort [3]. At the same time, the application of fibrin glue obviates the need for bulky dressings, drains, ointments, wraps, and postoperative supportive garments [4, 5].

Besides these obvious advantages in face lift surgery, fibrin does have distinct disadvantages. One of these disadvantages is the fact that some patients develop localized skin necrosis, probably due to inconsistent preparation, including failure to dissolve the glue material properly during preparation, inhomogeneous and overly thick areas of glue application, or improper patient positioning with resultant pooling and clumping [6]. In nerve surgery involving nerve repair, nerve-constricting

granulomas have also been reported after the application of fibrin glue [7]. Another major disadvantage of fibrin glue is the fact that it is derived from human and bovine plasma, and may therefore potentially transmit infectious agents such as viruses and prions [8]. Despite the fact that the risk of transmitting viruses can be reduced by heating the glue to 60°C and screening plasma donors for prior exposure, fibrin glue can still potentially transmit prions such as the Creutzfeldt–Jakob disease agent. To add to the disadvantages, fibrin glue is contraindicated in individuals known to be hypersensitive to bovine protein because of the possible risk of anaphylaxis [9].

Bearing these risks of the application of fibrin glue in mind, we looked for an alternative. Our criteria for an alternative sealant were that it should be biodegradable, biocompatible, and entail no risk of viral transmission. It should also induce minimal tissue reaction, be readily available, easy to apply, and function in a moist and bloody environment, while inducing hemostasis and establishing a strong and stable bond. Initial surgical reports have indicated that polyethylene glycol (PEG) sealant, receiving US food and drug administration approval in December 2003, possesses these characteristics [10–13]. PEG sealant is a hydrogel that is formed when two derivatized PEG powders are mixed together and applied to the tissues. To examine whether PEG sealant could replace fibrin glue as a hemostatic agent in raw surfaces and to determine its possible value in plastic surgery, we compared the subcutaneous behavior of both sealants in an experimental rabbit model.

## Materials and methods

### Animal model

Ten female New Zealand White rabbits from a single breed (Harlan, NL), with a mean weight of 3,990 g (range 3,650–4,300 g) were chosen for the experiments. All surgical procedures were completed in accordance with Swiss animal protection laws for the use of laboratory animals for research purposes.

### Surgical procedure

For each operation, the rabbits were premedicated with 65 mg/kg ketamine and 4 mg/kg xylazine i.m., before oral intubation and preoperative antibiotic prophylaxis with 0.8 ml/4 kg sulfonamide/trimetoprim. Anesthesia was maintained with isoflurane, with O<sub>2</sub> and N<sub>2</sub>O, under spontaneous breathing.

The surgical procedure was identical on both sides. On the dorsal thighs, the skin was shaved and a subcutaneous

2×2 cm pocket was created by an incision medial to the sciatic vein. No cauterization of bleeders was carried out. The pockets were randomly filled with 0.2 ml of either fibrin or polyethylene glycol sealants. Both sealants were pre-filled in ready-to-use syringes already fitted into a Duploject<sup>R</sup> system that enables their simultaneous mixing and application through a special nozzle. Before application, fibrin had to be thawed and warmed to room temperature, whereas PEG could be used immediately as it can be stored at room temperature. After application of the sealants, the incisions were closed in two layers, subcutaneously with polyglactin 910 5/0, and subcuticularly with nylon 5/0.

After the operation, the dorsal thighs were macroscopically inspected for hematoma, seroma, or granuloma. Eleven weeks later, the animals were killed and the fibrin and polyethylene glycol-filled pockets were harvested en bloc with the overlying skin, and processed for histological examination. The specimens were examined for the presence of scar tissue, fibrin, and inflammatory response. They were fixed in buffered formaldehyde (4%) and embedded in paraffin. From each paraffin block, 2- $\mu$ m-thick slides were cut and stained with hematoxylin and eosin, Elastica van Gieson and acid fuchsin-orange G. Elastica van Gieson stains for collagen and elastic fibers, both of which are the major components of scar tissue, while acid fuchsin-orange G is a specific stain for fibrin. The specimens were examined for the presence or absence of the two types of inflammation: chronic lymphohistiocytic and granulomatous.

Results were analyzed using SPSS 13.0 (SPSS, Chicago, IL). Nominal variables were summarized as % and were compared between the left and right hind leg by the Chi-square and the Fisher's exact test. A *p* value of  $\leq 0.05$  was considered significant.

## Results

On application, the gel formation for fibrin and PEG was comparably quick, taking place within a few seconds (<3 s). The wound healing was uneventful in all 20 thighs, and there was no hematoma formation, seroma formation, or skin necrosis in either group.

Due to the death of one rabbit before the final examination, and technical problems in the histological preparation of one specimen, there were ultimately eight specimens in the fibrin group and nine in the PEG group.

### Macroscopic examination

At the endpoint of the experiments, a swelling was visible at the experimental site in three thighs (38%) where fibrin

glue had been applied (Fig. 1). In contrast, there was no visible swelling or palpable tissue augmentation in any of the thighs where PEG had been applied.

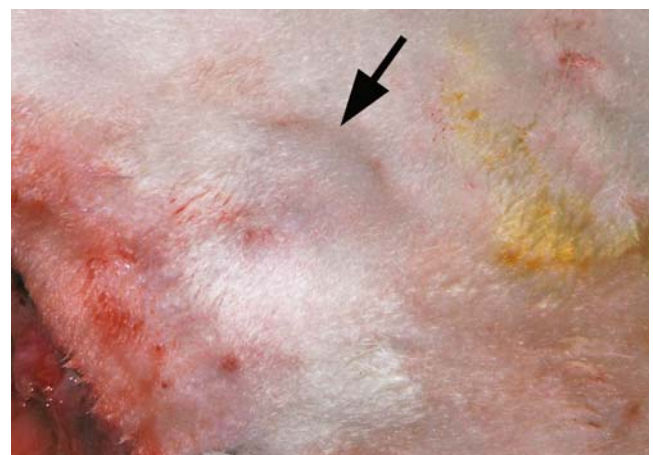
### Histologic examination

Two (25%) specimens in the fibrin group and five specimens in the PEG group (55%) showed no signs of inflammation (Fig. 2a). Signs of chronic lymphohistiocytic inflammation were seen in six specimens (75%) from the fibrin group and in four specimens (45%) from the PEG group (Fig. 2b). Granulomatous inflammations with epithelioid and giant cells were encountered five times (55%) in the fibrin group (Fig. 2c) and three times (33%) in the PEG group. Although more specimens in the PEG group showed no reaction and no signs of inflammation, the difference was not statistically significant. Remnants of fibrin were encountered in one case from the fibrin group and in two cases from the PEG group. In all three cases, the fibrin was intermingled with blood remnants; thus, it is likely that the fibrin was derived from the rabbits themselves.

## Discussion

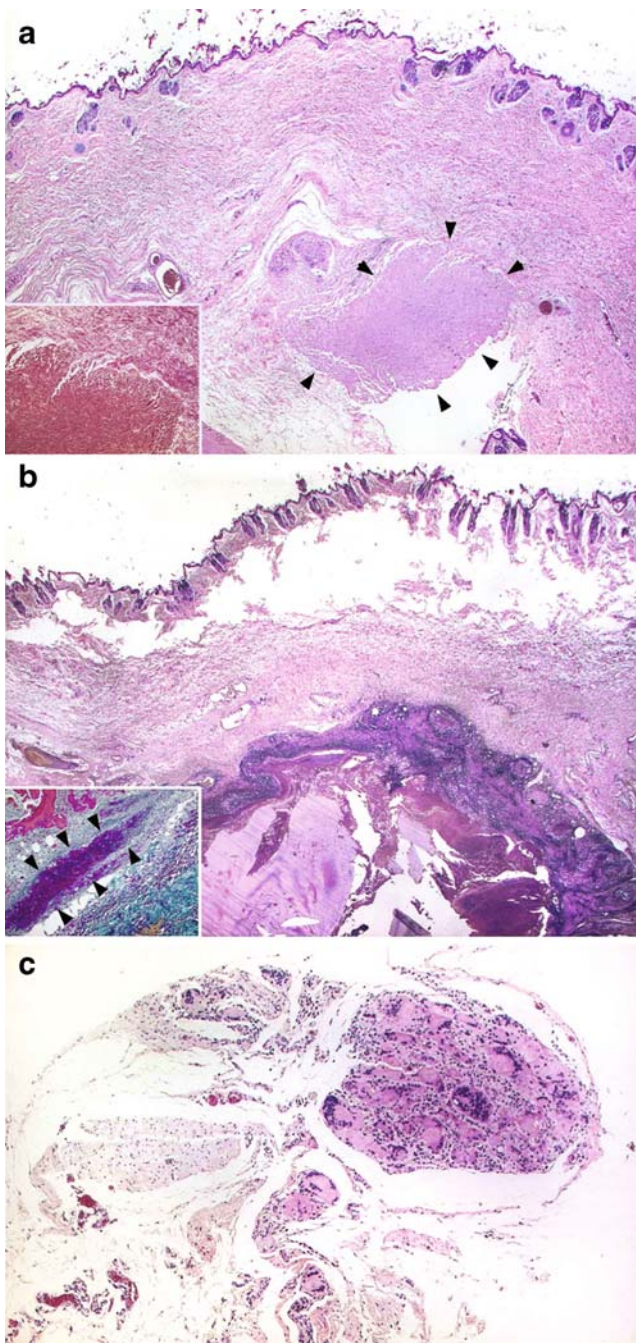
The results of the study showed that, 11 weeks after application of either fibrin or PEG sealant, 2/3 of the specimens in the fibrin group and in approximately 50% of the specimens in the PEG group showed signs of chronic or even granulomatous inflammation with epithelioid and giant cells. Only two specimens of the fibrin group and five specimens of the PEG group revealed no signs of inflammation at all.

Concerning fibrin glue, we saw similar results in experimental gluing of the peroneal nerves of New Zealand



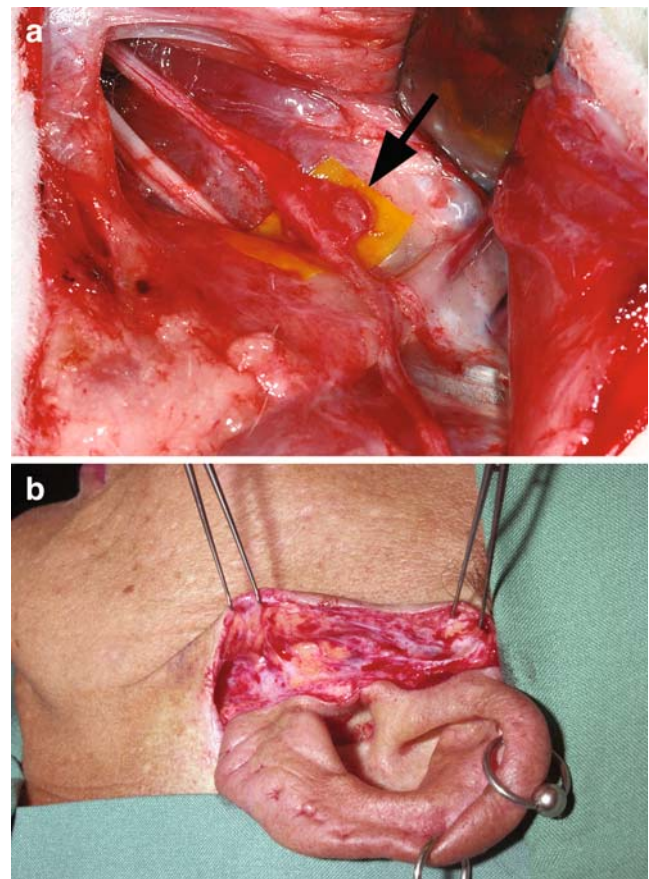
**Fig. 1** Macroscopic view of the dorsal thigh of a New Zealand White rabbit. Arrow indicates the bulging of the pocket 11 weeks after application of fibrin glue





**Fig. 2** **a** Overview of a specimen with PEG: subcutaneous pocket with (arrows) scar tissue (hematoxylin–eosin,  $\times 15$ ). Inset: in the magnification of the scar tissue no inflammatory reaction can be seen (Elastica van Gieson,  $\times 20$ ). **b** Overview of a specimen with fibrin remnants with chronic lympho-histiocytic reaction (hematoxylin–eosin,  $\times 15$ ). Inset: arrowheads show the reaction in detail (acid fuchsin-irange G,  $\times 40$ ). **c** Example of a specimen with fibrin shows scar tissue with granulomatous inflammation with giant cells (hematoxylin–eosin,  $\times 60$ )

White rabbits with the ready-to-use fibrin, resulting in a considerable swelling at the coaptation site 11 weeks after application (Fig. 3a). Histological examination showed chronic granulomatous inflammation with nerve-constricting scar tissue at the suture site.



**Fig. 3** Two examples of application of fibrin glue. **a** Nerve bonding with fibrin glue 11 weeks after application of fibrin glue at a peroneal nerve of a New Zealand white rabbit; there is a granulomatous inflammation at the previous transection site. **b** Face lift surgery with fibrin glue. Reopening the preauricular scar 1 year after the primary lifting shows a whitish laminar scar formation, which permits an easy, nearly bloodless dissection

At first glimpse, the long persistence of the ready-to-use fibrin glue seems to be in clear contrast to the reports on the presence of fibrin glue of other researchers. For example, Smahel et al. [1] used fibrin for gluing the sciatic nerve of rats at our clinic 20 years ago. They noticed that on the first postoperative day, there were large amounts of fibrin present in the gap at the periphery of the nerves. On the third postoperative day, little remained of the previously noted fibrin deposits on the glued nerves, and on the seventh postoperative day, no fibrin was present in the region of the junction site.

The main difference between our study and the study of Smahel et al. is the different concentration of aprotinin in the ready-to-use fibrin glue. While Smahel and others varied the aprotinin (and thrombin) concentration according to need and used a concentration of only 100 U/ml aprotinin for gluing nerves, in our study, the predetermined concentration of aprotinin in the ready-to-use fibrin was 3,000 KIU/ml. The thought of Smahel et al., that low concentrations of aprotinin must be used to prevent fibrosis

at the junction site of nerves, stems from the work of Matras and Kuderna [14, 15], who performed the most extensive research on the subject. Smahel et al. also composed the four components of fibrin glue themselves, and tested (by varying the aprotinin and thrombin concentrations) which concentrations of the single components gave the best results in regard to a short duration of resorption (by timing the fibrinolysis) and high strength of bond. Finally, Smahel et al. and others [16] had recommended a concentration of not more than 50 KIU/ml aprotinin in the fibrin glue to prevent fibrosis at the coaptation site of nerves and thereby hindrance of nerve regeneration while still guaranteeing sufficient bond strength.

With the introduction of the two pre-packed delivery forms of fibrin, many researchers decided to use them for the sake of convenience and accepted the concentrations that are provided in the kit and in the ready-to use syringes. However, it should be noted that the provided concentration of 3,000 KIU/ml of aprotinin is 60 times higher than what Kuderna et al. recommended for their nerve-bonding technique in humans. It is therefore not surprising that with such a high concentration of aprotinin many researchers had the same adverse experience after application of this kind of fibrin as we had. Moy [7], for example, compared the efficacy of fibrin glue to nylon sutures in primary peripheral microneurorrhaphy of the tibial nerve in adult New Zealand White rabbits. Even after 18 weeks, the fibrin seal group exhibited a fibrous thickening around each repair site. In the first postoperative week, the fibrin seal group also exhibited areas of increased cellularity composed of acute inflammatory cells. Moy reasoned that some of this inflammation may be related to the cross-species allogenic glue interaction with the recipient's biology, but he found that it appeared to resolve without serious sequelae. In his results, he explained the significantly decreased mean amplitude in the fibrin seal groups as indicative of a lag in axonal regeneration. Hamm [17], using the pre-packed fibrin glue, also noticed remnants of fibrin glue with inflammatory cells 4 weeks after gluing sciatic nerves in Albino Wistar rats, and a complete fibrotic hindrance of axon regeneration. In contrast, Wieken [18] and Narakas [19, 20] found no such hindrance of axon regeneration.

Still other studies have used different concentrations of aprotinin, thus confounding comparison of the results [21]. For example, Yin [22] injected fibrin glue with a concentration of 1,000 KIU/ml bovine lung aprotinin around a nerve repair site in the sciatic nerves of Sprague–Dawley rats, and observed in histologic sections that the fibrin that could be clearly visualized at 5 days could still be identified at 15 days, but was no longer present after 30 days. He made no comment as to fibrosis or inflammatory reactions. Becker [23] even used fibrin glue with a concentration of 20,000 KIU/ml aprotinin in comparing skeletal muscle

metabolism after repair of divided rat sciatic nerves with either microsurgical sutures or fibrin tissue adhesive, but made no special comment as to the remnants of fibrin glue after 60 or 150 days of application.

Face lift surgery is an application where a high concentration of aprotinin, and thus the long persistence of the fibrin glue, may turn out to be beneficial. In this application, we observed (Fig. 3b) that even 1 year after the primary lifting (even with the use of aerosolized fibrin glue), we still encountered clear traces of the fibrin application upon reopening the sutures. The remnants of fibrin glue, a whitish laminar scar formation, were more easily visible where a thicker layer of fibrin had been applied. As a result, a secondary dissection on the level of the fibrin glue was nearly bloodless, and the skin flaps withstood considerable traction as they acted as “preconditioned” flaps.

At a primary face lift, when thick layers of fibrin are applied, the fibrin glue obviously acts as a barrier to revascularization of the skin flaps and prevents normal capillary growth in a timely fashion, with the danger of impeding proper wound healing and ultimately causing localized areas of skin necrosis [5]. The thicker and more irregular the application of the fibrin glue is, the higher the likelihood of skin necrosis. Yet, when the skin survives, it becomes independent of the underlying tissues, thus permitting more skin resection at a second surgery without the danger of necrosis.

On the other hand, discussing the properties of PEG, Hagberg et al. [10] examined the effectiveness of PEG for managing anastomotic bleeding after implantation of Dacron grafts during aortic reconstruction for nonruptured aneurysms, and reported no adverse events related to the use of PEG and in comparison to Gelfoam/thrombin. PEG demonstrated significantly better ultimate sealing properties.

A study by Glickman [11] stated that PEG sealant inhibited anastomotic suture hole bleeding more rapidly than fibrin and demonstrated good biocompatibility. In another study by Cosgrove [12], who evaluated the safety and efficacy of PEG for watertight dural repair, he found no sealant-related adverse events. PEG provided an effective, watertight closure when used as an adjunct to sutured dural repair during cranial surgery.

All studies to date demonstrate that PEG is very effective as a hemostatic agent in sealing suture holes in vascular grafts, even in polytetraethylene (PTEE) grafts. It is well-known that sealing of PTEE grafts represents the greatest challenge due to leakage from holes created in the graft by needles during suturing. There were no adverse events related to PEG in the cited studies, supporting the overall benefit-to-risk ratio of PEG for use in sealing of vascular grafts.

In our study, comparing the properties of fibrin and PEG sealants, both led to chronic and even granulomatous



inflammation at the application site, even 11 weeks after application. Besides their comparable potential to induce inflammatory tissue reactions, PEG sealant possesses some notable advantages as it is purely synthetic and has no risk of transmission of viral pathogens or prions. PEG can also be stored at room temperature.

This safety profile, the ease of storage, and the reported consistently good hemostatic results obtained with PEG might make it an interesting alternative to fibrin glue in plastic surgery.

Although the small number of experimental animals and their thick skin makes this study purely preliminary, these promising results lend support to the completion of a larger study.

## References

- Smahel J, Meyer VE, Bachem U (1987) Glueing of peripheral nerves with fibrin: experimental studies. *J Reconstr Microsurg* 3(3):211–220
- Bruck HG (1982) Fibrin tissue adhesion and its use in rhytidectomy: a pilot study. *Aesthet Plast Surg* 6(4):197–202
- Baxt S (2001) Tissue glue. *Plast Reconstr Surg* 107(5):1311–1312
- Marchac D, Ascherman J, Arnaud E (1997) Fibrin glue fixation in forehead endoscopy: evaluation of our experience with 206 cases. *Plast Reconstr Surg* 100(3):704–712
- Fezza JP, Cartwright M, Mack W, Flaharty P (2002) The use of aerosolized fibrin glue in face-lift surgery. *Plast Reconstr Surg* 110(2):658–664
- Grossman JA, Capraro PA, Atagi T (2002) A prospective, randomized, double-blind trial of the use of fibrin sealant for face lifts. *Plast Reconstr Surg* 110(5):1371–1372
- Moy OJ, Peimer CA, Koniuch MP et al (1988) Fibrin seal adhesive versus nonabsorbable microsuture in peripheral nerve repair. *J Hand Surg (Am)* 13(2):273–278
- Rohrich RJ, Beran SJ (1997) Evolving fixation methods in endoscopically assisted forehead rejuvenation: controversies and rationale. *Plast Reconstr Surg* 100(6):1575–1582
- Mitsuhashi H, Horiguchi Y, Saitoh J et al (1994) An anaphylactic reaction to topical fibrin glue. *Anesthesiology* 81(4):1074–1077
- Hagberg RC, Safi HJ, Sabik J et al (2004) Improved intraoperative management of anastomotic bleeding during aortic reconstruction: results of a randomized controlled trial. *Am Surg* 70(4):307–311
- Glickman M, Gheissari A, Money S et al (2002) A polymeric sealant inhibits anastomotic suture hole bleeding more rapidly than gelfoam/thrombin: results of a randomized controlled trial. *Arch Surg* 137(3):326–331
- Cosgrove GR, Delashaw JB, Grotenhuis JA et al (2007) Safety and efficacy of a novel polyethylene glycol hydrogel sealant for watertight dural repair. *J Neurosurg* 106(1):52–58
- Buskens E, Meijboom MJ, Kooijman H et al (2006) The use of a surgical sealant (CoSeal) in cardiac and vascular reconstructive surgery: an economic analysis. *J Cardiovasc Surg (Torino)* 47(2):161–170
- Matras H, Mamoli B, Lassmann H (1976) Adhesion of nerve anastomoses using coagulation substances. *Fortschr Kiefer Gesichts-Chir* 20:112–114
- Kuderna H (1976) Clinical application of nerve-anastomoses adhesion using fibrinogen. *Fortschr Kiefer Gesichts-Chir* 21:135
- Boedts D (1987) A comparative experimental study on nerve repair. *Arch Otorhinolaryngol* 244(1):1–6
- Hamm KD, Steube D, Beer R et al (1987) Microsurgical suture and fibrin gluing of nerve anastomoses. Animal experiment study using Cohn I human plasma fraction. *Zentralbl Neurochir* 48(3):206–218
- Wieken K, Angioi-Duprez K, Lim A et al (2003) Nerve anastomosis with glue: comparative histologic study of fibrin and cyanoacrylate glue. *J Reconstr Microsurg* 19(1):17–20
- Narakas AO (1980) The surgical treatment of traumatic brachial plexus lesions. *Int Surg* 65(6):521–527
- Narakas AO (1988) The use of fibrin glue in repair of peripheral nerves. *Orthop Clin North Am* 19(1):187–199
- Medders G, Mattox DE, Lyles A (1989) Effects of fibrin glue on rat facial nerve regeneration. *Otolaryngol Head Neck Surg* 100(2):106–109
- Yin Q, Kemp GJ, Yu LG et al (2001) Neurotrophin-4 delivered by fibrin glue promotes peripheral nerve regeneration. *Muscle Nerve* 24(3):345–351
- Becker CM, Gueuning CO, Graff GL (1984) Sutures of fibrin glue for divided rat nerves. Schwann cell and muscle metabolism. *J Reconstr Microsurg* 1(2):139–145