

Christoforos Stoupis
Karin Ludwig
Daniel Inderbitzin
Dai-Do Do
Juergen Triller

Stent grafting of acute hepatic artery bleeding following pancreatic head resection

Received: 6 July 2005
Revised: 27 March 2006
Accepted: 18 April 2006
Published online: 24 August 2006
© Springer-Verlag 2006

C. Stoupis · K. Ludwig · J. Triller
Department of Diagnostic,
Interventional and Pediatric Radiology,
University of Berne, Inselspital,
CH-3010 Berne, Switzerland

D. Inderbitzin
Clinic for Visceral and Transplantation
Surgery,
University of Berne, Inselspital,
CH-3010 Berne, Switzerland

D.-D. Do
Clinic for Angiology,
University of Berne, Inselspital,
CH-3010 Berne, Switzerland

C. Stoupis (✉)
Radiology, Kreisspital,
CH-8708 Maennedorf, Switzerland
e-mail: c.stoupis@spitalmaennedorf.ch
Tel.: +41-44-9222007
Fax: +41-44-9222051

Abstract The purpose of this study was to report the potential of hepatic artery stent grafting in cases of acute hemorrhage of the gastroduodenal artery stump following pancreatic head resection. Five consecutive male patients were treated because of acute, life-threatening massive bleeding. Instead of re-operation, emergency angiography, with the potential of endovascular treatment, was performed. Because of bleeding from the hepatic artery, a stent graft (with the over-the-wire or monorail technique) was implanted to control the hemorrhage by preserving patency of the artery. The outcome was evaluated. In all cases, the hepatic artery stent grafting was successfully performed, and the bleeding was immediately stopped. Clinically, immediately after the procedure, there was an obvious improvement in the general patient condition. There were no immediate procedure-related com-

plications. Completion angiography (n=5) demonstrated control of the hemorrhage and patency of the hepatic artery and the stent graft. Although all patients recovered hemodynamically, three individuals died 2 to 10 days after the procedure. The remaining two patients survived, without the need for re-operation. Transluminal stent graft placement in the hepatic artery is a safe and technically feasible solution to control life-threatening bleeding of the gastroduodenal artery stump.

Keywords Endovascular stent graft · Emergency · Gastrointestinal tract hemorrhage · Hepatic artery · Pancreatic surgery · Complications · Interventional radiology

Introduction

Delayed arterial hemorrhage after pancreaticoduodenectomy is not a common, but a potentially fatal complication after the Whipple procedure [1–3]. In case of vascular complications after pancreatic head resection, the patient's clinical outcome is adversely affected [4]. Massive arterial bleeding occurs mainly as a result of a vascular erosion, potentially related to leakage of pancreatic exogenic secretion from the pancreatico-jejunal anastomosis.

According to the current literature [5], the recommended management of postoperative hemorrhage after pancreatic head resection tends to the endovascular approach with embolization of the bleeding artery [6, 7]. To our knowledge, there is only one case report published introducing a new approach to treat artery stump hemorrhage following the Whipple procedure, by means of transluminal covered stent graft placement [8], in order to achieve vascular repair retaining patency of the hepatic artery.

We therefore report our experience in five cases with massive hepatic arterial bleeding after pancreatic head

resection, demonstrating the potential of interventional radiology in the initial treatment of hemorrhage, instead of re-operation, using transluminal stent graft placement for emergency vessel repair.

Materials and methods

Patients

Between December 2001 and June 2004, five male individuals, 60, 50, 76, 61 and 67 years old, were referred from two different surgical clinics for emergency angiography because of unstable clinical hemodynamic conditions and abdominal pain. In all cases, there was a history of previous pancreatic head resection because of pancreatic disease (final diagnosis: $n=1$ T3N0 pancreatic head carcinoma, $n=3$ chronic pancreatitis and $n=1$ duodenal diverticulum) 3 to 5 weeks prior to the recent acute onset of symptoms, performed in two surgical clinics (see Table 1). Two patients with chronic pancreatitis underwent a duodenum-preserving pancreatic head resection, while the remaining individuals with suspected pancreatic carcinoma ($n=2$) and duodenal diverticulum ($n=1$) were operated on using the pylorus-preserving Whipple pancreatic head resection technique. The immediate postoperative course in all cases was unremarkable; there were no immediate postoperative complications noted, and three of the five patients had already been discharged from the hospital without any abdominal symptoms.

At the time of readmission ($n=3$ cases), respectively, in-hospital ($n=2$ cases) onset of abdominal symptoms, the five patients presented with an unstable clinical condition (heart rate higher than 90 beats per minute; blood pressure lower than 80/40 mmHg; hemoglobin lower than 6.5 mg%). Emergency contrast-enhanced computed tomography (CT) was initially performed in three individuals [helical CT in one; multidetector row (MD) CT in two patients]. CT findings were compatible with, or suspicious of, active bleeding (high attenuating fluid collection in a small bowel segment, compatible with blood, in one case and hemorrhagic ascites or peritoneal hematoma in the other cases). Immediate diagnostic angiography was performed by one of three experienced interventional radiologists, in the angiography suite, in order to identify the location of bleeding and evaluate the potential of endovascular treatment, according to the surgeon's request. Because of the emergency situation, coagulation parameters were not evaluated at this point.

Angiography and stent graft placement techniques

All procedures were performed under local anesthesia. Patients were monitored by ECG and blood pressure

measurements by the anesthesiology nurse, acting under the supervision of an anesthesiologist.

After the initial angiography of the abdominal aorta (retrograde femoral access for all patients), the celiac axis as well as the superior mesenteric artery, using a 5F cobra catheter (Cook, Bloomington, Mass), were selectively imaged (power injector; volume 40–60 ml; flow 4–6 ml/s). Both arterial and portal venous phases were assessed, firstly in order to detect the site of bleeding and secondly to exclude portal vein thrombosis. Further assessment of the superior mesenteric artery was not performed, since the bleeding site was evident. The anterior-posterior view of the selective angiography of the celiac axis demonstrated in all cases active bleeding from the hepatic artery, just at the site of the gastroduodenal artery stump. During the surgical procedure of pancreatic head resection, the proximal gastroduodenal artery is routinely double ligated and secured by the additional application of a vascular titanium clip.

In four cases, the extravasation of contrast agent occurred conspicuously into the peritoneal cavity, while in one case the extravasation took place into the Roux-en-Y jejunal bowel loop, placed around the pancreas after the duodenum-preserving pancreatic head resection.

In one case, thrombosis of the portal vein was evident, and in another, stenosis of the portal vein was detected (this stenosis was treated by means of dilatation after the graft placement), while in the remaining three cases, the portal vein was patent.

Two different transluminal stent placement techniques, using two types of stent graft, were performed:

- (1) Over-the-wire technique, using a Jostent graft ($n=2$ cases):

After the selective angiography, demonstrating in the first case active extravasation into the Roux-en-Y jejunal bowel loop (Fig. 1a,b), through the 5F cobra catheter and under fluoroscopic guidance, a 0.35-inch guide-wire (Terumo Cor., Tokyo, Japan) was passed through the area of the bleeding and placed into a distal branch of the right or the left hepatic artery. The femoral 5F introducer was then changed to a 8F Super-Arrow Flex sheath (Arrow Int. Inc, Reading, PA). Over the wire and using the coaxial technique, the Arrow sheath with a 4F Cobra (Terumo Cor., Tokyo, Japan) catheter inside (instead of the initial 5F catheter) was advanced through the celiac trunk into the site of the hepatic artery bleeding. The cobra catheter was then removed at that point.

In the first case, a 17-mm long covered Jostent graft (Abbott Lab, IL), dilatable to 4–9 mm, was crimped on a 4/40-mm 5F Fox balloon catheter (Abbott Lab, IL) and was advanced through the 8F Arrow sheath, placed distally to the site of extravasation. The sheath was then drawn back about 2 cm to allow the initial exposure of the stent graft (Fig. 1c). The device was

Table 1 Patient and procedure characteristics

Age	Underlying disease	Acute onset post-op	Imaging findings	Technique stent graft	Stent-graft size	Imaging follow-up	Clinical follow-up
50-year-old male	Chronic pancreatitis	18 days dpp	CT (helical): blood clot in the small bowel loop Angiography: active bleeding in the duodenal loop	Over-the-wire technique, Jostent graft, balloon expandable (Abbott Lab, IL)	4–9/17 mm	15 days, angiography	18 months clinical and laboratory findings normal
60-year-old male	Duodenal diverticulum	32 days pp Whipple	MDCT: thrombosis of portal vein, intraperitoneal hematoma Angiography: active intraperitoneal bleeding, portal vein thrombosis	Over-the-wire technique, Jostent graft, balloon expandable (Abbott Lab, IL)	4–9/17 mm	3 days, angiography	10 days exitus (abdominal sepsis)
61-year-old male	Pancreatic head-CaT ₃ N ₀	28 days pp Whipple	Angiography: active intraperitoneal bleeding	Monorail technique Symbiot, self-expandable (Boston Scientific Scimed Inc., Maple Grove, MN)	5/31 mm	1 day, angiography	2 days exitus (multiorgan failure)
76-year-old male	Chronic pancreatitis	16 days pp Whipple	Angiography: active intraperitoneal bleeding, portal vein stenosis	Monorail technique Symbiot, self-expandable (Boston Scientific Scimed Inc., Maple Grove, MN)	5/20 mm	1 day, angiography	7 days exitus (neuromyopathy, renal failure)
67-year-old male	Chronic pancreatitis	27 days dpp	MDCT (outside): diagnosis prospectively missed, retrospectively identified Angiography: active intraperitoneal bleeding	Monorail technique Symbiot, self-expandable (Boston Scientific Scimed Inc., Maple Grove, MN)	5/20 mm (two stents)	1 day, angiography	6 months clinical and laboratory findings normal

dpp: duodenum-preserving pancreatic head resection, pp Whipple: pylorus preserving Whipple pancreatic head resection, MDCT: multidetector row CT

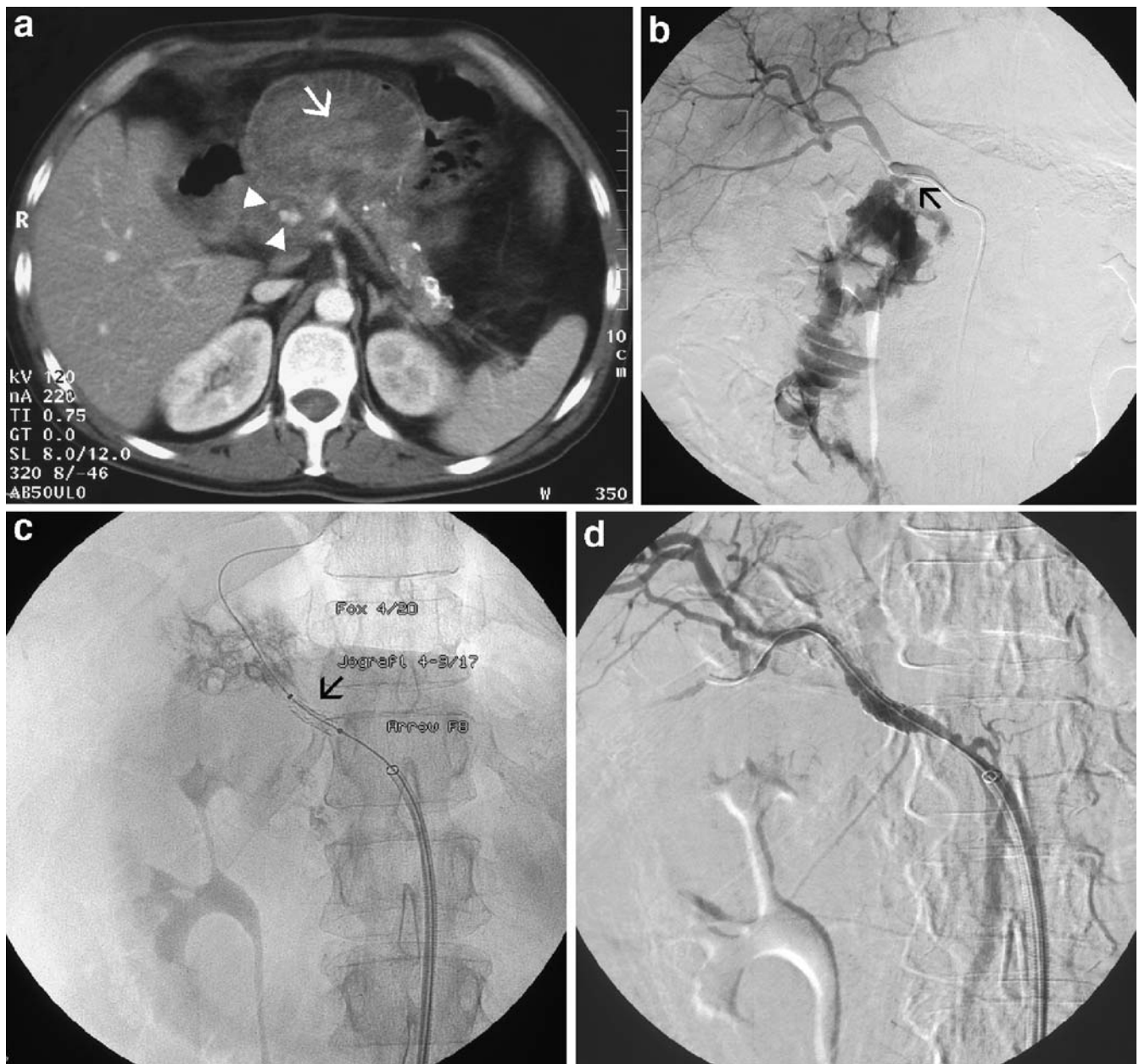

Fig. 1 A 50-year-old patient with suspected bleeding 18 days after duodenum-preserving pancreatic head resection. **a:** Contrast-enhanced CT of the upper abdomen demonstrates changes of chronic pancreatitis with foci of calcification in the pancreatic body and tail. Anterior to the pancreas there is a dilated loop of small bowel, filled with material of high attenuation (arrow), which was also seen on the non-enhanced scan (not shown), compatible with coagulated blood. In the anatomic area of the resected pancreatic head, contrast enhancing “spots” (arrowheads) are evident. **b:** Selective angiography of the common hepatic artery demonstrates massive contrast

agent extravasation in the anatomic area of the gastroduodenal artery marked by the titanium clip (arrow) with consecutive filling of the Roux-en-Y bowel loop, revealing the typical jejunal folds. **c:** Stent graft placement (Jostent graft) with the over-the-wire technique through an Arrow F8 sheath placed close to the arterial leak, in the hepatic artery. Note the 5F Fox 4/20 mm balloon catheter within the stent graft (arrow) for postdilatation. **d:** Completion angiography after Jostent graft placement demonstrates regular flow within the patent hepatic artery and its branches. No evidence of bleeding as compared to the initial angiography

then deployed by inflating the balloon to a pressure of 6 atmospheres. A 5/20-mm Fox balloon catheter was then used to postdilate the stent graft. The final angiography demonstrated control of the hemorrhage and stent graft patency (Fig. 1d).

A similar technique was used for the second patient. A 17/4–9 mm Jostent graft (Abbott Lab, IL) was crimped to a 4/20 mm 5F Fox balloon catheter (Abbott Lab, IL). After deployment, a 6/20 mm Fox balloon catheter was

used for post-dilatation. Completion angiography was performed for the same reasons as above.

(2) Monorail technique, using a self-expandable stent graft (n=3):

Similar to the procedure described previously, diagnostic angiography was performed, and the diagnosis of active bleeding from the hepatic artery was established (Fig. 2a). Afterwards, the tip of the Terumo 0.35-inch guide-wire was placed through the 5F cobra catheter into a distal branch of the right or left hepatic artery. In all cases, there was no need to exchange the Terumo wire with a stiffer one. However, instead of an Arrow Flex sheath, we used a 8F Mach1 guiding catheter (Boston Scientific Scimed Inc., Maple Grove, MN), with a 4F Cobra catheter inside (Terumo Cor., Tokyo, Japan), which was advanced over the Terumo guide-wire, and finally positioned at the site of the hepatic artery bleeding. The hydrophilic guide-wire was then substituted by a 0.014 Spartacore wire (Guidant Corporation, Santa Clara, CA), the end of which was placed similarly into an arterial branch of the right hepatic artery. Over the Spartacore wire, a Symbiot, self-expandable coronary stent graft (Boston Scientific Scimed Inc., Maple Grove, MN) was advanced to the bleeding site and deployed over the site of extravasation. (Fig. 2b). The size of the Symbiot stent graft was 5/31 mm for the first, 5/20 mm for the second and 5/20 mm for the third case. Similar to the previous cases, control angiography was performed to demonstrate patency of the hepatic artery and control of the bleeding site. In the last case, due to leakage at the site of stent graft placement, an extension with a second stent graft of 5/20 mm was performed. The final

angiography documented patency of the stent grafts and exclusion of the hemorrhage (Fig. 2c).

In all individuals, antibiotics were given to prevent infection (for both aerobic and non-aerobic bacteria). In addition, 100 mg per day of Aspirin Cardio (Bayer) and 75 mg per day of Plavix (Sanofi/Bristol-Meyers Squibb) were ordered as permanent medication in order to avoid thrombosis of the stent graft.

Definition of technical success

We considered the transluminal placement of the stent graft to be technically successful at the final completion selective angiography when: (1) the treated bleeding site was shown to be completely controlled and (2) the hepatic artery was patent, specifically in the area of the stent graft.

Follow-up angiography was performed from 1 day up to 15 days after the procedure in all cases, not only to rule out thrombosis of the stent graft or occlusion of the hepatic artery and its branches, but also to document the results of the transluminal approach to manage the bleeding as well. We considered the procedure to be clinically successful if immediately, and upon 1 h after the intervention, the patient was stable in terms of hemodynamic condition and 6 h after the procedure there was no need for a blood transfusion. For the further clinical follow-up, patient clinical condition and laboratory (liver function test) findings were documented at discharge or at the appointments at the outpatient clinic up to the recorded period time.

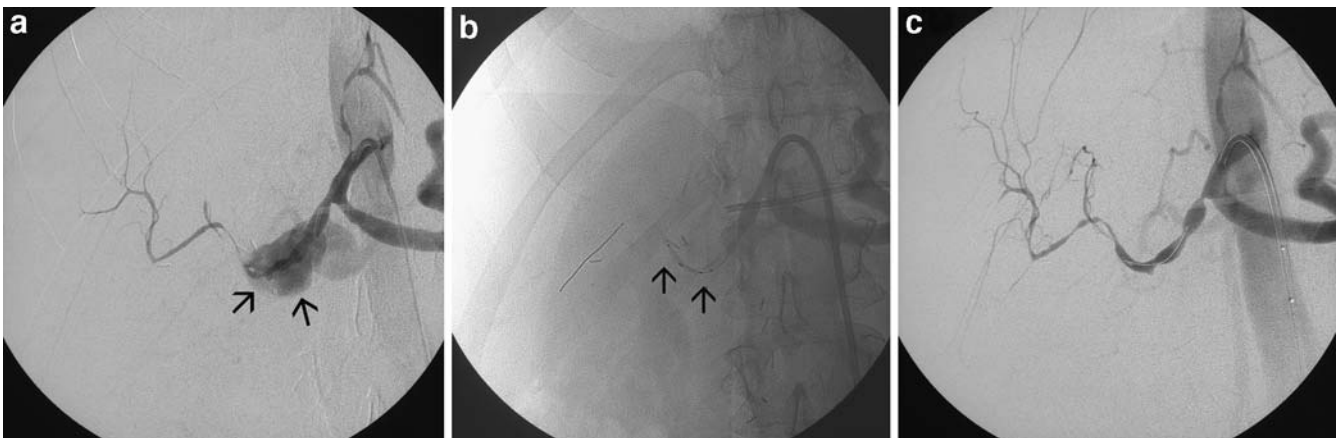


Fig. 2 A 61-year-old patient with suspected abdominal bleeding 28 days after pylorus-preserving Whipple pancreatic head resection. **a:** Angiography of the celiac trunk demonstrates active intraperitoneal bleeding at the area of the gastroduodenal artery stump (arrows). **b:** Monorail technique using the self-expandable Symbiot and the 8-F Mach-1 guiding catheter: the 5/20 mm stent graft,

guided by the 0.014 Spartacore wire placed in an arterial branch of the right hepatic artery, is deployed at the bleeding site of the hepatic artery. Note the radiopaque ends of the stent graft (arrows). **c:** After placement of the Symbiot stent graft, there is no more evidence of bleeding. Note the vascular spasm of the hepatic artery and its branches

Results

Success and outcome of intervention

Complete occlusion of the bleeding area using a stent graft was achieved in all patients. In all but one case, control of hemorrhage was successful using one stent graft; in the last patient, because of a tortuous artery and therefore an unfavorable location of the bleeding stump, two stents were placed coaxially to stop the extravasation completely.

The control angiography performed immediately after the transluminal stent graft placement demonstrated patency of the hepatic artery in all individuals. Similar results were seen at the follow-up angiography examination (n=5 cases) from 1 day up to 15 days after the interventional procedure.

There were no vascular adverse events during or after the procedure, such as dissection, thromboembolic occlusions or any vascular damage of the celiac axis or the hepatic artery and its branches. As expected, because of the intraarterial guide wire manipulation, there was a degree of vasospasm of the distal hepatic artery during and immediately after the procedure seen on the control angiography; this did not affect the outcome of the intervention and was not present at the follow-up angiographic examination.

The diagnostic angiography lasted 25–35 min, and the stent graft placement procedure took place within 35–55 min, while after the initial angiography, a consultation of the interventional radiologist with the referring surgeon and anesthesiologist, in order to discuss treatment options, lasted 15 to 20 min, with the time amount decreasing after the initial experience with the first patients.

None of the patients needed (clinical and according to follow-up angiography) further intervention after the initial successful occlusion of the bleeding site.

Clinical success

The patient's hemodynamic condition was stabilized 2 to 4 h following control of the hemorrhage. There were no clinical signs of abdominal pain (related to ischemia) 24 h after the procedure. No fever was noted. Laboratory findings (liver function tests), performed immediately and 1 day after the procedure, were within the normal range.

Follow-up

The first patient was followed up 15 days after the event by selective hepatic artery angiography, revealing no abnormality of the hepatic artery origin, demonstrating patency of the hepatic artery and the stent graft, as well as normal liver perfusion. Clinical and laboratory follow-up findings

18 months after the procedure were unremarkable, and the patient had no abdominal symptoms.

The second patient was followed up by means of angiography 3 days later due to new hemodynamic instability. Until that time, clinical and laboratory finding in this hospitalized patient demonstrated no obvious liver abnormality. At the time of angiography, the stent graft was patent; however, bleeding from the splenic artery was seen (the patient underwent pylorus-preserving Whipple pancreatic head resection), and the splenic artery hemorrhage was treated by means of microcoil embolization. The patient died 7 days later because of sepsis due to ischemia and bowel perforation.

The third patient died 2 days after the intervention because of multiorgan failure. There was no active bleeding seen at a follow-up angiography 24 h after stent graft placement, with a patent stent graft and hepatic artery. Due to intraperitoneal blood accumulation, after the initial hepatic artery hemorrhage, an abdominal compartment syndrome had developed. Re-operation, however, was not recommended by the surgeon at that time.

The fourth patient was followed up by means of angiography 1 day later, and the stent graft as well as the hepatic artery remained patent. Unfortunately, this older patient developed a critical illness neuropathy and a severe renal failure due to the initial hypovolemic shock, and hence 6 days after the stent graft placement, the patient died.

The fifth patient was followed up 1 day after the procedure by means of angiography, revealing a patent stent graft and hepatic artery, without any signs of bleeding. He was discharged from the hospital 8 days later; clinical and laboratory findings up to 6 months after the procedure were within the normal range. Further follow-up examinations are scheduled.

Discussion

Pancreatic head resection is a common surgical procedure in case of benign or malignant pancreatic head disease. Delayed complications after pancreatic head resection include intraabdominal or upper gastro-intestinal bleeding [1, 2, 4, 7]. Hemorrhage after pancreatic surgery occurs either due to vascular erosion related to leakage of pancreatic secretions at the site of the pancreatico-jejunal anastomosis or iatrogenic as an uncommon surgical complication after hepatic, biliary or pancreatic procedures [9]. Bleeding from the hepatic artery remains a fatal complication and, in case of previous extensive abdominal surgery, re-operation and a surgical approach to locate the origin of bleeding is not an easy procedure, specifically during this period of time after the initial operation in which the adhesions constitute a nightmare for the surgeon, since adhesiolysis is time consuming and hazardous. Moreover, because of the urgent situation in a hemody-

namically unstable patient, there may not be enough time for the surgeon to proceed to explorative laparotomy, thereby leading to an undesirable outcome for the patient [10]. Operative management of acute bleeding after pancreaticoduodenectomy is related with high mortality and morbidity, up to 90% [9, 10]; therefore, surgery is reserved for patients for whom embolization fails or for whom it is not feasible [9].

Embolization is one of the most effective techniques to treat visceral arterial bleeding, mainly due to pseudoaneurysms, but depending upon the site and location of the bleeding pseudoaneurysms, necrosis of the organ distal to the bleeding area may occur, thus with additional complications [11–13]. In our cases, embolization of the hepatic artery across the bleeding site (proximal and distal to the bleeding site) would have influenced the liver vascularization (specifically in those individuals with portal vein stenosis or thrombosis), and the purpose of percutaneous stent graft placement was to preserve patency of the vessel.

In the endovascular management of aneurysms, fistulas and other arterial injuries, a new approach has been introduced recently, based on the repair of the arterial wall and, therefore, the origin of bleeding, by implanting a stent graft covered with either prosthetic material or autogenous vein [13–15]. The use of endovascular exclusion of true or false aneurysms with a covered stent has been successfully utilized, as reported in cases of small-caliber peripheral and visceral arteries [16, 17]. To our knowledge, there is only one case reported in which a life-threatening hemorrhage of the gastroduodenal artery stump following pylorus-sparing Whipple procedure was successfully treated with a covered stent [8]. A similar case was reported demonstrating the potential of endovascular treatment with a coronary stent graft in a case of a right hepatic artery hemorrhage due to pseudoaneurysm [18].

In all our cases described above, the location for the bleeding was similar and typically located at the site of the gastroduodenal artery stump, which was identified during the angiography by means of the titanium clips, which are routinely placed by the surgeon during the operation to secure the arterial stump. For a potential endovascular hemorrhage treatment with superselective microcoil embolization, the situation in our cases was particularly complex: there was no obvious pseudoaneurysm sac to be filled up, and the shortness of the stump, perpendicular to the hepatic artery, did not allow a safe and permanent transcatheter embolization [13]. On the other hand, embolization of the hepatic artery itself, proximal and distal to the arterial leak, with a non-patent portal vein (portal vein stenosis in one, and portal vein thrombosis in another case), may influence the liver perfusion and have an undesirable effect for the patient.

In the first two cases, to treat the bleeding stump, we used a Jostent graft, crimped on a balloon catheter, as previously reported [8]; the advantage of this stent graft is

the option of treatment in vessels with diameters ranging from 4 to 12 mm. However, there is a need for a balloon catheter in order to crimp the stent graft on it; consequently, the introducer gains in diameter and that might have negative impact in case of small or peripheral vessels, with potential dissection of the arterial wall.

In the last three cases, a self-expandable stent graft was used for the endovascular repair, and in fact, these are the first cases describing this transluminal treatment technique in case of splanchnic arterial bleeding under emergency conditions. The advantage of Symbiot graft is that the introducer catheter can be placed in a central location, while, the securely mounted stent graft over a guidewire (0.014 inch in diameter) can then be easily advanced, even through tortuous vessels, at the bleeding site without fearing a dislocation of the stent graft. We changed our treatment technique, for obvious reasons. Practicality and time sparing are the main strengths of the monorail technique, enabling complete expansion of the stent graft in the desired position. No calibrating angiography was necessary; the size of the stent graft was estimated according to the size of the native vessel. In all our cases, we had to deal with a proximal arterial segment where the anatomical relationships had been changed due to previous surgery with pancreatic head resection and entero-enteric anastomosis.

The advantages of endovascular therapy in such an emergency situation are evident. Percutaneous treatment with a stent graft is a fast, feasible and efficient management technique and can be performed in the angiography suite by means of femoral puncture after the diagnostic angiography without any general anesthesia, as soon as possible. However, the procedure demands interventional experience. Regarding the duration of the whole procedure, the endovascular stent graft placement, requires an acceptably additional time period following the diagnostic angiography, which in any case is tolerated in this emergency, as opposed to any other surgical procedure.

The circumstances of massive intra-abdominal bleeding in cases where there has been previous abdominal surgery with major changes of the normal vessel anatomy will make the surgical approach to achieve hemostasis difficult, complex, time consuming and potentially perilous. The endovascular stent graft repair provides a good alternative option for satisfactory treatment, specifically in cases where embolization is not possible due to a lack of an arterial neck in case of a pseudoaneurysm or due to the location of the bleeding, such as in the case of gastroduodenal artery stump hemorrhage, as demonstrated in our patient population. Despite the very small number of patients, our results demonstrate a trend of lower mortality compared to the available data of operative interventions.

In case of a tortuous and small-caliber bleeding arterial segment, the self-expandable Symbiot graft placement with the monorail technique is recommended; the Jostent graft is

otherwise easy to place, using the over-the-wire technique in straight and centrally located bleeding vessels.

Potentially, over time, progressive occlusion of the stent graft due to intimal hyperplasia could be an issue; however, due to the gradual occlusion process, formation of collateral arterial circulation might be efficient to ensure liver perfusion without clinical symptoms. Infection of stent graft might be similar to the risk of coil infection, although there are no controlled data published in the current literature.

Although this endovascular procedure enables fast and efficient controlling of the bleeding in a hemodynamically unstable patient, for the optimization of the management strategy in case of life-threatening splanchnic arterial injury, long-term results and more clinical experience are needed. In the patients presented here, death occurred in

three individuals as a result of complications not directly related to the endovascular stent graft placement itself, but to hypovolemic shock and the following multiorgan failure. The urgent clinical situation of catastrophic bleeding was initially rescued on time, as opposed to surgical intervention. Reduction of the time delay between the initial clinical suspicion of massive bleeding and the following emergency angiography, resulting in the endovascular stent graft repair, probably improves morbidity and, specifically, mortality.

In summary, in case of life-threatening hemorrhagic complications, after pancreatic head surgery, percutaneous PTFE-covered stent placement at the site of arterial leak is a solution to be considered, demonstrating the role of endovascular treatment to minimize morbidity and mortality and avoiding inadvisable re-operation.

References

- Miedema BW, Sarr MG, van Heerden JA, Nagorney DM, McIlrath DC, Ilstrup D (1992) Complications following pancreaticoduodenectomy. Current management. *Arch Surg* 127 (8):945–949, Aug, discussion 949–950
- Hoshal VL Jr, Benedict MB, David LR, Kulick J (2004) Personal experience with the Whipple operation: outcomes and lessons learned. *Am Surg* 70 (2):121–125, Feb, discussion 126
- Santoro R, Carlini M, Carboni F, Nicolas C, Santoro E (2003) Delayed massive arterial hemorrhage after pancreaticoduodenectomy for cancer. Management of a life-threatening complication. *Hepatogastroenterology* 50(54):2199–2204, Nov-Dec
- Kim AW, McCarthy WJ 3rd, Maxhimer JB, Quiros RM, Hollinger EF, Doolas A, Millikan KW, Deziel DJ, Godellas CV, Prinz RA (2002) Vascular complications associated with pancreaticoduodenectomy adversely affect clinical outcome. *Surgery* 132(4):738–744, Oct, discussion 744–747
- Yoon YS, Kim SW, Her KH, Park YC, Ahn YJ, Jang JY, Park SJ, Suh KS, Han JK, Lee KU, Park YH (2003) Management of postoperative hemorrhage after pancreatoduodenectomy. *Hepatogastroenterology* 50(54):2208–2212, Nov-Dec
- Otah E, Cushin BJ, Rozenblit GN, Neff R, Otah KE, Cooperman AM (2002) Visceral artery pseudoaneurysms following pancreatoduodenectomy. *Arch Surg* 137(1):55–59, Jan
- Sohn TA, Yeo CJ, Cameron JL, Geschwind JF, Mitchell SE, Venbrux AC, Lillemoe KD (2003) Pancreaticoduodenectomy: role of interventional radiologists in managing patients and complications. *J Gastrointest Surg* 7 (2):209–219, Feb
- Mansueto G, D’Onofrio M, Iacono C, Rozzanigo U, Serio G, Procacci C (2002) Gastroduodenal artery stump haemorrhage following pylorus-sparing Whipple procedure: treatment with covered stents. *Dig Surg* 19(3):237–240
- Tessier DJ, Fowl RJ, Stone WM, McKusick MA, Abbas MA, Sarr MG, Nagorney DM, Cherry KJ, Gloviczki P (2003) Iatrogenic hepatic artery pseudoaneurysms: an uncommon complication after hepatic, biliary, and pancreatic procedures. *Ann Vasc Surg* 17(6):663–669, Nov, Epub 2003 Oct 23
- Bassi C, Falconi M, Salvia R, Mascetta G, Molinari E, Pederzoli P (2001) Management of complications after pancreaticoduodenectomy in a high volume centre: results on 150 consecutive patients. *Dig Surg* 18:453–458
- Okuno A, Miyazaki M, Ito H, Ambiru S, Yoshidome H, Shimizu H, Nakagawa K, Shimizu Y, Nukui Y, Nakajima N (2001) Nonsurgical management of ruptured pseudoaneurysm in patients with hepatobiliary pancreatic diseases. *Am J Gastroenterol* 96(4):1067–1071, Apr
- Bottger TC, Junginger T (1999) Factors influencing morbidity and mortality after pancreaticoduodenectomy: critical analysis of 221 resections. *World J Surg* 23(2):164–171, Feb, discussion 171–172
- Reber PU, Baer HU, Patel AG, Triller J, Buchler MW (1998) Life-threatening upper gastrointestinal tract bleeding caused by ruptured extrahepatic pseudoaneurysm after pancreatoduodenectomy. *Surgery* 124(1):114–115, Jul
- Rundback JH, Rizvi A, Rozenblit GN, Poplasky M, Maddineni S, Crea G, Agrawal U, Olson C, Matalon TA (2000) Percutaneous stent-graft management of renal artery aneurysms. *J Vasc Interv Radiol* 11(9):1189–1193, Oct
- Rocek M, Peregrin JH, Dutka J, Ryska M, Belina F, Lastovckova J (2002) Percutaneous treatment of a superior mesenteric artery pseudoaneurysm using a stent-graft. *AJR Am J Roentgenol* 178(6):1459–1461, Jun
- Larson RA, Solomon J, Carpenter JP (2002) Stent graft repair of visceral artery aneurysms. *J Vasc Surg* 36 (6):1260–1263, Dec
- Cowan S, Kahn MB, Bonn J, Becker GJ, Dimuzio P, Leichter R, Carabasi RA (2002) Superior mesenteric artery pseudoaneurysm successfully treated with polytetrafluoroethylene covered stent. *J Vasc Surg* 35(4):805–807, Apr
- Venturini M, Angeli E, Salvioni M, De Cobelli F, Trentin C, Carlucci M, Staudacher C, Del Maschio A (2002) Hemorrhage from a right hepatic artery pseudoaneurysm: endovascular treatment with a coronary stent-graft. *J Endovasc Ther* 9(2):221–224, Apr