

F.H. Hetzer • D. Hahnloser • Y. Knoblauch • F. Löhlein • N. Demartines

New screening technique for sacral nerve stimulation under local anaesthesia

Received: 30 July 2004 / Accepted: 23 November 2004

Abstract Background The purpose of this study was to assess the influence of the type of anaesthesia (local vs. general) and of the electrode used (test electrode vs. tined lead) on a successful screening period. **Methods** Between May 2001 and January 2004, we performed 25 percutaneous nerve evaluation (PNE) tests in 20 patients (11 women). The first 15 PNE tests were followed by introducing a conventional electrode, and since 2003 by a tined lead electrode. Success was defined as reduction of symptoms by more than 50%. **Results** A stimulator was implanted in 13 (68%) patients, including 4 of 14 screened with the conventional electrode and 9 of 10 screened with tined lead electrode ($p=0.005$). Eleven (44%) of the PNE tests were done under local anaesthesia, but the success rate was not influenced by the type of anaesthesia (local 46% vs. general 61%, $p=0.682$). **Conclusions** PNE testing and implantation of the tined lead electrode can be easily

performed at the same time under local anaesthesia. The use of the new tined lead electrode significantly increased the success rate for the screening phase.

Key words Faecal incontinence • Sacral nerve stimulation • Minimally invasive sacral neuromodulation • Tined lead electrode

Introduction

Sacral nerve stimulation (SNS) is an amazing therapy option for patients with urinary and bowel dysfunction [1–6]. The procedure involves three stages. The first step is a percutaneous nerve evaluation with a foramen needle. If a contraction of the pelvic floor can be observed, the second step consists of introducing a test electrode and an external pulse generator for a screening phase of 10–14 days. In patients with a positive response (symptoms decrease of more than 50% measured by a continence diary), the third step replaces the test electrode with a permanent electrode, and a definitive implantation of the “internal pulse generator” (IPG) can be performed [1, 7].

However, the technique of SNS for the treatment of faecal incontinence is not standardised yet. Due to a high migration rate of test electrodes and due to the invasiveness of open implantation of the permanent system [8], Spinelli et al. [9], and the manufacture of the stimulator (Medtronic, Minneapolis, USA) recently developed a transcutaneous electrode (tined lead electrode) and a minimally invasive introducing kit. The new transcutaneous system is designed as a permanent electrode and can be used for both screening and permanent stimulation. It is supposed to improve the success rate of screening by decreasing the risk of electrode migration. In addition, implantation of the new tined lead electrode can be performed under local anaesthesia. Thereafter, the patient can feel and localise the stimulation

F.H. Hetzer • D. Hahnloser • Y. Knoblauch
F. Löhlein • N. Demartines (✉)
Clinic for Visceral and Transplantation Surgery
University Hospital
Ramistr. 100, 8091 Zurich, Switzerland
E-mail: nicolas.demartines@usz.ch

during the procedure, thus increasing the accuracy of sacral stimulation, which eases the procedure.

Today, most centres favour a combination of percutaneous nerve evaluation with primary implantation of test electrodes. After successful screening, those test electrodes have to be replaced by permanent electrode (two step procedure). The permanent implantation is performed through a presacral incision under general anaesthesia.

The aims of this study were to assess the influence of the type of electrode used (conventional test electrode vs. new tined lead electrode) and the type of anaesthesia (local anaesthesia vs. general anaesthesia) on success of the SNS screening test.

Patients and methods

Between May 2001 and January 2004, we performed 25 percutaneous nerve evaluation tests in 20 patients (11 women) with faecal incontinence of median age 63 years (range, 33–86). The aetiology of incontinence was idiopathic in 5 patients, obstetrical injury ($n=4$), after low anterior rectum resection ($n=3$), residual Guillain-Barré polyneuritis ($n=2$), and in 1 case each after repair of complete external rectal prolapse, multiple sclerosis, spinal trauma, anal atresia, radiochemotherapy for anal carcinoma and subsequent to haemorrhoidectomy. These patients remained faecally incontinent despite of medical treatment and biofeedback therapy. All patients had persisting symptoms within the last 12 months.

Evaluation tests gave a positive response in 24 of 25 cases, and were followed by a screening phase. For the screening, a conventional test electrode was implanted 14 times, and since January 2003 the new tined lead electrode used for 10 screenings. Fifteen interventions were done as day-case procedure (<12 hours hospital stay) and 10 patients were hospitalised overnight (<36 hours hospital stay).

There was no significant difference in type and severity of incontinence for the two types of electrodes used in the evaluation test. Patients with conventional test electrode had a median Wexner score of 13.5 (range, 8–16) and those with tined lead 15 (range, 6–20); $p=0.553$. All patients received single dose antibiotics preoperatively (1000 mg cefazolin and 500 mg metronidazole intravenously). Wexner score and a daily diary were used to assess continence preoperatively, during the screening phase (10–14 days) and up to one month after implantation of the permanent system. All patients underwent a thorough clinical investigation, including colonoscopy, anal endosonography and anorectal physiology. The results of the preoperative anal manometry and rectal

sensation tests are shown in Table 1. Success was defined as a reduction in the number of incontinence episodes or days and, for the urge incontinence group, as a decrease of voiding frequency by more than 50% during the screening phase.

Surgical technique

Percutaneous nerve evaluation was performed with the patient in prone position using an insulated foramen needle (model 141828; Medtronic, Minneapolis, USA) in all patients. The procedure was done either under local or general anaesthesia without any curarization to assess the responses to electrostimulation. The best response of S₃ to S₄ was tested on both sides.

Immediately after the observation of pelvic floor contraction, a temporary conventional test electrode (model 30576SC; Medtronic) or a new tined lead (model 3889, Medtronic) (Fig. 1) was inserted. The conventional electrode was fixed at the skin level and connected through the extension (model 41827, Medtronic) to the external impulse generator (Screener model 3625, Medtronic). A neutral electrode (model 41826, Medtronic) usually placed on the abdomen skin was necessary for this setting. The tined lead electrode was introduced in Seldinger technique over a guide wire through an introducer and the exact position of the electrode tip was checked by laterolateral pelvic fluoroscopy. In case of positive response, the proximal part of the tined lead electrode (Fig. 1) and the extension (model 3550–05, Medtronic) were tunnelled and connected to a screening cable (model 3550–03, Medtronic) and to the external pulse generator.

The stimulation parameters were identical for patients in both groups: pulse width, 210 μ s; frequency, 15 Hz; amplitude adaptable by the patients (limited range, 0–10 V).

Permanent implantation took place immediately after the screening period. At the beginning of the study, the conventional test electrode had to be removed and in the same place the permanent electrode (model 3080, Medtronic) was implanted in an open way and sutured to the fascia of the sacrum in 5 patients [10, 11]. The internal stimulator IPG (InterStim model 3023, Medtronic) was placed in a subcutaneous pocket made on the opposite gluteal region of the implanted electrode and connected to the electrode. In patients who had a successful screening with the tined lead electrode, the transcutaneous screening cable was removed and the stimulator IPG was directly connected in the same manner.

Results were documented by their median values as well their minima and maxima. Statistical analysis for the type of electrodes was performed with the Mann-Whitney test. To compare the pre- and postoperative incontinence scores, Wilcoxon's paired rank sum test was used.

Table 1 Results of preoperative anal manometry and rectal sensation in 19 screened patients with faecal incontinence. Values are median (range)

	Conventional test electrode	Tined lead electrode	<i>p</i>
Resting pressure (normal, >40 mmHg)	30 (12–60)	38 (10–50)	0.877
Squeeze pressure increment (normal, >50 mmHg)	35 (0–100)	40 (20–50)	0.756
Threshold volume (normal, <30 ml air)	35 (30–200)	28 (15–30)	0.023
Urge volume (normal, 150 \pm 20 ml air)	90 (50–120)	55 (30–70)	0.086
Maximum tolerated volume (normal, 150 \pm 20 ml air)	125 (60–170)	125 (60–180)	0.864

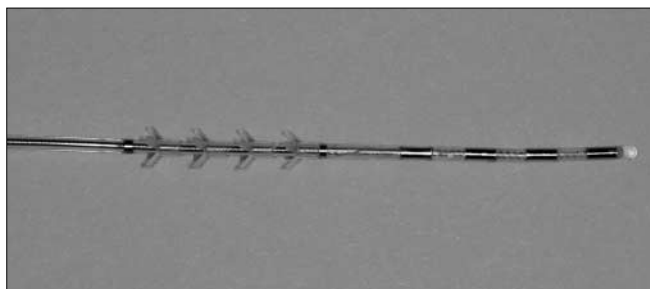


Fig. 1 Tined lead (model 3889, Medtronic) with four electrodes (0–3) at the distal part, followed by four rings of small anchors to fix the system in the sacral foramen

Results

A total of 24 screening electrodes were placed in 19 patients depending on the best pelvic floor response observed intraoperatively. The conventional electrode was introduced in the sacral foramen S₃ in 13 and in S₄ in 2 evaluations tests; the tined lead electrode was placed in S₃ in 7 cases and in S₄ in 2 cases. In one case of spinal trauma with neurological faecal incontinence, the percutaneous nerve evaluation did not induce any pelvic floor contraction and the screening phase was cancelled. Types of implanted electrodes and results of the screening are summarised in Table 2.

Nine patients had a primary successful screening result and 3 needed a second screening period before permanent stimulator was implanted. In one patient, a third screening was performed 12 months after insufficient unilateral permanent stimulation. This third screening was performed with a tined lead electrode and a bilateral twin stimulator was then implanted.

Dislocation of the electrode during the screening period was responsible for 7 screening failures (50%) in the conventional electrode group and for one failure (10%) in the tined lead electrode group ($p=0.79$). Four of 14 screenings with conventional test electrode and 9 of 10 screenings with tined lead electrodes received permanent stimulation ($p=0.005$). Overall the permanent stimulator was implanted in 13 of 19 patients (68%), with a median follow-up of 13 months (range, 5–33 months). Infection of electrodes did not occur in either group. One patient required a surgical revision of the IPG pocket due to a seroma.

Of all percutaneous nerve evaluation and screening procedures, 11 (44%) were done under local anaesthesia. All were subjectively and objectively well tolerated (no additional analgesia was necessary). Success of the percutaneous nerve evaluation test and success of definitive implantation were not influenced by the type of anaesthesia (local 46% vs. general 61%, respectively; $p=0.682$).

For all but five patients, the number of episodes of faecal incontinence per week decreased from a median of 6 (range, 0–31) to 2 (range, 0–8) ($p=0.009$) during screening phase. The ability to defer defecation improved in all but one patient in whom it remained unchanged. The median number of urgency episodes per week decreased from 9 (range, 2–96) to 4 (range, 0–28) ($p=0.005$).

The evaluation one month after the permanent implantation showed an improvement of continence in that all thirteen patients. The median Wexner score decreased from 14 (range, 6–20) preoperatively to 4 (range, 0–12); $p<0.001$.

Discussion

Early reports on spinal cord electrostimulation showed influence on bowel function in patients with severe constipation [12]. Sacral nerve stimulation was first used in patients with urinary bladder dysfunction [13] and later, on with a high success rate, in patients with faecal incontinence [14–16]. The minimally invasive two-step procedure of sacral nerve stimulation with percutaneous nerve evaluation, together with placement of the percutaneous lead, was performed at our institution without any complications. The use of the new tined lead significantly increased the technical success rate of screening tests from 30% to 90% ($p=0.005$). Similar results are reported for SNS in bladder dysfunction with improved success rates from 40% to 80% [9, 17, 18]. However, the learning curve and better patient selection may have also increased the implantation rate.

Our results showed a high migration rate for the conventional electrode compared to the tined lead. There are two main differences in the compared electrodes, which may explain the results. First, the conventional test wire is too thin and too flexible for keeping its position. It can easily move and dislodge in the sacral foramen. Secondly, the anchoring mechanism of the new tined lead proximal to the electrodes, is an integral part of the

Table 2 Results of screening tests and permanent stimulation grouped by type of screening electrode

Electrode	Electrode dislocations, n of screenings	Screening phase positive	Permanent implantation, n of patients
Conventional	7 of 14 (50%)	4 of 14 (29%)	4
Tined lead	1 of 10 (10%)	9 of 10 (90%)	9

lead body, inhibits axial movements of the lead more effectively than with the conventional electrode, which is normally fixed by a simple suture only at skin level.

The new tined lead electrode improves patient comfort during the screening period, as no neutral electrode is necessary. Moreover, the new implantation set decreased the electrode dislocation rate from 50% with the conventional test to 10% with the new electrode, $p=0.79$. As the new electrode is designed for both screening and permanent stimulation, an electrode change is no longer necessary at the time of the implantation of the internal stimulator. If the results of screening are positive, the lead is already in the precise place where positive results were obtained. This avoids false-negative screening tests and other failures after permanent implantation.

Another major advantage of the new set is the percutaneous implantation under local anaesthesia. The use of local anaesthesia allows the patients to report sensitive responses during implantation and helps to place the electrode at the best possible stimulation place. In addition to visualisation of pelvic floor contraction, patients under local anaesthesia were able to tell us intraoperatively if the response was symmetric and if additional, disturbing sensations in the legs or toes were present or not. However, we could not show any statistical benefit in this small patient number, as there were no differences in the screening success rates comparing local and general anaesthesia. Despite this, our experience with awake patients was very convincing.

The new electrode is more expensive than the conventional one (1600,00 Euro vs. 130,00 Euro, respectively) and the cost of an unsuccessful screening may be significantly higher. Moreover, pelvic fluoroscopy is necessary. On the other hand, local anaesthesia and a significantly higher success rate decrease the overall cost.

In conclusion, the use of the new tined lead electrode designed as permanent electrode allows an optimal screening with significantly less electrode dislocation. Moreover, a full implantation under local anaesthesia with patient guidance is a great advantage. The presented two-stage procedure under local anaesthesia with the new electrode should be recommended as standard procedure for SNS, provided an accurate patient selection is performed.

References

1. Matzel KE, Stadelmaier U, Hohenfellner M, Gall FP (1995) Permanent electrostimulation of sacral spinal nerves with an implantable neurostimulator in treatment of fecal incontinence. *Chirurg* 66:813–817
2. Malouf AJ, Vaizey CJ, Nicholls RJ, Kamm MA (2000) Permanent sacral nerve stimulation for fecal incontinence. *Ann Surg* 232:143–148
3. Leroi AM, Michot F, Grise P, Denis P (2001) Effect of sacral nerve stimulation in patients with fecal and urinary incontinence. *Dis Colon Rectum* 44:779–789
4. Ganio E, Realis Luc A, Clerico G, Trompetto M (2001) Sacral nerve stimulation for treatment of fecal incontinence: a novel approach for intractable fecal incontinence. *Dis Colon Rectum* 44:619–629; discussion 629–631
5. Varma JS, Binnie N, Smith AN et al (1986) Differential effects of sacral anterior root stimulation on anal sphincter and colorectal motility in spinally injured man. *Br J Surg* 73:478–482
6. Tanagho EA, Schmidt RA (1982) Bladder pacemaker: scientific basis and clinical future. *Urology* 20:614–619
7. Matzel KE, Stadelmaier U, Bittorf B et al (2002) Bilateral sacral spinal nerve stimulation for fecal incontinence after low anterior resection. *Int J Colorectal Dis* 17:430–434
8. Janknegt RA, Weil EH, Eerdmans PH (1997) Improving neuromodulation technique for refractory voiding dysfunctions: two-stage implant. *Urology* 49:358–362
9. Spinelli M, Giardiello G, Gerber M et al (2003) New sacral neuromodulation lead for percutaneous implantation using local anesthesia: description and first experience. *J Urol* 170:1905–1907
10. Chai TC, Mamo GJ (2001) Modified techniques of S3 foramen localization and lead implantation in S3 neuromodulation. *Urology* 58:786–790
11. Spinelli M, Giardiello G, Arduini A, van den Hombergh U (2003) New percutaneous technique of sacral nerve stimulation has high initial success rate: preliminary results. *Eur Urol* 43:70–74
12. Pescatori M, Meglio M, Cioni B, Colagrande C (1982) Colonic motility in two constipated neurological patients treated by spinal cord stimulation. In: Wienbeck M (ed) *Motility of the digestive tract*. Raven Press, New York, pp 541–547
13. Tanagho EA (1993) Sacral root stimulation. *Neurourol Urodyn* 12:505
14. Uludag O, Koch SM, van Gemert WG et al (2004) Sacral neuromodulation in patients with fecal incontinence: a single-center study. *Dis Colon Rectum* 47:1350–1357
15. Jarrett ME, Mowatt G, Glazener CM et al (2004) Systematic review of sacral nerve stimulation for faecal incontinence and constipation. *Br J Surg* 91:1559–1569
16. Rasmussen OO, Buntzen S, Sorensen M et al (2004) Sacral nerve stimulation in fecal incontinence. *Dis Colon Rectum* 47:1158–1162
17. Scheepens WA, Van Koevinge GA, De Bie RA et al (2002) Long-term efficacy and safety results of the two-stage implantation technique in sacral neuromodulation. *BJU Int* 90:840–845
18. Everaert K, Plancke H, Lefevre F, Oosterlinck W (1997) The urodynamic evaluation of neuromodulation in patients with voiding dysfunction. *Br J Urol* 79:702–707