

Case Report

Anterior Cervical Osteophytes Causing Dysphagia and Dyspnea: An Uncommon Entity Revisited

Roland Giger, MD,^{1,3} Pavel Dulguerov, MD,¹ and Michael Payer, MD²

¹Department of Otorhinolaryngology and Head & Neck Surgery, University Hospital of Geneva, Geneva, Switzerland; and ²Department of Neurosurgery, University Hospital of Geneva, Geneva, Switzerland

Abstract. Large anterior cervical osteophytes can occur in degeneration of the cervical spine or in diffuse idiopathic skeletal hyperostosis (DISH). We present the case of an 83-year-old patient with progressive dysphagia and acute dyspnea, necessitating emergency tracheotomy. Voluminous anterior cervical osteophytes extending from C3 to C7 and narrowing the pharyngoesophageal segment by external compression and bilateral vocal fold immobility were diagnosed radiologically and by fiberoptic laryngoscopy. Surgical removal of all osteophytes led to the resolution of symptoms. Dyspnea with or without dysphagia caused by hypertrophic anterior cervical osteophytes is an uncommon entity. The exhaustive diagnostic workup proposed in the literature could be simplified by using fiberoptic laryngoscopy and dynamic videofluoroscopy. The causes, treatment, and outcome are discussed.

Key words: Anterior cervical osteophytes — Dyspnea — Dysphagia — Deglutition — Deglutition disorders.

Hypertrophic anterior cervical osteophytes (HACO) occur in degenerative disc disease, as part of the physiologic or accelerated aging process, or in diffuse idiopathic skeletal hyperostosis (DISH), also known as Forestier's disease [1, 2]. Voluminous HACO can

compress the pharyngoesophageal and the laryngo-tracheal segments causing dysphagia. The incidence of dysphagia in patients with HACO or DISH ranged from 0.2% to 28% [1, 3, 4]. Dyspnea caused by HACO is less common. In a Medline search of the literature, only 27 publications describing 37 patients suffering from DISH (28 cases) or HACO (9 cases) complicated by dyspnea were found [2, 5–30]. A male-to-female ratio of 4:1 was reported with the most frequently involved segments, in 23% of all cases, being C3/C4, C4/C5, and C5/C6.

We report on one patient with large HACO that caused chronic dysphagia and sudden and severe dyspnea necessitating an emergency tracheotomy. The literature on HACO causing dyspnea with and without dysphagia is reviewed. Possible causes for swallowing and airway deterioration, the treatment, and the outcome are discussed. A simplified and more direct diagnostic workup is presented.

Case Report

An 83-year-old male complained of progressive dysphagia for three months. Sudden and severe dyspnea, associated with life-threatening bronchoaspiration, required an emergency tracheotomy. Fiberoptic laryngoscopy examination revealed a retropharyngeal mass bulging from the posterior hypopharyngeal wall, bilateral vocal fold immobility in an intermediate position, and pooling of saliva in both pyriform sinuses. A cervical computed tomography (CT) scan demonstrated large HACO from C3 to C7 and showed compression of the hypopharynx with anterior displacement of the esophagus and larynx. Dynamic videofluoroscopy confirmed large HACO that displaced the pharyngeal lumen anteriorly and directed 90% of the bolus into the larynx, thereby causing serious aspiration (Fig. 1). The anterior view of the pharynx showed right-sided

Correspondence to: Roland Giger, MD, Department of ORL and Head Neck Surgery, University Hospital of Geneva, Rue Micheli-du-Crest 24, 1211 Geneva 14, Switzerland; E-mail: gigerro@hotmail.com, roland.giger@hcuge.ch

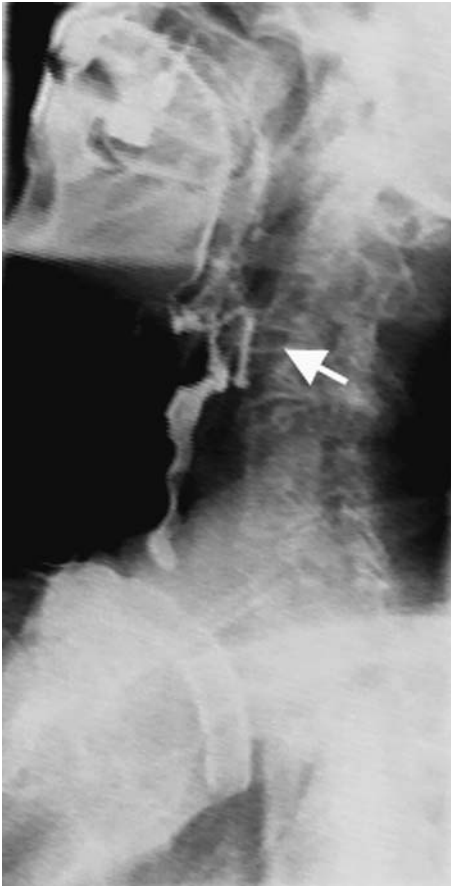


Fig. 1. Lateral view of dynamic videofluoroscopy revealing important anterior cervical osteophytes from C3 to C7 with a maximum at C3/4 (←) and a marked cervical lordosis. Tracheal aspiration can be seen.

pharyngeal wall dysfunction (Fig. 2). Flexible esophagoscopy was performed and percutaneous endoscopic gastrostomy was placed for nutritional support.

The patient underwent surgery with a right-sided anterolateral cervical approach to the spine. The dissection was medial to the carotid artery and lateral to the laryngotracheal and pharyngoesophageal segments. A self-retaining retractor was installed, and the level of the C4/5 disc was identified by lateral fluoroscopy. Large anterior osteophytes could be easily visualized and palpated, especially at the C3/4 and C6/7 levels. All osteophytes, together with a calcified anterior longitudinal ligament, were removed with rongeurs and a high-speed drill until the anterior spinal surface from C3 to C7 was flat on palpation and on lateral fluoroscopic control. Standard wound closure was performed.

After surgery the patient was mobilized without a collar. A postoperative lateral plain cervical spine radiograph demonstrated complete removal of all HACO from C3 to C7. Initial postoperative videofluoroscopy at one month showed absence of pharyngeal peristalsis and laryngeal elevation with aspiration. Three months after surgery, fiberoptic laryngoscopy demonstrated normal mobility of both vocal folds without any bronchoaspiration and oral feeding was introduced progressively. Seven months after surgery, the patient had a closed tracheotomy tube for 72 h and it was removed without further respiratory problems. The patient is still symptom-free three years after surgery.

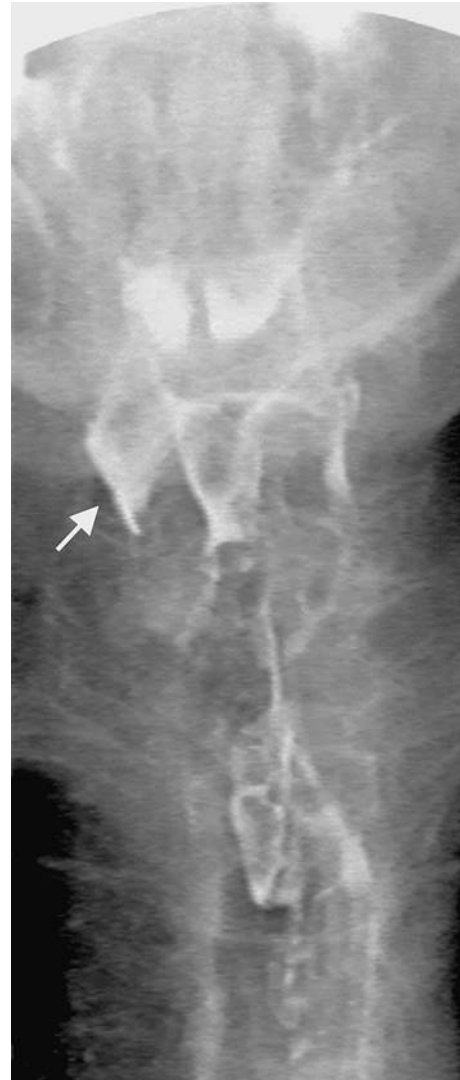

Fig. 2. Anterior view of dynamic videofluoroscopy illustrating unilateral pharyngeal wall dysfunction with residue in the right-side pyriform sinus. The pharyngeal wall on the damaged side enables the enlargement of the pyriform sinus (↑).

Discussion

Pathogenesis of Dysphagia

Postulated explanations for the dysphagia caused by HACO include mechanical compression causing esophageal obstruction, periesophagitis and peripharyngitis, fibrosis and adhesions with fixation of the esophagus, cricopharyngeal spasm triggered by pressure on the esophagus, impaired epiglottic motility, and distortion of the larynx or the laryngeal cartilages [10, 12, 13, 25, 27, 30–32]. In our case, dynamic videofluoroscopy showed a displacement of the pharyngeal lumen anteriorly by HACO. The unilateral dysfunction of the pharyngeal wall and the

bilateral vocal fold immobility allowing tracheal aspiration may result from damage of the pharyngeal and laryngeal neural plexuses caused by compression and/or inflammation. We cannot exclude direct damage of the cricoarytenoid joints as an explanation of the bilateral vocal fold immobility.

Pathogenesis of Dyspnea

Dyspnea as an additional or the only symptom of HACO is uncommon [2, 5–30]. Possible explanations for dyspnea include compression, glottic inflammation and edema, and vocal fold immobility. Dyspnea caused by a large extraluminal osteophytic mass directly compressing, distorting, and finally obstructing the airway with no evidence of associated vocal fold immobility or soft tissue swelling has been reported in 18 cases [5, 6, 8, 12, 14, 16, 18–20, 23, 24, 28–30]. Mechanical irritation of the retrocricoid area caused by rolling over prominent and spiky osteophytes at each swallow resulting in a chronic inflammatory edema obstructing the larynx has been postulated as the cause of dyspnea in five reported cases [2, 11, 17, 21, 27]. Similarly, iatrogenic manipulations such as tracheal intubation and respiratory infections may increase tissue inflammation and may complicate moderate symptoms [8, 12, 19]. Unilateral or bilateral vocal fold hypomobility or immobility has been reported in only 14 cases of HACO with dyspnea [7, 9, 10, 22, 24–26, 29]. The exact mechanism of vocal fold immobility remains unclear, although different hypotheses have been discussed: paresis of terminal laryngeal nerve fibers, trauma to the posteriorly located cricoarytenoid muscles (lateral and posterior), and direct involvement of the cricoarytenoid joint. All these mechanisms suppose a direct mechanical effect by the repeated friction of the larynx over a large bony hyperostosis [7, 9, 11, 24, 28]. The combination of unilateral pharyngeal wall dysfunction and bilateral vocal fold immobility in our case could probably be explained by neural damage due to mechanical compression.

Diagnostic Workup

Diagnostic workup should exclude other causes of dysphagia, dyspnea, and vocal fold hypo- or immobility. Flexible fiberoptic laryngoscopy will help to exclude a tumor and to estimate the vocal fold mobility and eventual inflammation. A lateral plain cervical radiograph shows anterior osteophytes. A CT scan with sagittal reconstruction demonstrates the craniocaudal and anteroposterior extent of cervical osteophytes and the location and degree of

pharyngoesophageal and laryngotracheal compression. Magnetic resonance imaging may reveal inflammatory lesions [2, 5–30]. Flexible esophagoscopy and bronchoscopy were proposed to evaluate the lower aerodigestive tract [8, 15, 23, 25, 26]. Dynamic videofluoroscopy is the main tool for investigating swallowing functions and shows the relationship between swallowing pathology and osteophyte size [31]. Finally, the literature and the experience with our case report let us conclude that fiberoptic laryngoscopy that confirms the bulge in the posterior pharyngeal wall and the laryngeal abnormalities, such as edema of the laryngeal mucosa and vocal fold hypo- or immobility, in combination with dynamic videofluoroscopy that shows the swallowing disorders in relation to the HACO would be sufficient and most helpful in establishing the diagnosis.

Therapy

The literature points out that treatment of HACO-induced dysphagia should depend on the nature and severity of the disease. Sedation, antibiotics, anti-inflammatory drugs, steroids, and muscle relaxants with an appropriate soft diet have been used successfully [32]. However, there is no doubt that in cases with prominent respiratory symptoms, the offending bony mass and spurs have to be removed with surgery to avoid further complications and respiratory failure [7]. As observed in our case report and in the reviewed literature, dysphagia is almost always a preexisting symptom that appears several months before the occurrence of dyspnea [2, 5–30]. Which patient will develop dyspnea is unclear.

Outcome

The prognosis for the restoration of swallowing is good. Every case in our literature review that had undergone surgery showed improvement of the dysphagia [2, 5–30]. However, the prognosis for the restoration of respiration and vocal fold mobility remains unclear [2, 5–30]. Sixteen of the 17 patients with dyspnea caused by posterior pharyngeal bulging with and without laryngeal edema with no signs of vocal fold hypo- or immobility showed improvement of respiration within one month after surgery. Only 5 of the 12 patients with dyspnea caused by posterior pharyngeal bulging with and without laryngeal edema and vocal fold hypo- or immobility showed improvement of respiration and vocal fold mobility within one month after surgery. The other five patients, including our case, showed slow improvement in respiration and vocal fold mobility in the

months right after surgery, while in two patients no resolution of dyspnea and vocal fold immobility was observed. In nine patients, no further treatment was performed. These findings let us conclude that patients with mechanical burden with or without mucosal edema causing dyspnea probably have a better prognosis and faster restoration of respiration after surgery than patients with additional vocal fold hypo- or immobility, which is probably a sign of acute and chronic inflammation followed by tissue fibrosis and/or neurologic damage.

Conclusions

Hypertrophic anterior cervical osteophytes (HACO) constitute an uncommon cause of dyspnea in combination with dysphagia. Large HACO may lead to life-threatening dyspnea with or without dysphagia by different mechanisms: (1) mechanical compression of the upper aerodigestive tract and (2) mechanical tissue irritation that induces inflammation, edema, fibrosis, ankylosis, and compression of neurologic structures (vagus nerve, pharyngeal and laryngeal branches of the vagus nerve, recurrent laryngeal nerve) compromising laryngeal or vocal fold mobility and esophageal peristalsis. Clinical examination by fiberoptic laryngoscopy that confirms the bulge in the posterior pharyngeal wall and the laryngeal signs of dyspnea such as edema of the laryngeal mucosa and vocal fold hypo-/immobility, in combination with dynamic videofluoroscopy that shows the swallowing disorders in relation to the HACO, would be sufficient and most helpful in establishing the diagnosis. Surgical removal of all HACO seems to be successful treatment in most cases.

References

1. Resnick D, Shaul SR, Robins JM: Diffuse idiopathic skeletal hyperostosis (DISH): Forestier's disease with extraspinal manifestations. *Radiology* 115:513–524, 1975
2. Matan AJ, Hsu J, Fredrickson A: Management of respiratory compromise caused by cervical osteophytes: a case report and review of the literature. *Spine J* 2:456–459, 2002
3. Nemours-Auguste S, Barag N: Dysphagia caused by cervical arthrosis. *Presse Med* 25:2295–2297, 1960
4. Saffouri HH, Ward PH: Surgical correction of dysphagia due to cervical osteophytes. *Ann Otol Rhinol Laryngol* 83:65–70, 1974
5. El-Sallab RA, Laws JW: Oesophageal and tracheal pseudotumours due to anterior cervical osteophytes. *Br J Radiol* 38:682–684, 1965
6. Benhabyles M, Brattström H, Sundén G: Dysphagia and dyspnoea as complications in spondylarthritis ankylopoetica with cervical osteophytes. *Acta Orthop Scand* 41:396–401, 1970
7. Saunders WH: Cervical osteophytes and dysphagia. *Ann Otol Rhinol Laryngol* 79:1091–1097, 1970
8. Girgis IH, Guirguis NN, Mourice M: Laryngeal and pharyngeal disorders in vertebral ankylosing hyperostosis. *J Laryngol Otol* 96:659–664, 1982
9. Hassard AD: Cervical ankylosing hyperostosis and airway obstruction. *Laryngoscope* 94:966–968, 1984
10. Sidi J, Hadar T, Shvero J, Har-El G, Shoshana M, Abraham A: Respiratory distress due to diffuse cervical hyperostosis. *Ann Otol Rhinol Laryngol* 96:178–181, 1987
11. Solomons NB, Linton DM, Potgieter PD: Cervical osteophytes and respiratory failure. *S Afr Med J* 71:259–260, 1987
12. Davies RP, Sage MR, Brophy BP: Cervical osteophyte induced dysphagia. *Australas Radiol* 33:323–325, 1989
13. Karlins NL, Yagan R: Dypnea and hoarseness. A complication of diffuse idiopathic skeletal hyperostosis. *Spine* 16:235–237, 1991
14. Rath T, Aita JF, Strauss DF, Hellbusch LC: A case report of Forestier's disease. *Nebraska Med J* 74:306–308, 1989
15. Jonathan D, Baer S: Cervical osteophytes: their significance in ENT practice (Ankylosing vertebral hyperostosis-Forestier's disease). *J Laryngol Otol* 104:23–238, 1990
16. Alonso-Vielba J, Morais D, Matesanz A, Santos J: Distress of the airway due to vertebral ankylosing hyperostosis or Forestier-Rotes' disease. *An Otorinolaringol Ibero Am* 21:159–167, 1994
17. Demuyneck K, Van Calenbergh F, Goffin J, Verschakelen J, Demedts M, Van de Woestijne K: Upper airway obstruction caused by a cervical osteophyte. *Chest* 108:283–284, 1995
18. Laus M, Malaguti MC, Alfonso C, Ferrari D, Zappoli FA, Giunti A: Dysphagia due to cervical osteophytosis. *Chir Organi Mov* 80:263–271, 1995
19. Bruno E, Alessandrini M, De Angelis E: Giant cervical hyperostosis of the prevertebral space: presentation of two cases and a review of the literature. *Acta Otorhinolaryngol Ital* 16:532–536, 1996
20. Tollefsen I, Hognestad S, Svihus R: Forestier syndrome. A rare cause of dysphagia and dyspnea. *Tidsskr Nor Laegeforen* 117:4076–4078, 1997
21. Marks B, Schober E, Swoboda H: Diffuse idiopathic skeletal hyperostosis causing obstructing laryngeal edema. *Eur Arch Otorhinolaryngol* 255:256–258, 1998
22. Verstraete WL, De Cauwer HG, Verhulst D, Jacobs F: Vocal cord immobilisation in diffuse idiopathic skeletal hyperostosis (DISH). *Acta Otorhinolaryngol Belg* 52:79–84, 1998
23. Papakostas K, Thakar A, Nandapalan V, O'Sullivan G: An unusual case of stridor due to osteophytes of the cervical spine: Forestier's disease. *J Laryngol Otol* 113:65–67, 1999
24. Kasper D, Hermichen H, Köster R, Schultz-Coulon HJ: Clinical manifestations of diffuse idiopathic skeletal hyperostosis (DISH). *HNO* 50:978–983, 2002
25. Maiuri F, Stella L, Sardo L, Buonamassa S: Dysphagia and dyspnea due to an anterior cervical osteophyte. *Arch Orthop Trauma Surg* 122:245–247, 2002
26. Manceau A, Beutter P, Lescanne E: Cervical osteophytes and ENT disease: three surgery cases. *Ann Otolaryngol Chir Cervicofac* 119:44–51, 2002
27. Stancampiano FF, Zavaleta E, Astor F: Anterior cervical osteophytes: a rare cause of dysphagia and upper airway

- obstruction in older patients. *J Am Geriatr Soc* 50:1910–1911, 2002
28. Aronowitz P, Cobarrubias F: Anterior cervical osteophytes causing airway compromise. *N Engl J Med* 349:2540.
 29. Fuerderer S, Eysel-Gosepath K, Schröder U, Delank KS, Eysel P: Retro-pharyngeal obstruction in association with osteophytes of the cervical spine. *J Bone Joint Surg (Br)* 86-B:837–840, 2004
 30. Kodama M, Sawada H, Udaka F, Kameyama M, Koyama T: Dysphagia caused by an anterior cervical osteophyte: case report. *Neuroradiology* 37:58–59, 1995
 31. Mader R: Clinical manifestations of diffuse idiopathic skeletal hyperostosis of the cervical spine. *Semin Arthritis Rheum* 32:130–135, 2002
 32. Deutsch EC, Schild JA, Mafee MF: Dysphagia and Forestier's disease. *Arch Otolaryngol* 111:400–402, 1985