

V.A.C.[®] Abdominal Dressing System

A Temporary Closure for Open Abdomen

Ludwig Labler¹, Jörn Zwingmann¹, Dieter Mayer², Reto Stocker¹, Otmar Trentz¹, Marius Keel¹

Abstract

Background and Purpose: The study reports experience with the recently commercially available V.A.C.[®] Abdominal Dressing System, a system designed for a temporary closure of an open abdomen situation under negative pressure. The method allows a late primary fascial closure after laparotomy in case of damage control, abdominal compartment syndrome or severe intra-abdominal spesis and facilitates delayed reconstruction of a large ventral hernia.

Patients and Methods: 18 patients with an open abdomen after laparotomy were managed between February 2002 and September 2004.

Results: Twelve patients after primary, one patient after secondary fascial closure and one patient with partially primary closure and resorbable mesh for abdominal wall reconstruction were free of wound infection or dehiscence of the abdominal wall. Evisceration or enteric fistulas were not observed. Five patients died in consequence of severe injury, a multiple organ failure or septic complications.

Conclusion: V.A.C.[®] Abdominal Dressing System is an effective temporary closure technique for open abdomen in critically ill patients which makes a late primary fascial closure up to 2 months after initial laparotomy possible either in trauma patients or in case of severe intraabdominal infection. The technique is simple and easily mastered.

Key Words

Vacuum-assisted closure · V.A.C. · Open abdomen · Abdominal compartment syndrome · Damage control · Fascial closure

Eur J Trauma 2005;31:488–94

DOI 10.1007/s00068-005-2031-y

Introduction

The management of abdominal compartment syndrome (ACS), with its effect on pulmonary, cardiac and renal functions, or the concept of damage-control laparotomy are techniques that proved to be an important advance of life-saving in trauma care [1–3]. A massive early resuscitation of trauma patients is often accompanied by marked visceral edema, retroperitoneal hematoma or a packing of the peritoneal cavity and results in an open abdomen situation. The same applies to reexploration of visceral viability after damage-control procedures or to intraabdominal contamination [4–6]. Also ischemia and necrosis of the abdominal fascia, caused either by the tension after a forced abdominal wall closure or by an intraabdominal infection, may lead to a dehiscence of the abdominal wall up to an abdominal rupture and to an open abdomen situation [7]. A primary fascial closure in all the above cases is not feasible [8] and a temporary abdominal closure (TAC) is indicated. Among diverse TAC techniques [5, 8, 9], vacuum-assisted closure (VAC), the efficient dressing technique for the management of problematic wounds [10–16], was successfully used also for treatment of open abdomen situations in the course of recent few years [17–23]. The V.A.C.[®] Abdominal Dressing System (KCI Vacuum Assisted Closure, San Antonio, TX, USA), a modification of the VAC technique designed specifically as a temporary closure of open abdomen, appeared on the market recently. This study reports our experience with the device named.

¹Division of Trauma Surgery, Department of Surgery, University Hospital Zurich, Switzerland,

²Division of Cardiovascular Surgery, University Hospital Zurich, Switzerland.

Received: March 18, 2005; accepted: June 12, 2005.

Table 1. Clinical characteristics. AIS: Abbreviated Injury Scale; F: female; ICU: intensive care unit; ISS: Injury Severity Score [25]; M: male.

Patient #	Gender	Age (years)	Cause for laparotomy				AIS					ISS	Hospital stay (days)	ICU stay (days)	
			Traffic accident	Work accident	Gunshot wound	Varia	Head	Face	Thorax	Abdomen	Pelvis/ extremities				Integument
1	M	24	+				3		4	4	3	2	41	71	25
2	M	69			+									41	26
3	M	58	+				4		4	4	2		48	46	46
4	F	24	+				4		3	5		2	50	103	69
5	M	13	+							5	4	2	45	89	57
6	M	47			+									14	14
7	M	24	+				5					1	26	27	27
8	M	62	+				2	2	4		3	1	29	60	60
9	M	33			+					5		1	26	93	37
10	M	48				+								99	99
11	M	58		+						3	4		25	30	7
12	M	17	+				3		4	3	3		34	27	26
13	M	21	+				2		5	5			52	60	35
14	F	21			+				3	5	2		38	50	13
15	M	43	+						3	4		1	26	67	2
16	M	15	+				6		4		3		61	2	2
17	M	37	+				4	2	5	4	2	3	57	23	23
18	M	18	+				3			5	5		59	7	7

Patients and Methods

Patients

18 patients with open abdomen after laparotomy were treated with the commercial V.A.C.® Abdominal Dressing System between February 2002 and September 2004. 15 patients were severely injured and three patients had other indications. The trauma patients were managed according to Advanced Trauma Life Support guidelines [24]. All hemodynamically stable patients with severe intraabdominal trauma or infection were evaluated by CT scan before laparotomy. The hemodynamically unstable patients were submitted to a damage control and a packing in the operating room (OR) and transferred afterwards to the intensive care unit (ICU). The clinical records (Table 1) include patients' data, Abbreviated Injury Scale (AIS), Injury Severity Score (ISS) [25], the ICU and hospital stay.

Technique

The commercially available V.A.C.® Abdominal Dressing System (KCI Vacuum Assisted Closure) consists of a thin black polyurethane foam encapsulated in the center of a perforated polyethylene sheet, a separate black polyurethane foam, a suction drain and of adhesive drapes. The sheet is cut to an appropriate dimension, placed over the viscera and tucked under the wound edges (Figure 1). A second black polyurethane foam, cut to fit the wound, is placed over the embedded plastic sheet with the thin foam. If necessary, the foam is fixed to the skin edges with staples (Figure 2). The surrounding skin is cleaned with benzine, and adhesive dressing drapes are trimmed as a patchwork to seal the wound. A hole of 2 cm diameter is cut out in the drape, the TRAC-PAD® (KCI Vacuum Assisted Closure) is positioned on this occlusive seal (Figure 3) and connected with a vacuum pump (KCI



Figures 1a to 1c. a) Open abdomen. b) Perforated polyethylene sheet with a thin polyurethane sponge encapsulated in the center. c) The sheet is tucked under the wound edges to prevent adhesion of the viscera to the peritoneum.

Figure 2. A second polyurethane sponge shaped to the size of the wound is placed over the embedded plastic sheet and fixed to the skin edges with staples.

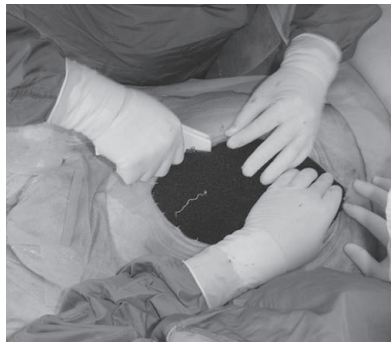
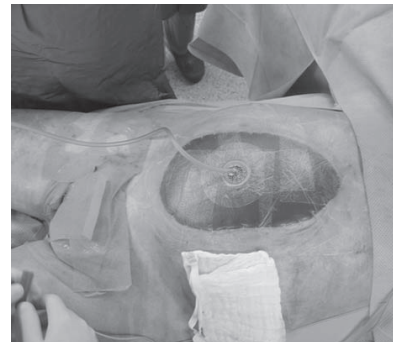
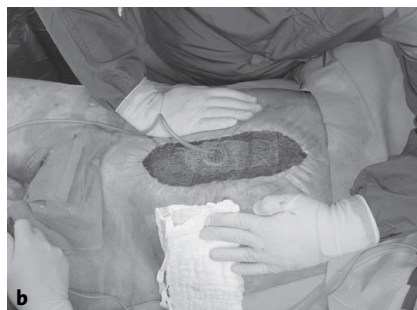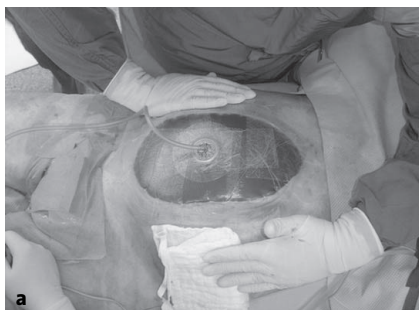Figure 3. The surrounding skin is cleaned with benzine, and adhesive dressing drapes are placed as a patchwork. A hole is cut out, and the TRAC-PAD® is positioned on the occlusive seals.



Vacuum Assisted Closure) via a container. The pump is adjusted to a constant negative pressure of 75 mmHg and set in action. The layers collapse and exert a uniform pressure upon both the wound and the abdominal fascia, and the suction draws the wound edges slowly together (Figure 4). At the same time, the wound fluid is continuously removed through the drain and transferred into the container. Technical problems with the VAC system are rare. Occasional leak is repaired by an additional piece of the adhesive drape at the bedside. The dressing is replaced by a new one generally in the OR, or if necessary, the procedure may also be carried out at the bedside in the ICU. As the V.A.C.® Abdominal Dressing System is stable enough as a TAC, the patients may be extubated and mobilized in an armchair for a better pulmonary rehabilitation on the ICU. As soon as the edema resolves, no necrosis is present on the fascia layers and granulation tissue formation of subcutaneous tissue takes place, the fascia may be stepwise closed by suturing [12, 13, 26]. When the patients are already in a stable condition but the primary fascia closure still is not feasible, a conventional VAC dressing (KCI Vacuum Assisted Closure) is applied until a healthy granulation tissue covers the viscera and the wound edges. When the wound bed is free of infection, the granulated open wound is skin-grafted or an absorbable mesh is implanted.



Figures 4a and 4b. a) V.A.C.® Abdominal Dressing System before suction is started. b) Suction is started and the foam collapses.

Results

Indication for laparotomy and the management of open abdomen are summarized in Table 2. Laparotomy was performed for abdominal damage control in eight patients (# 5, 9, 11–14, 16, 18). A gunshot injury (patient # 14) was managed by nephrectomy and segmental colon resection. The laparotomy wound developed an infection resulting in a disruption of the abdominal wall caused supposedly by retroperitoneal abscess formation on the right side. In two patients (# 16, 18), the damage control was combined with a tamponade of retroperitoneal hematoma of pelvic ring injuries. Three patients developed ACS in the course of the therapy. Two (# 6, 10) were under treatment for necrotizing fasciitis with severe septic course and one patient (# 7) had severe head injury. Complications in open abdomen situation emerged after early total care in three patients. In one patient (# 3) the wound disrupted with intraabdominal peritonitis or developed an intraabdominal abscess (# 15) after splenectomy. In both cases the abdomen was left open for second-look interventions. Relaparotomy had to be carried out also in patient # 4 2 weeks after early total care with splenectomy because of initially overlooked small pancreas rupture with severe peritonitis. Further therapy required open abdomen treatment. One patient (# 2) was treated for pyoderma gangraenosum of lower extremities. After 11 days of therapy, laparotomy was indicated because of spontaneous ascending and descending colon perforation with severe peritonitis. Right hemicolectomy and Hartmann procedure were carried out, and the abdomen was left open for second-look operations. Because of clinical signs of acute abdomen on the 3rd day after trauma (# 1), laparotomy was performed with intraop-

Table 2. Laparotomy and vacuum-assisted closure (VAC) dressing.

Patient #	Indication for laparotomy					Open abdomen dressing (days)	VAC dressing (changes)	Closure of abdominal wall				Death		
	ACS	Damage control	Early total care	Intra-abdominal infection	Infection after laparotomy			Primary fascial closure	Mesh graft	Secondary fascial closure	Resorbable mesh	Before primary closure	After primary closure	
1				+		29	10	+						
2				+		21	3	+						
3			+			11	4	+						
4			+			72	30	+						
5		+				42	16	+						
6	+					3	2	+						
7	+					19	7					+		
8				+		10	6	+						+
9		+				50	15		+	+				
10	+					32	12	+						
11		+				2	1	+						
12		+				2	1	+						
13		+				21	9	+						
14		+				9	3	+						
15			+			40	13	(+)				+		
16		+				2	0						+	
17					+	5	1						+	
18		+				6	5						+	

erative diagnosis of posttraumatic pancreatitis. Because of intraabdominal finding and distended bowels, the abdomen was left open for further surgical revisions and to prevent ACS development. One patient (# 8) developed ischemic small bowel perforation in the course of his trauma therapy. 10 days after resection and anastomosis, a leakage appeared with severe peritonitis. Relaparotomy with repeated lavage resulted in an open abdomen situation. Shocking gastric bleeding took place in patient # 17 after 17 days of trauma therapy. Gastroto-my and surgical control of bleeding were carried out. 4 days later the patient sustained abdominal wall disruption which, regarding his severe thoracic trauma, was treated by open abdomen therapy to prevent ACS. During open abdomen procedure two patients (# 1, 9) developed intraabdominal abscesses between small bowel loops, and in two patients (# 13, 14) a retroperitoneal abscess formation was observed during therapy which was surgically treated by irrigation and drainage. Four patients died during the treatment of open abdomen and before fascial closure. Two patients died because of severe head injury (# 7, 16), associated in patient # 16 with initially survived atlantooccipital dissociation (AOD). Patients # 17 and 18 died owing to a sepsis and multiorgan failure after severe trauma. One patient (# 8) died after performed fascial closure of the open abdomen due to multiorgan failure.

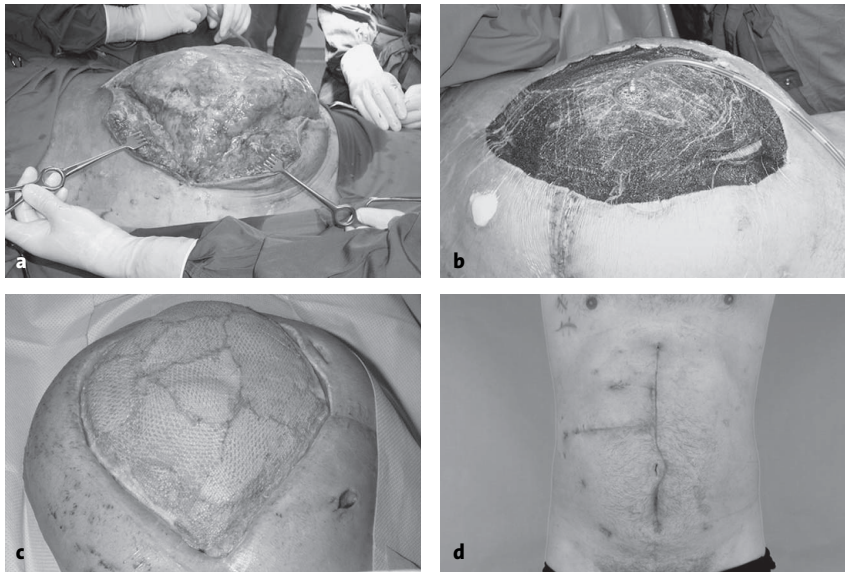
The VAC dressing was changed eight times on average (range, one to 30 changes). The dressing remained in place according to the circumstances for an average of 2.5 days (range, 1–5 days), except patient # 2 because of severe pulmonary complications. In this case the dressing was left in place up to 7 days.

A primary fascial closure was achieved in twelve patients. In the case of a penetrating trauma (patient # 9), the primary fascial closure failed because of persistent edema of the viscera. The open abdomen was then mesh-grafted and a secondary fascial closure was performed 22 days later when the patient was in stable condition (Figure 5). In one patient (# 15), a primary fascial closure was achieved in the medial laparotomy only, whereas the transverse accessory laparotomy had to be closed by an absorbable mesh.

All 13 patients who survived were available to follow-up examination in the time interval of 5–33 months. None developed a wound infection or a dehiscence of the abdominal wall.

Discussion

Open abdomen management of seriously injured or ill patients has been a challenge for the surgeon. Laparotomy after damage control with a tamponade, occurrence of ACS, abdominal wall defects and severe intraabdominal infections requiring repetitive exploration of the ab-



Figures 5a to 5d. a) Open abdomen after penetrating gunshot injury. b) Management of open abdomen after penetrating gunshot injury with V.A.C.® Abdominal Dressing System. c) The primary fascial closure failed because of persistent edema of the viscera and mesh grafting of the granulation tissue over the bowels was performed. d) Reconstruction of the abdominal wall was without complications.

dominal cavity are situations where a closure of the abdominal wall is impracticable and TAC is indicated. Also the systemic inflammatory response syndrome (SIRS) with its hypermetabolic state which leads to a capillary leakage and a consecutive swelling of the soft tissue encounters the same problem. TAC prevents a contamination of the peritoneal cavity, a bowel desiccation, an evisceration and a mechanical injury of the viscera. Further, it should be easily applied and managed. Several TAC techniques for management of open abdomen [5, 8, 9] and associated complications and problems [27–30] were reported. The negative pressure therapy with its wide range of indications was introduced into the clinical practice during the last decade. As TAC of open abdomen, VAC for the first time was applied quite early [17]. Nevertheless, 5 years elapsed before further reports appeared in the literature [18–23]. The negative pressure as the open abdomen management reported in the literature includes three systems: the vacuum-pack technique (A), VAC technique (B), and the commercial V.A.C.® Abdominal Dressing System (C), which differ in technical details. Unlike the customary VAC technique used for different sorts of wounds, all three open abdomen systems mentioned apply a perforated polyethylene sheet placed between the abdominal viscera and the anterior peritoneum. The sheet prevents adherence of the viscera to the peritoneum, allows the abdominal wall to

glide over the viscera and facilitates an easy TAC removal at repeated abdominal entries. The sheet perforation allows the wound fluid to be drained out of the abdominal cavity. The sheet delivered with the commercial device (C) is equipped with a thin foam encapsulated in its center helping minimize dressing shift within the abdomen. The polyethylene sheet is covered either with a moist sterile surgical towel (A) [17, 18, 20] or with a black polyurethane foam (B, C) [19, 21–23]. This layer fills up the open laparotomy wound, distributes a uniform negative pressure over the abdomen [19], and filters the removed abdominal fluid thus preventing a blockage of the drain. The skin is sutured (B) [19, 21–23] tightly [19, 21] or loosely [23] over the foam to prevent retraction of the fascial edge

or is let free in vacuum-pack (A). In our study, the foam was let free or, if necessary, fixed to the skin edges with staples. In our opinion, suturing over the foam might cause necrosis of the wound edges and the underlying bowels.

Two suction drains are installed over the towel dressing (A) and connected via a Y-adapter with the suction source [17, 18]. Alternatively, one suction drain only is introduced into the foam (B) [19, 21, 22], and then the dressings (A, B) are covered with an adhesive drape placed over the entire wound to get an airtight seal. Continuous suction of 100–150 mmHg [17, 18, 23] or 175 mmHg [21, 22] is started. The system (C) seals the dressing with an adhesive drape first, then a hole is cut into the drape and, finally, a TRAC-PAD® is installed and connected with a container and a vacuum pump. Unlike the published data, a negative pressure of 75 mmHg only was applied in our study. The lower pressure suffices entirely for an adequate fluid removal from the open abdomen and thus sufficiently prevents retraction of the wound edges. The urinary output in patients was lower than expected. The cause supposedly was the large wound fluid volume, up to 3 l ($1,640 \pm 1,334$ ml) in some cases, removed by the VAC system during the first dressing in accordance with the data (2–5 l) reported [23]. The removed volume then decreased to 825 ± 119 ml before the open abdomen could be closed.

Table 3. Vacuum-assisted closure (VAC) therapy of open abdomen.

Autor	Patients (n)	Mortality rate before closure (n)	Time of open abdomen (days)	Dressing change (days)	Primary fascial closure		Mesh grafting (n)	Complication after primary closure		
					(n)	% of survived		Fistula rate (n)	Intra-abdominal abscess (n)	Wound infection or dehiscence (n)
Brock et al. [17]	28	7	< 11	1–3	14	67	7	4	–	3
Barker et al. [18]	112	22	1–34	1–11	63	70	27	5	5	–
Garner et al. [21]	14	–	3–21	2–3	13	93	1	–	–	2
Miller et al. [19]	148	65	< 9–49	2–5	59	71	24	–	9	9
Markley et al. [20]	6	1	3–21	?	5	100	–	–	–	–
Suliburk et al. [22]	35	6	3–18	2–3	25	86	4	2	–	–
Stonerock et al. [23]	15	1	< 15–36	2–3	10	71	4	–	–	2
Labler et al.	18	4	2–72	2–7	12 + (1)	93	1	–	2	6

In some of our patients (# 4, 5, 9, 15) the abdomen was left open for a rather long time of 51 days on average (range, 40–72 days). In this group of patients the mean AIS for abdomen was 4.7 (range, 4–5) and the mean ISS was 37 (range, 26–50). Two of these patients suffered from severe intraabdominal septic complications after early total care procedure (# 4, 15). Patient # 5 was treated for traumatic hemipelvectomy, and patient # 9 had a gunshot injury to the liver with persistent edema of the viscera. On the other hand, this demonstrates that even such extremely long open abdomen situations may be practicable and, regarding the fact that all four patients survived, successful as well.

The results achieved by VAC therapy of open abdomen published in the literature and our own results are summarized in Table 3. Some of the authors (Table 3) failed to close the fascia primarily and had to apply mesh grafting over the granulation tissue in order to close the wound as also was the case in our patient # 9 with a penetrating trauma. Some of the patients had to be operated later for a second time in order to reconstruct the abdominal wall [18, 22]. Our five patients died in consequence of severity of their injuries, a multiple organ failure and/or septic complications, which correlates to other studies in Table 3.

Complication reported in the literature and connected with the use of VAC for open abdomen are ACS developed after installation of the vacuum pack technique [18] and fistula formations [17, 18, 22]. It was, however, not quite clear whether the fistulas were directly related to the dressing technique or associated with the primary injury or the surgical treatment. The bleeding, a well-known complication of VAC treatment of open wounds, has not yet been observed. Complications relat-

ed to the abdominal wall reconstruction were anastomotic disruption and wound infection [17, 19, 21, 23]. Poor quality of the fascia after the use of VAC therapy leading to ventral hernia was also described [23]. In our study, in accordance with similar observations [18], we did not observe any deep necrosis of the fascia after debridement and could perform the fascial closure without hernia formation or a dehiscence in 14 of our 18 patients. Fistula formation or bleeding was not observed. A formation of two intraabdominal abscesses between adherent bowels was a complication which may occur in a septic open abdomen. Its occurrence was observed not only in VAC but also after application of other TAC techniques and probably is not related to a particular dressing technique.

Conclusion

The VAC system, as well as its modification, the V.A.C.® Abdominal Dressing System, is a useful alternative technique for the management of open abdomen. The advantage of modifications B and C is the more uniform topic negative pressure to the wound edges and the fascia of the open abdomen. The encapsulated foam in the center of the polyethylene sheet of the commercial available V.A.C.® Abdominal Dressing System prevents the intraabdominal shift of the sheet. This modification keeps the device in position and secures the functionality of the system. In most cases, it allows a primary closure of the fascia thus preventing a formation of large ventral hernias and diminishes additional risks during subsequent reconstructive surgery of the abdominal wall. It seems that the traction force of the negative pressure on the wall edges of the open abdomen does not increase intraabdominal pressure. The technique is easy to handle, is performed in short time and can be mastered without difficulties.

References

1. Wittmann DH, Iskander GA. The compartment syndrome of the abdominal cavity: a state of the art review. *J Intensive Care Med* 2000;15:201–20.
2. Shapiro MB, Jenkins DH, Schwab CW, et al. Damage control: collective review. *J Trauma* 2000;49:969–78.
3. Ertel W, Oberholzer A, Platz A, et al. Incidence and clinical pattern of the abdominal compartment syndrome after “damage-control” laparotomy in 311 patients with severe abdominal and/or pelvic trauma. *Crit Care Med* 2000;28:1747–53.
4. Morris JA Jr, Eddy VA, Blinman TA, et al. The staged celiotomy for trauma. Issues in unpacking and reconstruction. *Ann Surg* 1993;217:576–84.
5. Aprahamian C, Wittmann DH, Bergstein JM, et al. Temporary abdominal closure (TAC) for planned relaparotomy (etappenlavage) in trauma. *J Trauma* 1990;30:719–23.
6. Garcia-Sabrido JL, Tallado JM, Christou NV, et al. Treatment of severe intra-abdominal sepsis and/or necrotic foci by an “open-abdomen” approach. Zipper and zipper-mesh techniques. *Arch Surg* 1988;123:152–6.
7. Graham DJ, Stevenson JT, McHenry CR. The association of intra-abdominal infection and abdominal wound dehiscence. *Am Surg* 1998;64:660–5.
8. Howdieshell TR, Yeh KA, Hawkins ML, et al. Temporary abdominal wall closure in trauma patients: indications, technique, and results. *World J Surg* 1995;19:154–8, discussion 158.
9. Schein M, Saadia R, Jamieson JR, et al. The “sandwich technique” in the management of the open abdomen. *Br J Surg* 1986;73:369–70.
10. Fleischmann W, Strecker W, Bombelli M, et al. Vacuum sealing as treatment of soft tissue damage in open fractures. *Unfallchirurg* 1993;96:488–92.
11. Morykwas MJ, Argenta LC, Shelton-Brown EI, et al. Vacuum-assisted closure: a new method for wound control and treatment: animal studies and basic foundation. *Ann Plast Surg* 1997;38:553–62.
12. Argenta LC, Morykwas MJ. Vacuum-assisted closure: a new method for wound control and treatment: clinical experience. *Ann Plast Surg* 1997;38:563–76.
13. Morykwas MJ, Argenta LC. Nonsurgical modalities to enhance healing and care of soft tissue wounds. *J South Orthop Assoc* 1997;6:279–88.
14. Fabian TS, Kaufman HJ, Lett ED, et al. The evaluation of subatmospheric pressure and hyperbaric oxygen in ischemic full-thickness wound healing. *Am Surg* 2000;66:1136–43.
15. Philbeck TE Jr, Whittington KT, Millsap MH, et al. The clinical and cost effectiveness of externally applied negative pressure wound therapy in the treatment of wounds in home healthcare Medicare patients. *Ostomy Wound Manage* 1999;45:41–50.
16. Labler L, Oehy K. Vacuum sealing of problem wounds. *Swiss Surg* 2002;8:266–72.
17. Brock WB, Barker DE, Burns RP. Temporary closure of open abdominal wounds: the vacuum pack. *Am Surg* 1995;61:30–5.
18. Barker DE, Kaufman HJ, Smith LA, et al. Vacuum pack technique of temporary abdominal closure: a 7-year experience with 112 patients. *J Trauma* 2000;48:201–6.
19. Miller PR, Thompson JT, Faler BJ, et al. Late fascial closure in lieu of ventral hernia: the next step in open abdomen management. *J Trauma* 2002;53:843–9.
20. Markley MA, Mantor PC, Letton RW, et al. Pediatric vacuum packing wound closure for damage-control laparotomy. *J Pediatr Surg* 2002;37:512–4.
21. Garner GB, Ware DN, Cocanour CS, et al. Vacuum-assisted wound closure provides early fascial reapproximation in trauma patients with open abdomens. *Am J Surg* 2001;182:630–8.
22. Suliburk JW, Ware DN, Balogh Z, et al. Vacuum-assisted wound closure achieves early fascial closure of open abdomens after severe trauma. *J Trauma* 2003;55:1155–60.
23. Stonerock CE, Bynoe RP, Yost MJ, et al. Use of a vacuum-assisted device to facilitate abdominal closure. *Am Surg* 2003;69:1030–4.
24. Collicott PE, Hughes I. Training in advanced trauma support. *JAMA* 1980;293:1156–9.
25. Baker SP, O’Neill B, Haddon W Jr, et al. The Injury Severity Score: a method for describing patients with multiple injuries and evaluating emergency care. *J Trauma* 1974;14:187–96.
26. Greer SE, Longaker MT, Margiotta M, et al. The use of subatmospheric pressure dressing for the coverage of radial forearm free flap donor-site exposed tendon complications. *Ann Plast Surg* 1999;43:551–4.
27. Sherck J, Seiver A, Shatney C, et al. Covering the “open abdomen”: a better technique. *Am Surg* 1998;64:854–7.
28. Nagy KK, Fildes JJ, Mahr C, et al. Experience with three prosthetic materials in temporary abdominal wall closure. *Am Surg* 1996;62:331–5.
29. Wouters DB, Krom RAF, Slooff MJH, et al. The use of Marlex mesh in patients with generalized peritonitis and multiple organ system failure. *Surg Gynecol Obstet* 1983;156:609–14.
30. Fry DE, Osler T. Abdominal wall considerations and complications in reoperative surgery. *Surg Clin North Am* 1991;7:1–11.

Address for Correspondence

Ludwig Labler
 Division of Trauma Surgery
 Department of Surgery
 University Hospital Zurich
 Rämistrasse 100
 8091 Zürich
 Switzerland
 Phone (+41/1) 255-1111, Fax -4406
 e-mail: ludwig.labler@usz.ch