

Transaortic transcatheter aortic valve replacement with the Sapien™ valve and the first generations of Ascendra™

Enrico Ferrari*, Denis Berdajs, Piergiorgio Tozzi and René Prêtre

Cardiac surgery unit, University Hospital of Lausanne, Lausanne, Switzerland

* Corresponding author. Cardiac surgery unit, University Hospital of Lausanne (CHUV), 46 Rue du Bugnon, CH-1011 Lausanne, Switzerland. Tel: +41-793101386; fax: +41-213142278; e-mail: enricoferrari@bluewin.ch (E. Ferrari).

Received 2 April 2013; received in revised form 26 April 2013; accepted 1 May 2013

Abstract

Traditionally, the transcatheter aortic valve replacement is performed through a transapical, a transfemoral or a trans-subclavian approach. Recently, the transaortic approach for transcatheter aortic valve replacement through the distal part of the ascending aorta was successfully implemented in order to avoid peripheral vascular access-related complications and apical life-threatening haemorrhage. The Sapien™ stent valve has great transaortic potential because it can be loaded 'upside down' in different generations of delivery systems. However, because of their health regulatory systems and despite the launch, in 2012, of the latest generation of the Ascendra™ delivery system, the Ascendra+™, specifically designed for transapical and transaortic valve placements, several countries are still using the first generations of Ascendra™ (Ascendra™ 1 and 2). This device was specifically designed for transapical procedures, and retrograde stent-valve positioning through the stenotic aortic valve may be very challenging and risk the integrity of the aorta. We describe the manoeuvre required in order to pass the stenotic aortic valve safely in a retrograde direction using the Sapien™ stent valve and the first generations of Ascendra™.

Keywords: Transcatheter aortic valve replacement • Transaortic transcatheter aortic valve replacement • Aortic valve stenosis

INTRODUCTION

Transcatheter aortic valve replacement (TAVR) is a successful procedure for inoperable patients and patients at high risk for surgery [1, 2]. Three access sites have been successfully employed for this procedure, namely the transapical (TA), the transfemoral (TF) and the trans-subclavian access. Nevertheless, some concerns have risen about the risk of life-threatening apical bleeding or apical dysfunction/scar/pseudo-aneurysm after TA-TAVR, and the risk of severe access-related vascular complications after TF-TAVR and trans-subclavian procedures [3, 4]. Recently, a technique combining the advantages of all transcatheter procedures without carrying their disadvantages was implemented in experienced centres; this technique is the transaortic approach (TAO-TAVR) through an upper mini-sternotomy or a right mini-thoracotomy at the second intercostal space [5, 6]. Both self-expandable (Corevalve; Medtronic, Minneapolis, MN, USA) and balloon-expandable valves (Sapien™ THV; Edwards Lifesciences, Irvine, CA, USA) were tested with good results [5–8]. In particular, the new Ascendra+™ delivery system for Sapien™ was specifically designed for this purpose. However, in several countries (in particular in the USA) the Sapien™ is still implanted using the Ascendra™ first generations only (Ascendra™ 1 and, later, the Ascendra™ 2), a tool designed to cross the valve in an antegrade direction. We describe the manoeuvre that represents a 'key point' allowing TAVR teams to cross the valve in a retrograde direction with the old system during TAO-TAVR.

TECHNIQUE

The first generations of Ascendra™ (Edwards Lifesciences), the Ascendra™ 1 and 2, have structural differences compared with the new Ascendra+™. In particular, they were not designed to enter vessels, and the distal part of the balloon catheter did not incorporate a nose-cone to facilitate retrograde valve crossing (Fig. 1A). Thus, in order to perform TAO-TAVR procedures, some centres used the Retroflex™ (Edwards Lifesciences), a delivery system designed to perform TF-TAVR. However, the Retroflex™ requires challenging manipulations when placed behind the patient's right shoulder due to its extensive length, and the procedure becomes more complex, with less stability, less precision and the risk of loss of sterility. As a consequence, the first generations of Ascendra™ were employed, and the following manoeuvre was developed in order to cross the valve in a retrograde direction.

- (i) After placing the super-stiff guidewire through the valve, the 6 French sheath is replaced by the Ascendra™.
- (ii) In order to avoid damage to the ascending aorta, vascular dilators are used to enlarge the hole (the set suggested for TF-TAVR or sets for percutaneous arterial cannulation). In this phase, bleeding is controlled by manipulating the aorta or by tying purse-string sutures, with concomitant blood pressure control.
- (iii) The Ascendra™ is gently inserted into the ascending aorta, with rotational manipulations to cross the wall thickness. Care is required to avoid aortic dissection.

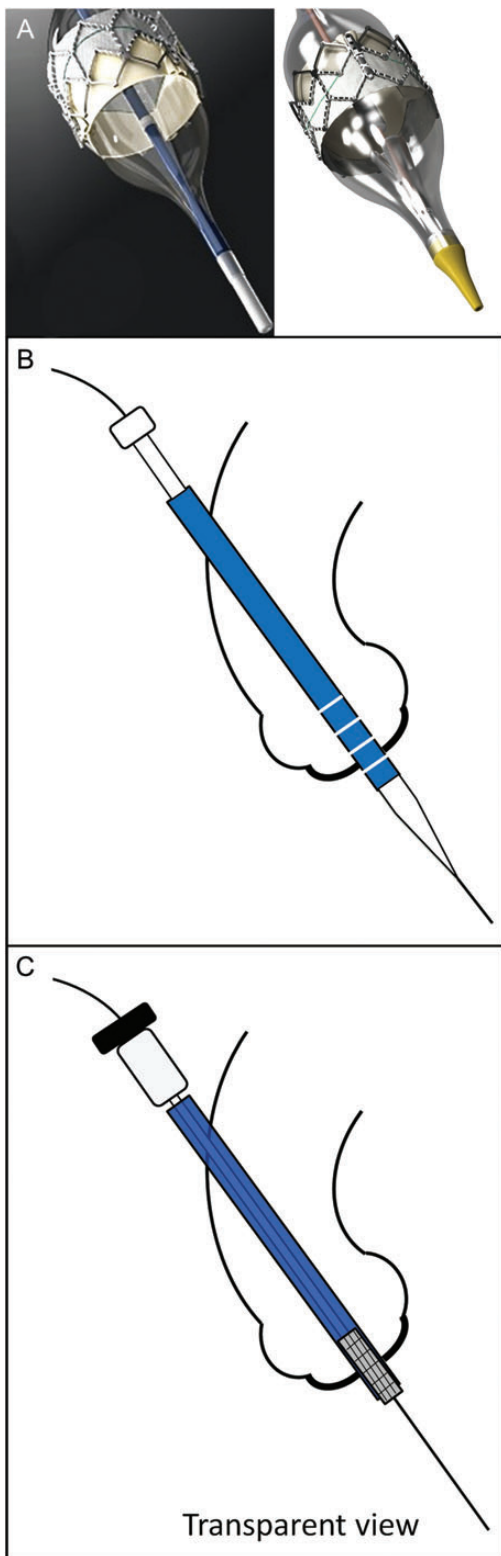


Figure 1: (A) The tip of the old generation Ascendra™ 1 (left) compared with the nose-cone of the new Ascendra+™ (right). (B) Over the wire, the first generation of Ascendra™ is placed through the stenotic aortic valve using the white dilator to cross the valve easily in a retrograde direction. The tip markers of the Ascendra™ should lie in the left ventricular outflow tract. (C) The white dilator is retrieved, and the loader carrying the crimped valve is connected to the Ascendra™. Then, the Sapien™ valve is placed across the diseased aortic valve under fluoroscopic control.

- (iv) Once the Ascendra™ has been inserted (1–2 cm) and the white dilator removed, the sheet is attached to the purse-string sutures as in standard aortic cannulation. This will prevent involuntary displacement of the delivery system.
- (v) Through the Ascendra™, the balloon is inserted, and the aortic valvuloplasty is performed following standard guidelines.
- (vi) After the balloon is removed, the stitch fixing the Ascendra™ to the purse-string sutures is removed and the white dilator is repositioned inside the sheet.
- (vii) Under fluoroscopic control, the sheet and the dilator are placed, over the wire, deep into the ascending aorta, through the diseased aortic valve (Fig. 1B). The radiopaque tip markers have to lie in the left ventricular outflow tract.
- (viii) The dilator is removed and the sheet left in place across the valve. Usually, this manoeuvre does not interfere with haemodynamics.

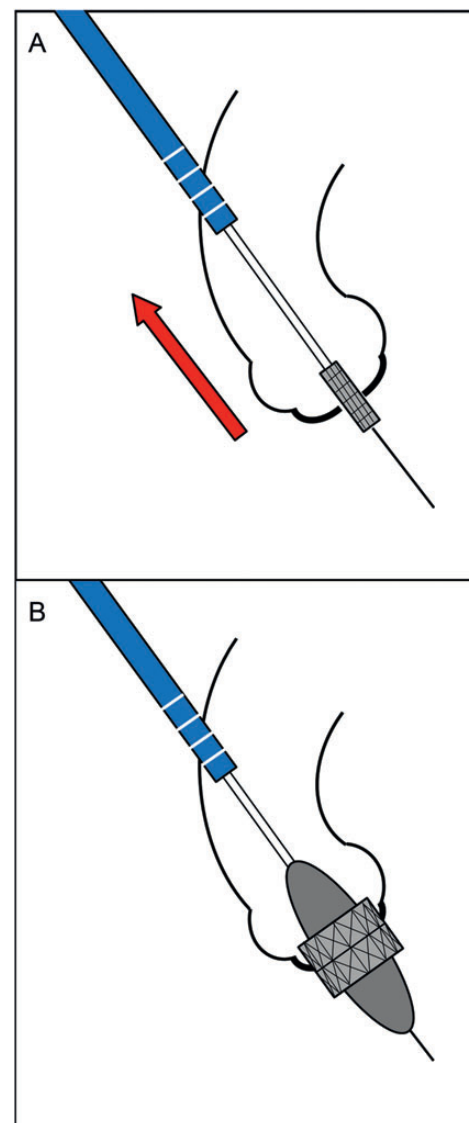


Figure 2: (A) The Ascendra™ is retrieved and parked in the distal ascending aorta while the crimped stent valve is left in place across the diseased aortic valve. (B) The Sapien™ is placed following standard guidelines.

- (ix) The valve loader is connected, and the crimped valve is inserted and placed across the aortic valve under fluoroscopic control, still covered by the sheet (Fig. 1C).
- (x) The balloon catheter with the valve is left in place while the Ascendra™ is retrieved into the ascending aorta. In this phase, extreme care is required not to displace the stent valve and not to extract the Ascendra™ completely (Fig. 2A). Then, the sheet is refixed to the purse-string sutures.
- (xi) The pusher is retrieved without displacing the Sapien™. Then, the valve is positioned and delivered following standard guidelines (Fig. 2B).

To date, several TAO-TAVR cases have been successfully performed in Europe using the first generations of Ascendra™ (Ascendra™ 1 and 2) and the above-described manoeuvre.

CONCLUSION

Transaortic TAVR is a promising approach for transcatheter valve replacement because the risk of peripheral vascular damage and apical bleeding is dramatically reduced. Moreover, compared with TF-TAVR or TA-TAVR, the aortic arch is much less stressed by guidewires, catheters and delivery systems, and this potentially reduces the risks of neurological complications. Reported aortic dissections can be attributed to an earlier phase (without the use of this manoeuvre and before the launch of the new Ascendra+™) or to the introduction of the sheet into the aorta (dilators can help). The Sapien™ stent valve has great potential in TAO-TAVR, and several implants have already been performed worldwide [5–8]. However, the new Ascendra+™ is engineered for this approach, whereas the first generations were not; thus, in order to cross the valve safely in a retrograde direction the manoeuvre described represents a ‘key factor’ for all Ascendra™ 1 and 2 users [owing to different health regulatory systems, these first generations of

Ascendra™ are the only ones available in several countries (e.g. USA), and they can still be employed safely in TAO-TAVR].

In conclusion, the technique described is safe, reproducible and easy and it allows TAVR teams using the Sapien™ platform to treat patients with a tailored approach, regardless of the generation of the medical device employed.

Conflict of interest: none declared.

REFERENCES

- [1] Walther T, Falk V, Borger MA, Dewey T, Wimmer-Greinecker G, Schuler G *et al.* Minimally invasive transapical beating heart aortic valve implantation – proof of concept. *Eur J Cardiothorac Surg* 2007;31:9–15.
- [2] Kempfert J, Rastan A, Holzhey D, Linke A, Schuler G, van Linden A *et al.* Transapical aortic valve implantation: analysis of risk factors and learning experience in 299 patients. *Circulation* 2011;124:S124–9.
- [3] Pasic M, Buz S, Dreyse S, Drews T, Unbehaun A, Klein C *et al.* Transapical aortic valve implantation in 194 patients: problems, complications, and solutions. *Ann Thorac Surg* 2010;90:1463–9.
- [4] Rodés-Cabau J, Gutiérrez M, Bagur R, De Larocheillère R, Doyle D, Côté M *et al.* Incidence, predictive factors, and prognostic value of myocardial injury following uncomplicated transcatheter aortic valve implantation. *J Am Coll Cardiol* 2011;57:1988–99.
- [5] Bapat V, Thomas M, Hancock J, Wilson K. First successful trans-catheter aortic valve implantation through ascending aorta using Edwards SAPIEN THV system. *Eur J Cardiothorac Surg* 2010;38:811–3.
- [6] Latsios G, Gerckens U, Grube E. Transaortic transcatheter aortic valve implantation: a novel approach for the truly “no-access option” patients. *Catheter Cardiovasc Interv* 2010;75:1129–36.
- [7] Bapat V, Khawaja MZ, Attia R, Narayana A, Wilson K, Macgillivray K *et al.* Transaortic Transcatheter Aortic valve implantation using Edwards Sapien valve: a novel approach. *Catheter Cardiovasc Interv* 2012;79:733–40.
- [8] Hayashida K, Romano M, Lefèvre T, Chevalier B, Farge A, Hovasse T *et al.* The transaortic approach for transcatheter aortic valve implantation: a valid alternative to the transapical access in patients with no peripheral vascular option. A single center experience. *Eur J Cardiothorac Surg* 2013;44:692–700.