

CASE REPORTS

Fatal myocardial infarction after lung resection in a patient with prophylactic preoperative coronary stenting[†]

C. Marcucci¹, P.-G. Chassot¹, J.-P. Gardaz¹, L. Magnusson¹, H.-B. Ris², A. Delabays³ and D. R. Spahn^{1*}

¹Department of Anaesthesiology, ²Department of Surgery and ³Division of Cardiology, University Hospital Lausanne (CHUV), 46 Rue Bugnon, CH-1011 Lausanne, Switzerland

*Corresponding author. E-mail: donat.spahn@chuv.hospvd.ch

In this report we present the case of a 77-yr-old man who underwent resection of the upper lobe of the left lung for a carcinoma, six weeks after percutaneous transluminal coronary angioplasty (PTCA) with stenting of the left anterior descending (LAD) and circumflex coronary arteries. Antiplatelet therapy with clopidogrel was interrupted two weeks before surgery to allow for epidural catheter placement and to minimize haemorrhage. The surgical procedure was uneventful. In the immediate postoperative period, however, the patient suffered severe myocardial ischaemia. Emergency coronary angiography showed complete thrombotic occlusion of the LAD stent. In spite of successful recanalization, reinfarction occurred and the patient died in cardiogenic shock. Prophylactic preoperative coronary stenting may put the patient at risk of stent thrombosis if surgery cannot be postponed for three months. In such cases, other strategies such as perioperative β -blockade for preoperative cardiac management should be considered.

Br J Anaesth 2004; **92**: 743–7

Keywords: complications, coronary artery disease; heart, coronary revascularization; surgery, non-cardiac

Accepted for publication: June 11, 2003

Patients with severe coronary artery disease (CAD) scheduled for urgent major surgery such as for cancer are a particular challenge for anaesthetists: one can proceed with surgery with the risk of postoperative cardiac complications, or coronary revascularization might be performed first and surgery postponed. However, delay can be undesirable because of the risk of tumour progression.

In patients with severe CAD, percutaneous transluminal coronary angioplasty (PTCA) before surgery may reduce postoperative morbidity and mortality.^{1–3} The use of intracoronary stents has modified the situation. Kaluza and colleagues⁴ reported that PTCA with coronary stenting increased the risk of stent thrombosis and myocardial infarction if surgery was performed within 6 weeks. The new ACC/AHA guidelines propose a 4–6-week interval between PTCA with stenting and non-cardiac surgery "to allow 4 full weeks of dual antiplatelet therapy and re-

endothelialization of the stent to be completed, or nearly so".⁵

We present a case of early non-cardiac surgery performed after coronary revascularization by balloon angioplasty and stenting, where the recommended delay was respected.

Case report

A nodular lesion, highly likely to be a primary tumour, was detected in the upper lobe of the left lung of a 77-yr-old man; mediastinoscopy with lobe resection was indicated. He had arterial hypertension, hypertensive cardiomyopathy and chronic renal insufficiency (serum creatinine 190 $\mu\text{mol litre}^{-1}$, creatinine clearance 29 ml min^{-1}). He had dyspnoea

[†]This article is accompanied by Editorial II.

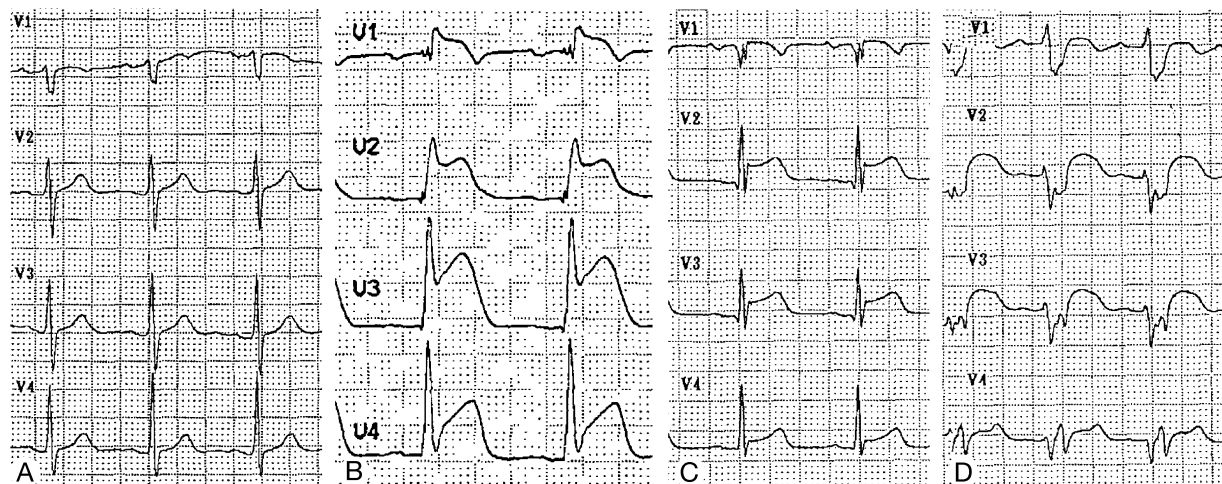


Fig 1 (A) Preoperative ECG; (B) 2 h after surgery; acute anterior myocardial infarction; (C) arrival in the intensive care unit after recanalization; (D) postoperative day 2, left bundle branch block with hypotension and cardiogenic pulmonary oedema.

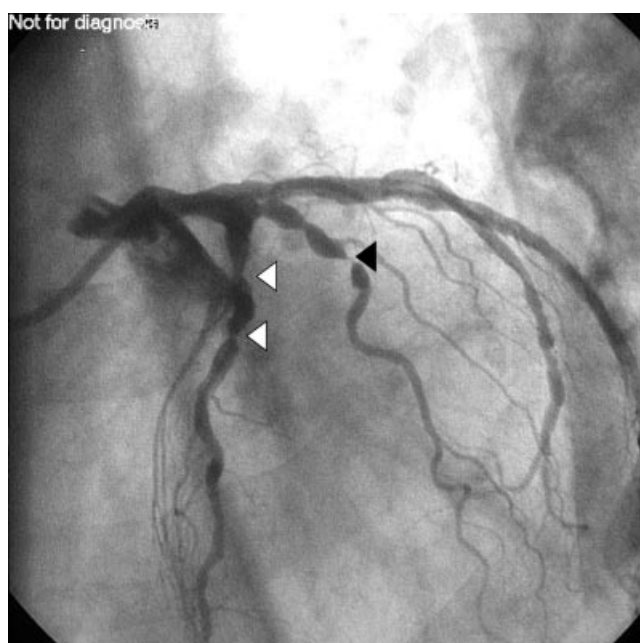


Fig 2 Preoperative coronary angiography showing 75% stenosis of the proximal and middle parts of the left anterior descending coronary artery (white triangles) and 95% stenosis of a diagonal branch (black triangle) (60% left anterior oblique view with 20% cranial inclination).

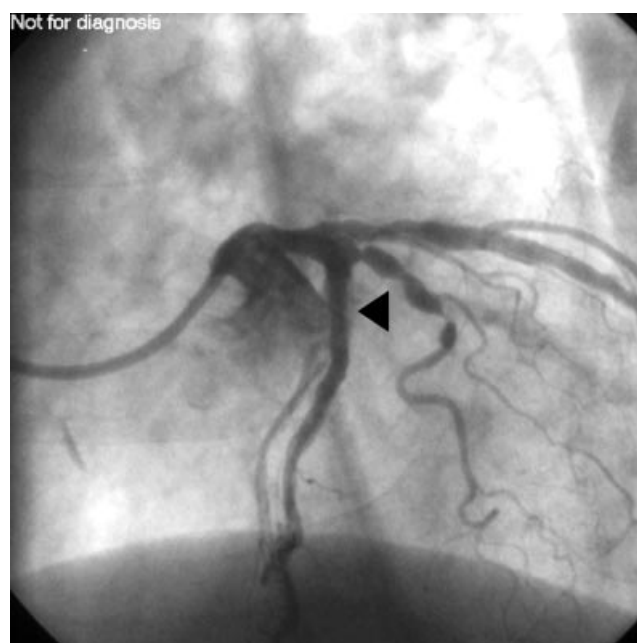

Fig 3 Restoration of flow in the left anterior descending coronary artery after successful recanalization (black triangle) (60% left anterior oblique view with 20% cranial inclination).

on exertion (NYHA grade II) and angina (Canadian Cardiovascular Society class II).

Baseline ECG (Fig. 1A), bronchoscopy, spirometry and lung volumes were all within normal limits. Exercise testing confirmed ischaemic heart disease, with retrosternal pain accompanied by a 0.2 mV depression of the ST segments in leads V5 and V6 at 96% of the theoretical maximal heart rate. Coronary angiography showed severe two-vessel disease with 90% stenosis of the proximal and middle parts of the circumflex coronary artery (Cx), 75% stenoses

of the proximal and middle parts of the left anterior descending coronary artery (LAD) and 95% stenosis of a diagonal branch of the LAD (Fig. 2). Left ventricular function was preserved, with an ejection fraction of 0.65. Both Cx and LAD were dilated and stented, with two stents in each of the coronary arteries (two Jomed stents in the Cx and two Velocity stents in the LAD) (Fig. 3). Since the diagonal branch was considered a minor coronary artery it was not dilated. The patient was treated with clopidogrel 75 mg day⁻¹ and aspirin 300 mg day⁻¹ for 4 weeks, followed by aspirin 300 mg day⁻¹ alone for 2 more weeks. Clopidogrel

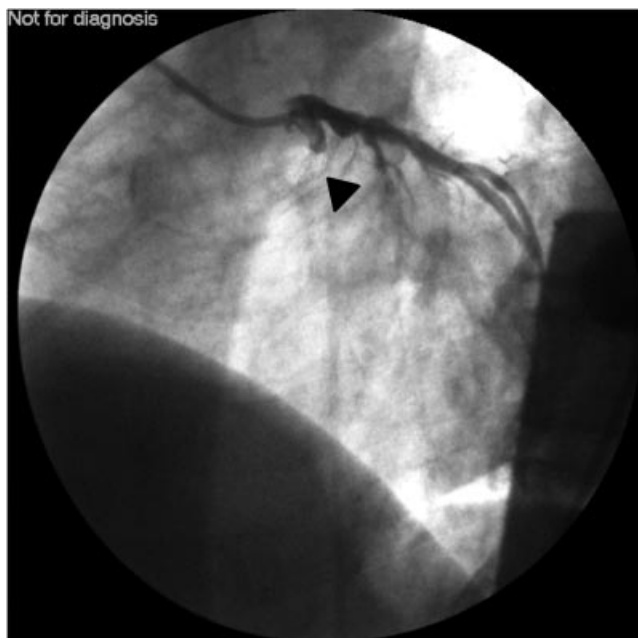


Fig 4 Postoperative coronary angiography showing complete occlusion of the left anterior descending coronary artery stent (black triangle) (60% left anterior oblique view with 20% cranial inclination).

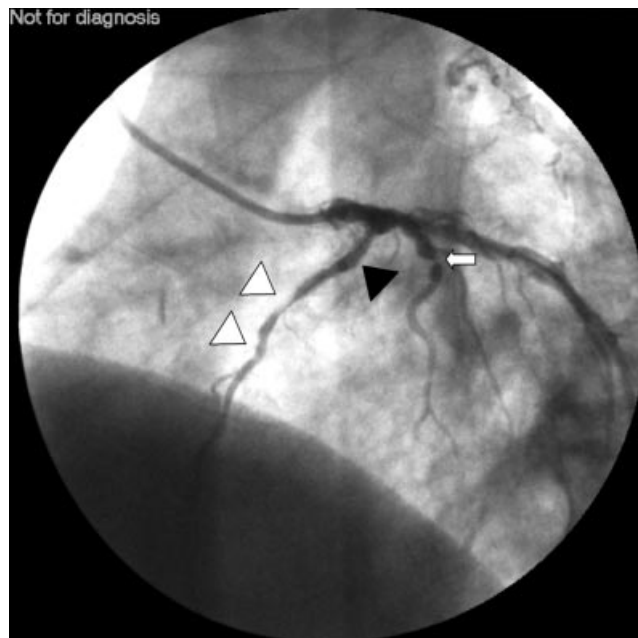


Fig 5 After recanalization of left anterior descending coronary artery stent (black triangle), multiple-staged thrombi (white triangles), stable 95% lesion of the diagonal branch (arrow) (60% left anterior oblique view with 20% cranial inclination).

was stopped 2 weeks before surgery to allow the use of an epidural catheter and to reduce the risk of surgical haemorrhage.

Six weeks after coronary revascularization, the patient was admitted for surgery. An epidural catheter was inserted in the T4–T5 interspace. General anaesthesia was induced with propofol 150 mg, fentanyl 300 µg and vecuronium 8 mg. Tracheal intubation was with a 39-French right-sided double-lumen tracheal tube. Supplemental fentanyl 200 µg boluses were given at the times of tracheal intubation and surgical incision. Anaesthesia was maintained with desflurane, and intraoperative analgesia was provided with a continuous epidural infusion of bupivacaine 0.5% 6 ml h⁻¹ and a remifentanyl infusion adjusted as needed. Monitoring included a five-lead ECG with continuous ST segment analysis, oesophageal temperature, pulse oximetry, $F_{I_{O_2}}$ and $F_{E'_{CO_2}}$ and invasive arterial pressure measurement using a 3F cannula in the right radial artery. Biopsies taken during mediastinoscopy were tumour free, and a left upper lobe resection with ipsilateral lymph node resection was carried out using a posterolateral incision. The surgical procedure took 210 min and was uneventful. The tumour was an epidermoid carcinoma with hilar lymph node metastases (T₁N₁M₀). The patient was extubated in the operating theatre. During surgery, the patient's circulation remained stable and no signs of myocardial ischaemia were seen on ST segment analysis.

On arrival in the recovery room, the patient was in pain and epidural analgesia was given, with a total of 8 mg of i.v. morphine; labetalol 20 mg was given i.v. to suppress the responses to pain (arterial pressure 200/90 mm Hg, heart

rate 116 beats min⁻¹), after which the patient became pain free and cardiovascular measures improved (arterial pressure 150/90 mm Hg, heart rate 76 beats min⁻¹). One h later, however, the patient developed sudden severe retrosternal pain and dyspnoea. Conventional ECG displayed Pardee curves up to 0.6 mV above baseline in leads V1–V4 (Fig. 1B). The patient was given supplemental oxygen; acetylsalicylic acid 500 mg, esmolol boluses up to 40 mg and morphine 8 mg were administered i.v. An infusion of nitroglycerine was started at 2 µg kg⁻¹ min⁻¹. Arterial pressure and heart rate remained stable at 140/80 mm Hg and 80 beats min⁻¹, respectively.

Emergency coronary angiography showed occlusion of the proximal LAD stent (Fig. 4) but there was no flow reduction in the Cx stents. After successful recanalization of the proximal LAD stent, several thrombi and a distal occlusion were found in the LAD (Fig. 5). Because of the risk of postoperative haemorrhage, intracoronary thrombolytic therapy was not given, nor treatment with a IIb-IIIa receptor inhibitor (abciximab).

After angiography, the patient was haemodynamically stable and was transferred to the intensive care unit (ICU). The ECG on admission showed signs of improvement, with the ST segment 0.2 mV above baseline in V2 and V3, and 0.1 mV in V4 (Fig. 1C). Serum troponin-I values increased from below 0.03 µg litre⁻¹ at the time of the acute event in the recovery room to 0.18 µg litre⁻¹ 2 h later at arrival in the ICU (normal range <0.03 µg litre⁻¹). Anticoagulation was with heparin titrated to an activated partial thromboplastin time (aPTT) of 30–40 s, and oral clopidogrel 300 mg was given once as a single dose followed by 75 mg daily. The

patient remained haemodynamically stable throughout the night and the following day, without supportive therapy.

During the second night after surgery the patient developed left bundle branch block (Fig. 1D) and cardiac failure (arterial pressure 83/48 mm Hg, heart rate 105 beats min^{-1} , central venous pressure 16 cm H_2O) with pulmonary oedema. Transthoracic ECG showed extensive antero-septo-apical akinesia and hypokinesia in the other segments of the left ventricle. Ejection fraction was estimated at 0.20. Troponin-I levels exceeded 100 $\mu\text{g litre}^{-1}$, confirming a large myocardial infarction.

In spite of increased anticoagulant therapy (heparin titrated to aPTT of 45–55 s), dobutamine 8 $\mu\text{g kg}^{-1} \text{min}^{-1}$ and norepinephrine 0.4 $\mu\text{g kg}^{-1} \text{min}^{-1}$, the patient's clinical status deteriorated, with tachypnoea (24 bpm) and tachycardia (131 beats min^{-1}). Arterial pressure was 101/58 mm Hg. A pulmonary artery catheter showed pulmonary hypertension (39/24 mm Hg) and increased pulmonary capillary wedge pressure (mean 21 mm Hg). Cardiac index was 2.17 $\text{litre min}^{-1} \text{m}^{-2}$. In view of the patient's advanced age, the extent of myocardial infarction, the severe left ventricular dysfunction and the poor prognosis of the malignant lung disease ($\text{T}_1\text{N}_1\text{M}_0$), haemodynamic and respiratory support was not increased and the patient died in asystole on the fourth day after surgery.

Discussion

Early in-stent thrombosis is a complex phenomenon. First, during the atherosclerotic process, coronary endothelial cells change from an antithrombotic to a prothrombotic phenotype.⁶ Second, immediately after balloon dilation, there is an inflammatory reaction with enhanced expression and disposition of prothrombotic factors on the injured endothelium.⁷ This endothelial injury is exaggerated if an intracoronary stent is placed,⁸ partly because higher inflation pressures and oversized balloons are used for stent deployment. This injury and subsequent inflammation cause loss of endothelial barrier function for 3 months after coronary stenting.⁹ Third, the stent itself causes inflammatory and prothrombotic changes: a fibrinogen layer immediately covers the surface of the stent¹⁰ and major platelet activation is induced.¹¹ Fourth, the type of stent used may also cause thrombosis. The culprit stent in the case described was a bare-metal stent known to cause severe local inflammation.¹² Finally, in this particular patient, the inflammatory response after surgery and activation of the coagulation system, as well as a possible coagulopathy linked to the underlying malignant process, could have contributed to the thrombosis. Immediately after surgery this patient also had severe pain with hypertension and tachycardia resulting from insufficient afferent and sympathetic epidural blockade. A more efficient cardiac sympathectomy might have helped prevent these adverse cardiac events.

Recent research has focused on the long-term consequences of endothelial injury and its inflammatory reaction, leading to neointimal hyperplasia and late in-stent stenosis.¹³ This occurs in 15–30% of patients within months of intracoronary stenting and requires reintervention. New anti-inflammatory and antimetogen drugs, as well as new techniques such as intracoronary radiation, are being tested, with contradictory results.¹⁴ Stent technology is also advancing, and new types of intracoronary stents are being used, including the cytostatic eluting stents. Designed to prevent neointimal hyperplasia in the stent's lumen, these stents effectively inhibit cellular proliferation on the stent wall, delaying intimal healing and increasing fibrinogen deposition.¹⁵ Patients treated with such stents will need longer dual antiplatelet therapy. The consequences of these new stents for a patient having surgery are unclear.

Compared with simple balloon angioplasty, the intracoronary stent offers better short- and long-term outcome in patients not having surgery.¹⁶ For surgical patients, PTCA with balloon dilation may reduce the risk of perioperative cardiac complications.^{2,3,17} No studies, however, have compared preoperative PTCA with and without stenting. Recent reports of adverse outcomes^{4,18} and the present case suggest that non-cardiac surgery soon after coronary stenting is associated with a major risk of postoperative myocardial ischaemia, even if the recommended interval of 6 weeks is respected. There are no prospective randomized trials defining the minimum safe delay between PTCA with stenting and subsequent surgery. Therefore, treatment has to be guided by basic science and observational studies. A 3-month delay between PTCA with stenting and any surgical intervention has been recently recommended to minimize the risk of in-stent thrombosis.¹⁹ However, in the case described here, the pulmonary lesion turned out to be a potentially operable lung cancer, and a 3-month delay after coronary revascularization may have been difficult to justify because of the risk of tumour progression. Comparing the images of the pre- and postoperative coronarographies we can also see that the high-grade stenosis of the diagonal branch remained unchanged throughout the perioperative period. Although it is a critical stenosis, it can be considered as a stable coronary lesion because it has an intact endothelium. An incompletely re-endothelialized stent, on the other hand, is an unstable coronary lesion and should be treated as such (i.e. with aggressive antiplatelet therapy). We stopped clopidogrel 2 weeks before the operation, as recommended⁵ to prevent surgical haemorrhage and to allow placement of an epidural catheter. However, 6 weeks may not be long enough for re-endothelialization to be completed. In retrospect, continuation of clopidogrel until the day of surgery, forgoing the advantages of epidural analgesia and accepting an increased risk of bleeding, might have been a better choice.

What alternative strategies exist for the perioperative management of such patients? First, aggressive haemody-

dynamic management with perioperative β -blockade without PTCA or stenting may be considered. This approach has been advocated by six publications summing a total of 502 patients receiving perioperative β -blockade. Only three of these studies were randomized (201 β -block patients in total) and only two were outcome studies (158 β -block patients vs 154 controls). These studies found that perioperative β -blockade reduced cardiac morbidity and mortality in high-risk patients.^{19,20} Second, if PTCA with stenting is performed before surgery, surgery should be postponed for as long as possible and antiplatelet therapy should be continued in the perioperative period. If this is inappropriate and coronary intervention is indicated, we suggest a two-step procedure: if surgery cannot be postponed for 3 months, preoperative revascularization could be limited to a balloon angioplasty without stenting. Once the patient has recovered from the non-cardiac operation, a definitive PTCA with stenting could then be done. Because intracoronary stenting has better short- and long-term results compared with angioplasty without stenting, and because no clinical data are available comparing the two techniques in a perioperative setting, cardiologists may be reluctant to apply this latter approach. Even if preoperative coronary revascularization, with or without stenting, is performed, these patients should still be considered as high risk and could benefit from perioperative β -blockade.

In conclusion, we describe a fatal myocardial infarction in a patient with CAD who had major surgery for malignant disease after coronary revascularization with PTCA and stenting 6 weeks before this surgery. The AHA/ACC guidelines recommend a 4–6-week interval between coronary stenting and major non-cardiac surgery but this case illustrates that a risk continues after this interval and that additional aggressive antiplatelet therapy and haemodynamic protective measures, such as β -blockade and optimal pain control, are needed.

References

- Elmore JR, Hallett JW, Gibbons RJ, et al. Myocardial revascularization before abdominal aortic aneurysmorrhaphy: effect of coronary angioplasty. *Mayo Clin Proc* 1993; **68**: 637–41
- Huber KC, Evans MA, Bresnahan JF, Gibbons RJ, Holmes DR. Outcome of noncardiac operations in patients with severe coronary artery disease successfully treated preoperatively with coronary angioplasty. *Mayo Clin Proc* 1992; **67**: 15–21
- Gottlieb A, Banoub M, Sprung J, Levy PV, Beven M, Masha EJ. Perioperative cardiovascular morbidity in patients with coronary artery disease undergoing vascular surgery after percutaneous transluminal coronary angioplasty. *J Cardiothor Vasc Anesth* 1998; **12**: 501–6
- Kaluza GL, Lee JR, Raizner ME, Raizner AE. Catastrophic outcomes of noncardiac surgery soon after coronary stenting. *J Am Coll Cardiol* 2000; **35**: 1288–94
- ACC/AHA Guideline update for perioperative cardiovascular evaluation for noncardiac Surgery – Executive summary. *Circulation* 2002; **105**: 1257–67
- Giovanni A, van Veldhuisen DJ, Tio RA, Mariani M. Pathophysiology of vascular endothelium and circulating platelets: implications for coronary revascularization and treatment. *Int J Cardiol* 2001; **79**: 265–75
- Picard P, Smith PJ, Monge JC, et al. Expression of endothelial factors after arterial injury in the rat. *J Cardiovasc Pharmacol* 1998; **31**(Suppl 1): S323–7
- Caramori PRA, Lima VC, Seidelin PH, et al. Long-term endothelial dysfunction after coronary artery stenting. *J Am Coll Cardiol* 1999; **34**: 1675–9
- Van Beusekom HM, Whelan DM, Hofma SH, et al. Long-term endothelial dysfunction is more pronounced after stenting than after balloon angioplasty in porcine coronary arteries. *J Am Coll Cardiol* 1998; **32**: 1109–17
- Grewe PH, Deneke T, Machraoui A, et al. Acute and chronic tissue response to coronary stent implantation: pathologic findings in human specimen. *J Am Coll Cardiol* 2000; **35**: 157–63
- Teruo I, Ryoichi S, Toshiyasu M, et al. Comparison of activation process of platelets and neutrophils after coronary stent implantation versus balloon angioplasty for stable angina pectoris. *Am J Cardiol* 2000; **86**: 1057–62
- Kornowski R, Hong MK, Tio FO, et al. In-stent restenosis: contributions of inflammatory responses and arterial injury to neointimal hyperplasia. *J Am Coll Cardiol* 1998; **31**: 224–30
- Hoffmann R, Mintz GS, Dussallant GR, et al. Patterns and mechanisms of in-stent restenosis: a serial intravascular ultrasound study. *Circulation* 1996; **94**: 1247–54
- Holmes DR, Savage M, Lablanche JM, et al. Results of prevention of restenosis with Tranilast and its outcomes (PRESTO) trial. *Circulation* 2002; **106**: 1243–50
- Hiatt BL, Ikeno F, Yeung AC, Carter AJ. Drug-eluting stents for the prevention of restenosis: in quest for the Holy Grail. *Catheter Cardiovasc Int* 2002; **55**: 409–17
- Maynard C, Wright SM, Every NR, Ritchie JL. Comparison of outcomes of coronary stenting versus conventional coronary angioplasty in the Department of Veterans Affairs medical centers. *Am J Cardiol* 2001; **87**: 1240–5
- Posner KL, Van Norman GA, Chan V. Adverse cardiac outcomes after noncardiac surgery in patients with prior percutaneous transluminal coronary angioplasty. *Anesth Analg* 1999; **89**: 553–60
- Vicenzi MN, Ribitsch D, Luha O, et al. Coronary artery stenting before noncardiac surgery: more threat than safety? *Anesthesiology* 2001; **94**: 367–8
- Chassot PG, Delabays A, Spahn DR. Preoperative evaluation of patients with, or at risk of, coronary artery disease undergoing non-cardiac surgery. *Br J Anaesth* 2002; **89**: 747–59
- Zaugg M, Schaub MC, Pasch T, Spahn DR. Modulation of β -adrenergic receptor subtype activities in perioperative medicine: mechanisms and sites of action. *Br J Anaesth* 2002; **88**: 101–23