

Cladophialophora bantiana: a rare cause of fungal brain abscess. Clinical aspects and new therapeutic options

CHRISTIAN GARZONI*, LYDIA MARKHAM†, PHILIPPE BIJLENGA‡ & JORGE GARBINO†

*Infectious Diseases Division, University Hospital of Bern, Bern, †Infectious Diseases Division, University Hospitals of Geneva, Geneva, and ‡Neurosurgery, Department of Clinical Neurosciences, University Hospitals of Geneva, Geneva, Switzerland

Black molds or dematiaceous fungi are rare etiologic agents of intracerebral abscesses and such infections carry a high mortality of up to 70% despite combined surgical and antifungal therapy. While the growing use of immunosuppressive therapies and organ transplantation have caused an increase in the incidence of rare fungal cerebral infections, occurrence in immunocompetent hosts is also possible. We describe a 60-year-old female patient with a cerebral abscess caused by *Cladophialophora bantiana*. The case illustrates the clinical and radiological similarities between glioblastomas and brain abscesses and emphasizes the need to perform histological and microbiological studies prior to the initiation of any form of therapy. Long-term survival from cerebral black mold abscesses has been reported only when complete surgical resection was possible. The recommended antifungal treatment involves the use of amphotericin B combined with a triazole and, if possible, flucytosine. Highly-active new generation triazole antifungal compounds (voriconazole or posaconazole) are likely to offer improved survival rates for patients with rare mold infections. In particular, posaconazole could be a new therapeutic option given its better tolerance, lower toxicity and fewer drug-drug interactions. We discuss clinical, microbiological and practical pharmacological aspects and review current and evolving treatment options.

Keywords brain abscess, *Cladophialophora bantiana*, dematiaceous fungus, posaconazole, voriconazole

Introduction

Cladophialophora bantiana is a highly neurotropic dematiaceous fungus and a rare cause of cerebral abscesses. Such infections carry a high mortality of up to 70% and neurosurgical radical resection associated with powerful antifungal treatment is the most successful therapeutic strategy reported to date. We describe a case involving a 60-year-old woman with an unresectable *C. bantiana* brain abscess treated by a combined approach of CT-guided aspiration and

aggressive antifungal therapy. Sequential imaging suggests that the fungal infection was contained. This case illustrates the absence of a pathognomonic image of glioblastoma and the absolute need to obtain histopathological confirmation when possible before initiation of any treatment. Highly active new-generation antifungal compounds will probably improve the prognosis of rare mold infections of the central nervous system (CNS) and we review the microbiological and practical pharmacological aspects of these evolving therapies.

Received 4 September 2007; Accepted 14 January 2008

Correspondence: Jorge Garbino, Service of Infectious Disease, University Hospitals of Geneva, 24 Rue Micheli-du-Crest, 1211 Geneva 14, Switzerland. Tel: + 41 22 372 9839; Fax: + 41 22 372 9832; E-mail: jorge.garbino@hcuge.ch

Case Report

A 60-year-old woman was referred to our institution because of fever and frequent falls ten days after her arrival in the country. Upon admittance, she was sleepy

and confused. Her medical history included long-term corticoid therapy (10 mg/d) and cholechine 1 mg/d for systemic sclerosis, pulmonary fibrosis and Raynaud's phenomenon which was in remission after six months of cyclophosphamide treatment she received three years earlier. She had chronic hepatitis C-related cirrhosis, chronic thrombocytopenia linked to secondary hypersplenism (60 G/L, normal range 150–350 G/L) and arterial hypertension.

Neurological examination was normal apart from drowsiness and confusion, as was the rest of the clinical examination. Laboratory investigations revealed the lack of an inflammatory syndrome (normal leucocytes, C-reactive-protein <1 mg/l). Liver enzymes were known to be chronically elevated because of active hepatitis C. A cerebral CT-scan showed a 2 cm diameter ring-enhancing lesion in the left posterior arm of the

internal capsule compressing the left lateral ventricle (Fig. 1A & B). Magnetic resonance imaging (MRI) of the brain showed a ring-enhancing lesion in the body of the caudate infiltrating the corpus callosum and the posterior arm of the internal capsule, strongly suggesting the diagnosis of high grade glioma (Fig. 1C & D). Due to the history of chronic immunosuppressive therapy with prednisone and previous cyclophosphamide treatment for systemic sclerosis, the probability of a secondary cerebral lymphoma or an opportunistic infectious process was considered. Antibiotic treatment with imipenem-cilastatin 500mg i.v. every 6 h associated with dexamethasone 100 mg was started. Serology for toxoplasma was negative (IgM and IgG) eliminating the possible presence of a cerebral toxoplasmosis abscess.

The patient deteriorated during the first week with the appearance of progressive right hemiparesis,

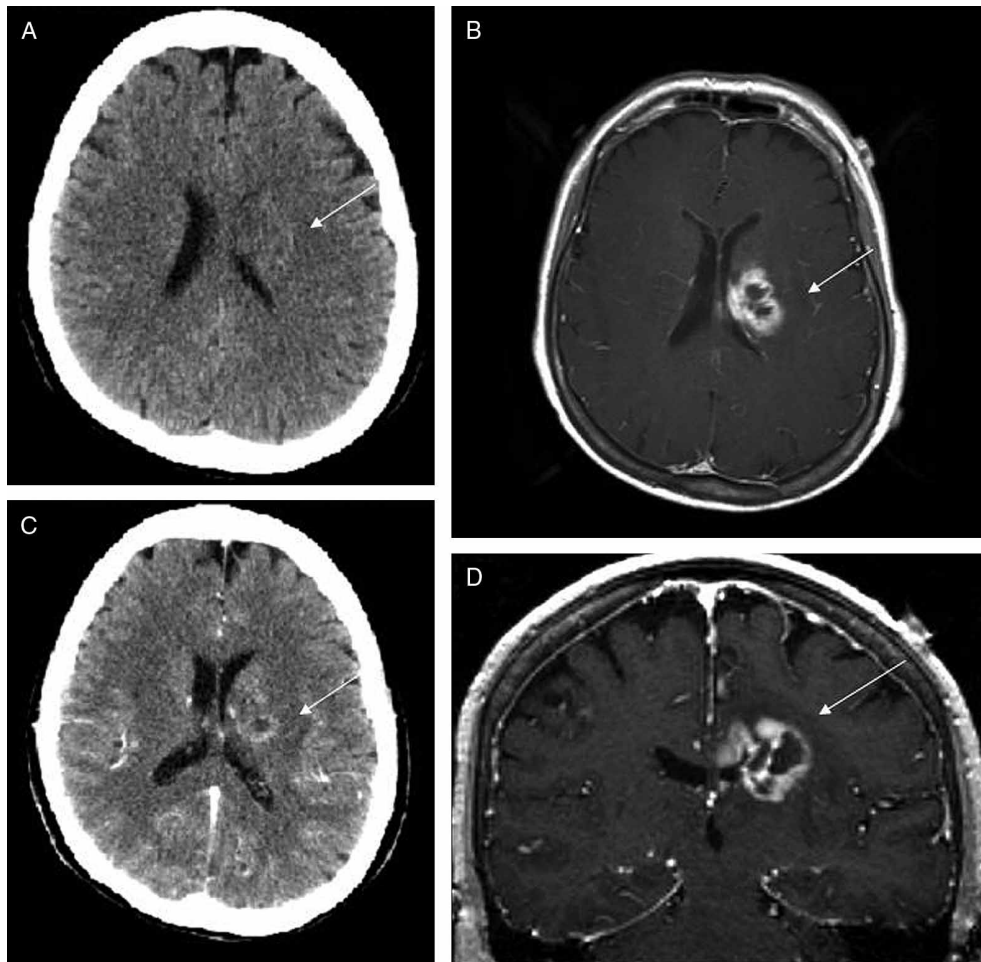


Fig. 1 Initial imaging of lesion. (A) Axial section of native CT-Scan demonstrating a discrete hypodensity in the left body of the caudate and mass effect on the lateral ventricle. (B) Contrast-enhanced CT-Scan showing enhancement of the lesion. (C) Axial section of contrast-enhanced T1-weighted MRI. (D) Coronal reconstruction of contrast-enhanced T1-weighted MRI showing extension within corpus callosum.

aphasia and a worsening in sensorium. Notwithstanding both the risk of hemorrhage increased by thrombocytopenia and radiological features advocating glioblastoma diagnosis, a neuronavigation-guided frameless needle biopsy was performed under platelet transfusion. Approximately 5 ml of a total lesion volume of approximately 6–7 ml was aspirated. Microscopic analysis of Gram, Calcofluor white and Grocott silver stained biopsy material revealed a brain abscess suspected to be caused by a black mold.

The presumptive diagnosis was confirmed by further analysis. The aspirated liquid was cultured onto CHROMagar Candida (Beckton Dickinson, New Jersey, USA). After 12 days, 20 mm size colonies were noted developing in culture. They had a velvety texture and were olive gray to black on the obverse and black on the reverse. Microscopic examination of a lactophenol stained slide culture preparation revealed brown septate hyphae with long, sparsely branched conidiophores bearing wavy chains of smooth oval conidia. The latter did not display dark attachment scars as has been described for other *Cladosporium* spp. Aspirated liquid was also inoculated onto Sabouraud dextrose agar. The isolate recovered could grow at 42°C, a feature that differentiates *C. bantiana* from other morphologically similar saprophytic fungi (Fig. 2). To corroborate the identification of the species, samples were subjected to a polymerase chain reaction (PCR) amplification with ITS (internal transcribed spacer) 1 and ITS4 primers as previously described [1]. The amplicon was sequenced on an ABI PRISM 310 Genetic Analyser sequencer (Applied Biosystems, Rotkreuz, Switzerland); the resulting sequence was

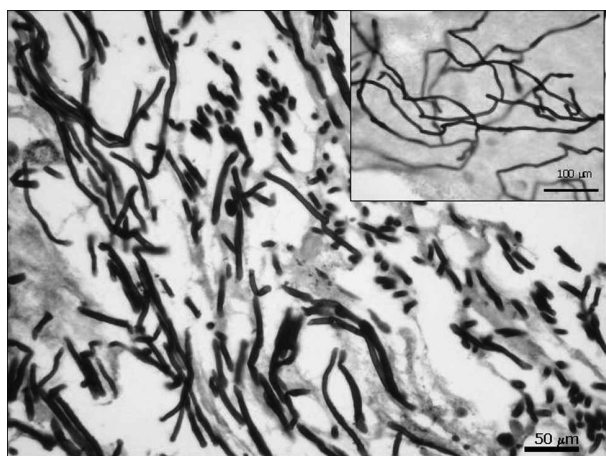


Fig. 2 Histological and cytological (inset) analysis (Grocott silver stain coloration) revealed invasion of brain structures by septed low branching hyphae.

analyzed with the FASTA program and compared with other sequences of the *Cladophialophora* genus published in GenBank (NCBI) and SeqWeb2.1.0. [1]. The results confirmed the microbiological diagnosis.

C. bantiana was susceptible to all antifungal agents apart from fluconazole. The minimal inhibitory concentrations (MIC; YeastOne™ Trek Diagnostic, Pennsylvania, USA) obtained were (μg/ml): amphotericin B, 1.0 μg/ml (susceptible = S); fluconazole, 64 μg/ml (resistant); itraconazole, 0.023 μg/ml (S); ketoconazole, 0.032 μg/ml (S); flucytosine, 1.0 μg/ml (S); voriconazole 0.064 μg/ml (S); posaconazole, 0.02 μg/ml (S); caspofungin, 0.50 μg/ml (S). Since no breakpoints have been well established for the different antifungal drugs, it is difficult to establish a standardized antifungal therapy. In addition, the efficacy of various antifungal agents against black molds is not clearly defined in cases involving humans. However, there has been limited clinical experience with the newer antifungal compounds like third-generation antifungal triazoles posaconazole and voriconazole.

Voriconazole (400 mg p.o.s b.i.d) and liposomal amphotericin B (5 mg/kg body weight daily) were started and gradually increased to 7 mg/kg/day. Voriconazole was preferred over itraconazole because of better bioavailability (96% vs 55%) and cerebrospinal fluid penetration (90% vs. 50%). Flucytosine could not be added to this regimen because of the risk of myelotoxicity in a patient with chronic thrombocytopenia. Aphasia remained unchanged and right hemiplegia worsened. Brain MRI performed 5 days after starting treatment showed an increase in the initial lesion and new lesions following the biopsy tract (Fig. 3A). The increase in the levels of liver enzymes (ASAT and ALAT) from 59 and 105 U/l at admission to 176 and 310 U/l, respectively (normal range, 11–42 U/l) confirmed hepatotoxicity and voriconazole was replaced by posaconazole (400 mg b.i.d p.o.s). Ten days after the change to posaconazole, liver enzymes improved rapidly (ASAT 115 U/l and ALAT 189 U/l).

A third MRI performed 11 days after the introduction of posaconazole showed control of the growing brain abscesses. The volume of the lesions was significantly reduced and less midline shift was evidenced (Fig. 3B). Neurological deficits remained stable. Considering the dynamic of abscess growth before the introduction of posaconazole, the findings were interpreted as evidence of the efficacy of the treatment with posaconazole. Unfortunately, the patient developed aspiration nosocomial pneumonia with severe sepsis and died.

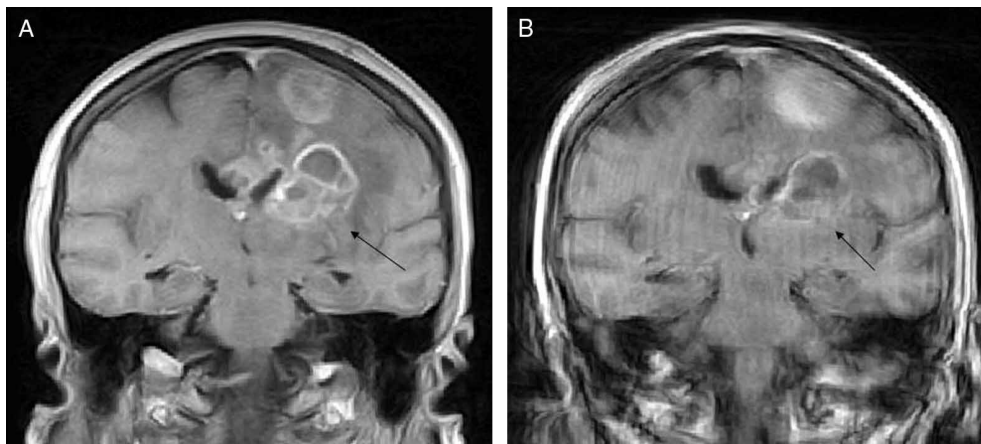


Fig. 3 MRI coronal reconstruction of T1-weighted contrast-enhanced images at similar rostro-caudal levels. (A) Two days before posaconazole treatment initiation. Note seeding along biopsy tract. (B) Eleven days after posaconazole treatment the enhancement of the lesions were reduced.

Discussion

Infection of the central nervous system caused by a dermatiaceous mold is referred to as cerebral phaeohyphomycosis, which may be literally defined as ‘infection due to dark-walled fungi’, i.e., those with the dark pigment melanin. While rare, *C. bantiana* (formerly *Cladosporium bantianum*, *Cladosporium trichoides* and *Xylohypha bantiana*) is the most common agent of this disease.

Although infections caused by dematiaceous fungi are not common, they are being increasingly recognized as being involved in human disease, particularly in the immunocompromised host [2,3]. They can cause soft-tissue infection, sinusitis, mycetoma and CNS abscesses. In particular, *C. bantiana* has a high specificity for the CNS as evidenced in a recent extensive review of 101 cases of cerebral phaeohyphomycosis in which 48 cases were associated with *C. bantiana* [2]. The infection usually results from haematogenous dissemination from a primary site of invasion, commonly the lung. However, the absence of a primary focus is not unusual.

Brain abscesses caused by *C. bantiana* have been reported in both immunocompetent and immunocompromised patients, predominantly in transplant recipients [4–13]. Immunosuppression due to corticoid therapy, neutropenia or diabetes mellitus has also been associated with infections caused by this mold [14,15]. Direct inoculation, eye trauma and intravenous drug use are other known risk factors. Given the increasing use of immunosuppressive therapies and organ transplantation, the incidence of rare fungal diseases, including cerebral mold infections, will certainly be observed more frequently.

Clinically, patients may present with insidious headaches and slow evolving neurological signs. It is important to stress that fever is not always present and infection parameters can be normal on admission of the patient. The abscess can be single or multiple and is usually easy to identify through CT or MRI studies [16]. Radiologically, fungal abscesses caused by rare fungi such as *C. bantiana* cannot be differentiated with certitude from bacterial abscesses, primary CNS neoplasia or cerebral metastasis. In particular, differentiating between brain abscesses and cystic brain tumors such as high-grade gliomas and metastasis is often difficult, if not impossible [17]. In the immunocompromised host, the differential diagnosis is broader and opportunistic infections (toxoplasmosis, nocardiosis, and listeriosis among others) and specific malignancy like lymphoma should also be considered. Cerebral biopsy with histological studies and exhaustive microbiological cultures for bacteria, mycobacteria and fungi are considered the gold diagnostic standard and should always be performed.

The mortality rate of cerebral *C. bantiana* infection is high. A recent series confirmed a death rate of 70% despite surgical resection and systemic antifungal therapy [1]. Several studies have shown that radical surgical resection followed by targeted pharmacological treatment enabled good recovery in some cases [18]. One study of 26 cases of cerebral *C. bantiana* infections concluded that radical surgical resection of the CNS lesions was the best outcome predictor [16]. However, given that CNS disease by *C. bantiana* is a rare, life-threatening condition, recommendations for systemic antifungal therapy can only be based upon the experience of isolated cases. Based on a large case series [16], systemic antifungal treatment does, however,

appear to affect outcomes. Antifungal therapy is evolving rapidly and more efficient and better tolerated new drugs are now available.

Fluconazole is not active against *C. bantiana* and the classical medical treatment is amphotericin B i.v. alone or associated with flucytosine and itraconazole. In the largest published review of 48 cases, mortality was as high as 70% despite the use of these antifungal agents [2]. The major factor causing such high mortality rates is the poor penetration of amphotericin B (either as deoxycholate or liposomal form) and itraconazole across the blood-brain barrier [19,20]. Furthermore, major adverse effects associated with the use of these drugs often limit and force an interruption of treatment. Amphotericin B is known for its renal toxicity and electrolyte disturbances. Flucytosine use is limited by its high bone marrow toxicity. Itraconazole is an azole used as standard treatment but its oral formulation presents large inter-individual differences in gastrointestinal absorption which is a major limitation and necessitates monitoring of drug levels.

Voriconazole or posaconazole are new second-generation triazole compounds and represent very attractive options to replace itraconazole in *C. bantiana* cerebral infections. Both show broad antifungal spectrum *in vitro*, including *C. bantiana*, with a very good oral bioavailability, high volume distribution and high tissue concentration including the CNS [21]. Successful treatment of *C. bantiana* cerebral infections with both compounds has been reported recently [22,23]. The most common side effects reported with voriconazole are transient visual disturbances and liver toxicity [24]. Posaconazole is also very active, both *in vitro* and *in vivo*, in other human fungal infections such as aspergillosis or zygomycosis [15,21,25]. Efficacy of posaconazole was shown to be superior to itraconazole or amphotericin B in a recent mouse model of *C. bantiana* infection [26]. Posaconazole could be considered as an alternative to voriconazole in cases of pre-existing liver disease or side effects during treatment as occurred in our patient. The case reported herein showed a rapid reduction in liver enzymes after a switch from voriconazole to posaconazole treatment and signs of radiological improvement following posaconazole introduction that were not observed during voriconazole treatment. Other new antifungals are the echinocandins, of which three are currently available, i.e., caspofungin, micafungin, and anidulafungin. They have limited toxicity profiles and minimal drug-drug interactions. Unfortunately, black molds are less susceptible to them.

New antifungal drugs such as voriconazole or posaconazole will probably lead to an improvement

of the prognosis of cerebral fungal abscesses but it should be kept in mind that, whenever possible, neurosurgical radical removal of the abscess is currently the treatment of choice and its role will probably not change despite new compounds.

Conclusions

Although rare, *C. bantiana* is frequently associated with CNS abscesses. However, other rare fungal etiologic agents should not be excluded from the diagnosis even in the immunocompetent host. Biopsy and microscopic observations, along with microbiological studies for bacteria, mycobacteria and fungi should always be performed to confirm the diagnosis in cases of evolving intracerebral mass lesions. A multidisciplinary approach among neurosurgeons, infectious disease specialists and microbiologists is mandatory in all cases of rare cerebral fungal disease in order to correctly interpret test results and optimize antifungal therapy. The latter is rendered difficult because of the rarity of such diseases, difficulties in extrapolating drug efficacy from *in vitro* susceptibility testing, availability of several new potent drugs, experience in adverse events and drug-drug interactions. Promising new therapies are currently available and additional studies will confirm soon if their introduction into clinical practice will really translate into improved survival. Despite the often fatal outcome, we encourage clinicians to consider newer therapeutic approaches for these life-threatening infections when resection is not possible.

Acknowledgements

We are grateful to Kalthum Bouchuigui-Waf for her microbiological support.

References

- 1 White TJ, Bruns T, Lee S, Taylor J. Amplification and direct sequencing of fungal ribosomal RNA genes for phylogenetics. In: Innis MA, Gelfand DH, Sninsky JJ, White TJ (eds). *PCR Protocols: a Guide to Methods and Applications*. San Diego (CA): Academic Press, 1990: 312–322.
- 2 Revankar SG, Sutton DA, Rinaldi MG. Primary central nervous system phaeohyphomycosis: a review of 101 cases. *Clin Inf Dis* 2004; **38**: 206–216.
- 3 Rossmann SN, Cernoch PL, Davis JR. Dematiaceous fungi are an increasing cause of human disease. *Clin Inf Dis* 1996; **22**: 73–80.
- 4 Baddley JW, Salzman D, Pappas PG. Fungal brain abscess in transplant recipients: epidemiologic, microbiologic and clinical features. *Clin Transpl* 2002; **16**: 419–424.
- 5 Banerjee TK, Patwari AK, Dutta R, Anand VK, Chabra A. *Cladosporium bantianum* meningitis in a neonate. *Indian J Pediatr* 2002; **69**: 721–723.

- 6 Fica A, Diaz MC, Luppi M, et al. Unsuccessful treatment with voriconazole of a brain abscess due to *Cladophialophora bantiana*. *Scand J Infect Dis* 2003; **35**: 892–893.
- 7 Freitas A, Pedral-Sampaio DB, Espinheira Nogueira L, et al. *Cladophialophora bantiana* (previously *Cladosporium trichoides*): first report of a case in Brazil. *Braz J Infect Dis* 1997; **1**: 313–316.
- 8 Gupta SK, Manjunath-Prasad KS, Sharma BS, et al. Brain abscess in renal transplant recipients: report of three cases. *Surg Neurol* 1997; **48**: 284–287.
- 9 Kantarcioglu AS, Hoog GS. Infections of the central nervous system by melanized fungi: a review of cases presented between 1999 and 2004. *Mycoses* 2004; **47**: 4–13.
- 10 Keyser A, Schmid FX, Linde HJ, Merk J, Birnbaum DE. Disseminated *Cladophialophora bantiana* infection in a heart transplant recipient. *J Heart Lung Transplant* 2002; **21**: 503–505.
- 11 Raut A, Muzumdar D, Narlawar R, et al. Cerebral abscess caused by *Cladosporium bantianum* infection. *Neurol Med Chir (Tokyo)* 2003; **43**: 413–415.
- 12 Silveira ER, Resende MA, Mariano VS, et al. Brain abscess caused by *Cladophialophora (Xylohypha) bantiana* in a renal transplant patient. *Transpl Infect Dis* 2003; **5**: 104–107.
- 13 Vyas MC, Joshi YR, Bhargava N, Joshi KR, Tanwar RK. Cerebral chromoblastomycosis – a rare case report of cerebral abscess and brief review of the literature – a case report. *Indian J Pathol Microbiol* 2000; **43**: 81–85.
- 14 Lee YM, Tambyah PA, Lee KH, Tan KC, Lim SG. Successful treatment of *Xylohypha bantiana* brain abscess mimicking invasive cerebral aspergillosis in a liver transplant recipient. *J Infect* 2003; **47**: 348–351.
- 15 Levin TP, Baty DE, Fekete T, Truant AL, Suh B. *Cladophialophora bantiana* brain abscess in a solid-organ transplant recipient: case report and review of the literature. *J Clin Microbiol* 2004; **42**: 4374–4378.
- 16 Roche M, Redmond RM, O'Neill S, Smyth E. A case of multiple cerebral abscesses due to infection with *Cladophialophora bantiana*. *J Infect* 2005; **51**: e285–288.
- 17 Hakyemez B, Erdogan C, Yildirim N, Parlak M. Glioblastoma multiforme with atypical diffusion-weighted MR findings. *Br J Radiol* 2005; **78**: 989–992.
- 18 Mamelak AN, Mampalam TJ, Obana WG, Rosenblum ML. Improved management of multiple brain abscesses: a combined surgical and medical approach. *Neurosurgery* 1995; **36**: 76–86.
- 19 Collette N, Van der Auwera P, Meunier F, et al. Tissue distribution and bioactivity of amphotericin B administered in liposomes to cancer patients. *J Antimicrob Chemother* 1991; **27**: 535–548.
- 20 Como JA, Dismukes WE. Oral azole drugs as systemic antifungal therapy. *N Engl J Med* 1994; **330**: 263–272.
- 21 Greenberg RN, Mullane K, van Burik JAH, et al. Posaconazole as salvage therapy for zygomycosis. *Antimicrob Agents Chemother* 2006; **50**: 126–133.
- 22 Al-Abdely HM, Alkhunaizi AM, Al-Tawfiq JA, et al. Successful therapy of cerebral phaeohyphomycosis due to *Ramichloridium mackenziei* with the new triazole posaconazole. *Med Mycol* 2005; **43**: 91–95.
- 23 Lyons MK, Blair JE, Leslie KO. Successful treatment with voriconazole of fungal cerebral abscess due to *Cladophialophora bantiana*. *Clin Neurol Neurosurg* 2005; **107**: 532–534.
- 24 Herbrecht R, Denning DW, Patterson TF, et al. Invasive Fungal Infections Group of the European Organisation for Research and Treatment of Cancer and the Global *Aspergillus* Study Group. Voriconazole versus amphotericin B for primary therapy of invasive aspergillosis. *N Engl J Med* 2002; **347**: 408–415.
- 25 Walsh TJ, Raad I, Patterson TF, et al. Treatment of invasive aspergillosis with posaconazole in patients who are refractory to or intolerant of conventional therapy: an externally controlled trial. *Clin Infect Dis* 2007; **44**: 2–12.
- 26 Al-Abdely HM, Najvar LK, Bocanegra R, Graybill JR. Antifungal therapy of experimental cerebral phaeohyphomycosis due to *Cladophialophora bantiana*. *Antimicrob Agents Chemother* 2005; **49**: 1701–1707.

This paper was first published online on iFirst on 5 March 2008.