

- [7] Hagl C, Khaladj N, Karck M, Kallenbach K, Leyh R, Winterhalter M *et al.* Hypothermic circulatory arrest during ascending and aortic arch surgery: the theoretical impact of different cerebral perfusion techniques and other methods of cerebral protection. *Eur J Cardiothorac Surg* 2003;24:371–8.
- [8] Khaladj N, Shrestha M, Meck S, Peterss S, Kamiya H, Kallenbach K *et al.* Hypothermic circulatory arrest with selective antegrade cerebral perfusion in ascending aortic and aortic arch surgery: a risk factor analysis for adverse outcome in 501 patients. *J Thorac Cardiovasc Surg* 2008;135:908–14.
- [9] Shrestha M, Khaladj N, Baraki H, Al Ahmad A, Koigeldiyev N, Pichlmaier M *et al.* Aortic root reoperation: a technical challenge. *J Heart Valve Dis* 2010;19:177–81.
- [10] Bisdas T, Bredt M, Pichlmaier M, Aper T, Wilhelmi M, Bisdas S *et al.* Eight-year experience with cryopreserved arterial homografts for the *in situ* reconstruction of abdominal aortic infections. *J Vasc Surg* 2010;52:323–30.
- [11] Aavik A, Lieberg J, Kals J, Pulges A, Kals M, Lepner U. Ten years experience of treating aorto-femoral bypass graft infection with venous allografts. *Eur J Vasc Endovasc Surg* 2008;36:432–7.
- [12] Bisdas T, Wilhelmi M, Haverich A, Teebken OE. Cryopreserved arterial homografts vs silver-coated Dacron grafts for abdominal aortic infections with intraoperative evidence of microorganisms. *J Vasc Surg* 2011;53:1274–81 e1274.
- [13] Leyh RG, Knobloch K, Hagl C, Ruhparwar A, Fischer S, Kofidis T *et al.* Replacement of the aortic root for acute prosthetic valve endocarditis: prosthetic composite versus aortic allograft root replacement. *J Thorac Cardiovasc Surg* 2004;127:1416–20.
- [14] Musci M, Weng Y, Hubler M, Amiri A, Pasic M, Kosky S *et al.* Homograft aortic root replacement in native or prosthetic active infective endocarditis: twenty-year single-center experience. *J Thorac Cardiovasc Surg* 2010;139:665–73.
- [15] Litzler PY, Thomas P, Danielou E, Lucq J, Jacques B, Frebourg N *et al.* Bacterial resistance of refrigerated and cryopreserved aortic allografts in an experimental virulent infection model. *J Vasc Surg* 1999;29:1090–6.
- [16] McCready RA, Bryant MA, Divilbiss JL, Chess BA, Chitwood RW, Paget DS. Arterial infections in the new millennium: an old problem revisited. *Ann Vasc Surg* 2006;20:590–5.
- [17] Gomez-Caro A, Martinez E, Rodriguez A, Sanchez D, Martorell J, Gimferrer JM *et al.* Cryopreserved arterial allograft reconstruction after excision of thoracic malignancies. *Ann Thorac Surg* 2008;86:1753–61; discussion 1761.
- [18] Teebken OE, Pichlmaier MA, Brand S, Haverich A. Cryopreserved arterial allografts for *in situ* reconstruction of infected arterial vessels. *Eur J Vasc Endovasc Surg* 2004;27:597–602.
- [19] Wilhelmi MH, Teebken OE, Pichlmaier MA, Haverich A. High resolution computed tomography imaging for individualized allograft replacement of an infected Dacron aortic arch prosthesis. *Interact CardioVasc Thorac Surg* 2008;7:720–1.
- [20] Wasselius J, Malmstedt J, Kalin B, Larsson S, Sundin A, Hedin U *et al.* High <sup>18</sup>F-FDG uptake in synthetic aortic vascular grafts on PET/CT in symptomatic and asymptomatic patients. *J Nucl Med* 2008;49:1601–5.
- [21] Pichlmaier M, Knigina L, Kutschka I, Bara C, Oswald H, Klein G *et al.* Complete removal as a routine treatment for any cardiovascular implantable electronic device-associated infection. *J Thorac Cardiovasc Surg* 2011;142:1482–90.
- [22] Bisdas T, Beckmann E, Marsch G, Burgwitz K, Wilhelmi M, Kuehn C *et al.* Prevention of vascular graft infections with antibiotic graft impregnation prior to implantation: *in vitro* comparison between daptomycin, rifampin and nebacetin. *Eur J Vasc Endovasc Surg* 2012;43:448–56.
- [23] Mashqi B, Marsch G, Shrestha M, Graf K, Stiesch M, Chaberny IF *et al.* Antibiotic pretreatment of heart valve prostheses to prevent early prosthetic valve endocarditis. *J Heart Valve Dis* 2011;20:582–6.
- [24] Wilhelmi MH, Bara C, Kofidis T, Wilhelmi M, Pichlmaier M, Haverich A. Long-term cardiac allograft valves after heart transplant are functionally and structurally preserved, in contrast to homografts and bioprostheses. *J Heart Valve Dis* 2006;15:777–82.
- [25] Cebotari S, Tudorache I, Ciubotaru A, Boethig D, Sarikouch S, Goerler A *et al.* Use of fresh decellularized allografts for pulmonary valve replacement may reduce the reoperation rate in children and young adults: early report. *Circulation* 2011;124:S115–23.

European Journal of Cardio-Thoracic Surgery 43 (2013) 1175–1176  
doi:10.1093/ejcts/ezs621 Advance Access publication 7 January 2013

EDITORIAL COMMENT

## Re: Cryopreserved human allografts (homografts) for the management of graft infections in the ascending aortic position extending to the arch

Thierry Carrel\*, Martin Czerny and Jürg Schmidli

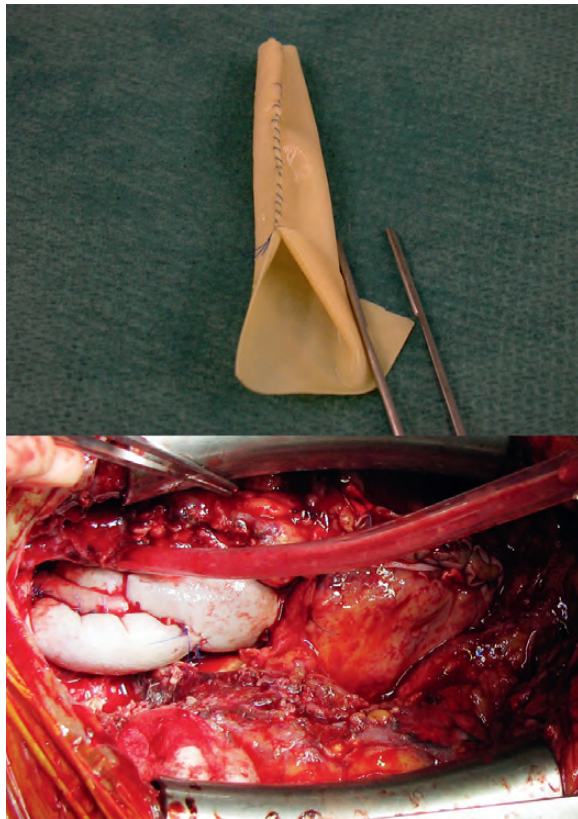
Clinic for Cardiovascular Surgery, University Hospital Berne, Berne, Switzerland

\* Corresponding author. Clinic for Cardiovascular Surgery, University Hospital Berne, Freiburgstrasse, 3010 Berne, Switzerland. Tel: +41-31-6322375; fax: +41-31-6324443; e-mail: thierry.carrel@insel.ch (T. Carrel).

**Keywords:** Thoracic aorta • Thoraco-abdominal aorta • Graft infection • Endograft infection • Surgical treatment • Antibiotic treatment

Infection of a vascular prosthesis or endovascular stent graft is probably the most serious complication that may occur after replacement of the aortic root and aortic arch and dramatically affects the patient's outcome. Surgical treatment is always required as long as the patient is operable, but early and

mid-term morbidities remain significant even following a technically successful repair. Complete resection of the infected foreign material with debridement of the surrounding tissue has been increasingly accepted as the best option and most probably gives the better results. Orthotopic reconstruction is the



**Figure 1:** Reconstruction of the ascending aorta, the aortic arch as well as the innominate artery and the left common carotid artery in a severe recurrent aortic infection, using xenopericardial tube grafts. (Synovis Surgical Innovations, St. Paul, MN, USA; Supple PeriGuard 8 cm × 14 cm). Both illustrations copyright by Elsevier [2, 4].

best strategy for all thoracic and thoraco-abdominal pathologies and the use of biomaterial–homografts or self-made vascular tubes from xenopericardial tissue—is the most accepted technique in the literature. In some exceptional situations, endovascular stent graft can be performed as bridging to a more complete treatment if the general condition of the patient has to be stabilized, but introduction of more foreign material is usually not a wise decision in a complex aortic graft infection.

The series reported in the present issue of European Journal of Cardiothoracic Surgery summarizes the experience of the Hannover Medical School with a limited number of patients who presented with infected aortic root and ascending and aortic arch graft prostheses following different procedures, but all involving at least the proximal aortic arch [1]. The strategy was uniform in all patients, and surgery was complicated by substantial early mortality (24%) and early and mid-term morbidity: in 1 patient, very early degeneration of the homograft valve occurred after 16 months only. In this critical context, it is questionable if re-replacement with another homograft was the best possible treatment. At least if the patient was not infected at 3rd operation, a more durable solution might have been discussed.

In cases where the full aortic arch had to be replaced, the authors proceeded with a proximal to distal repair, starting the procedure at the aortic root and performing the most distal anastomosis (which is the most difficult one) at the end. This might have required a prolonged perfusion to rewarm the patient and made the anastomosis technically more demanding;

in fact, the authors report some uncontrollable bleeding that required additional stent coverage of the anastomosis in the next few days. Introducing prosthetic material (the endovascular stent graft) in an infectious setting is not optimal.

Personally, we are not sure that a proceeding like this would have any advantages: the authors claim that this helped to save an additional suture line that might have had the potential of bleeding or later degeneration. Performing the distal anastomosis first allows a better visualization of the operative site and has the additional advantage that rewarming can be started immediately thereafter: this helps to shorten perfusion times considerably and may have a positive effect on haemostasis.

In addition to graft and/or endovascular graft excision, we agree that debridement of all inflammatory tissues and appropriate drainage of the prosthetic bed are important principles to prevent persistence of the infection process. In some instances, vacuum-assisted wound drainage and delayed sternal closure may be an interesting option to sterilize the operative site.

Recently, we summarized our experience with vascular graft and endograft infections in the thoracic and thoraco-abdominal aortic location over the last 5-year period (2006–10) that were treated with a self-constructed xenopericardial vascular tube graft [2]. Fifteen patients with graft infection after prior thoracic or abdominal aortic replacement were treated with complete removal of the infected alloplastic material, extensive local debridement and orthotopic vascular reconstruction by one or more neo-aortic segments constructed with a bovine pericardial patch. Perioperative mortality was similar to that described in the present series 27% ( $n = 4$ ). All deaths were due to multiorgan failure as sequelae of the underlying infective process. The mean follow-up is now 36 months and CT scans has shown regular regional findings at the operative site in all patients. Freedom from reinfection was 100%; under continued antibiotic treatment for a mean of 6 months. Following hospital discharge, freedom from reoperation was also 100%. Some additional cases were recently published in the Multimedia Manual of Cardiothoracic Surgery to add some practical issues when dealing with such a pathology [3]. The most interesting points of self-constructed xenopericardial vascular grafts are (i) that the material is always available (in contrary to homografts), and (ii) that the size and the length of the aortic segment and/or supraaortic branches to be reconstructed can be chosen accordingly, from 8 mm to approximately 25 mm. The picture shows a case where not only the ascending aorta and the arch had to be replaced, but also the innominate artery and the left common carotid artery [4] (Fig. 1).

## REFERENCES

- [1] Khaladj N, Pichlmaier U, Stachmann A, Peterss S, Reichelt A, Hagl C *et al.* Cryopreserved human allografts (homografts) for the management of graft infections in ascending aortic position extending to the arch. *Eur J Cardiothorac Surg* 2013;43:1189–94.
- [2] Czerny M, von Allmen R, Opfermann P, Sodeck G, Dick F, Stellmes A *et al.* A new conceptual surgical approach in treatment graft infections after surgery or endovascular grafting for thoracic and abdominal aortic pathologies. *Ann Thorac Surg* 2011;92:1657–62.
- [3] Carrel T, Schmidli J. Management of vascular graft and endoprosthetic infection of the thoracic and thoraco-abdominal aorta. Experience with 15 cases. *MMCTS* 2011; doi: 10.1510/mmcts.2010.004705.
- [4] Carrel T, Czerny M, Reineke D. Huge ruptured and infected pseudoaneurysm of the ascending aorta and aortic arch with erosion of sternum after previous cardiac surgery. *Semin Thorac Cardiovasc Surg* 2012;24:229–31.