

## Polyclonal Proliferation of Large Granular Lymphocytes during Cytomegalovirus Primary Infection in a Human Immunodeficiency Virus–Infected Patient Receiving Antiretroviral Therapy

Andreas Kronenberg,<sup>1</sup> Jörg D. Seebach,<sup>2</sup> Walter Bossart,<sup>3</sup> and Rainer Weber<sup>1</sup>

<sup>1</sup>Division of Infectious Diseases and Hospital Epidemiology and <sup>2</sup>Laboratory for Transplantation Immunology, Department of Internal Medicine, University Hospital of Zürich, and <sup>3</sup>Institute of Clinical Virology, University of Zürich

**We report the first case of a patient infected with HIV in whom polyclonal CD8<sup>+</sup>/CD57<sup>-</sup> T lymphocyte large granular lymphocyte (LGL) proliferation was observed in association with cytomegalovirus primary infection. Because the differential diagnosis of an increased number of LGLs includes both monoclonal LGL leukemia and polyclonal proliferation of LGL, patients in whom LGL proliferation is detected always need close hematological and clinical observation to determine whether therapeutic intervention is necessary.**

In HIV-infected individuals who are receiving potent antiretroviral therapy, opportunistic infections may manifest atypically. Here we describe the case of a patient who presented with clinical and hematological features strongly resembling malignant lymphoma while suffering from acute cytomegalovirus (CMV) infection.

**Case report.** A 33-year-old HIV-positive homosexual man presented with fever and mild symptoms that included headache, arthralgias, malaise, night sweats, cough, and diarrhea that had lasted for 3 weeks. His medical history included *Can-*

*didia* stomatitis, amoebiasis with liver abscess, intestinal *Giardia lamblia* infection, and recurrent perianal condylomata acuminata. Oral anticoagulant therapy had been initiated 6 years earlier following vena cava thrombosis and pulmonary embolisms that were associated with elevated levels of plasminogen activator inhibitor and antiphospholipid antibodies. He had been receiving antiretroviral therapy for 10 years. His current medication included stavudine, lamivudine, nelfinavir, and efavirenz.

The patient's HIV-1 RNA load was 340 copies/mL. One month before the onset of the acute illness, the total peripheral blood lymphocyte count was 2004 cells/ $\mu$ L (CD4<sup>+</sup>, 575 cells/ $\mu$ L [29% of total lymphocytes]; and CD8<sup>+</sup>, 697 cells/ $\mu$ L [34%]; CD4<sup>+</sup>:CD8<sup>+</sup> ratio, 0.8). A physical examination revealed a body temperature of 37.8°C, but other clinical findings were unremarkable. A computer scan of the thorax and abdomen appeared normal except for mild splenomegaly (length of sagittal axis, 16 cm). The patient's LDH level was 858 U/L, and CRP level was 26 mg/L. The prothrombin time was prolonged while he was receiving anticoagulant therapy (international normalized ratio, 1.5), but serum levels of electrolytes and markers of liver and kidney function were in the normal range. The WBC count was 9390 cells/ $\mu$ L, and the lymphocyte count was 5420 cells/ $\mu$ L (57.7% of WBC count). The thrombocyte count was 139,000 cells/ $\mu$ L, and the hematocrit was in the normal range.

A scattergram produced by an automatic cell counter (ADVIA120; Bayer Switzerland) revealed lymphocytosis and elevated levels of large unknown cells (LUC; 2440 cells/ $\mu$ L; 23.8% of WBCs; figure 1A); therefore, microscopic examination of a peripheral blood smear was performed. It revealed that 33% of the patient's lymphocytes were LGL (figure 1B). Immunophenotypical analysis of peripheral blood mononuclear cells (PBMC) by means of flow cytometry revealed that a majority of CD3<sup>+</sup>/TCR $\alpha\beta$ <sup>+</sup> T cells (77.2% of PBMC) coexpressed CD8 (3319 cells/ $\mu$ L; 47.9% of PBMC), whereas only a minority of the cells expressed CD4 (603 cells/ $\mu$ L; 8.7% of PBMC), CD57 (6.3% of PBMC), or natural killer (NK) cell markers, including CD16 (8.2% of PBMC) and CD56 (11.0% of PBMC). This corresponded to markedly reduced CD4<sup>+</sup>:CD8<sup>+</sup> ratio of 0.2. Furthermore, the activation markers CD25 (12.5% of PBMC) and CD69 (19.3% of PBMC) were present on a subset of PBMC.

Clonal T cell proliferation was ruled out by the results of a Southern blot analysis of the TCR rearrangement in PBMC, and a bone marrow biopsy specimen did not show evidence of infiltrative lymphoma. Serological analysis revealed seroconversion, with newly detectable anti-CMV IgM and IgG anti-

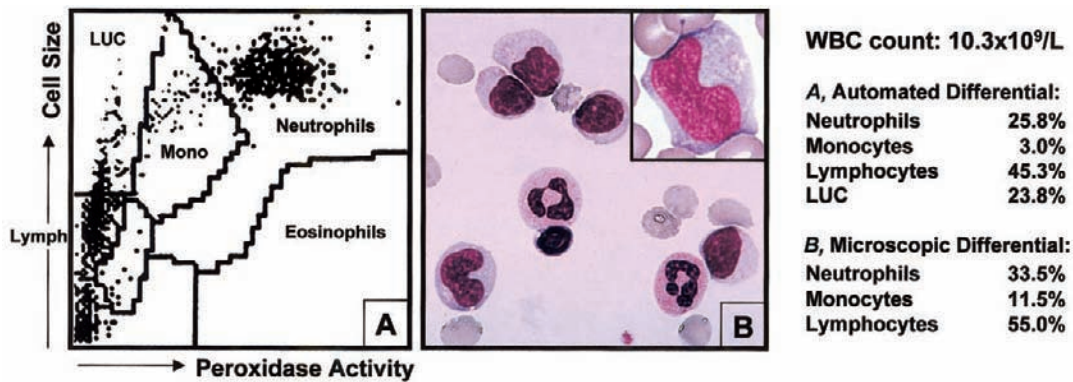
Received 30 October 2000; revised 23 February 2001; electronically published 30 July 2001.

Financial support: J.D.S. is a recipient of a Swiss Clinicians Opting for Research (SCORE) award from the Swiss National Science Foundation.

Reprints or correspondence: Dr. Rainer Weber, Division of Infectious Disease and Hospital Epidemiology University Hospital, CH-8091 Zürich, Switzerland (infweb@usz.unizh.ch), or Dr. Andreas Kronenberg, same address (andreas.kronenberg@dim.usz.ch).

**Clinical Infectious Diseases** 2001;33:e34–6

© 2001 by the Infectious Diseases Society of America. All rights reserved.  
1058-4838/2001/3305-00E4\$03.00



**Figure 1.** Automated and microscopic WBC counts and differential counts for an HIV-positive patient with an increase in the number of large granular lymphocytes (LGL) in response to cytomegalovirus infection. *A*, Scattergram of WBC generated by an automated hemocytometer by cell size (*Y*-axis) and peroxidase activity (*X*-axis). The increase in the number of large unknown cells (LUC) in the upper left field indicates the presence of LGL. *B*, Papanheim-stained blood smear of WBC concentrate with several LGL compared with normal neutrophils. The inset shows the typical morphology of large granular lymphocytes, which are characterized by a large, irregular shaped nucleus and azurophilic granules (original magnification,  $\times 400$ ; inset,  $\times 1000$ ).

bodies. Levels of CMV-specific antibodies were determined by use of commercial ELISA systems (IgG: VIDAS, bioMérieux; IgM: MEDAC). Antibody titers, which were determined in 4 consecutive serum samples obtained during a period of roughly 6 months, were as follows: for IgG, 0, 18, 30, and 48 arbitrary units/mL; and for IgM, indexes (i.e., signal over background ratio) of 0.1, 14.1, 6.8, and 0.9.

CMV was isolated from shell-vial cultures of specimens of MRC-5 human fibroblasts and was confirmed by means of immunofluorescence assay (monoclonal antibody MicroTrak; Behring) and PCR (with use of primers and PCR protocol as described in [1]). No evidence was found of other acute bacterial or viral infections, including herpes simplex virus 1 and 2, Epstein-Barr virus, and human herpesvirus 6 or human herpesvirus 8.

Lymphocytosis and elevated LUC levels normalized without specific therapy in  $<1$  week, and the patient became asymptomatic during the following weeks. After 1 year of follow-up, slightly elevated CD8<sup>+</sup> counts of 1000–1200 cells/ $\mu$ L were found, which were associated with CD4<sup>+</sup> counts of 600–750/ $\mu$ L. At that time, 54.5% of the patient's CD8<sup>+</sup> cells (554 cells/ $\mu$ L) coexpressed the CD57 marker.

**Discussion.** LGL are a morphologically recognizable subset of lymphocytes, comprising 10%–15% of normal PBMC. Differential diagnosis of an increased number of LGL includes monoclonal LGL leukemia and polyclonal proliferation of LGL [2, 3]. Monoclonal LGL leukemia is thought to develop from an initially antigen-driven specific response and is further divided into 2 phenotypical subgroups. (1) The first of these is the more common CD3<sup>+</sup> T-LGL leukemia, which manifests as a chronic disorder associated with the following: systemic symptoms, such as fever, night sweats, and/or weight loss; sple-

nohepatomegaly; autoimmune diseases, such as rheumatoid arthritis; and neutropenia, which is likely to be induced by soluble Fas ligand molecules and can lead to recurrent bacterial infections. (2) The second phenotypical subgroup is the rare but clinically more aggressive CD3<sup>-</sup> NK-LGL leukemia. In contrast to frank leukemia, polyclonal LGL proliferations are usually benign and self-limited. They occur in patients with a variety of clinical disorders, including solid tumors, idiopathic thrombocytopenic purpura, Hodgkin's and non-Hodgkin's lymphoma, and viral infections. Overall, the finding of elevated numbers of LGL in a blood smear, even in the absence of peripheral blood lymphocytosis [4], warrants further diagnostic evaluation for the presence of LGL leukemia or the underlying cause of LGL proliferation.

In our patient, CD8<sup>+</sup>/CD57<sup>-</sup> LGL proliferation was associated with both long-standing HIV infection and acute CMV infection, both of which may have been responsible for the observed proliferation. The CD8 coreceptor recognizes MHC class I molecules and is associated with cytotoxic T lymphocytes, proliferation of which is induced by viral infections. In contrast, much less is known about the function and significance of the CD57 glycoprotein, which can be expressed by subsets of both NK cells and T cells. Only recently, the coexpression by CD8<sup>+</sup> T cells of CD57, which are found in a variety of diseases including viral infections, has become a focus of interest [5]. It has been shown that CMV infection can induce a self-limited increase of CD8<sup>+</sup>/CD57<sup>-</sup> granular T cells in immunocompetent hosts. A rapid increase of CD8<sup>+</sup>/CD57<sup>-</sup> T cells was also observed during the first week of CMV infection in solid organ transplant recipients who were receiving immunosuppressive therapy [6]. In a majority (12 of 16) of these patients the absolute number of CD8<sup>+</sup> T cells remained elevated

for  $\leq 4$  years, with a progressive replacement of the initial polyclonal CD8<sup>+</sup>/CD57<sup>-</sup> T lymphocytes by CD8<sup>+</sup>/CD57<sup>+</sup> cells [6]. Other studies have described 3 patients with monoclonal proliferations of CD8<sup>+</sup>/CD57<sup>+</sup> T LGLs after kidney transplantation in the absence of ongoing active CMV infection or any other viral disease [7, 8]. Two of these patients had suffered from acute CMV infection early after transplantation, suggesting a transformation from CMV-induced polyclonal to monoclonal proliferation of CD8<sup>+</sup>/CD57<sup>+</sup> T lymphocytes [7]. All 3 patients had a clinically indolent course, which is in sharp contrast to the course of posttransplantation lymphoproliferative disease caused by CD8<sup>+</sup>/CD56<sup>+</sup>/CD57<sup>-</sup> T-LGL leukemia [8].

CMV infection or reactivation frequently occurs during the first 3 months after allogeneic bone marrow transplantation and leads to a strong polyclonal stimulation of CD8<sup>+</sup>/CD57<sup>+</sup> T cells. This immunological response, which occurs during immunosuppressive therapy, provides protection from CMV disease and, interestingly, seems to be associated with both graft-versus-leukemia activity and a low incidence of relapse of leukemia in recipients of T cell-depleted bone marrow [9].

On the other hand, early HIV infection may induce an increase in the number of CD8<sup>+</sup> T cells. Rarely, CD8<sup>+</sup> lymphocytosis syndrome may develop, or a diffuse infiltrative lymphocytosis syndrome, which is characterized by the sequestration of CD8<sup>+</sup> T cells in the salivary glands, lungs, kidneys, and other visceral sites [10]. The absolute increase of CD8<sup>+</sup> lymphocytes is thought to represent an immune response to HIV-related antigens, and it has been demonstrated that these CD8<sup>+</sup> T cells have functional activity against HIV.

Smith et al. [10] found that lymphoproliferation was monoclonal in 5 out of 18 patients with CD8<sup>+</sup> lymphocytosis who were examined. Nevertheless, the clinical course was benign, indicating that the change to monoclonal lymphoproliferation is not necessarily associated with clinical malignancy. Moreover, proliferation of morphologically atypical CD8<sup>+</sup> lymphocytes has been described in cases of acute coinfection with HIV and CMV [11, 12]. However, in most of these cases, the CD57 phenotype, TCR rearrangement, and the presence or absence of LGL were not determined [12]. Only 2 cases of benign LGL proliferation have been described in HIV-infected patients: CD3<sup>-</sup>/CD8<sup>-</sup> NK-LGL proliferation in one [13], and monoclonal CD3<sup>+</sup>/CD8<sup>+</sup>/CD57<sup>+</sup> T-LGL proliferation in the other [14]. It is not clear whether these cases of proliferation were associated with CMV infection because CMV detection by means of antigen-detection or positive PCR results was not performed.

Because LGL proliferation was not present in our patient prior to CMV-infection, we strongly believe that the polyclonal proliferation of CD8<sup>+</sup>/CD57<sup>-</sup> T LGL was induced by acute

CMV infection and not by preexisting HIV infection. Although there was no further treatment, the proliferation had a benign, self-limited clinical course characterized by the emergence of a CD8<sup>+</sup>/CD57<sup>+</sup> population. However, patients in whom LGL proliferation is detected always need close hematological and clinical observation to determine whether therapeutic intervention is necessary.

## Acknowledgments

We wish to thank Mrs. R. Rüegg, for the photographs, U.B. Matter Reissmann, S. Märki, for technical assistance, and Dr. D. Zimmermann, for Southern blot analysis.

## References

1. Khan G, Kangro HO, Coates PJ et al. Inhibitory effects of urine on the polymerase chain reaction for cytomegalovirus DNA. *J Clin Pathol* **1991**;44:360–5.
2. Lamy T, Loughran TP, Jr. Current concepts: large granular lymphocyte leukemia. *Blood Rev* **1999**;13:230–40.
3. Zambello R, Semenzato G. Large granular lymphocytosis. *Haematologica* **1998**;83:936–42.
4. Seebach J, Schleiffenbaum B, Ruegg R et al. Epinephrine test and plasma elastase as diagnostic tools in a patient with CD3<sup>+</sup> large granular lymphocyte proliferation. *Br J Haematol* **1995**;89:630–2.
5. Wang EC, Borysiewicz LK. The role of CD8<sup>+</sup>, CD57<sup>+</sup> cells in human cytomegalovirus and other viral infections. *Scand J Infect Dis Suppl* **1995**;99:69–77.
6. Labalette M, Salez F, Pruvot FR et al. CD8 lymphocytosis in primary cytomegalovirus (CMV) infection of allograft recipients: expansion of an uncommon CD8<sup>+</sup>. *Clin Exp Immunol* **1994**;95:465–71.
7. Gentile TC, Hadlock KG, Uner AH et al. Large granular lymphocyte leukaemia occurring after renal transplantation. *Br J Haematol* **1998**;101:507–12.
8. Hanson MN, Morrison VA, Peterson BA et al. Posttransplant T-cell lymphoproliferative disorders: an aggressive, late complication of solid-organ transplantation. *Blood* **1996**;88:3626–33.
9. Dolstra H, Preijers F, Wiel-van Kemenade E et al. Expansion of CD8<sup>+</sup>CD57<sup>+</sup> T cells after allogeneic BMT is related with a low incidence of relapse and with cytomegalovirus infection. *Br J Haematol* **1995**;90:300–7.
10. Smith PR, Cavenagh JD, Milne T et al. Benign monoclonal expansion of CD8<sup>+</sup> lymphocytes in HIV infection. *J Clin Pathol* **2000**;53:177–81.
11. Oksenhendler E, Gerrard L, Molina JM et al. Lymphocytosis in primary HIV infection is associated with CMV co-infection. *AIDS* **1993**;7:1023–4.
12. Bonetti A, Weber R, Vogt MW et al. Co-infection with human immunodeficiency virus-type 1 (HIV-1) and cytomegalovirus in two intravenous drug users. *Ann Intern Med* **1989**;111:293–6.
13. Ghali V, Castella A, Louis-Charles A et al. Expansion of large granular lymphocytes (natural killer cells) with limited antigen expression (CD2<sup>+</sup>, CD3<sup>+</sup>, CD4<sup>+</sup>, CD8<sup>-</sup>, CD16<sup>+</sup>, NKH-1<sup>-</sup>) in a human immunodeficiency virus-positive homosexual man. *Cancer* **1990**;65:2243–7.
14. Pulik M, Lionnet F, Genet P et al. CD3<sup>+</sup> CD8<sup>+</sup> CD56<sup>-</sup> clonal large granular lymphocyte leukaemia and HIV infection. *Br J Haematol* **1997**;98:444–5.