

ulated immune responses, possibly occurring in susceptible individuals with a genetic predisposition. Persistent stimulation by cytokines such as IFN- $\gamma$  and TNF- $\alpha$  could promote dietary or autoantigen presentation to T cells and B cells followed by production of specific antibodies. Complexing of antibodies to local or circulating antigens presumably leads to chronic immune complex deposition in the glomerulus, where complement activation could promote hypocomplementaemia. A membranoproliferative pattern of glomerulonephritis usually indicates the presence of a chronic immune stimulus with continuous or episodic levels of circulating immune complexes [15]. In our case, the close temporal association between initiation of a gluten-free diet and the resolution of proteinuria (without use of immunosuppressive therapy and despite tapering of angiotensin enzyme inhibitor) strongly supports an aetiological association. This case illustrates that MPGN may precede overt clinical evidence of CS, via subclinical disease mediated by chronic antigen stimulation. Importantly, CS-associated MPGN can resolve clinically following initiation of gluten-free diet, without resort to immunosuppressive therapy.

*Conflict of interest statement.* None declared.

## References

1. Katz A, Dyck RF, Bear RA. Coeliac disease associated with immune complex glomerulonephritis. *Clin Nephrol* 1979; 11: 39–44
2. Scholey J, Freeman HJ. Coeliac sprue-associated immune complex glomerulonephritis. *J Clin Gastroenterol* 1986; 8: 181–183
3. Booth CC. History of coeliac disease. *Br Med J* 1989; 298: 527
4. Holmes G. Coeliac disease and type 1 diabetes mellitus—the case for screening. *Diabet Med* 2001; 18: 169–177
5. Collin P, Kaukinen K, Välimäki M *et al.* Endocrinological disorders and coeliac disease. *Endocr Rev* 2002; 23: 464–483
6. Kingham J, Parker D. The association between primary biliary cirrhosis and coeliac disease: a study of relative prevalences. *Gut* 1998; 42: 120–122
7. Matteoni C, Goldblum J, Wang N *et al.* Coeliac disease is highly prevalent in lymphocytic colitis. *J Clin Gastroenterol* 2001; 32: 225–227
8. Sugai E, Vazquez H, Nachman F *et al.* Accuracy of testing for antibodies to synthetic gliadin-related peptides in coeliac disease. *Clin Gastroenterol Hepatol* 2006; 4: 1112
9. Kolacek I, Booth I, Taylor C. Food, mucosal immunity and IgA nephropathy. *J Pediatr Gastroenterol Nutr* 1990; 11: 175–178
10. Rostoker G, Delchier J, Chaumette M. Increased intestinal intraepithelial T lymphocytes in primary glomerulonephritis. *Nephrol Dial Transplant* 2001; 16: 513–517
11. Collin P. Coeliac disease and HLA DQ in patients with IgA nephropathy. *Am J Gastroenterol* 2002; 97: 2572–2576
12. Fornasieri A, Sinico R, Maldifassi P *et al.* IgA—antigliadin antibodies in IgA mesangial nephropathy. *Br Med J* 1987; 295: 78–80
13. Coppo R, Amore A, Roccatello D. Dietary antigens and primary immunoglobulin A nephropathy. *J Am Soc Nephrol* 1992; 2: S173–S180
14. Swarbrick ET, Fairclough PD, Campbell PJ *et al.* Coeliac disease, chronic active hepatitis and mesangiocapillary glomerulonephritis in the same patient. *Lancet* 1980; 2: 1804–1805
15. Rennke H. Secondary membranoproliferative glomerulonephritis, nephrology forum. *Kidney Int* 1995; 47: 643–656

*Received for publication: 9.6.09; Accepted in revised form: 25.6.09*

*Nephrol Dial Transplant* (2009) 24: 3548–3551

doi: 10.1093/ndt/gfp377

Advance Access publication 25 July 2009

## Haemolytic uraemic syndrome caused by factor H mutation: is single kidney transplantation under intensive plasmatherapy an option?

Patricia Hirt-Minkowski<sup>1</sup>, Stefan Schaub<sup>1</sup>, Michael Mayr<sup>1</sup>, Jürg A. Schifferli<sup>2</sup>, Michael Dickenmann<sup>1</sup>, Véronique Frémeaux-Bacchi<sup>3</sup> and Jürg Steiger<sup>1</sup>

<sup>1</sup>Division of Transplantation Immunology and Nephrology, <sup>2</sup>Division of Internal Medicine, University Hospital Basel, Basel, Switzerland and <sup>3</sup>Assistance Publique-Hôpitaux de Paris, Department of Biological Immunology, Hôpital Européen Georges Pompidou, Paris, France

*Correspondence and offprint requests to:* Patricia Hirt-Minkowski; E-mail: phirt@uhbs.ch

### Abstract

Complement factor H (CFH) mutation is one of the causes of atypical haemolytic uraemic syndrome (aHUS). Patients with CFH mutation-associated aHUS progress often to end-stage renal disease despite plasma exchange therapy. When such patients are transplanted, aHUS recurs almost invariably and causes graft failure making the rationale of single

kidney allograft transplantation questionable. Since CFH is synthesized mostly by the liver, combined liver–kidney transplantation has been recommended. However, fatal outcomes have been reported using this strategy. We report a case of successful single kidney allograft transplantation in a patient with a CFH gene mutation (R1210C), who had end-stage renal failure after three flares of aHUS treated

with plasma exchange. He received peri- and postoperative infusions of fresh frozen plasma, which to date has prevented recurrence of the disease. He has preserved renal function 1-year post-transplant.

**Keywords:** complement factor H; haemolytic uraemic syndrome; kidney transplantation

## Background

Haemolytic uraemic syndrome (HUS) is a clinical syndrome characterized by microangiopathic haemolytic anaemia, thrombocytopenia and acute renal failure [1]. Paediatric cases are often caused by shiga-like toxin-producing *Escherichia coli*. However, atypical cases may occur with a manifestation at all ages, showing a tendency to relapse, to occur in families and to have a poor outcome (= atypical HUS, aHUS). Recent evidence has indicated that many of such aHUS cases are associated with mutations in proteins of the complement system. Mutations in the complement factor H (CFH) gene account for ~10–30% of cases of familial or recurrent HUS [2–4]. CFH is synthesized mostly by the liver. It is a major regulator of the complement cascade by inactivation of C3b in the fluid phase and on host cells as well [5]. Patients, who have a mutation responsible for a loss of binding of CFH on cell surfaces, are at risk of developing endothelial cell damage when the complement is activated. Plasma exchange therapy or plasma infusions may improve the clinical course of aHUS related to CFH gene mutations, possibly by supplementing large quantities of normal CFH [6]. However, the disease recurs and many patients finally progress to end-stage renal disease (ESRD) after having had several relapses [7].

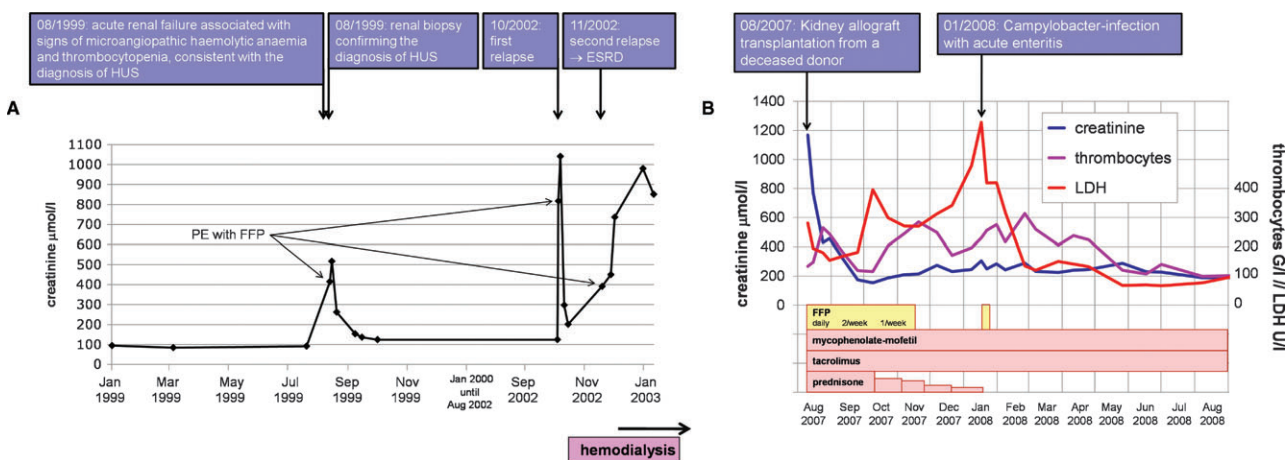
Atypical HUS almost invariably recurs in kidney grafts and causes graft failure, making the rationale of single kidney allograft transplantation questionable [8]. Given that CFH is mostly synthesized by the liver, combined liver–kidney transplantation may correct the complement abnor-

mality associated with mutations in the gene encoding CFH and prevent recurrence of aHUS [9]. Recently, combined liver–kidney transplantation has been recommended as the preferred therapeutic regimen for patients with ESRD due to aHUS associated with mutations in genes encoding complement regulatory proteins such as CFH and complement factor I [10]. However, some fatal outcomes have been reported using this strategy (reviewed in [8]).

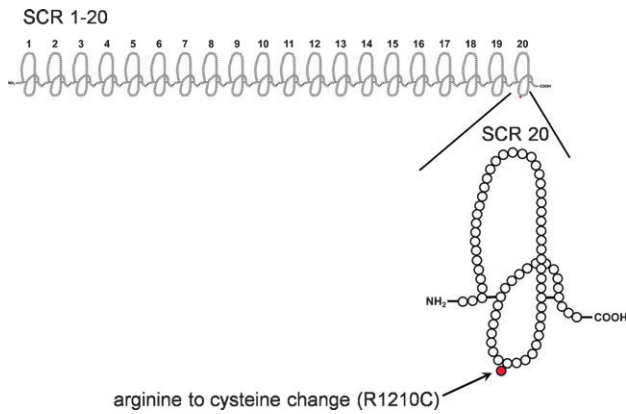
We report a case of successful single kidney allograft transplantation in a patient with aHUS due to a CFH gene mutation treated with multiple infusions of fresh frozen plasma (FFP) peri- and postoperatively.

## Case report

The clinical course before and after transplantation is summarized in Figure 1A and B. On August 1999, following a prolonged upper respiratory tract infection with fever but no diarrhoea, a 23-year-old man developed acute renal failure associated with microangiopathic haemolytic anaemia and thrombocytopenia, consistent with the diagnosis of HUS. He presented with impaired general state of health with asthenia, nausea and loss of appetite. He showed elevated blood pressure, generalized oedema and proteinuria (7 g/day). He was treated with daily plasma exchange therapy (PE), and renal function recovered almost completely with only a slightly elevated serum creatinine level of ~120–150  $\mu\text{mol/l}$  (1.4–1.7 g/dl). A renal biopsy was performed, confirming thrombotic microangiopathy (TMA) in the glomeruli and arterioles. The further clinical course was characterized by two relapses of HUS (one following an atypical pneumonia, the second one without an apparent trigger). Again, daily PE was started. Renal function partly recovered after the first relapse with an elevated serum creatinine level of ~180–220  $\mu\text{mol/l}$  (2.0–2.5 g/dl). But after the second relapse only one month later, the patient remained anuric despite PE, and finally ESRD occurred. Chronic haemodialysis was started in November 2002 (Figure 1A).



**Fig. 1.** Follow-up before (A) and after transplantation (B). PE = plasma exchange therapy. HUS = haemolytic uraemic syndrome.



**Fig. 2.** CFH structure that consists of 20 so-called short consensus repeats (SCR 1–20) arranged in continuous fashion. On the detail of the most C-terminal SCR 20 of CFH, the localization of the point mutation (arginine to cysteine change in position 1210) is shown. CFH = complement factor H.

A comprehensive complement analysis revealed normal complement factor C3, C4, B, I and H serum concentrations and the activity of the von Willebrand factor-cleaving protease (ADAMTS 13) was normal. However, genetic studies disclosed a heterozygous point mutation in the most C-terminal short consensus repeat 20 [translation of arginine to cysteine in amino acid position 1210 (R1210C)] of the CFH gene (Figure 2), which has been previously identified in five pedigrees and seven individual patients with aHUS [11], leading to the diagnosis of functionally deficient CFH (= loss of binding to endothelial cells).

The patient underwent kidney transplantation from a deceased donor in August 2007. To avoid HUS recurrence, peri- and postoperative plasma infusions of FFP containing 45–70 mg blood group-specific proteins/ml were given as follows: 6 ml/kg before anaesthesia, 6 ml/kg before unblocking the perfusion of the organ, then 3 ml/kg every 6 h for 48 h, followed by daily infusions of 3 ml/kg in the first week, twice a week for 1 month and thereafter weekly for another month. Immunosuppressive therapy consisted of triple therapy with tacrolimus, mycophenolate mofetil and prednisone as well as basiliximab on Day 0 and 4.

Five allograft biopsies were performed between Day 5 and Month 10 post-transplant. The first two biopsies were done 5 days and 3 weeks post-transplant due to initial delayed graft function, and both showed histo-morphological signs consistent with acute tubular necrosis. Two protocol biopsies were done at Months 3 and 6 post-transplant, which demonstrated polyoma BK virus-associated nephropathy (i.e. numerous SV40-antigen-positive tubular epithelial cells). Immunosuppressive therapy was continuously reduced and after BK viraemia became negative, the fifth biopsy done 10 months post-transplant confirmed the resolution of polyoma BK virus-associated nephropathy. Importantly, all five allograft biopsies revealed no histological features of TMA.

Furthermore, blood examinations demonstrated no signs consistent with TMA during the follow-up [normal lactate dehydrogenase (LDH), no thrombocytopenia, no schistocytes and normal haptoglobin] with the exception of an el-

evated LDH during an episode of campylobacter enteritis, which was treated with antibiotics and prophylactic administration of FFP. A 1-year follow-up showed stable graft function (Figure 1B).

## Discussion

One year post-transplant, there is no evidence of HUS recurrence after single kidney transplantation in this patient with a CFH gene mutation. However, caution is necessary, and the patient has to be followed closely. Our strategy of preventive plasma infusions may have avoided recurrence of the disease and allowed successful transplantation. Indeed, the kidney endothelial cells are particularly vulnerable immediately after transplantation in patients with aHUS due to CFH and other complement mutations, as ischaemia is a potent trigger of complement activation. We know that aHUS flares were responding to plasma exchange in this patient (probably more to the plasma infusion than to the extraction of the patient's plasma as suggested by Remuzzi *et al.* [6]). We have not continued the infusions of plasma after the second month, and the patient is certainly again at risk for recurrence. Platelets, blood counts and renal function are monitored closely, and any infection is controlled as well.

It is not possible to be certain that plasma infusions prevented an HUS episode, but previous attempts to transplant similar patients have been rather disappointing due to immediate or late recurrence followed by graft loss. For example, Martinez-Barricarte *et al.* [11] reported four patients who had been transplanted, and three of them had a recurrence in the allograft (two within 1 year after transplantation and one patient 27 months after transplantation). A unique case report is not sufficient to change the proposals made recently [10]. However, the strategy used here suggests that combined liver–kidney transplantation is not an absolute requirement for successful transplantation in patients with CFH gene mutations. Furthermore, the humanized monoclonal C5 antibody (eculizumab) might be a promising treatment option for aHUS [12–13], which could also facilitate single kidney transplantation in these patients in the future.

**Acknowledgement.** The authors wish to thank Dr L. Hirt for courtesy of the figures.

**Conflict of interest statement.** None declared.

## References

- Caprioli J, Peng L, Remuzzi G. The hemolytic uremic syndromes. *Curr Opin Crit Care* 2005; 11: 487–492
- Caprioli J, Bettinaglio P, Zipfel PF *et al.* The molecular basis of familial hemolytic uremic syndrome: mutations analysis of factor H gene reveals a hot spot short consensus repeat 20. *J Am Soc Nephrol* 2001; 12: 297–307
- Perez-Caballero D, Gonzalez-Rubio C, Gallardo EM *et al.* Clustering of missense mutations in the C-terminal region of factor H in atypical hemolytic uremic syndrome. *Am J Hum Genet* 2001; 68: 478–484
- Neumann HPH, Salzmann M, Bohnert-Iwan B *et al.* Hemolytic uraemic syndrome and mutations of the factor H gene: a registry

- based study of German speaking countries. *J Med Genet* 2003; 40: 676–681
5. Weiler JM, Daha MR, Austen KF *et al.* Control of the amplification convertase of complement by the plasma protein beta1H. *Proc Natl Acad Sci USA* 1976; 73: 3268–3272
  6. Noris M, Remuzzi G. What not to learn from a meta-analysis. *Nat Rev Nephrol* 2009; 5: 186–188
  7. Caprioli J, Noris M, Brioschi S *et al.* Genetics of HUS: the impact of MCP, CFH, and IF mutations on clinical presentation, response to treatment, and outcome. *Blood* 2006; 108: 1267–1279
  8. Zimmerhackl LB, Scheiring J, Prüfer F *et al.* Renal transplantation in HUS patients with disorders of complement regulation. *Pediatr Nephrol* 2007; 22: 10–16
  9. Remuzzi G, Ruggenenti P, Codazzi D *et al.* Combined kidney and liver transplantation for familial hemolytic syndrome. *Lancet* 2002; 359: 1671–1672
  10. Saland JM, Ruggenenti P, Remuzzi G, and the Consensus Study Group. Liver-kidney transplantation to cure atypical hemolytic uremic syndrome. *J Am Soc Nephrol* 2009; 20: 940–949
  11. Martinez-Barricarte R, Pianetti G, Gautard R *et al.* The complement factor H R1210C mutation is associated with atypical hemolytic uremic syndrome. *J Am Soc Nephrol* 2008; 19: 639–646
  12. Gruppo RA. Eculizumab for congenital atypical hemolytic-uremic syndrome. *N Engl J Med* 2009; 360: 544–546
  13. Nürnberger J, Witzke O, Opazo Saez A *et al.* Eculizumab for atypical hemolytic-uremic syndrome. *N Engl J Med* 2009; 360: 542–544

*Received for publication: 10.5.09; Accepted in revised form: 6.7.09*