

Case report

## Traumatic free wall and ventricular septal rupture – ‘hybrid’ management in a child

Alexander Kadner<sup>a,\*</sup>, Margrit Fasnacht<sup>b</sup>, Oliver Kretschmar<sup>b</sup>, René Prêtre<sup>a</sup>

<sup>a</sup>Division of Congenital Cardiac Surgery, Children’s Hospital, University Zurich, Switzerland

<sup>b</sup>Department of Cardiology, Children’s Hospital, University Zurich, Switzerland

Received 10 September 2006; received in revised form 19 January 2007; accepted 23 January 2007; Available online 6 March 2007

### Abstract

A 8-year-old boy showed a traumatic ventricular septal rupture following a blunt chest trauma, and was scheduled for elective catheter closure. Two weeks later, a follow-up echocardiogram revealed a pseudoaneurysm of the anterior wall of the left ventricle. Because of the apical location of the VSD, it was decided to proceed with transcatheter occlusion. After successful VSD closure, the patient was taken to the operation room for surgical repair of the left ventricular pseudoaneurysm. Symptoms and signs seen in patients with ventricular pseudoaneurysms appear to be discrete and variable, and a high clinical index of suspicion with a very close echocardiographic follow-up is strongly recommended after occurrence of a blunt cardiac trauma. The combined ‘hybrid’ approach of transcatheter closure of the intraventricular rupture followed by surgical closure of the pseudoaneurysm allows for a less invasive and efficient management of this rare combination of post-traumatic ventricular free wall and septal rupture in a child.

© 2007 European Association for Cardio-Thoracic Surgery. Published by Elsevier B.V. All rights reserved.

**Keywords:** Pseudoaneurysm; Traumatic VSD; Chest trauma; Hybrid therapy

### 1. Case report

A 8-year-old boy was admitted with a left-sided blunt chest trauma following a kick by a horse. On arrival, the patient was awake and presented hemodynamically and respiratory stable. Contusions were noted on the anterior left chest, and auscultation revealed a pansystolic cardiac murmur between the third and fifth intercostal spaces at the left-sided sternal border. A computer tomogram showed left-sided pulmonary contusions without any rib fracture or mediastinal pathologies. His electrocardiogram showed a sinus tachycardia with a heart rate of 130 beats/min, elevation of the ST-segments in the leads V1 through V4, and a rise in serum levels of the myocardial-specific isoenzyme of creatine kinase (174 mcg/l), and of troponine (2.83 mcg/l). A two-dimensional transthoracic echocardiogram revealed an apical muscular ventricular septal defect (VSD) of 7–8 mm diameter with a left-to-right shunt. The patient was monitored for 1 day at the ICU and had an uneventful in-hospital course thereafter. He was discharged with an ACE-inhibitor medication after 1 week. The elective

interventional catheter closure of the VSD was scheduled for the following month.

Two weeks later, a follow-up transthoracic echocardiogram revealed the presence of a 23 mm × 12 mm anterior cavity communicating with the left ventricle by a small defect, which was interpreted as a pseudoaneurysm of the anterior free wall of the left ventricle (Fig. 1a). The following cardiac catheterization and transesophageal echocardiogram showed the pseudoaneurysm to be positioned in between the normal appearing left anterior descending and the proximal circumflex coronary artery with an apical localized VSD of 10–11 mm. Because of the apical location of the VSD, it was decided to proceed with transcatheter occlusion with a 12 mm Amplatzer muscular VSD-occluder (Fig. 1b). After successful VSD closure, the patient was directly taken to the operation room for surgical repair of the left ventricular pseudoaneurysm.

Following median sternotomy, cardiopulmonary bypass was established, the ascending aorta was cross-clamped, and the heart was arrested by cold blood cardioplegia. The pseudoaneurysm was noted on the anterior left ventricular free wall in between the proximal left anterior descending and circumflex coronary arteries. An incision was made into the epicardium and the borders of the aneurysm were determined, which appeared thick and fibrous (Fig. 1c). Several small thrombi were removed from the aneurysm cavity. Closure of the aneurysm was performed with two

\* Corresponding author. Address: Division of Congenital Cardiac Surgery, Children’s Hospital, University Zurich, Steinwiesstrasse 75, 8032 Zürich, Switzerland. Tel.: +41 1 266 8020; fax: +41 1 266 8021.

E-mail address: a.kadner@web.de (A. Kadner).

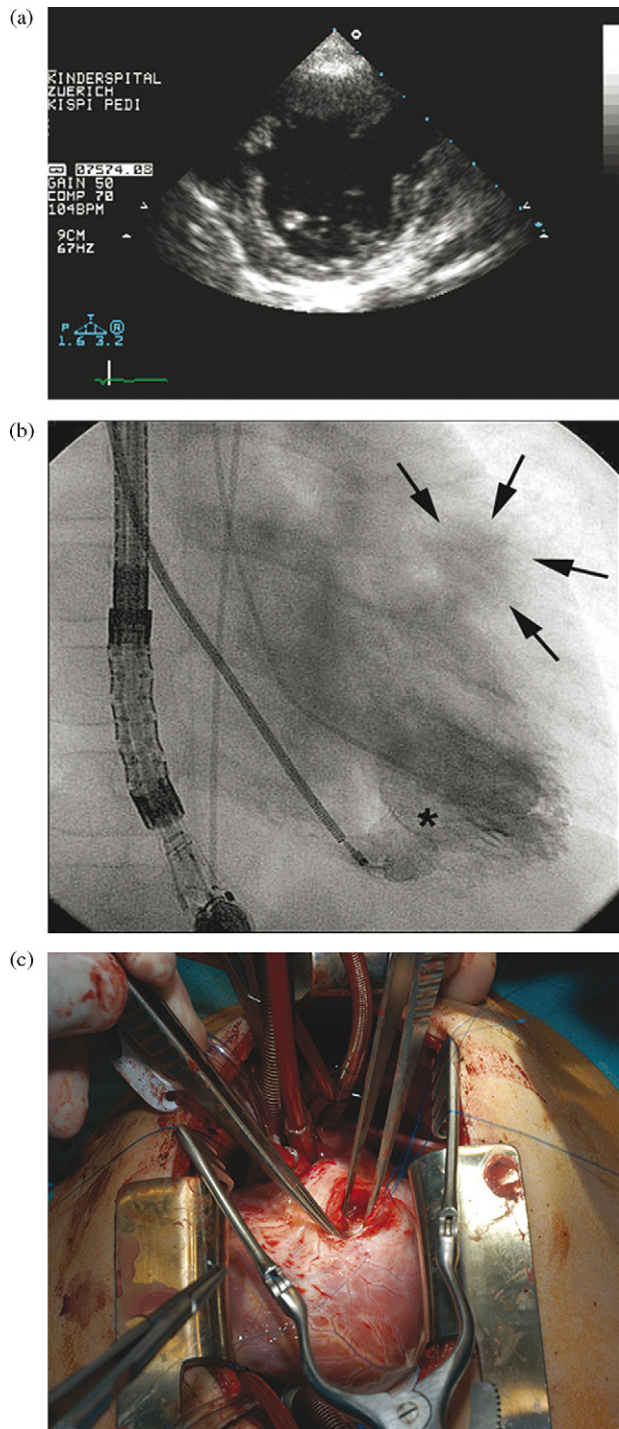


Fig. 1. (a) Parasternal short axis view of 2D-transthoracic echocardiogram revealing the VSD (\*) and the pseudoaneurysm of the LV free wall (arrows). (b) Interventional catheter image showing the placement of the Amplatzer VSD occluder device with an already opened left ventricular disc (\*). The right-sided disc is still mounted on the catheter. (Arrows: pseudoaneurysm of the LV free wall). (c) Intraoperative situs demonstrating the opened pseudoaneurysm cavity prior to layered closure with a running suture.

layers of 5-0 prolene running suture. The epicardium was closed by a 6-0 prolene suture. The patient was easily weaned off bypass; the transesophageal echocardiogram showed no residual communications with achievement of complete closure of the aneurismal cavity.

The postoperative course was uneventful. The patient was extubated on postoperative day 1. Thereafter, he made rapid progress and was discharged from the hospital on postoperative day 8. Four months after his injury, the patient was doing well, and a repeat echocardiogram showed normal left ventricular dimensions and function, no residual segmental hypokinesis, and no residual VSD. There was no evidence of pseudoaneurysm recurrence.

## 2. Comment

Rupture of the ventricular septum is well described following blunt chest trauma [1–3]. The responsible mechanism is assumed to be an anteroposterior compression of the heart between the sternum and the spine during early systole, with the ventricular cavity filled and the atrioventricular valves closed. Location of traumatic VSD is found to be most common in the muscular portion of the interventricular septum near the cardiac apex, and the rupture may occur immediately at the time of injury, as it was the case in our patient, or may be delayed for several days [4]. There can be a wide spectrum in physical presentation, with patients without any chest complaints at all or in clear cardiogenic shock. Our patient presented in a stable condition, and the first diagnostic hint was a characteristic pansystolic murmur at the left sternal border. The ECG was not very specific for determining the diagnosis in this case. Echocardiography has proven to be the most effective screening tool in the acute setting, and in this case also led to the correct and immediate diagnosis of a post-traumatic VSD [5,6].

Management of hemodynamically unstable patients with a large septal rupture consists of inotropic support, left ventricular afterload reduction by medical therapy, as well as placement of an intra-aortic balloon pump. Urgent surgical closure of such VSDs is recommended [1]. In our case, the patient did not show any signs of hemodynamical instability. The traumatic muscular VSD was 7–8 mm large, and it was decided to schedule the interventional transcatheter closure of this defect in the subsequent weeks.

Frequently, patients with a traumatic VSD are likely to suffer from concomitant intrathoracic injuries such as rib fractures, hemothorax, aortic disruption, as well as intracardiac lesions like myocardial contusion and infarction, valve injuries, and coronary artery lesions. The concomitant rupture of the ventricular free wall and subsequent formation of a pseudoaneurysm appears to be rare. A search of the literature did not reveal such a case of combined complications after blunt chest trauma. In contrast to the quite obvious mechanism explaining the formation of a traumatic septal defect, several mechanisms are considered to lead to the formation of a post-traumatic ventricular aneurysm [5,7]. The contusion of the myocardial wall, a vascular lesion involving the left anterior descending coronary artery with subsequent ischemic necrosis, or an intramyocardial dissection after blunt chest injury are thought to result in aneurysm formation. In this patient, post-traumatic myocardial dissection is likely to be the responsible mechanism resulting in the formation of the pseudoaneurysm during the following days after the accident. Importantly, follow-up echocardiography was the key to discover the formation of

the pseudoaneurysm, which allowed for timely intervention. No other symptoms or hints in the condition of the patient suggested the formation of a pseudoaneurysm after his hospital discharge 7 days following the accident.

Frequently, muscular septal defects are difficult to approach for accurate surgical closure. Often, they are hidden beneath the trabeculations of the free wall, and it has been even recommended to perform a ventricular incision for the exposure of such defects. Given these drawbacks, the decision was made to proceed with transcatheter closure of the VSD, and subsequent surgical closure of the pseudoaneurysm. This combined 'hybrid' management resulted in a less invasive approach, a perfect result, and supports the idea of creating facilities, which allow the performance of 'hybrid' surgical and interventional procedures to offer new treatment options for patients with congenital heart disease.

## References

- [1] Rollins MD, Koehler RP, Stevens MH, Walsh KJ, Doty DB, Price RS, Allen TL. Traumatic ventricular septal defect: case report and review of the English literature since 1970. *J Trauma* 2005;58:175–80.
- [2] Lindenbaum G, Larrieu AJ, Goldberg SE, Wolk LA, Ghosh SC, Ablaza SG, Fernandez J. Diagnosis and management of traumatic ventricular septal defect. *J Trauma* 1987;27:1289–93.
- [3] Pretre R, Chilcott M. Blunt trauma to the heart and great vessels. *N Engl J Med* 1997;336:626–32.
- [4] Moront M, Lefrak EA, Akl BF. Traumatic rupture of the interventricular septum and tricuspid valve: case report. *J Trauma* 1991;31:134–6.
- [5] Frances C, Romero A, Grady D. Left ventricular pseudoaneurysm. *J Am Coll Cardiol* 1998;32:557–61.
- [6] Mackenzie JW, Lemole GM. Pseudoaneurysm of the left ventricle. *Tex Heart Inst J* 1994;21:296–301.
- [7] Maselli D, Micalizzi E, Pizio R, Audo A, De Gasperis C. Posttraumatic left ventricular pseudoaneurysm due to intramyocardial dissecting hematoma. *Ann Thorac Surg* 1997;64:830–1.