

Ivermectin Treatment of a Traveler Who Returned from Peru with Cutaneous Gnathostomiasis

F. Chappuis, T. Farinelli, and L. Loutan

Travel and Migration Medicine Unit, Department of Community Medicine, Geneva University Hospital, Geneva

We describe a 21-year-old patient who experienced a relapse of cutaneous gnathostomiasis after receiving initial treatment with albendazole and who had a successful outcome after receiving a short course of ivermectin for the relapse. This is the first reported case of gnathostomiasis acquired by a human in Peru.

A 21-year-old woman of Peruvian origin visited her family in Peru for 5 weeks in 1999. During the 3 years prior to her visit to Peru, she had lived in Geneva, Switzerland. The patient was based in Lima while in Peru, but she traveled to Huraz, located in central Peru, for a 5-day stay. One week before her return to Switzerland, while she was staying in Huraz, she presented with epigastric pain, watery diarrhea, nausea, and anorexia, all of 4 days' duration. Five days later (day 0), she noted pruritic swelling on the left side of the groin and used an antihistaminic ointment to treat it. The swelling spontaneously resolved by day 5, but a second area of swelling, which appeared on the inner left thigh on day 9, lasted for a few days. The subcutaneous swelling subsequently migrated toward the inner left knee on day 13, followed by migration to the outer left knee on day 16 and to the top of the outer left thigh on day 19 (figure 1). The patient was examined in a district hospital on day 20 and was referred to us on day 22.

The patient complained of general itching, fatigue, and headache. She did not complain of other neurological symptoms or fever. Physical examination revealed a subcutaneous and cutaneous tumefaction located on the outer, left mid-

thigh. There were no other skin lesions, and the lymph nodes were not enlarged. The patient's vital signs were within normal limits, as were the results of the rest of the physical examination. A complete blood count showed normal RBC values but an absolute eosinophil count of 2700 cells/mm³ (31% of 8900 WBCs/mm³). Her platelet count was slightly elevated (386,000 cells/mm³). The erythrocyte sedimentation rate and levels of C-reactive protein, electrolytes, blood urea nitrogen, creatinine, aspartate aminotransferase, alanine aminotransferase, bilirubin, and creatine kinase all were within normal limits. Serologic tests for parasitic diseases were performed.

A more thorough history of the patient's travel experiences revealed that she had eaten ceviche (a very popular dish made of raw fish marinated in lime juice) on a daily basis. Different species of saltwater or freshwater fish can be used in the preparation of the dish. The patient denied having consumed any other raw or improperly cooked food.

Despite the absence in the literature of reported cases of gnathostomiasis in humans in Peru, clinical suspicion of gnathostomiasis was strong enough for the patient to start receiving, on day 22, albendazole, 400 mg b.i.d. for 3 weeks. The swelling migrated down to the popliteal area of the left knee on day 25 and did not reappear while the patient received albendazole therapy. The eosinophil count decreased to 165 cells/mm³ by the end of treatment. Results of serologic tests performed at Mahidol University in Bangkok, Thailand, confirmed the diagnosis of gnathostomiasis, by use of an indirect ELISA that detected specific antibodies to a purified 24-kDa antigen obtained from advanced third-stage larvae of *Gnathostoma spinigerum*. In Thailand, this test has been reported to be 100% sensitive and 100% specific [1] for the detection of gnathostomiasis. Results of serologic tests for paragonimiasis, fascioliasis, toxocariasis, filariasis, strongyloidiasis, and cysticercosis were all negative. Results of 3 stool sample examinations were also negative.

The patient had no symptoms until >2 weeks after the end of albendazole therapy (day 60), when an 8-cm × 5-cm cutaneous inflammatory plaque reappeared on her inner left knee. Her eosinophil count was 150 cells/mm³. Ivermectin, 12 mg (200 µg/kg)/day, was then given for 2 consecutive days. There were no side effects, and there were no signs of relapse at the 12-month follow-up. The patient can be considered cured.

Human gnathostomiasis, a disease that is endemic in Southeast Asia, is most frequently caused by *G. spinigerum*. It is acquired as a result of ingestion of encysted larvae in the flesh

Received 23 October 2000; revised 9 January 2001; electronically published 20 July 2001.

Reprints or correspondence: Dr. F. Chappuis, Travel and Migration Medicine Unit, Dept. of Community Medicine, Geneva University Hospital, 24 rue Micheli-du-Crest, 1211 Geneva 4, Switzerland (francois.chappuis@hcuge.ch). Alternate contact: Dr. L. Loutan, Travel and Migration Medicine Unit, Dept. of Community Medicine, Geneva University Hospital, 24 rue Micheli-du-Crest, 1211 Geneva 4, Switzerland (louis.loutan@hcuge.ch).

Clinical Infectious Diseases 2001;33:e17-9

© 2001 by the Infectious Diseases Society of America. All rights reserved.
1058-4838/2001/3304-00E2\$03.00

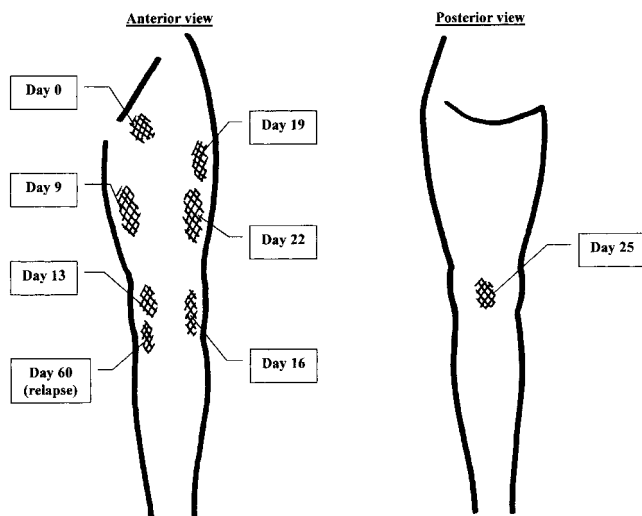


Figure 1. Migration of the subcutaneous swelling on the left lower limb.

of undercooked fish, poultry, frogs, and many other animals. Most cases have been reported from Thailand and Japan. The disease is due to the migration of the third-stage larvae. It most frequently affects the skin and subcutaneous tissue, but larvae can migrate to the vital organs, including the CNS, lungs, and eyes, and the disease can be fatal [2]. The first case of gnathostomiasis in humans in Latin America was reported in Mexico in 1970 [3]. Since then, >1000 cases have been identified in Mexico [4–6]. Most cases have been related to the consumption of raw freshwater fish (especially tilapia) prepared as ceviche, a custom that began after the construction of dams and reservoirs and the introduction of tilapia in artificial freshwater lakes in 1964. Lime juice is ineffective in killing the larvae, even when the fish have been marinated in the lime juice at room temperature for several days. In South America, gnathostomiasis in humans has been reported in Ecuador [7], with sporadic cases seeming to have occurred in Peru as well (E. Gotuzzo, personal communication).

The specific chemotherapy used for the treatment of patients with gnathostomiasis relies on high-dose albendazole therapy given for 3 weeks; rates of cure (i.e., absence of recurrence) that are as high as 94% have been reported at 6 months after initiation of treatment [8]. Ivermectin, an avermectin B derivative, is effective against several nematodes in the larval stages (i.e., *Oncocerca volvulus* and *Ancylostoma* species that cause cutaneous larva migrans) as well as the adult stage (i.e., *Strongyloides stercoralis* and *Ascaris lombricoides*). Ivermectin was also efficacious in rabbits that were experimentally infected with third-stage larvae of *G. spinigerum* [9]. A relapse of a case of cutaneous gnathostomiasis in a human recently was reported to have relapsed after 2 consecutive doses of ivermectin, 200 $\mu\text{g}/\text{kg}$, were given [10]. Albendazole was effective in markedly

reducing the eosinophil count in our patient, but it did not prevent a relapse of swelling. This raises a question regarding the nature of this relapse that occurred 17 days after the completion of albendazole treatment. Although the relapse is thought to be related to the presence of the migrating larva, we cannot rule out the possibility that it is related to a local reaction caused by the spontaneous death of the parasite. Since the completion of the 2-day course of ivermectin, no relapses have occurred, which suggests some efficacy of ivermectin.

In summary, we describe the first report of gnathostomiasis in a human in Peru, including the successful outcome provided by a short course of ivermectin. Gnathostomiasis is a potentially serious infection that is acquired by ingestion of raw fish, which is a well-known source of several other parasitic diseases (i.e., anisakiasis, clonorchiasis, and opisthorchiasis); travelers may be particularly at risk. In view of this case, the epidemiologic findings regarding gnathostomiasis should be studied further in Peru. Moreover, additional research regarding the efficacy of ivermectin for the treatment of individuals from different areas of endemicity would be worthwhile, considering the excellent tolerance for the drug, its short 2-day treatment schedule, and the expectation of better patient compliance with the regimen.

Acknowledgments

We thank Prof. Wanpen Chaicumpa and her colleagues from the Immunodiagnostic Unit of the Faculty of Tropical Medicine, Mahidol University, Bangkok, Thailand, for having performed the serologic test for gnathostomiasis. We also thank Prof. Eduardo Gotuzzo, Institute of Tropical Medicine “Alexander von Humboldt,” Lima, Peru, for his information and advice.

References

1. Nopparatana C, Setasuban P, Chaicumpa W, Tapchaisri P. Purification of *Gnathostoma spinigerum* specific antigen and immunodiagnosis of human gnathostomiasis. *Int J Parasitol* **1991**;21:677–87.
2. Rusnak JM, Lucey DR. Clinical gnathostomiasis: case report and review of the English-language literature. *Clin Infect Dis* **1993**;16:33–50.
3. Pelaez D, Perez-Reyes R. Gnathostomiasis humana en America. *Rev Latinoam Microbiol* **1970**;12:83–91.
4. Ogata K, Nawa Y, Akahane H, et al. Short report: gnathostomiasis in Mexico. *Am J Trop Med Hyg* **1998**;58:316–8.
5. Diaz Camacho SP, Ramos MZ, Ponce E, et al. Clinical manifestations and immunodiagnosis of gnathostomiasis in Culiacan, Mexico. *Am J Trop Med Hyg* **1998**;59:908–15.
6. Rojas-Molinas N, Pedraza-Sanchez S, Torres-Bibiano B, Meza-Martinez H, Escobar-Gutierrez A. Gnathostomiasis, an emerging foodborne zoonotic disease in Acapulco, Mexico. *Emerg Infect Dis* **1999**;5:264–6.
7. Ollague W, Ollague J, Guevara de Veliz A, Penaherrera S. Human gnathostomiasis in Ecuador (nodular migratory eosinophilic panni-

- culitis) first finding of the parasite in South America. *Int J Dermatol* **1984**; 23:647–51.
8. Kraivichian P, Kulkumthorn M, Yingyourd P, Akarabovorn P, Paireepai C. Albendazole for the treatment of human gnathostomiasis. *Trans R Soc Trop Med Hyg* **1992**; 86:418–21.
 9. Anantaphruti MT, Nuamtanong S, Waikagul J. Effect of ivermectin on experimental gnathostomiasis in rabbits. *Trop Med Parasitol* **1992**; 43: 65–7.
 10. Ruiz-Maldonado R, Mosqueda-Cabrera M. Human gnathostomiasis (nodular migratory eosinophilic panniculitis). *Int J Dermatol* **1999**; 38:52–7.