

Management of radiation dermatitis in patients receiving cetuximab and radiotherapy for locally advanced squamous cell carcinoma of the head and neck: proposals for a revised grading system and consensus management guidelines

J. Bernier^{1*}, E. G. Russi², B. Homey³, M. C. Merlano⁴, R. Mesía⁵, F. Peyrade⁶ & W. Budach⁷

¹Department of Radiation Oncology, University of Geneva, Clinique de Genolier, Genolier, Switzerland; ²Department of Radiation Oncology, Santa Croce General Hospital, Cuneo, Italy; ³Department of Dermatology, University Hospital Duesseldorf, Duesseldorf, Germany; ⁴Department of Medical Oncology, Santa Croce General Hospital, Cuneo, Italy; ⁵Department of Medical Oncology, Catalan Institute of Oncology, Hospitalet de Llobregat, Barcelona, Spain; ⁶Department of Medical Oncology, Centre Antoine-Lacassagne, Nice, France; ⁷Clinic and Policlinic for Radiotherapy and Radiation Oncology, University Hospital Duesseldorf, Duesseldorf, Germany

Received 18 November 2010; revised 3 March 2011; accepted 7 March 2011

Background: Radiation dermatitis developing in patients receiving cetuximab concomitantly with radiotherapy for locally advanced squamous cell carcinoma of the head and neck (LA SCCHN) is now recognized to have different pathophysiological and clinical characteristics to the radiation dermatitis associated with radiotherapy or concomitant chemotherapy and radiotherapy. Current grading tools were not designed to grade this type of radiation dermatitis; their use may lead to misclassification of reactions and inappropriate management strategies, potentially compromising cancer treatment.

Patients and methods: An advisory board of seven leading European specialists (three medical oncologists, three radiation oncologists and a dermatologist) with extensive experience of the use of cetuximab plus radiotherapy produced consensus guidelines for the grading and management of radiation dermatitis in patients receiving cetuximab plus radiotherapy.

Results: Modifications to the current, commonly used National Cancer Institute—Common Terminology Criteria for Adverse Events version 4.3 for grading radiation dermatitis were proposed. Updated management guidelines, building on previously published guidelines from 2008, were also proposed.

Conclusions: The proposed revisions to the grading system and updated management guidelines described here represent important developments toward the more appropriate grading and effective management of radiation dermatitis in patients receiving cetuximab plus radiotherapy for LA SCCHN.

Key words: cetuximab, guidelines, locally advanced squamous cell carcinoma of the head and neck, management, radiation dermatitis, radiotherapy

introduction

the need for revised grading criteria and updated management guidelines

Radiotherapy plus the epidermal growth factor receptor (EGFR) antibody cetuximab is now a standard treatment approach for patients with locally advanced squamous cell carcinoma of the head and neck (LA SCCHN) [1, 2]. Five-year results of the pivotal phase III trial, which demonstrated that adding cetuximab to radiotherapy had significant locoregional

control and survival benefits compared with radiotherapy alone, reported that the improvement in survival seen with cetuximab plus radiotherapy was maintained long term (median 49.0 versus 29.3 months; 5-year survival rate 45.6% versus 36.4%; hazard ratio 0.73; $P = 0.018$) [3].

Adding cetuximab to radiotherapy does not appear to unduly increase the side-effects generally associated with radiotherapy [1]. However, there have been reports of severe radiation dermatitis-like skin reactions with cetuximab plus radiotherapy in contrast to those seen with radiotherapy alone [4–9]. In the pivotal phase III trial, there was no statistically significant difference between the arms in the incidence of radiation dermatitis (either all grades or grade ≥ 3), although there was an increase of $\sim 5\%$ in the incidence of grade ≥ 3 radiation dermatitis

*Correspondence to: Dr J. Bernier, Department of Radiation Oncology, University of Geneva, Clinique de Genolier, 1272 Genolier, Switzerland. Tel: +41-22-319-7700; Fax: +41-22-319-7778; E-mail: jbernier@genolier.net

in the cetuximab arm [1]. This is generally not higher than the increase seen with concurrent chemotherapy and radiotherapy [chemoradiotherapy (CRT)] compared with radiotherapy alone [10, 11], although underreporting cannot be excluded. Outside the setting of a randomized trial, data suggest that while there may be a higher incidence of grade ≥ 3 radiation dermatitis in patients receiving cetuximab plus radiotherapy compared with those receiving concurrent CRT, the side-effects of CRT may have a greater negative effect than cetuximab plus radiotherapy in terms of patient symptoms and compliance with treatment [12] (RM, personal communication). A single-center nonrandomized comparison between patients receiving cetuximab plus radiotherapy ($n = 50$) or CRT ($n = 48$) during the same time period showed that the incidence of grade 3/4 dermatitis (recorded by the same specialist nurse) was significantly higher with radiotherapy plus cetuximab than with CRT (18.0% versus 2.1%; $P = 0.014$), although treatment compliance was significantly higher for cetuximab plus radiotherapy compared with CRT (noncompliance 12.0% versus 37.5%, respectively; $P = 0.003$) (RM, personal communication).

In 2008, the conclusions of an advisory board convened to discuss the management of skin reactions in patients receiving EGFR inhibitors in combination with radiotherapy were published [13]. Since these first guidelines were published, there has been an increase in the understanding of the pathophysiology of these skin reactions and a greater familiarity among physicians with their clinical appearance. It is now recognized that the skin reactions seen with cetuximab plus radiotherapy have a different clinical appearance to those seen with radiotherapy alone: they develop early, resolve rapidly and often do not leave scarring. The National Cancer Institute—Common Terminology Criteria for Adverse Events (NCI-CTCAE) version 4.3 is an established, commonly used tool for grading radiation dermatitis [14]. While it has proved invaluable for the grading of dermatitis in patients receiving radiotherapy with or without concurrent chemotherapy, the NCI-CTCAE may be less appropriate for grading the type of dermatitis seen in patients receiving cetuximab plus radiotherapy and this may potentially compromise effective treatment strategies. It is timely to consider modifications to the current grading system and updated treatment guidelines to help physicians to correctly grade and effectively manage radiation dermatitis in patients receiving cetuximab plus radiotherapy, thus optimizing treatment compliance and the chances of a good clinical outcome.

This article reflects the findings from an advisory board meeting held in February 2010, involving seven leading European specialists (three medical oncologists, three radiation oncologists and a dermatologist) with extensive experience of the use of cetuximab and radiotherapy in SCCHN.

pathophysiological differences between dermatitis observed following radiotherapy alone and cetuximab plus radiotherapy

For patients receiving treatment with cetuximab plus radiotherapy, the combination of skin responses induced by the individual treatments leads to the characteristic reactions that are reported with this treatment approach.

The primary effect of radiotherapy is on the proliferating basal cells, the depletion of which leads to an alteration in the normal turnover of skin cells. This effect is compounded by the activity of radiotherapy on the differentiating functional strata, comprising the less radiosensitive granular cells and anucleated corneocytes. The result of these effects is a thinning of the stratum granulosum, which is involved in the production of lipids, natural moisturizing factor and keratin, all of which are important factors in the prevention of transepidermal water loss [15]. This thinning is visible as clumps of exfoliated corneocytes (scales), characteristic of the dry desquamation associated with a grade 1 radiation dermatitis reaction. When the radiation dose is sufficiently high, an almost complete loss of the basal cell layer, associated with a disruption of the basement membrane and the failure of the barrier function, leads to the exposure of the inflamed dermis and the moist desquamation described for grade 2–3 reactions. While skin necrosis or ulceration of the full-thickness dermis, as described for grade 4 reactions, are possible side-effects of high-dose radiotherapy, to our knowledge, such reactions have not been reported in the acute phase with modern fractionated megavolt radiotherapy.

The EGFR signaling pathway plays an integral part in the development and maintenance of the skin and can have a marked impact on the inflammatory and/or immune responses of the skin [16]. As such, the finding that disruption of the EGFR signaling pathway results in skin reactions is not surprising [17]. The EGFR signaling pathway regulates the survival, migration and proliferation of the various types of skin cells [16]. It also has a major impact on the inflammatory/immune reactions of the skin: activation of the pathway appears to enhance the innate immune response and reduce the proinflammatory functions of keratinocytes [16, 18–20]. Inhibition of the EGFR induces thinning of the functional strata [21]; the development of xerosis [17]; skin inflammation, particularly around the follicles; and alteration of the expression of Toll-like receptors, thereby compromising the synthesis of antimicrobial peptides [16] and favoring microbial colonization and superinfection.

It is known that cetuximab enhances the sensitivity of tumor cells to radiation [22], and it is likely that the concurrent administration of cetuximab and radiotherapy results in some degree of interplay between the effects of the individual agents on the skin and an exacerbation of the reactions seen with the individual agents. This interaction manifests as a more marked xerosis, a more intense inflammatory response localized to the subepidermis, a more obvious thinning of the epidermis and, sometimes, necrosis of the superficial dermis and of the epidermis (Figure 1). The reaction between cetuximab and radiotherapy also induces the production of an inflammatory exudation that mixes with the exfoliated corneocytes and dries rapidly to form crusts (Figure 2A). These crusts can compromise healing of the affected area in several ways. First, they can be a cause of sustained microtrauma and are prone to abrasion leading to bleeding and discomfort and/or pain (Figure 2B). Secondly, they may harbor bacteria, thereby potentially increasing the risk for superinfection (Figure 2C and supplemental Figure S1, available at *Annals of Oncology* online), an effect that may be exacerbated by the previously discussed

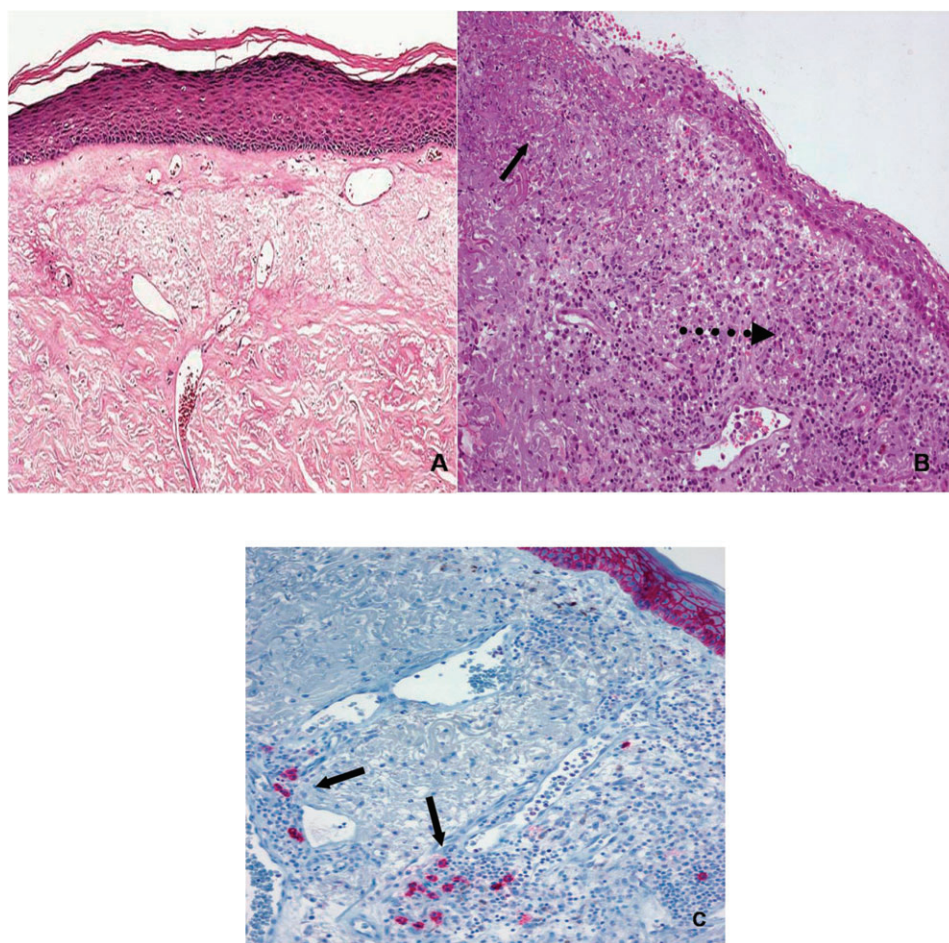


Figure 1. Histological differences between the radiation dermatitis seen with radiotherapy alone (A) and that seen with cetuximab plus radiotherapy (B and C). The epidermis is thin and devoid of rete ridges. The basal stratum is the most atrophic. (A) This shows a lichenoid tissue reaction (interface dermatitis), a basophilic degeneration of the superficial dermis and dilated blood vessels. (B) In some areas, an interruption of the epidermis and limited necrosis of the epidermis and of the superficial dermis (arrow) is associated with inflammatory lymphoplasmacellular and granulocytic infiltration of the subepidermis (dotted arrow). (C) An immunostain for CD138 illustrates the plasmacellular population (arrows). The slide for cetuximab plus radiotherapy was obtained from a patient undergoing treatment in the AlteRCC trial (Alternating Radiotherapy and Chemotherapy combined with Cetuximab) in which patients received three cycles of cisplatin (20 mg/m²/day for 5 days) and 5-fluorouracil (200 mg/m²/day for 5 days) rapidly alternating with three split courses of radiotherapy (up to 70 Gy) and concurrent weekly cetuximab [9]. Slides provided by Dr Rodolfo Brizio, Department of Histopathology, Santa Croce-Carle General Hospital, Cuneo, Italy.

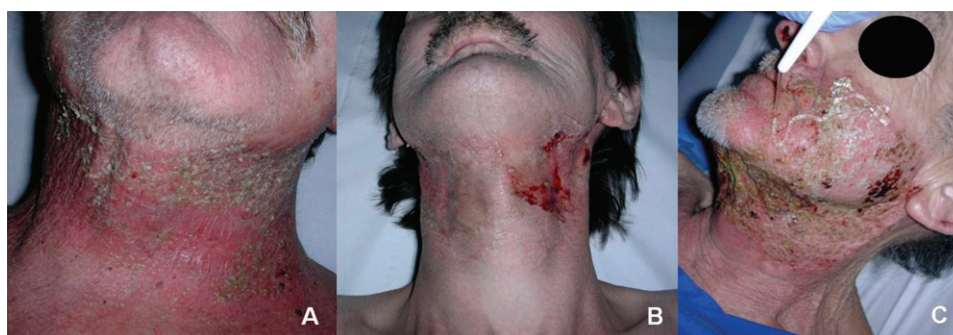

Figure 2. Examples of radiation dermatitis in three patients receiving cetuximab plus radiotherapy. (A) Modified grade 2 radiation dermatitis with non-hemorrhagic crusts. (B and C) Two examples of modified grade 3 reactions that could be overclassified using the NCI-CTCAE grading system. In B, bleeding is from <40% of the irradiated site and in C, hemorrhagic crusts cover <50% of the involved field. In C, hydrogel is being applied to the crusts. NCI-CTCAE, National Cancer Institute—Common Terminology Criteria for Adverse Events.

effects of EGFR inhibition on inflammatory/immune reactions. In the case of severe reactions, superficial ulcerations with crusty exudates are typically observed. In most cases, a small number of basal stem cells are preserved, particularly around the hair follicles, and this allows for the rapid regeneration of the damaged skin.

The type of reaction observed following concurrent administration of cetuximab and radiotherapy depends on the degree of interaction between the two treatment modalities. This results in varying degrees of a combination of the dry/moist desquamation associated with radiotherapy and the xerosis, inflammation and innate immune defense deregulation associated with EGFR inhibition. It also appears that the combination of the two treatment modalities alters the timing of the onset of radiation dermatitis. In patients receiving cetuximab plus radiotherapy, the onset of radiation dermatitis may be earlier than that observed with radiotherapy alone (week 1 or 2 compared with 3+ to 5+ weeks, respectively).

While the clinical appearance of reactions in patients receiving cetuximab plus radiotherapy is of a more severe dermatitis than is seen with radiotherapy alone, patients generally recover within 1–2 weeks following the end of treatment, even when there is crusting (Figure 2A). In addition, there is generally no scarring following radiation dermatitis with cetuximab plus radiotherapy (Figure 3C) [8]. To date, no other long-term skin-related sequelae have been reported.

Factors influencing the development of radiation dermatitis

Although the majority of patients receiving radiotherapy will develop dermatitis, a number of predisposing factors will influence the severity of the reaction, independent of the dose of radiotherapy. Intrinsic factors include the general skin condition, nutritional status, chronoaging, photoaging and comorbidities [23]. In addition, the stratum corneum in the neck area is thinner than in other areas and so is more prone to

damage from skin reactions. Extrinsic factors include radiation dose, energy and fractionation regimen [23] and the combination of radiotherapy with chemotherapy [11]. These intrinsic and extrinsic factors may provide the physician with valuable pretreatment information regarding which patients may be considered likely to require close monitoring for skin reactions.

Grading for radiation dermatitis in patients receiving cetuximab plus radiotherapy

Radiation dermatitis associated with radiotherapy or CRT can be effectively graded using the NCI–CTCAE version 4.3 [14]. However, given that the dermatitis associated with radiotherapy administered in combination with cetuximab is different from that seen with radiotherapy/CRT, the NCI–CTCAE scale may be less appropriate for the grading of these types of reactions. Specifically, there are two main issues with the use of this scale in this setting. First, the distinction between the gradings is unclear, particularly with regard to grade 3 and 4 reactions. Skin necrosis or ulceration of the full-thickness dermis is included within the grade 4 reaction category of the NCI–CTCAE. In patients receiving cetuximab plus radiotherapy, the presence of the crusts makes a clinical diagnosis of a true grade 4 reaction difficult to make without a biopsy, which is not generally carried out in these patients. Secondly, as the NCI–CTCAE scale was not designed to provide grading for dermatitis associated with cetuximab plus radiotherapy, its use may lead to a misclassification of grade 3 reactions to grade 4 reactions, particularly in the case of the development of confluent crusty exudates. Such misclassification may compromise the appropriate management of skin reactions and, more importantly, may lead to treatment delay or interruption, thereby potentially adversely affecting outcome. The misclassification of reactions also complicates the interpretation of intertrial comparisons of the incidence of radiation dermatitis observed with different treatment approaches.

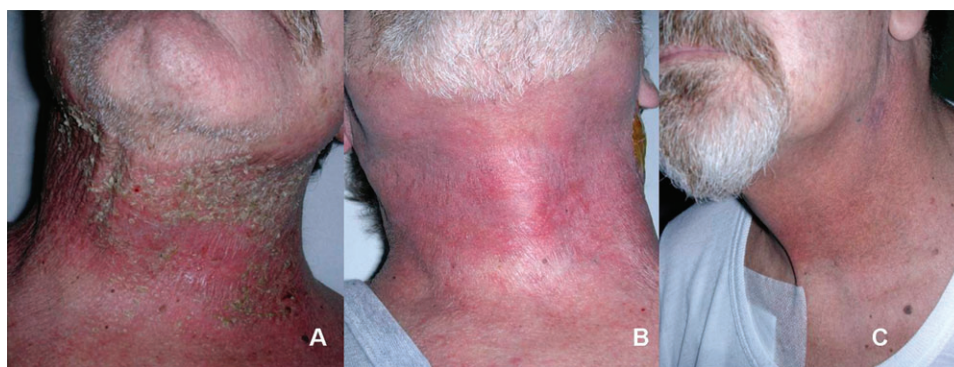


Figure 3. Time course of radiation dermatitis in a patient receiving cetuximab and radiotherapy. (A) Modified grade 2 radiation dermatitis with non-hemorrhagic crusts; (B) 1 week after completion of treatment; (C) 40 days after completion of treatment. Images are taken from one patient treated in the AlterRCC trial (Alternating Radiotherapy and Chemotherapy combined with Cetuximab) in which patients received three cycles of cisplatin (20 mg/m²/day for 5 days) and 5-fluorouracil (200 mg/m²/day for 5 days) rapidly alternating with three split courses of radiotherapy (up to 70 Gy) and concurrent weekly cetuximab [9]. On the appearance of dry desquamation and crusty exudation (A), hydrogel was applied to facilitate debridement. Ultrathin hydrocolloid dressings were then applied to protect the skin from trauma and were changed twice weekly, or when indicated by excessive exudation.

In view of these issues, the advisory board proposed a series of modifications to the NCI–CTCAE version 4.3-defined gradings with the aim of making the scale more applicable to the radiation dermatitis seen with cetuximab plus radiotherapy. The proposals for the revisions to each grade are detailed in Table 1. The major modifications proposed are the inclusion of the following features at different grades:

- Grades 2–4
 - Crusting, the type (hemorrhagic or non-hemorrhagic) and the extent of which are an important part of grading.
 - The potential for local or systemic superinfection, which will influence the selection of the most appropriate management strategy. Superinfection can be identified by the clinical appearance of the affected area [moist desquamation and crusts, with yellowing (Figure 2C and supplemental Figure S1, available at *Annals of Oncology* online)] and by microbiological assessment (from swabs of the area and blood tests).

- Grade 4
 - The extent of spontaneous bleeding (Figure 2B). According to the modified grading, extensive (>40% of the involved site) spontaneous bleeding, rather than any level of spontaneous bleeding, can be a feature of a grade 4 reaction. The authors recognize that it is difficult to distinguish between true isolated spontaneous bleeding and bleeding due to mechanical trauma [particularly where there is crusting (Figure 2B)].
 - Extensive confluent hemorrhagic crusting or ulceration (>50% of the involved area) [5].

Physicians should continue to monitor patients for isolated spontaneous bleeding and full-thickness necrosis, as the development of these sequelae cannot be ruled out. Photographic documentation of all grades of reactions is recommended.

management guidelines for radiation dermatitis in patients receiving cetuximab plus radiotherapy

Effective management should address both the epidermal barrier disruption and the inflammatory and superinfection components of the skin reaction to cetuximab plus radiotherapy, to ensure treatment compliance and optimize clinical outcome and medical resource use. While there is currently no validated way of preventing the development of radiation dermatitis, intervention at an early stage is crucial for effective management. In addition, close collaboration with the dermatologist at an early stage is advised, with this involvement diminishing over time as physicians become more familiar with the grading and management of the skin reactions. This approach will optimize both effective management approaches and the use of hospital resources.

The format of the management guidelines here does not follow general NCI–CTCAE intervention rules, in terms of the timing and route of treatment administration in accordance with grade, e.g. grade 1, no treatment; grade 2, topical treatment; grade 3, oral treatment; and grade 4, i.v. treatment. Instead, the focus of these treatment guidelines concerns the impact of skin reactions on the optimal delivery of anticancer treatment and how such reactions can be managed so that anticancer treatment compliance can be ensured. In general, patients with grade 1–3 reactions can be managed as outpatients, although this should be decided on an individual patient basis. Initially, patients should be monitored weekly by the management team for signs of skin reactions, until the first sign of erythema, at which point monitoring should become more frequent (at least twice weekly). Patients developing severe early erythema should be monitored closely throughout treatment. In cases of radiation dermatitis of grade ≥ 3 , the management team should evaluate the need for daily assessment of the patient. Where daily assessment is not possible, for instance, during weekends, patients should be advised of what action to take should the severity of a skin reaction increase.

The continuation of treatment with cetuximab depends on the grade of radiation dermatitis observed. Cetuximab can continue to be administered on a weekly basis to patients developing up to grade 2 dermatitis and in those developing grade 3 dermatitis who are being treated in a center experienced in the management of these types of skin reactions. It may be appropriate to consider a brief interruption in the treatment of severe grade 3 dermatitis. While grade 4 dermatitis is considered to be a rare event, cetuximab, and/or other systemic anticancer treatments, should be discontinued.

general measures

Patients should be provided with written information on how to manage their skin reactions and the use of a nursing diary is recommended. Skin hygiene is of paramount importance and patients should be advised to keep the affected skin clean, to wash their hands before touching the affected area and to use clean towels. The affected area should be washed not more than twice a day (once in the morning and once in the evening), using pH 5 (pH skin neutral) soaps and/or showering oils for sensitive skin, followed by moisturization with an unperfumed moisturizer recommended for dry skin (supplemental Table S1, available at *Annals of Oncology* online). There is no evidence of any benefit of *Aloe vera* and there have been observations that it may aggravate the reaction to treatment [25, 26]. Moisturizers that contain urea (<3%) and/or have a high glycerol content are recommended. Shaving with a sharp, disinfected wet razor should be encouraged, where appropriate, to reduce the risk for folliculitis, although care should be taken to avoid local trauma. Patients should be advised to avoid sunbathing/sun exposure, scratching and mechanical trauma in the affected area, and the use of skin irritants, such as alcohol-based lotions and perfumes.

The debridement of crusts by a member of the management team may help to reduce the risk for superinfection and bleeding and may help with pain management. However, local trauma should be avoided. Hydrogels, which can be used on their own to keep crusts flexible and so reduce the risk for skin trauma and

Table 1. Proposed modifications to the NCI–CTCAE v4.03 grading and grade-specific management strategies for patients developing radiation dermatitis during treatment with cetuximab plus radiotherapy

	Grade of dermatitis associated with radiation-based therapy			
	Grade 1	Grade 2 ^a	Grade 3 ^a	Grade 4 ^a
Definition: NCI–CTCAE, v4.03 dermatitis radiation	Faint erythema or dry desquamation	Moderate to brisk erythema; patchy moist desquamation, mostly confined to skin folds and creases; moderate edema	Moist desquamation in areas other than skin folds and creases; bleeding induced by minor trauma or abrasion	Life-threatening consequences; skin necrosis or ulceration of full-thickness dermis; spontaneous bleeding from involved site; skin graft indicated
Definition: Proposed modification of NCI–CTCAE, v4.03	Faint erythema or dry desquamation	Moderate to brisk erythema and/or dry desquamation; patchy moist desquamation, or non-hemorrhagic crusts mostly confined to skin folds and creases	Moist desquamation or hemorrhagic crusts; non-hemorrhagic crusts other than in skin folds and mostly confined to skin folds and creases; bleeding induced by minor trauma or abrasion; superinfection requiring oral antibiotics	Life-threatening consequences; extensive confluent hemorrhagic crusts or ulceration (>50% of involved field); extensive spontaneous bleeding from involved site (>40% of the involved site); skin necrosis or ulceration of full-thickness dermis or any size ulcer with extensive destruction, tissue necrosis or damage to muscle, bone or supporting structures with or without full-thickness skin loss ^b ; skin graft indicated; ulceration associated with extensive superinfection with i.v. antibiotics indicated
General management approaches	Reinforce general management approaches ^c	Reinforce general management approaches ^c	Reinforce general management approaches ^c	Reinforce general management approaches ^c
Grade-specific management approaches	<ul style="list-style-type: none"> Weekly follow-up is adequate, unless rapid progression is noted 	<ul style="list-style-type: none"> Consider twice-weekly assessments to monitor for rapid change A. <i>Dry desquamation without crusts:</i> <ul style="list-style-type: none"> Consider glucocorticosteroid cream or ointment for a limited period (1–2 weeks) Topical antiseptics and antibiotics at any sign of superinfection Consider the use of topical antiseptics and antibiotics for the prevention of more severe reactions 	<ul style="list-style-type: none"> Evaluate the need for daily assessment Closely monitor for signs of local or systemic infection For grade 3 reactions occurring at <50 Gy, consider brief interruption in treatment A. <i>Confluent moist desquamation without crusts:</i> <ul style="list-style-type: none"> Topical antiseptic 	<ul style="list-style-type: none"> Consider interrupting treatment with both radiotherapy and cetuximab. Cetuximab should be interrupted until the skin reaction has resolved to at least grade 2 In the case of severe superinfection, consider the use of i.v. antibiotics if unresponsive to oral antibiotics Hospitalize the patient

Table 1. (Continued)

Grade of dermatitis associated with radiation-based therapy			
Grade 1	Grade 2 ^a	Grade 3 ^a	Grade 4 ^a
	<p><i>B. Moist desquamation in skin folds:</i></p> <ul style="list-style-type: none"> ● Topical antiseptic ● Consider adding daily topical glucocorticosteroid lotion to reduce inflammation for a limited period (1–2 weeks) ● Topical antibiotics active against <i>Staphylococcus aureus</i> at any sign of superinfection. Consider systemic antibiotics if superinfection becomes more severe ● Topical eosin or soft zinc preparations in the skin folds. A thin layer of a soft zinc preparation may be used in skin folds, but should be removed before treatment with radiotherapy to avoid radiation dosimetric problems. Topical eosin in skin folds or on erosive lesions may also be a useful treatment approach. <p><i>C. Dry desquamation with isolated non-hemorrhagic crusts:</i></p> <ul style="list-style-type: none"> ● Topical antiseptic ● Consider adding daily topical glucocorticosteroid lotion to reduce inflammation for a limited period (1–2 weeks) ● Topical antibiotics active against <i>S. aureus</i> at any sign of superinfection. Consider systemic antibiotics if superinfection becomes more severe 	<ul style="list-style-type: none"> ● Consider adding daily topical glucocorticosteroid lotion to reduce inflammation for a limited period (1–2 weeks) ● Topical antibiotics active against <i>S. aureus</i> at any sign of superinfection ● If superinfection becomes more severe, consider the use of i.v. antibiotics if unresponsive to oral antibiotics ● Topical eosin or soft zinc preparations in the skin folds. A thin layer of a soft zinc preparation may be used in skin folds, but should be removed before treatment with radiotherapy to avoid radiation dosimetric problems. Topical eosin in skin folds or on erosive lesions may also be a useful treatment approach <p><i>B. Confluent moist desquamation with crusts:</i></p> <ul style="list-style-type: none"> ● Topical antiseptic ● If superinfection becomes more severe, consider the use of i.v. antibiotics if unresponsive to oral antibiotics ● Consider debridement using hydrogels. Skin trauma should be avoided to prevent superinfection 	

Table 1. (Continued)

	Grade of dermatitis associated with radiation-based therapy			
	Grade 1	Grade 2 ^a	Grade 3 ^a	Grade 4 ^a
		<ul style="list-style-type: none"> • Topical eosin or soft zinc preparations in the skin folds. A thin layer of a soft zinc preparation may be used in skin folds but should be removed before treatment with radiotherapy to avoid radiation dosimetric problems • Hydrogels can be used to keep crusts flexible • Consider debridement using hydrogels (Figure 2C). Skin trauma should be avoided to prevent superinfection 	<ul style="list-style-type: none"> • If hydrocolloid dressings are used, the thickness of the dressing should be taken into account for the radiotherapy dosimetry. Hydrofiber dressings can be used after completion of radiotherapy 	
Management team	Radiation oncologist, medical oncologist, nurse, dermatologist ^d	Radiation oncologist, medical oncologist, nurse, dermatologist ^d	Radiation oncologist, medical oncologist, nurse, dermatologist ^d	Involve a wound-healing specialist in addition to the radiation oncologist, medical oncologist, nurse, dermatologist ^d

See the supplemental Table S1 (available at *Annals of Oncology* online) for examples of suitable products.

^aPossibility of local superinfection as indicated by the clinical appearance (moist desquamation and crusts, with yellowing) and by microbiological assessment (from swabs of the area and blood tests); suspected systemic superinfection is indicated by the presence of at least two of the following four variables of systemic inflammatory response syndrome [24]: fever with a core temperature $>38^{\circ}\text{C}$ or $<36^{\circ}\text{C}$, heart rate >90 beats per min, respiratory rate >20 breaths per min, leukocytosis ($>12 \times 10^9/l$) or leukopenia ($<4 \times 10^9/l$).

^bSkin necrosis of full-thickness dermis is rarely seen with the recommended doses of cetuximab plus radiotherapy and this type of diagnosis should be based only on a biopsy of tissue from the involved site.

^cSee 'General Measures' section in the text.

^dEarly involvement of a dermatologist may facilitate effective management.

NCI-CTCAE, National Cancer Institute—Common Terminology Criteria for Adverse Events.

pain (supplemental Table S1, available at *Annals of Oncology* online), can also be used to facilitate debridement. Following debridement, emollients can be used to moisturize the skin, and/or hydrocolloid or hydrofiber dressings [27] can be used to protect the skin from further trauma (supplemental Figure S1, available at *Annals of Oncology* online). All dressings should be transparent, so that any signs of superinfection can be observed (supplemental Figure S1, available at *Annals of Oncology* online). Also, consideration should be given to the need to remove dressings before radiotherapy sessions if the type of dressing significantly decreases the buildup effect of photon radiation. Care should be taken to ensure that anything used on the skin, in terms of dressings or creams, does not alter the dose of radiation delivered to the skin [28]. Given the relatively high risk for superinfection, the patient should be closely monitored for signs of systemic inflammatory response and changes in the clinical presentation of dermatitis. Where superinfection is suspected in cases of dermatitis up to grade 2, local antiseptics and/or topical antibiotics may be beneficial. The use of systemic antibiotics may be considered if superinfection becomes more severe. Before the initiation of any antibiotic treatment, culture data should, where feasible, be obtained.

grade-specific management guidelines

Grade-specific management strategies are given in Table 1 and examples of specific agents recommended for use in both general and grade-specific management strategies are given in the supplemental Table S1 (available at *Annals of Oncology* online).

While glucocorticosteroid creams or ointments can help in the treatment of xerosis and reduce water loss from the skin, there is no consensus regarding the efficacy of these agents in the management of radiation dermatitis in patients receiving cetuximab and radiotherapy [29, 30]. Indeed, some authors suggest that topical glucocorticoids may potentiate the cutaneous toxicity of EGFR inhibitors [31]. It is, therefore, advisable to limit the use of glucocorticosteroids to short periods of time (1–2 weeks). Short-term application of glucocorticosteroid lotion (without alcohol) [31] may be useful if moist desquamation (grade 2) starts to develop. Alternatively, the combination of topical glucocorticosteroids plus local antiseptics/antibiotics might be useful.

conclusions and future directions

Since the first regulatory approval of cetuximab plus radiotherapy for the treatment of LA SCCHN in 2006, the number of physicians using cetuximab in this setting has increased steadily. The guidelines proposed here use our current understanding of the pathophysiology and clinical course of the radiation dermatitis reactions seen with cetuximab plus radiotherapy to build on an existing grading system [14] and earlier management guidelines [13]. The aims of the proposed revisions to the grading system are to facilitate discussions on the appropriate grading of radiation dermatitis in patients receiving cetuximab and radiotherapy. The consensus management guidelines will provide physicians with a tool that can be used to ensure the effective treatment of these reactions, thereby enabling patients to continue with scheduled radiotherapy as planned and ensuring the efficient use of

medical resources. Specifically, the proposed adaptation of the grading system may provide a more accurate way of identifying of the highest grades of dermatitis. This adaptation has been driven by the fact that the currently used grading system was established before the introduction of treatment with a combination of radiotherapy and targeted agents, and the resulting change in the pathophysiology and distinctive clinical pattern of the dermatitis observed with this treatment approach. In addition to facilitating the correct grading of these types of reactions, the adapted grading system may help in determining the correct treatment approach for the most severe grades of skin reactions.

It is recognized that the management of radiation dermatitis associated with cetuximab plus radiotherapy is an evolving area and it is likely that as our knowledge of the pathophysiological mechanisms involved in these reactions improves, alternative management approaches may be considered. Current areas of interest for the management of this type of radiation dermatitis include the use of calcineurin inhibitors (pimecrolimus cream or tacrolimus ointment) for tackling inflammation, the place of prophylaxis with a glucocorticosteroid cream of low atrophogenic potential and the use of prophylactic antibiotics, including doxycycline, which has both antibiotic and immunomodulatory effects. While a few of the trials that have investigated approaches designed to prevent radiation dermatitis [26, 32–37] have demonstrated some degree of efficacy, there are currently no validated prevention strategies and this is an area that requires continued investigation. Finally, as the use of cetuximab plus radiotherapy in LA SCCHN continues to grow, physicians will become more familiar with these reactions [38] and this in itself may lead to the development of further management options.

acknowledgements

Editorial assistance in the preparation of this article was provided by Jo Shrewsbury-Gee, Cancer Communications and Consultancy Ltd, funded by Merck KGaA, Darmstadt, Germany. The authors thank Rodolfo Brizio, Department of Histopathology, Santa Croce-Carle General Hospital, Cuneo, Italy, for his assistance in selecting and supplying histopathology images. The authors take full responsibility for the content of this publication.

funding

Merck KGaA, Darmstadt, Germany.

disclosure

JB reports being an occasional member of advisory boards for Merck Serono; EGR reports being an advisory board member for Merck Serono; BH reports being a consultant for Merck Serono and Roche; MCM reports serving on paid advisory boards and receiving lecture fees from Merck Serono; RM reports being a member of the speakers' bureau for Merck Serono; FP reports conducting research sponsored by Merck Serono; WB reports receiving two research grants from Merck Serono.

references

- Bonner JA, Harari PM, Giralt J et al. Radiotherapy plus cetuximab for squamous-cell carcinoma of the head and neck. *N Engl J Med* 2006; 354: 567–578.
- Gregoire V, Lefebvre JL, Licitra L, Felip E. Squamous cell carcinoma of the head and neck: EHNS-ESMO-ESTRO Clinical Practice Guidelines for diagnosis, treatment and follow-up. *Ann Oncol* 2010; 21 (Suppl 5): v184–v186.
- Bonner JA, Harari PM, Giralt J et al. Radiotherapy plus cetuximab for locoregionally advanced head and neck cancer: 5-year survival data from a phase 3 randomised trial, and relation between cetuximab-induced rash and survival. *Lancet Oncol* 2010; 11: 21–28.
- Berger B, Belka C. Severe skin reaction secondary to concomitant radiotherapy plus cetuximab. *Radiat Oncol* 2008; 3: 5.
- Budach W, Bolke E, Homey B. Severe cutaneous reaction during radiation therapy with concurrent cetuximab. *N Engl J Med* 2007; 357: 514–515.
- Giro C, Berger B, Bolke E et al. High rate of severe radiation dermatitis during radiation therapy with concurrent cetuximab in head and neck cancer: results of a survey in EORTC institutes. *Radiat Oncol* 2009; 90: 166–171.
- Mydin AR, Armstrong JG. Acneiform rash secondary to cetuximab plus head and neck radiotherapy [Letter]. *Radiat Oncol* 2007; 85: 171.
- Bolke E, Gerber PA, Lammering G et al. Development and management of severe cutaneous side effects in head-and-neck cancer patients during concurrent radiotherapy and cetuximab. *Strahlenther Onkol* 2008; 184: 105–110.
- Merlano M, Russi E, Benasso M et al. Cisplatin-based chemoradiation plus cetuximab in locally advanced head and neck cancer: a phase II clinical study. *Ann Oncol* 2011; 22: 712–717.
- Calais G, Alfonsi M, Bardet E et al. Randomized trial of radiation therapy versus concomitant chemotherapy and radiation therapy for advanced-stage oropharynx carcinoma. *J Natl Cancer Inst* 1999; 91: 2081–2086.
- Wendt TG, Grabenbauer GG, Rodel CM et al. Simultaneous radiochemotherapy versus radiotherapy alone in advanced head and neck cancer: a randomized multicenter study. *J Clin Oncol* 1998; 16: 1318–1324.
- Teoh DC, Rodger S, Say J, Hartley A. Hypofractionated radiotherapy plus cetuximab in locally advanced head and neck cancer. *Clin Oncol (R Coll Radiol)* 2008; 20: 717.
- Bernier J, Bonner J, Vermorken JB et al. Consensus guidelines for the management of radiation dermatitis and co-existing acne-like rash in patients receiving radiotherapy plus EGFR inhibitors for the treatment of squamous cell carcinoma of the head and neck. *Ann Oncol* 2008; 19: 142–149.
- US Department of Health and Human Services. National Institutes of Health. National Cancer Institute. Common Terminology Criteria for Adverse Events (CTCAE). 28 May 2009 (v4.03: 14 June 2010). <http://evs.nci.nih.gov/ftp1/CTCAE/About.html> (October 2010, date last accessed).
- Madison KC. Barrier function of the skin: “la raison d’être” of the epidermis. *J Invest Dermatol* 2003; 121: 231–241.
- Pastore S, Mascia F, Mariani V, Girolomoni G. The epidermal growth factor receptor system in skin repair and inflammation. *J Invest Dermatol* 2008; 128: 1365–1374.
- Segaert S, Van Cutsem E. Clinical signs, pathophysiology and management of skin toxicity during therapy with epidermal growth factor receptor inhibitors. *Ann Oncol* 2005; 16: 1425–1433.
- Mascia F, Cataisson C, Lee TC et al. EGFR regulates the expression of keratinocyte-derived granulocyte/macrophage colony-stimulating factor in vitro and in vivo. *J Invest Dermatol* 2010; 130: 682–693.
- Pastore S, Mascia F, Mariotti F et al. ERK1/2 regulates epidermal chemokine expression and skin inflammation. *J Immunol* 2005; 174: 5047–5056.
- Sørensen OE, Thapa DR, Roupe KM et al. Injury-induced innate immune response in human skin mediated by transactivation of the epidermal growth factor receptor. *J Clin Invest* 2006; 116: 1878–1885.
- Albanell J, Rojo F, Averbuch S et al. Pharmacodynamic studies of the epidermal growth factor receptor inhibitor ZD1839 in skin from cancer patients: histopathologic and molecular consequences of receptor inhibition. *J Clin Oncol* 2002; 20: 110–124.
- Harari PM, Huang SM. Head and neck cancer as a clinical model for molecular targeting of therapy: combining EGFR blockade with radiation. *Int J Radiat Oncol Biol Phys* 2001; 49: 427–433.
- McQuestion M. Evidence-based skin care management in radiation therapy. *Semin Oncol Nurs* 2006; 22: 163–173.
- Bone RC. Systemic Inflammatory Response Syndrome: A Unifying Concept of Systemic Inflammation. Philadelphia, PA: Lippincott 1997.
- Heggie S, Bryant GP, Tripcony L et al. A phase III study on the efficacy of topical aloe vera gel on irradiated breast tissue. *Cancer Nurs* 2002; 25: 442–451.
- Olsen DL, Raub W Jr, Bradley C et al. The effect of aloe vera gel/mild soap versus mild soap alone in preventing skin reactions in patients undergoing radiation therapy. *Oncol Nurs Forum* 2001; 28: 543–547.
- Russi EG, Merlano MC, Comino A, Numico G. Ultrathin hydrocolloid dressing in skin damaged from alternating radiotherapy and chemotherapy plus cetuximab in advanced head and neck cancer (G.O.N.O. AlterRCC Italian Trial): in regard to Macmillan et al. (*Int J Radiat Oncol Biol Phys* 2007;68:864–872). *Int J Radiat Oncol Biol Phys* 2007; 69: 638–639.
- Burch SE, Parker SA, Vann AM, Arazie JC. Measurement of 6-MV X-ray surface dose when topical agents are applied prior to external beam irradiation. *Int J Radiat Oncol Biol Phys* 1997; 38: 447–451.
- Løkkevik E, Skovlund E, Reitan JB et al. Skin treatment with bepanthen cream versus no cream during radiotherapy—a randomized controlled trial. *Acta Oncol* 1996; 35: 1021–1026.
- Schmuth M, Wimmer MA, Hofer S et al. Topical corticosteroid therapy for acute radiation dermatitis: a prospective, randomized, double-blind study. *Br J Dermatol* 2002; 146: 983–991.
- Li T, Perez-Soler R. Skin toxicity associated with epidermal growth factor receptor inhibitors. *Target Oncol* 2009; 4: 107–119.
- Elliott EA, Wright JR, Swann RS et al. Phase III trial of an emulsion containing trolamine for the prevention of radiation dermatitis in patients with advanced squamous cell carcinoma of the head and neck: results of Radiation Therapy Oncology Group Trial 99-13. *J Clin Oncol* 2006; 24: 2092–2097.
- Halperin EC, Gaspar L, George S et al. A double-blind, randomized, prospective trial to evaluate topical vitamin C solution for the prevention of radiation dermatitis. CNS Cancer Consortium. *Int J Radiat Oncol Biol Phys* 1993; 26: 413–416.
- Pardo Masferrer J, Murcia Mejia M, Vidal Fernandez M et al. Prophylaxis with a cream containing urea reduces the incidence and severity of radio-induced dermatitis. *Clin Transl Oncol* 2010; 12: 43–48.
- Pommier P, Gomez F, Sunyach MP et al. Phase III randomized trial of Calendula officinalis compared with trolamine for the prevention of acute dermatitis during irradiation for breast cancer. *J Clin Oncol* 2004; 22: 1447–1453.
- Potera ME, Lookingbill DP, Stryker JA. Prophylaxis of radiation dermatitis with a topical cortisone cream. *Radiology* 1982; 143: 775–777.
- Williams MS, Burk M, Loprinzi CL et al. Phase III double-blind evaluation of an aloe vera gel as a prophylactic agent for radiation-induced skin toxicity. *Int J Radiat Oncol Biol Phys* 1996; 36: 345–349.
- Buiret G, Combe C, Favrel V et al. A retrospective, multicenter study of the tolerance of induction chemotherapy with docetaxel, cisplatin, and 5-fluorouracil followed by radiotherapy with concomitant cetuximab in 46 cases of squamous cell carcinoma of the head and neck. *Int J Radiat Oncol Biol Phys* 2010; 77: 430–437.