

Comparison of surgical and interventional therapy of native and recurrent aortic coarctation regarding different age groups during childhood

Seraina Früh^{a,1}, Walter Knirsch^{b,1,*}, Ali Dodge-Khatami^a, Hitendu Dave^a,
René Prêtre^a, Oliver Kretschmar^b

^aDivision of Pediatric and Congenital Cardiac Surgery, University Children's Hospital Zurich, Zurich, Switzerland

^bDivision of Pediatric Cardiology, University Children's Hospital Zurich, Zurich, Switzerland

Received 2 March 2010; received in revised form 21 September 2010; accepted 22 September 2010; Available online 18 December 2010

Abstract

Objective: The aim of the study was to analyze immediate results, rate of complications and re-interventions during medium-term outcome in pediatric patients with native or recurrent aortic coarctation. We focused on an age-related therapeutic approach comparing surgical and trans-catheter treatment. **Methods:** This is a retrospective, single-centre, clinical observational trial including 91 consecutive patients (age: 1 day–18 years) treated for native coarctation in 67 and recurrent aortic coarctation in 24 patients. Surgical treatment was performed in 56, trans-catheter treatment with balloon dilatation in 17, and by stent implantation in 18 patients. According to the age groups, we treated 48 children in group A (<6 months of age), 16 in group B (6 months–6 years), and 27 in group C (>6 years). A total of 41 patients in group A were operated (85%), patients in group B received either surgical or trans-catheter treatment (50% vs 50%), and 16 patients in group C were treated by stent implantation (62%). **Results:** Immediate results were excellent with a significant release of pressure gradient in all three age groups (64.7% in group A, 69.1% in group B, and 63.3% in group C). Complication rate and re-intervention rate (surgical and interventional) were both comparable between the three age groups (complications: group A 8.3%, group B 6.3%, and group C 3.7%; re-interventions: group A 16.6%, group B 18.8%, and group C 18.5%). Midterm outcome after a median follow-up period of 17.5 months was satisfactory with a re-intervention-free survival after 17.5 months of 83.4%, 81.2%, and 81.5% in group A, group B, and group C, respectively. **Conclusions:** The current strategy of an age-related therapy for native and recurrent aortic coarctation in our institution is surgery in infants <6 months (group A), either surgery or balloon dilatation in younger patients <6 years (group B), while in older children >6 years of age (group C) the trans-catheter treatment with stent implantation is an excellent alternative to surgery. Balloon dilatations showed limited results with an overall re-intervention rate of 53% and, therefore, should mainly be performed as a rescue procedure or in recurrent aortic coarctation in neonates.

© 2010 European Association for Cardio-Thoracic Surgery. Published by Elsevier B.V. All rights reserved.

Keywords: Aortic coarctation; Pediatric cardiac surgery; Stent; Trans-catheter treatment; Balloon dilatation

1. Introduction

Aortic coarctation (CoA) is a common congenital lesion in children with a frequency of 4–6% of all types of congenital heart defects. Aortic obstruction may be relieved by cardiac surgery or by trans-catheter techniques. Trans-catheter techniques include balloon angioplasty and endoluminal stent implantation, which have been established with successful immediate and long-term results in the past [1–7]. However, different clinical

studies comparing these three therapeutic options show conflicting data [8–14]. The long-term results of CoA, for either native or recurrent CoA after surgery, have been described for adolescents and adults [15,16], but the influence of the factor age, especially in the younger pediatric population, on the outcome of treatment of CoA, has not been described.

In our institution, neonates and infants with native CoA are routinely treated by surgery. By contrast, older children and adolescents are treated by stent implantation for native CoA. Balloon dilatation is performed mainly in recurrent aortic coarctation (Re-CoA), especially in neonates and infants.

Therefore, the aim of our study was to evaluate our age-related approach by comparing the results of the three treatment strategies: surgery, balloon dilatation, and stent implantation.

* Corresponding author. Address: Pediatric Cardiology, University Children's Hospital, Steinwiesstrasse 75, CH - 8032 Zurich, Switzerland.
Tel.: +41 44 266 7617; fax: +41 44 266 7981.

E-mail address: walter.knirsch@kispi.uzh.ch (W. Knirsch).

¹ Contributed equally as first authors.

2. Materials and methods

2.1. Patients

In our institution, all consecutive patients treated for native CoA and Re-CoA between September 2001 and September 2006 with an age younger than or equal to 18 years were treated according to our age-related treatment using surgery by a majority for neonates and infants, and stent implantation for older children (>6 years) and adolescents for native and recurrent CoA. The study was designed as a single-center, clinical, retrospective, observational trial. Medical records, angiographies, and echocardiographic and hemodynamic data were reviewed. Further follow-up was obtained by clinical evaluation (blood pressure gradient between upper and lower extremities) and two-dimensional and Doppler echocardiography. Study end points were re-interventions either by a second catheter intervention or by surgery. The study was approved by the local ethics committee.

All patients included in the study cohort had the cardiac diagnosis of an isolated native CoA or Re-CoA, either after surgery or after catheter-based therapy. Concomitant minor cardiac anomalies, for example, small ventricular septal defect (VSD), atrial septal defect (ASD), or mild aortic valve stenosis (AS, systolic blood pressure gradient ≤ 20 mmHg) were included, while all children with other major cardiac anomalies, for example, accessory severe generalized hypoplastic aortic arch anomalies such as in patients with hypoplastic left heart syndrome, were excluded.

The indications for treatment of native CoA with respect to Re-CoA were similar with (1) systolic blood pressure gradient of more than 20 mmHg between arms and legs, (2) an arterial hypertension of the upper extremities at rest or during exercise (after exclusion of other reasons for arterial hypertension), and (3) signs of left ventricular hypertrophy in echocardiography.

To compare the age-related therapy for native CoA and Re-CoA, we arbitrarily divided our patient cohort into three groups according to their age with group A less than 6 months of age, group B between 6 months and 6 years of age, and group C between 6 and 18 years of age.

2.2. Cardiac surgery

Cardiac surgery was performed by two experienced surgeons. The coarctation site was approached through a muscle-sparing left posterior thoracotomy with an extra- or transpleural access or by median sternotomy. The technique of extrapleural access to the operation site was performed as described earlier by Dave et al. [17]. Full dissection and mobilization of the aortic arch and the arch vessels and mobilization of the descending aorta permitted an extended resection and end-to-end anastomosis [18,19] of the descending aorta to the distal aortic arch without tension.

2.3. Catheter interventions

Cardiac catheter interventions were performed under general anesthesia. Percutaneous vessel access was achieved in all cases via the femoral artery. Heparin (100 units kg^{-1})

was given after successful arterial access, and repeated after 1 h (50 units kg^{-1}). The coarctation was crossed in a retrograde manner with a diagnostic catheter, and peak pressure gradients between the ascending aorta and the descending aorta were measured. Angiography of the coarctation was performed and recorded in the left anterior oblique (LAO 10–20°) and lateral projections (LAO 90°). The following bilateral measurements were performed: smallest diameter of the coarctation; diameter of the transverse aortic arch; and diameter of the descending aorta proximally and distally to the site of coarctation. The diameter of the balloon used for dilatation was chosen equally or 1 mm more than the diameter of the transverse aortic arch. Dilatation was performed over a period of 10 s; adenosine was used in some cases. Stent implantation was performed via a retrograde approach using a long sheath, which allowed a proper stent positioning and hand injections of contrast medium during implantation [20]. The stent was placed in most of the cases on a BiB balloon (balloon in balloon, NuMed Inc., Nicholville, NY, USA) allowing a precise and safe stent delivery. Immediately after balloon dilation or stent implantation, the invasive residual pressure gradient was measured and angiography was performed.

2.4. Follow-up

At the time of early (24 h after intervention) and late (last follow-up) follow-up, Doppler echocardiographic gradients were measured in both the surgical and trans-catheter group, respectively.

Significant early and late complications of the procedures were chylothorax, aortic aneurysm, vessel thrombosis, and stent dislocation.

Re-intervention was defined as secondary surgical or catheter interventional redo. Hemodynamic indication for re-intervention was a systolic pressure gradient of more than 20 mmHg across the recoarctation of the aortic arch. The follow-up period ended with the need for a re-intervention.

2.5. Statistics

Results are presented as mean and standard deviations or as median and ranges, as appropriate. For comparisons of Doppler gradients before and at day 1 after intervention, we used the Wilcoxon signed-rank test for each age group. For comparison of Doppler gradients before and at day 1 after intervention and for comparison of the performed procedure (surgery, balloon dilatation, or stent implantation), we used the Mann–Whitney *U* test to compare two procedures; and the Kruskal–Wallis one-way analysis of variance was used to compare all three procedures. Analyses were performed using Statistical Package for Social Sciences (SPSS) 16 (SPSS Inc., Chicago, IL, USA). A *p* value less than 0.05 was considered as significant.

3. Results

We enrolled 91 patients (61 males) treated for CoA ($n = 67$) and Re-CoA ($n = 24$). The median age at the time of the intervention was 0.4 years (range 1 day–18 years). The patients were treated either by surgery ($n = 56$) or by

interventional catheterization ($n = 35$). A total of 48 children were treated at an age <6 months (group A), 17 children were treated at an age between 6 months and 6 years (group B), and 26 older children and adolescents were treated at an age >6 years (group C). The age distribution of children treated for CoA and Re-CoA with the different techniques is shown in Figs. 1 and 2.

The follow-up period for the whole patient group was 17.5 months (range 1 day–60 months), within group A 20.5 months (1 day–60 months), group B 15 months (2–33 months), and group C 13 months (0.5–57 months).

Five patients younger than 6 months of age (group A) with native CoA were treated by balloon dilatation ($n = 4$) or stent implantation ($n = 1$) instead of surgery in a rescue procedure due to severe congestive heart failure. Four of five patients were treated by surgery after recovery of myocardial function; one patient after balloon dilatation recovered completely without any further re-intervention (Fig. 1).

One 7-year-old patient (group C) with native CoA was treated by surgery instead of stent implantation because moderate transverse aortic-arch hypoplasia was associated with CoA.

3.1. Cardiac surgery

Within the 91 enrolled children, 56 (37 males) underwent cardiac surgery. The median age of this group was 1.7 years (range 1 day–18 years) and median weight 4.8 kg (1–60 kg). The surgical access was left-sided posterior thoracotomy in 52 and median sternotomy in four patients, in one due to simultaneous ASD and VSD closure, and in three patients due to aortic arch extension plasty (all patients with Re-CoA). The surgical technique was an extended end-to-end anastomosis in 51 patients (91%), subclavian flap plasty in one (1.8%), U-

sliding plasty in one (1.8%), and patch augmentation in three (3.6%).

3.2. Catheter interventions

Trans-catheter interventions were balloon angioplasty performed in 17, and stent implantation in 18 patients (total 35 patients). The median age was 13.4 years (range 17 days–17 years) and median weight 28 kg (3.2–6 kg). Twenty-two patients had native CoA (61%) and 13 had Re-CoA.

Children <6 years of age treated by catheter interventions mainly underwent balloon angioplasty (13 of 15, 87%), whereas in the group of children >6 years of age (group C) stent implantation predominated (16 of 20, 80%), as shown in Figs. 1 and 2.

The median diameter of the used balloons was 8 mm (range 5–14 mm). These balloons had a low-pressure profile with a maximum pressure of 3.5 atm to be achieved during dilatation. The following stents were used: Cheatham Platinum (CP) Stents (NuMed Inc., Nicholville, NY, USA) in nine patients, Palmaz Genesis Stents (Johnson & Johnson Interventional System, Somerville, NJ, USA) in seven patients, and Jomed Stent (JOMED Deutschland, Haan, Germany) in two patients.

A significant decrease of Doppler gradient (%) was achieved in all three age groups (64.7% in group A, 69.1% in group B, and 63.3% in group C, $p < 0.05$), respectively (Table 1, Fig. 3). Comparing the type of procedure (surgery, balloon dilatation, or stent implantation), we found in group A significant higher decrease of Doppler gradient in patients treated by surgery (70.2%) compared with balloon dilatation (34.4%) (36.6 ± 17.3 pre- vs 10.9 ± 15.0 mmHg post-day 1 after surgery compared with 48.0 ± 7.3 pre- vs 31.5 ± 18.6 mmHg post-day 1 after balloon dilatation,

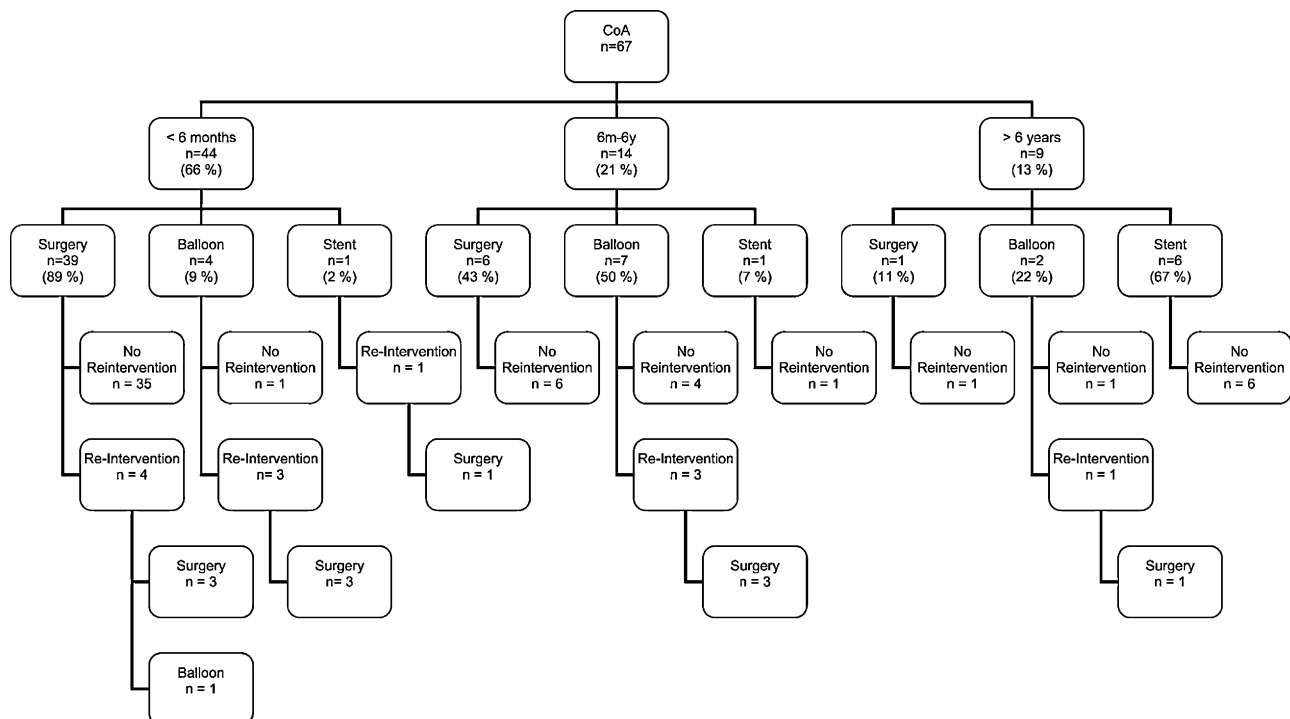


Fig. 1. Age-related treatment of native aortic coarctation (CoA) by cardiac surgery, balloon dilatation and stent implantation.

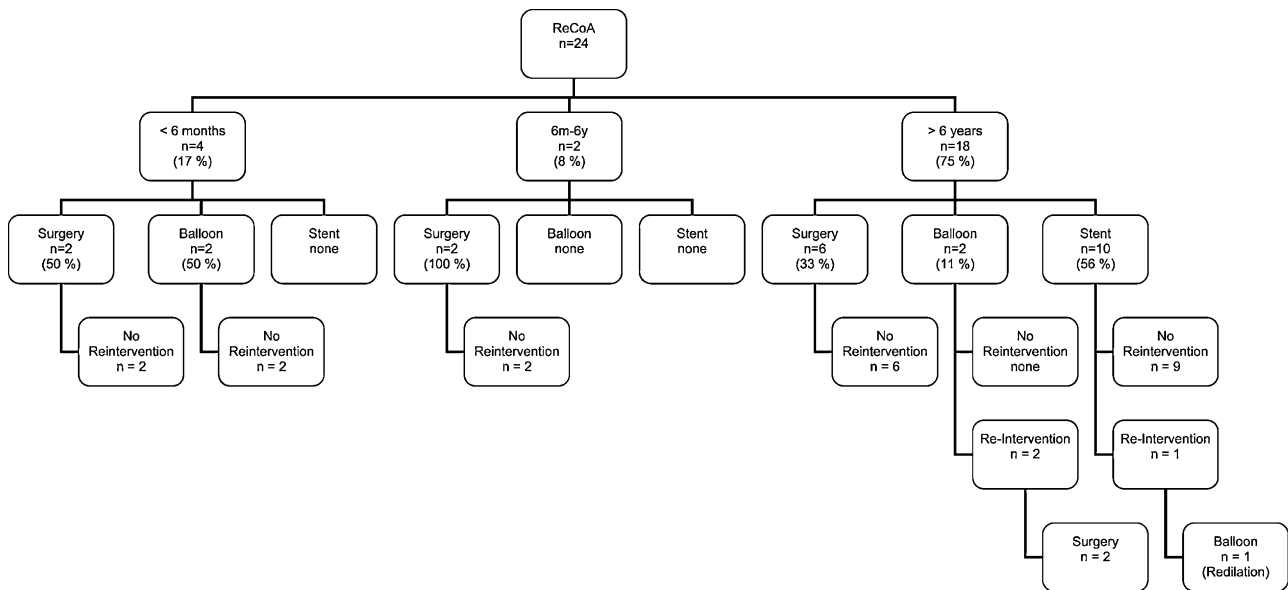


Fig. 2. Age-related treatment of recurrent aortic coarctation (Re-CoA) by cardiac surgery, balloon dilation and stent implantation.

$p = 0.017$). No differences between the three types of procedures were found in group B. In group C, we found a significant higher decrease of Doppler gradient in patients treated by stent implantation (73.7%) compared with balloon dilatation (10.3%) (43.3 ± 15.5 pre- vs 11.4 ± 13.0 mmHg post-day 1 after stent implantation compared with 39.8 ± 16.3 pre- vs 35.7 ± 11.2 mmHg post-day 1 after balloon dilatation, $p = 0.022$).

According to the type of pathology of CoA (native or recurrent), significant decrease in Doppler gradients for native versus Re-CoA were: in age group A 65.0% versus 62.5%, in age group B 68.7% versus 71.6%, and in age group C 48.7% versus 69.8%. Comparing the type of CoA (native or recurrent), we found no differences in decrease of Doppler gradients within each group.

In the whole patient group, re-interventions became necessary in 16 patients (17.6%), including eight patients in group A (children <6 months) (16.6%), three patients in group B (children between 6 months and 6 years) (18.8%), and five patients in group C (children >6 years) (18.5%). Re-interventions were performed after a median time interval

of 3 months (range 1 day–50 months) of the primary intervention.

Twelve re-interventions were necessary in patients treated for native CoA (18%) and three redos in patients with Re-CoA (12.5%) (Figs. 1 and 2).

In all other patients, after a median follow-up of 17.5 months, there was no significant increase of Doppler gradients.

Early and late complication rates for the whole patient group were low (6.6%).

Complications occurred in four patients of group A (children <6 months of age) (8.3%). After surgery, chylothorax requiring tube drainage occurred in one patient. After percutaneous intervention, stent dislocation into the descending aorta occurred in one patient. In this patient, a balloon dilatation of the coarctation and placement of the dislocated stent in the descending aorta was possible and a secondary re-operation could be successfully performed after 2 months. Arterial thrombosis occurred in another two patients after trans-catheter intervention. In group B (children between 6 months and 6 years of age), there was

Table 1. Immediate hemodynamic results by Doppler echocardiography, rate of complications and re-interventions during medium-term follow-up in different age groups for pediatric patients with native and recurrent coarctation of aortic arch.

	Group A Age < 6 months (n = 48)	Group B Age > 6 months–6 years (n = 16)	Group C Age > 6 years (n = 27)	Total Age 0–18 years (n = 91)
Doppler gradient pre [mmHg]	37.7 ± 16.9	46.0 ± 13.5	45.5 ± 16.3	41.4 ± 16.4
Doppler gradient post-day 1 [mmHg]	$13.3 \pm 16.3^*$	$14.2 \pm 15.6^*$	$16.7 \pm 14.9^*$	$14.4 \pm 15.7^*$
Rate of gradient reduction [%]	64.7	69.1	63.3	65.2
Rate of complications [n]	4 (8.3%)	1 (6.3%)	1 (3.7%)	6 (6.6%)
Rate of re-interventions [n]	8 (16.6%)	3 (18.8%)	5 (18.5%)	16 (17.6%)
Follow-up, median (range) [months]	20.5 (0–60)	15 (2–33)	13 (0.5–57)	17.5 (0–60)

Data are given as mean and standard deviation. Wilcoxon signed-rank test was used for comparison of Doppler gradient pre versus post-day 1.

* $p < 0.05$.

Table 2. Review of the literature for trans-catheter and surgical therapy for native and recurrent coarctation of the aortic arch in different age groups [2,3,5–11,19,25].

Author/ year	CoA/ Re-CoA	Type of treatment	Number of patients (n)	Age range	Complications						Re- interventions	Median follow-up (months)
					Aneurysm	Thrombosis	Stent disl	Chylothorax	Death	Others		
Wood et al. (2004) [19]	CoA	Surgery	181	0–1 years					0.5% ^{‡‡}	2.7%	2%	90
Wright et al. (2005) [25]	CoA	Surgery	83	0–1 years				2%	4%	3% ^{††}	6%	54
Ovaert et al. (2000) [6]	CoA	Balloon	69	6 months– 16.8 years	1%	11%			1%		13%	34
Hamdan et al. (2001) [2]	CoA/ Re-CoA	Stenting	34	4–36 years			11%		4%	9%*	9%	28
Harrison et al. (2001) [3]	CoA/ Re-CoA	Stenting	27	14–63 years	9%		3%			6% [†]	4%	22
Marshall et al. (2000) [5]	CoA/ Re-CoA	Stenting	33	5–60 years		3%				6% [‡]	24%	27
Suarez de Lezo et al. (2005) [7]	CoA/ Re-CoA	Stenting	73	20 ± 12 years		7%	3%		1%		0%	60
Hernandez- Gonzalez et al. (2003) [9]	CoA/ Re-CoA	Surgery	28	7 ± 4.1 years	25%			4%	7%	36% [§]	21%	16
	CoA/ Re-CoA	Balloon	30	6.6 ± 4.4 years	17%	10%			3.5%	33%	50%	16
Cowley et al. (2005) [8]	CoA	Surgery	16	5.7 ± 2.1 years	0%						13%	136
	CoA	Balloon	20	6.3 ± 2.0 years	35%						30%	127
Pedra et al. (2005) [10]	CoA	Balloon	15	18 ± 10 years	13%						7%	60
	CoA	Stenting	21	24 ± 11 years	5%	5%	10%				10%	22
Rodes-Cabeau et al. (2007) [11]	CoA	Surgery	30	1–35 years				3%		60% ^{**}	0%	43
	CoA	Balloon	31	1–38 years	1%					16% [†]	26%	38
	CoA	Stenting	19	1–38 years			11%				5%	38

Abbreviations: CoA: coarctation of aortic arch, disl: dislocation, Re-CoA: recurrent coarctation of aortic arch; *: 1 femoral arteriovenous fistula, 1 retroperitoneal hematoma, 1 dislocation of ruptured balloon fragment into the left axillary artery with need for surgical repair; †: 1 balloon rupture, 1 cerebral insult; ‡: 1 myocardial infarction, 1 complete heart block with need for cardiopulmonary resuscitation for 30 s; §: 2 major bleedings, 1 systemic arterial hypertension crisis, 1 diaphragmatic nerve injury, 3 pulmonary sepsis, 1 cardiogenic shock, 2 dehiscence sutures; ||: 3 major bleedings, 1 systemic arterial hypertension crisis, 1 anaphylactic shock, 1 cardiogenic shock, 4 inguinal hematoma; ††: 3 access site complications, 2 paradoxical arterial hypertension, 1 hematuria, 1 chest hematoma; **: 2 pleural effusion, 1 respiratory distress, 3 access site complications, 11 paradoxical hypertension, 1 reperfusion syndrome; ‡‡: 3 technical related complications; ‡‡: 0.5% hospital/30-day-mortality, plus 15 (8%) late deaths.

one significant complication (6.3%) with the occurrence of a significant aortic aneurysm after balloon dilatation leading to re-operation after 7 months. In group C (children >6 years of age), arterial thrombosis of the femoral artery occurred in one patient (3.7%) treated surgically for Re-CoA with peripheral cannulation for extracorporeal perfusion; a vein graft was used as bypass material.

There was no mortality associated with surgery or trans-catheter treatment or redo intervention.

4. Discussion

This is the first systematic report presenting an age-related comparison of the therapy of native or recurrent aortic coarctation from infancy to adolescence.

The strategy in our center is primary surgery in infants less than 6 months of age and primary trans-catheter treatment with stent implantation in children >6 years of age. Patients

between 6 months and 6 years of age receive either surgery or balloon dilatation, mainly depending on the morphology of the coarctation. Therefore, the indication for surgery instead of balloon dilatation or stent implantation is given in case of associated severe aortic arch hypoplasia. The extent of aortic arch hypoplasia is variable and requires interdisciplinary decision-making procedures by surgeons and interventionists.

This age-related approach has proven to be practicable with promising early and late results. Primary treatment at any age, either by surgery or by trans-catheter treatment, leads to a significant and lasting reduction of the pressure gradient across the aortic arch. We have seen an acceptable low complication rate between 3.7% in group C (>6 years), 6.3% in group B (6 months–6 years) and 8.3% in group A (<6 months). A re-intervention rate between 16.6 and 18.8% is also comparable with the results reported of other study groups, although the hemodynamic indication for re-intervention in our institution is rather restrictive [7,8,10]. The

different re-intervention rates for balloon dilatation, surgery, and stent implantation are shown in Table 2.

In the very young patients <6 months of age (group A), the early and long-term results of surgical resection are excellent. These data confirm surgery as the treatment of choice in this specific age group. Wood et al. have shown excellent long-term results after extended arch aortoplasty confirming our data [19]. A limited number of studies comparing surgery and balloon dilatation showed significantly lower re-intervention and complication rates after surgery than after balloon angioplasty [7,8,10]. In our institution, percutaneous procedures in this age group mainly serve as a rescue therapy for patients in severe heart failure, to stabilize their clinical condition and bridge them to definitive surgical correction later on. We were able to perform either balloon angioplasty ($n = 4$) or stent implantation ($n = 1$) in these high-risk patients with a good initial relief of the pressure gradient without significant morbidity or mortality (Fig. 1).

In children between 6 months and 6 years of age (group B) with isolated CoA, the acute results of reduction of gradients between surgery and angioplasty are comparable, as shown in the literature for similar age groups [6,21]. In our series, the rate of re-interventions in this age group was higher after angioplasty (37.5%) (Fig. 1). Re-intervention after angioplasty was necessary in three patients (Fig. 1): in one due to the formation of an aortic aneurysm after 7 months needing corrective surgery, and in two patients due to early (after 2 months) or late (after 16 months) restenosis leading to surgical repair. The overall rate of significant aortic aneurysm formation leading to surgery in our group was very low (1.1%). Nevertheless, long-term follow-up using magnetic resonance imaging (MRI) is recommended to detect aneurysm formation even years after primary or secondary intervention [8]. Stent implantation is not recommended in this age group due to the need for frequent redilatation in growing children, the lack of redilatable stents until adulthood, a high incidence of intimal proliferation in small stents and the potential development of post-stent aneurysm formation [20].

In children >6 years of age (group C), stent implantation is an excellent therapeutic alternative to surgery. Stents have the unique property to avoid elastic recoil of the vessel wall and to fix and stabilize the dissected intima and, by this, minimize the risk for aortic rupture and aneurysm formation. Previous studies have shown the safety of stent implantations in adolescents with excellent medium-term outcomes [2,3,10,22,23]. In our series, stent implantation was performed successfully with a low rate of re-interventions (6.3%) and no complications [2,4,11]. This interventional approach is suitable either for native CoA (Fig. 1) as well as for Re-CoA (Fig. 2) and the results are comparable to those of surgery. Of course, due to somatic growth of the children, there exists the need for further redilatation after stent implantation. We now routinely implant the CP stent (NuMed Inc., Nicholville, NY, USA), which enables redilatation sufficient for adult aortic sizes [18]. This platinum stent has perfect material properties with high radial forces, excellent tissue tolerance with optimal adhesion to the vessel wall, low fracture rates during follow-up, acceptable stent shortening during redilatation, and MRI compatibility [18,21]. It has been shown that serial dilatations of the CP stent, either covered or uncovered, are feasible, safe, and

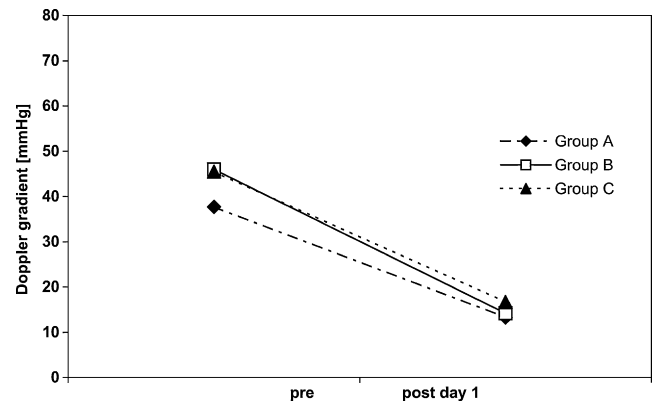


Fig. 3. Decrease of echocardiographic Doppler gradient comparing mean value pre and post-interventional at day 1 in children treated for CoA, and Re-CoA in three age groups with 64.7% in group A (age < 6 months), 69.1% in group B (age 6 months to 6 years), and 63.3% in group C (age > 6 years). For all groups: $p < 0.05$.

effective [21]. The only 're-intervention' (balloon redilatation) in our study group was necessary due to outgrowth of the original stent diameter in one patient.

We prefer to implant covered stents in patients with subaortic CoA, in adult patients, or after aortic dissection. In our opinion, in patients with a complex CoA/Re-CoA with hypoplasia of the aortic arch, surgery is, in most cases, a safe and the more effective approach.

Limitations of this study are its retrospective and non-randomized design, the miscellaneous collective, the relatively low number of patients in the subgroups, and only medium-term follow-up time. Isolated CoA may be associated with borderline hypoplasia of parts of the transverse aortic arch. Therefore, we included these borderline patients. Other confounders such as experience of the surgeon and anatomic differences could not be completely ruled out.

Promising new devices such as the growth stent or biodegradable stents have been developed [24]. Possibly, they might help to shift successful and durable trans-catheter interventions in early childhood and, by this, replace a certain amount of surgical procedures in these patients.

In the future, further prospective, multicenter trials are needed to investigate the medium- and long-term outcome of surgical and trans-catheter treatment by comparing patients in different age groups ranging from the neonatal period until adolescence and young adulthood.

References

- [1] Duke C, Rosenthal E, Qureshi SA. The efficacy and safety of stent redilatation in congenital heart disease. *Heart* 2003;89:905–12.
- [2] Hamdan MA, Maheshwari S, Fahey JT, Hellenbrand WE. Endovascular stents for coarctation of the aorta: initial results and intermediate-term follow-up. *J Am Coll Cardiol* 2001;38:1518–23.
- [3] Harrison DA, McLaughlin PR, Lazzam C, Connelly M, Benson LN. Endovascular stents in the management of coarctation of the aorta in the adolescent and adult: one year follow up. *Heart* 2001;85:561–6.
- [4] Mahadevan VS, Vondermuhll IF, Mullen MJ. Endovascular aortic coarctation stenting in adolescents and adults: angiographic and hemodynamic outcomes. *Catheter Cardiovasc Interv* 2006;67:268–75.
- [5] Marshall AC, Perry SB, Keane JF, Lock JE. Early results and medium-term follow-up of stent implantation for mild residual or recurrent aortic coarctation. *Am Heart J* 2000;139:1054–60.

- [6] Ovaert C, McCrindle BW, Nykanen D, MacDonald C, Freedom RM, Benson LN. Balloon angioplasty of native coarctation: clinical outcomes and predictors of success. *J Am Coll Cardiol* 2000;35:988–96.
- [7] Suarez de Lezo J, Pan M, Romero M, Segura J, Pavlovic D, Ojeda S, Algar J, Ribes R, Lafuente M, Lopez-Pujol J. Percutaneous interventions on severe coarctation of the aorta: a 21-year experience. *Pediatr Cardiol* 2005;26:176–89.
- [8] Cowley CG, Orsmond GS, Feola P, McQuillan L, Shaddy RE. Long-term, randomized comparison of balloon angioplasty and surgery for native coarctation of the aorta in childhood. *Circulation* 2005;111:3453–6.
- [9] Hernandez-Gonzalez M, Solorio S, Conde-Carmona I, Rangel-Abundis A, Ledesma M, Munayer J, David F, Ortegón J, Jimenez S, Sanchez-Soberanis A, Melendez C, Claire S, Gomez J, Teniente-Valente R, Alva C. Intraluminal aortoplasty vs. surgical aortic resection in congenital aortic coarctation. A clinical random study in pediatric patients. *Arch Med Res* 2003;34:305–10.
- [10] Pedra CA, Fontes VF, Esteves CA, Pilla CB, Braga SL, Pedra SR, Santana MV, Silva MA, Almeida T, Sousa JE. Stenting vs. balloon angioplasty for discrete unoperated coarctation of the aorta in adolescents and adults. *Catheter Cardiovasc Interv* 2005;64:495–506.
- [11] Rodes-Cabau J, Miro J, Dancea A, Ibrahim R, Piette E, Lapierre C, Jutras L, Perron J, Tchervenkov CI, Poirier N, Dahdah NS, Houde C. Comparison of surgical and transcatheter treatment for native coarctation of the aorta in patients > or = 1 year old. The Quebec Native Coarctation of the Aorta study. *Am Heart J* 2007;154:186–912.
- [12] Shaddy RE, Boucek MM, Sturtevant JE, Ruttenberg HD, Jaffe RB, Tani LY, Judd VE, Veasy LG, McGough EC, Orsmond GS. Comparison of angioplasty and surgery for unoperated coarctation of the aorta. *Circulation* 1993;87:793–9.
- [13] Wong D, Benson LN, Van Arsdell GS, Karamlou T, McCrindle BW. Balloon angioplasty is preferred to surgery for aortic coarctation. *Cardiol Young* 2008;18:79–88.
- [14] Zabal C, Attie F, Rosas M, Buendia-Hernandez A, Garcia-Montes JA. The adult patient with native coarctation of the aorta: balloon angioplasty or primary stenting? *Heart* 2003;89:77–83.
- [15] Hoimyr H, Christensen TD, Emmertsen K, Johnsen SP, Riis A, Hansen OK, Hjortdal VE. Surgical repair of coarctation of the aorta: up to 40 years of follow-up. *Eur J Cardiothorac Surg* 2006;30:910–6.
- [16] Walhout RJ, Suttorp MJ, Mackaij GJ, Ernst JM, Plokker HW. Long-term outcome after balloon angioplasty of coarctation of the aorta in adolescents and adults: is aneurysm formation an issue? *Catheter Cardiovasc Interv* 2009;73:549–56.
- [17] Dave HH, Buechel ER, Pretre R. Muscle-sparing extrapleural approach for the repair of aortic coarctation. *Ann Thorac Surg* 2006;81:243–8.
- [18] Dodge-Khatami A, Backer CL, Mavroudis C. Risk factors for recoarctation and results of reoperation: a 40-year review. *J Card Surg* 2000;15:369–77.
- [19] Wood AE, Javadpour H, Duff D, Oslizlok P, Walsh K. Is extended arch aortoplasty the operation of choice for infant aortic coarctation? Results of 15 years' experience in 181 patients. *Ann Thorac Surg* 2004;77:1353–7 [discussion 1357–8].
- [20] Bulbul ZR, Bruckheimer E, Love JC, Fahey JT, Hellenbrand WE. Implantation of balloon-expandable stents for coarctation of the aorta: implantation data and short-term results. *Catheter Cardiovasc Diagn* 1996;39:36–42.
- [21] Pandey R, Jackson M, Ajab S, Gladman G, Pozzi M. Subclavian flap repair: review of 399 patients at median follow-up of fourteen years. *Ann Thorac Surg* 2006;81:1420–8.
- [22] Magee AG, Brzezinska-Rajszys G, Qureshi SA, Rosenthal E, Zubrzycka M, Ksiazek J, Tynan M. Stent implantation for aortic coarctation and recoarctation. *Heart* 1999;82:600–6.
- [23] Pedra CA, Fontes VF, Esteves CA, Arrieta SR, Braga SL, Justino H, Kambara AM, Moreira SM, Sousa JE. Use of covered stents in the management of coarctation of the aorta. *Pediatr Cardiol* 2005;26:431–9.
- [24] Schranz D, Zartner P, Michel-Behnke I, Akinturk H. Bioabsorbable metal stents for percutaneous treatment of critical recoarctation of the aorta in a newborn. *Catheter Cardiovasc Interv* 2006;67:671–3.
- [25] Wright GE, Nowak CA, Goldberg CS, Ohye RG, Bove EL, Rocchini AP. Extended resection and end-to-end anastomosis for aortic coarctation in infants: results of a tailored surgical approach. *Ann Thorac Surg* 2005;80:1453–9.