

## Acute Renal Failure on Immune Reconstitution in an HIV-Positive Patient with Miliary Tuberculosis

Andreas W. Jehle,<sup>1</sup> Nina Khanna,<sup>2</sup> Jörg-Peter Sigle,<sup>2</sup> Katharina Glatz-Krieger,<sup>3</sup> Manuel Battegay,<sup>2</sup> Jürg Steiger,<sup>1</sup> Michael Dickenmann,<sup>1</sup> and Hans H. Hirsch<sup>2,4</sup>

Divisions of <sup>1</sup>Transplantation Immunology and Nephrology and <sup>2</sup>Infectious Diseases, and Institutes for <sup>3</sup>Pathology and <sup>4</sup>Medical Microbiology, University Hospitals Basel, Switzerland

**Immune reconstitution syndrome following HAART in human immunodeficiency virus (HIV)-infected patients is characterized by inflammatory worsening of organ functions despite improvement in HIV surrogate markers of HIV infection. We describe a patient with miliary tuberculosis and urinary shedding of acid fast bacilli who developed acute renal failure 8 weeks after initiation of antituberculosis therapy and 6 weeks after initiation of HAART. The diagnostic workup and further course of disease implicated immune reconstitution syndrome as the cause of acute renal failure.**

Acute renal failure (ARF) is frequently encountered in patients with HIV infection [1,2]. In a recent retrospective study of 92 HIV-infected patients with ARF admitted to a nephrology unit [3], at least 10 different entities were diagnosed: hemolytic-uremic syndrome (in 35% of patients), acute tubular necrosis (in 26%), HIV-associated nephropathy (in 15%), acute interstitial nephritis (in 2%), obstructive renal failure due to lymphoma and drug- and paraprotein-mediated causes (in 17%), and various forms of glomerulonephritis (in 4%). In contrast to ARF due to prerenal and postrenal causes, renal forms of ARF in HIV-infected patients are often related to HIV-mediated viral or immunological disease, or to treatment-related toxicity, both of which have changed since the introduction of HAART [1–3].

**Case report.** A 58-year-old male was hospitalized because of fever and weight loss of >10 kg in the 3 months prior to

hospital admission. HIV infection (CD4 cell count, 69 cells/ $\mu$ L; virus load, 1,247,786 copies/mL) and miliary tuberculosis was diagnosed. Acid-fast bacteria were seen in bronchoalveolar lavage fluid and in urine specimens. *Mycobacterium tuberculosis* was identified by culture and specific PCR. The patient was initially treated with standard doses of 4 antituberculosis agents (isoniazid, rifampicin, pyrazinamid, and ethambutol). Primary prophylaxis with trimethoprim-sulfamethoxazole (TMP-SMX) 3 times weekly was started. After 2 weeks, rifampicin was replaced with rifabutin at a reduced dosage of 150 mg q.o.d., at the time when HAART was initiated (zidovudine, lamivudine, and lopinavir/ritonavir) (figure 1). Drug-susceptibility testing of the *Mycobacterium tuberculosis* isolate revealed no resistance, and a 3-drug regimen consisting of isoniazid, pyrazinamid, and rifabutin was administered. The clinical condition improved, and the patient was referred to a rehabilitation clinic.

However, after 2 months, ARF developed with rising serum creatinine concentrations of 4.89 mg/dL (433  $\mu$ mol/L), and the patient was readmitted to the hospital. Overall, the clinical status had improved. There was no fever, coughing, or lymphadenopathy. Macrocytic hyperchromic anemia was found, with a hemoglobin concentration of 9 g/dL. The C-reactive protein level measured 95 mg/L (normal range, <5 mg/L), increasing to 142 mg/L. The HIV load had decreased by 4 log<sub>10</sub> to 104 copies/mL, and the CD4 cell count had increased to 82 cells/ $\mu$ L. Urine analysis showed mild proteinuria with a tubulointerstitial pattern (urine protein to creatinine concentration of 53 mg/mmol, and ratios of  $\alpha$ -1 microglobulin to creatinine and retinol-binding protein to creatinine increased by 31-fold and 46-fold, respectively) in addition to few granular casts and few leukocytes. Serial CT of the chest showed newly accentuated pulmonary infiltrates. Bronchoscopy and bronchoalveolar lavage were performed and revealed lymphocytosis, but yielded negative results for a range of infectious agents, including *Mycobacterium tuberculosis*, *Mycoplasma* and *Chlamydia* species, cytomegalovirus, and bacterial pathogens. A renal biopsy was performed. Histologic examination showed severe, nondestructive, granulomatous nephritis with interstitial infiltrates (figure 2). Immunohistochemical analysis was negative for complements C3 and C5b-9, fibrin, IgA, IgM, and IgG (not shown).

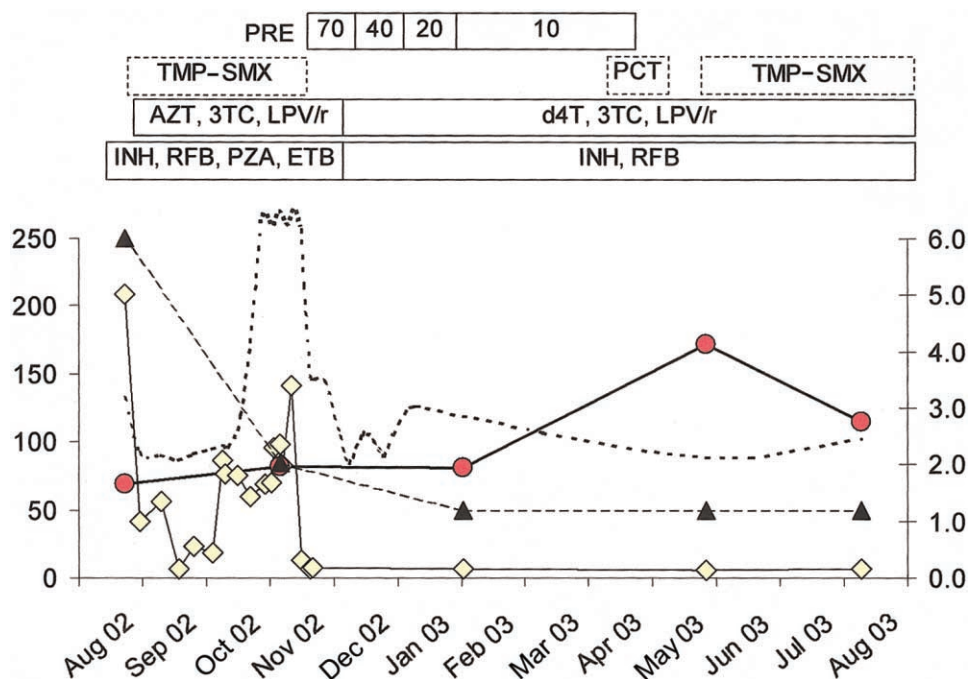
The diagnosis of immune reconstitution syndrome with manifestations in the lungs and kidneys was made 2 months after initiation of HAART, which effectively suppressed HIV replication and resulted in improved CD4 cell counts. Prednisone was administered at a dosage of 1 mg/kg for 2 weeks with a tapering dosage (figure 1). HAART was continued, but

Received 19 September 2003; accepted 3 November 2003; electronically published 30 January 2004.

Reprints or correspondence: Dr. Hans H. Hirsch, Division of Infectious Diseases, University Hospitals Basel, Petersgraben 4 CH-4031, Basel, Switzerland.

**Clinical Infectious Diseases** 2004;38:e32–5

© 2004 by the Infectious Diseases Society of America. All rights reserved.  
1058-4838/2004/3804-00E2\$15.00



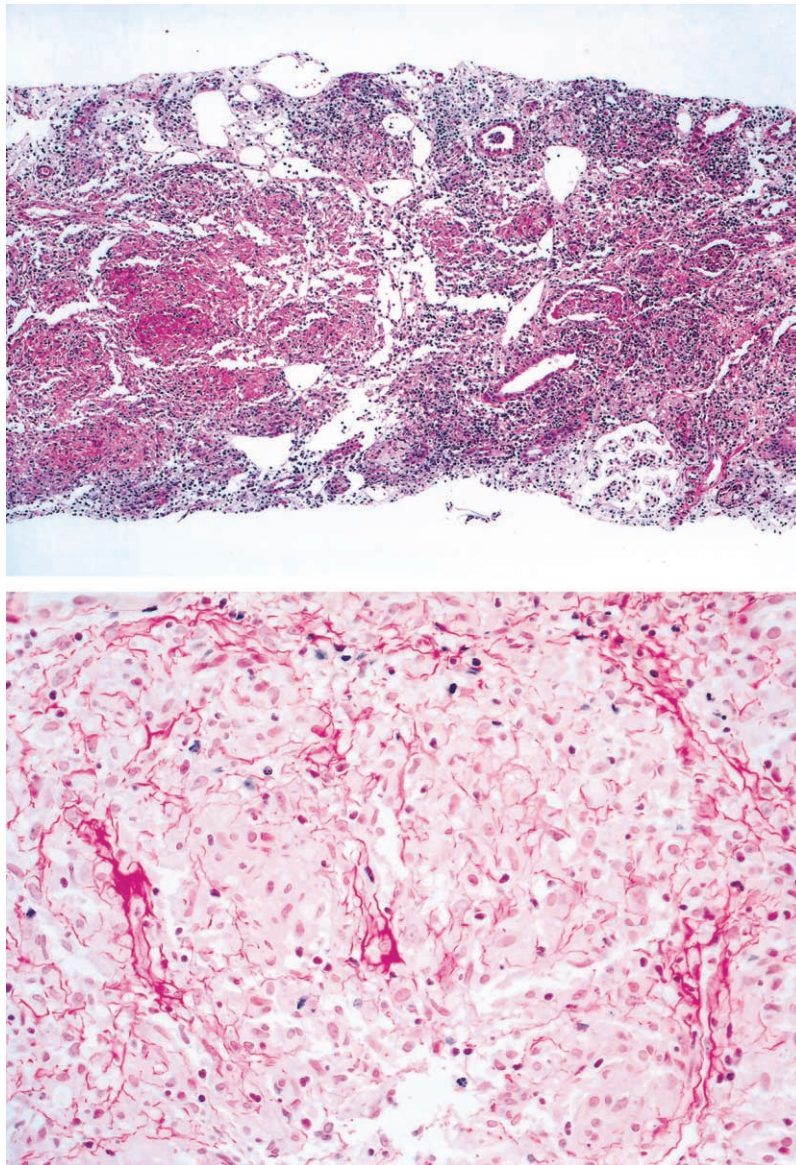
**Figure 1.** Time course of laboratory values and drug treatment in 2002 and 2003 for an HIV-infected patient with acute renal failure. Left Y-axis: Dotted line, Serum creatinine concentration,  $\mu\text{mol/L}$ ; squares, C-reactive protein levels,  $\text{mg/L}$ ; and circles, CD4 cell counts,  $\text{cells}/\mu\text{L}$ . Right Y-axis: Triangles, HIV-1 viral load,  $\log_{10}/\text{mL}$ . The treatment administered is shown on top: zidovudine (AZT), lamivudine (3TC), lopinavir/ritonavir (LPV/r), stavudine (d4T), trimethoprim-sulfamethoxazole primary prophylaxis (TMP-SMX), isoniazid (INH), rifabutin (RFB), pyrazinamide (PZA), ethambutol (ETB), prednisolone (PRE, dosage in mg) and pentacarinate (PCT).

stavudine was substituted for zidovudine because of anemia. TMP-SMX therapy was discontinued, and antituberculosis therapy was continued as a 2-drug regimen of isoniazid and rifabutin at the same dosages. C-reactive protein levels normalized and renal function improved, with serum creatinine concentrations of  $\sim 1.7 \text{ mg/dL}$  ( $145 \mu\text{mol/L}$ ) within 10 days (figure 1). Primary prophylaxis with pentacarinate was started but not tolerated, and TMP/SMX prophylaxis was reintroduced and well tolerated. The CD4 cell count increased to  $174 \text{ cells}/\mu\text{L}$  but then decreased slightly, and the HIV load remained undetectable ( $<20 \text{ copies/mL}$ ). After 1 year, the patient remained healthy while receiving HAART and TMP-SMX, and antituberculosis treatment could be discontinued.

**Discussion.** The inflammatory syndrome elicited by improving immune response to mycobacterial antigens has been described in patients with AIDS as early as 1992, at a time when only zidovudine was available for use against HIV [4]. Since the introduction of HAART, paradoxical clinical worsening is increasingly reported, most likely reflecting the more efficient immune recovery. The immune responses were directed against a range of antigens derived from infectious agents, such as cytomegalovirus, hepatitis viruses, *Histoplasma* species, polyomaviruses JC and BK, and *Cryptococcus neoformans* [5–7], but also from noninfectious antigens [8, 6]. The latter observation supports the notion that the primary pathogenic element of

immune reconstitution syndrome is a severe inflammatory response directed against antigens but not necessarily against ongoing infections. However, this distinction may be difficult to make at times. Apart from frequent manifestations in lungs [9–11], immune reconstitution syndrome directed against *M. tuberculosis* may affect the lymph nodes, CNS, liver, testicles, and gut [12–14]. In our patient, ARF occurred concurrently with radiologically documented signs of pulmonary worsening and increasing levels of C-reactive protein, and cultures remained negative for *M. tuberculosis*. The main differential diagnosis of ARF in our patient included drug toxicity caused by TMP-SMX and/or ritonavir. However, in contrast to previous reports, the ritonavir dosage was set as required for “boosting” protease inhibitor activity, and this therapy was safely continued for our patient. Similarly, TMP-SMX prophylaxis was safely reintroduced (figure 1). Ethambutol might represent a rare cause of interstitial nephritis, and this cause cannot be ruled out with certainty. However, there were no signs of neural toxicity or optic neuritis in our patient.

The initial identification of *M. tuberculosis* in the urine indicated a disseminated infection that involved the kidneys. The identification of ARF with granulomatous inflammation by renal biopsy concurrent with systemic inflammatory signs and paradoxical worsening of pulmonary infiltrates supports the diagnosis of immune reconstitution syndrome, despite only



**Figure 2.** Micrographs of a renal biopsy specimen showing granulomatous nephritis ( *top*, hematoxylin-eosin stain; original magnification 5 $\times$ ) with nonnecrotizing epithelioid granuloma and faint fibrosis (*bottom*, sirius stain; original magnification 200 $\times$ ).

modest increases in the CD4 cell count in the peripheral blood. It is remarkable that immune reconstitution syndrome has been observed in HIV-infected patients with substantially lesser increases in CD4 cell counts in the peripheral blood [5]. The pathophysiology of the immune reconstitution syndrome is still incompletely understood, but host- and antigen-specific factors may play a role, in addition to specific CD4 cell responses and, possibly, CD4 cell redistribution in tissue. However, the increasing incidence of immune reconstitution syndrome following the introduction of HAART suggests that suppression of HIV replication is a significant, but not a sufficient, factor. In our patient, a substantial decrease in HIV load (4 log<sub>10</sub>) was noted within only 6 weeks. In summary, immune reconsti-

tution syndrome should be considered as a cause of ARF after initiation of HAART in patients who have AIDS and renally disseminated antigens, as documented here for miliary tuberculosis.

## References

1. Kimmel PL, Barisoni L, Kopp JB. Pathogenesis and treatment of HIV-associated renal diseases: lessons from clinical and animal studies, molecular pathologic correlations, and genetic investigations. *Ann Intern Med* **2003**; 139:214–26.
2. Perazella MA. Acute renal failure in HIV-infected patients: a brief review of common causes. *Am J Med Sci* **2000**; 319:385–91.
3. Peraldi MN, Maslo C, Akposso K, et al. Acute renal failure in the

- course of HIV infection: a single-institution retrospective study of ninety-two patients and sixty renal biopsies. *Nephrol Dial Transplant* **1999**; 14:1578–85.
4. French MA, Mallal SA, Dawkins RL. Zidovudine-induced restoration of cell-mediated immunity to mycobacteria in immunodeficient HIV-infected patients. *AIDS* **1992**; 6:1293–7.
  5. Cheng VC, Yuen KY, Chan WM, et al. Immunorestitution disease involving the innate and adaptive response. *Clin Infect Dis* **2000**; 30: 882–92.
  6. DeSimone JA, Pomerantz RJ, Babinchak TJ. Inflammatory reactions in HIV-1-infected persons after initiation of highly active antiretroviral therapy. *Ann Intern Med* **2000**; 133:447–54.
  7. Hirsch HH, Steiger J. Polyomavirus BK. *Lancet Infect Dis* **2003**; 3: 611–23.
  8. Silvestre JE, Albares MP, Ramon R, Botella R. Cutaneous intolerance to tattoos in a patient with human immunodeficiency virus: a manifestation of the immune restoration syndrome. *Arch Dermatol* **2001**; 137:669–70.
  9. Chien JW, Johnson JL. Paradoxical reactions in HIV and pulmonary TB. *Chest* **1998**; 114:933–6.
  10. Narita M, Ashkin D, Hollender ES, Pitchenik AE. Paradoxical worsening of tuberculosis following antiretroviral therapy in patients with AIDS. *Am J Respir Crit Care Med* **1998**; 158:157–61.
  11. Fishman JE, Saraf-Lavi E, Narita M, et al. Pulmonary tuberculosis in AIDS patients: transient chest radiographic worsening after initiation of antiretroviral therapy. *AJR Am J Roentgenol* **2000**; 174:43–9.
  12. Crump JA, Tyrer MJ, Lloyd-Owen SJ, et al. Military tuberculosis with paradoxical expansion of intracranial tuberculomas complicating human immunodeficiency virus infection in a patient receiving highly active antiretroviral therapy. *Clin Infect Dis* **1998**; 26:1008–9.
  13. Guex AC, Bucher HC, Demartines N, et al. Inflammatory bowel perforation during immune restoration after one year of antiretroviral and antituberculous therapy in an HIV-1-infected patient: report of a case. *Dis Colon Rectum* **2002**; 45:977–8.
  14. Furrer H, Malinverni R. Systemic inflammatory reaction after starting highly active antiretroviral therapy in AIDS patients treated for extrapulmonary tuberculosis. *Am J Med* **1999**; 106:371–2.