

In conclusion, *S. boydii* should be considered among the rare but possible causes of vertebral osteomyelitis.

Robin Patel, Douglas R. Osmon, James M. Steckelberg, Mark B. Dekutoski, and Walter R. Wilson

Division of Infectious Disease and Internal Medicine, and Department of Orthopedics, Mayo Clinic, Rochester, Minnesota

Outer Retinal Necrosis Due to a Strain of Varicella-Zoster Virus Resistant to Acyclovir, Ganciclovir, and Sorivudine

The inhibitory activity of acyclovir is based on its phosphorylation by the viral thymidine kinase (TK). After patients with AIDS receive long-term treatment with acyclovir for the control of infections with herpes zoster and herpes simplex viruses, resistant isolates may appear. Most of the resistant strains are either deficient in TK or induce a TK with an altered substrate specificity [1, 2]. Foscarnet has a different inhibition mechanism and is the established alternative in these cases [3]. However, its toxicity and the need for intravenous administration are drawbacks. Sorivudine is one of the most active compounds against varicella-zoster virus (VZV) [4] and has favorable pharmacokinetics permitting once-daily administration. However, as its inhibitory mechanism is also based on the phosphorylation by the viral enzyme, strains with an altered TK [1, 5] may have reduced susceptibility to sorivudine as well.

Disseminated necrotic skin lesions developed in May 1994 in a 38-year-old woman with AIDS. These lesions diminished but never disappeared completely, despite the administration of high doses of oral acyclovir (5×800 mg/d). On 21 October outer retinal necrosis occurred in her right eye. Treatment with foscarnet (10 g/d) was started on 23 October. The skin lesions healed but she lost vision in her right eye, and the retina was completely detached by 26 October.

On 7 November treatment with foscarnet was interrupted because of renal failure, and treatment with sorivudine was started at reduced dosages of 40 mg every 2 days (usual dose, 40 mg/d). Skin lesions did not recur during therapy with sorivudine. However, retinal lesions appeared in her left eye on 8 December. Treatment with foscarnet was started again, combined with intravitreal administration of ganciclovir (200 μ g twice weekly). The retinal lesions responded, but her vision decreased on 24 January 1995 and progressed to blindness on 27 January. Treatment with sorivudine was discontinued on 11 January because of thrombocytopenia (nadir 10,000 platelets/ μ L), and foscarnet was withdrawn on 8 February. The patient died on 15 March.

Before treatment with foscarnet was started, VZV was isolated from CSF obtained by a lumbar puncture (21 October 1994); the virus was grown on fibroblasts. No other viruses were detected at

References

1. Twum-Danso K, Marwah S, Ahlberg A. Shigella osteomyelitis in a fit young man. *Trop Geogr Med* 1993;45:88-9.
2. Rubin HM, Eardley W, Nichols BL. *Shigella sonnei* osteomyelitis and sickle cell anemia. *Am J Dis Child* 1968;114:83-7.
3. Rothman PE. Dysentery bacillemlia. *J Pediatr* 1936;9:167-72.

Table 1. Susceptibility of the VZV isolate to various antiviral drugs.

Drug	Virus isolate	Susceptibility (inhibitory concentration of 50% [μ M])	
		Susceptible control	Cutoff
Acyclovir	215	6.3	10
Ganciclovir	24.5	3.3	5
BV-ARA-U*	4.7	0.003	<0.01
Foscarnet	211	200	250

NOTE. Human foreskin fibroblasts were seeded in 12-well plates. VZV-infected cells were seeded at a concentration that yielded 50-100 plaques per well and were incubated in the presence of antiviral drugs. After 4 days of incubation, plates were fixed and stained with Wright-Giemsa.

* [1- β -D-arabinofuranosyl-E-5[2-bromovinyl] uracil.

that time in bronchoalveolar lavage fluid, blood, saliva, throat swab specimens, or urine.

In addition, nested PCR revealed VZV DNA in anterior chamber fluid. PCR for cytomegalovirus, herpes simplex virus, and *Toxoplasma gondii* was negative. In each reaction with material from the patient, two H₂O samples were included as a negative control; a positive control was included as well. Primers from the following genomic regions were used: the membrane glycoprotein gpII region for VZV; the IE region for cytomegalovirus, the gene region of UL42 for herpes simplex virus, and the B₁ gene repeat for *T. gondii*. In addition, 10 μ L of the extracted DNA was used to amplify the TNF- α gene in a single-round PCR. The product of the inner PCR was checked for size on an agarose gel.

The VZV isolate replicated rapidly in cell culture, and the plaque reduction assay revealed resistance against acyclovir, ganciclovir, and BV-ARA-U (defined in table 1), although the patient had never been treated with BV-ARA-U before. The virus was susceptible to foscarnet.

Long-term administration of acyclovir to this patient with AIDS selected multiresistant VZV, which was also resistant to the potent VZV inhibitor sorivudine. This multiresistance was probably due to an altered or lacking TK and left only foscarnet as a treatment option, although this approach was seriously hampered by renal toxicity. This observation demonstrates the need for alternative nontoxic antiviral drugs with different mechanisms than the inhibition of TK.

Werner Wunderli, Richard Miner, Joëlle Wintsch, Sylviane von Gunten, Hans H. Hirsch, and Bernard Hirschel

Division des Maladies Infectieuses, Hôpital Cantonal Universitaire, Genève, Switzerland; Mount Zion Medical Center, San Francisco, California, USA; and Institute of Medical Microbiology, Basel, Switzerland

Reprints or correspondence: Dr. Werner Wunderli, Laboratoire Central de Virologie, Division des Maladies Infectieuses, Hôpital Cantonal Universitaire, 1211 Genève 14, Switzerland.

Clinical Infectious Diseases 1996;22:864-5
© 1996 by The University of Chicago. All rights reserved.
1058-4838/96/2205-0041\$02.00

References

1. Boivin G, Edelman CK, Pedneault L, Talarico CL, Biron KK, Balfour HH Jr. Phenotypic and genotypic characterization of acyclovir-resistant varicella-zoster viruses isolated from persons with AIDS. *J Infect Dis* 1994;170:68-75.
2. Erlich KS, Mills J, Chatis P, et al. Acyclovir-resistant herpes simplex virus infections in patients with the acquired immunodeficiency syndrome. *N Engl J Med* 1989;320:293-6.
3. Coen DM. The implications of resistance to antiviral agents for herpesvirus drug targets and drug therapy. *Antiviral Res* 1991;15:287-300.
4. Shigeta S, Yokota T, Iwabuchi T, et al. Comparative efficacy of antiherpes drugs against various strains of varicella-zoster virus. *J Infect Dis* 1983;147:476-584.
5. Talarico CL, Phelps WC, Biron KK. Analysis of the thymidine-kinase genes from acyclovir-resistant mutants of varicella-zoster virus isolated from patients with AIDS. *J Virol* 1993;67:1024-33.

Age Distribution Among Patients at High Risk for Human T-Cell Lymphotropic Virus Type I Infection

Human T-cell lymphotropic virus type I (HTLV-I) is a human retrovirus associated with adult T cell leukemia and tropical spastic paraparesis. We recently reported a high incidence of HTLV-I infection in Israeli Jews originating from the city of Mashhad in Iran [1, 2]. There is a characteristic age-dependent increase in the seroprevalence of HTLV-I infection in areas of endemicity. This increase typically occurs in adulthood and is higher in females than in males throughout their lifetimes [3, 4]. It is not fully understood whether age, immunity, and the CNS are distinctive factors or cofactors associated with morbidity in elderly populations. We designed the present study to investigate whether there is an age-dependent increase in the incidence of HTLV-I infection in a population at high risk; the results of our investigation were designed to be used as a model for CNS infectivity in the elderly.

The Jews of Mashhad were persecuted because of their religious beliefs since 1747, but they secretly continued to practice the Jewish religion and to intermarry, resulting in families that are closely related genetically. We included 321 Iranian Jews of Mashhad origin (either the subject or at least one of his or her parents was born in Mashhad) in our study. All subjects underwent physical and neurological examination, and samples of peripheral blood were obtained from each subject after informed consent was obtained. Sera were tested for antibodies to HTLV-I with use of the gelatin-particle agglutination test, and genomic DNA was amplified as previously reported [2]. Statistical analysis was performed with analysis of variance (ANOVA).

Of the 321 subjects included in the study, 203 were female and 118 were male (mean age \pm SD, 45.7 \pm 22.3 years). Fifty-eight (18%) of the 321 subjects (38 females and 20 males; mean age \pm SD, 50 \pm 17.3 years) were positive for HTLV-I antibody by serological testing and by PCR analysis. Of the 58 HTLV-I infected subjects, 36 were asymptomatic carriers, whereas 22 (14 females and 8 men; 38%) had signs of spastic paraparesis. None of the 263 subjects who were not infected had abnormalities of the pyramidal tract compatible with spastic paraparesis.

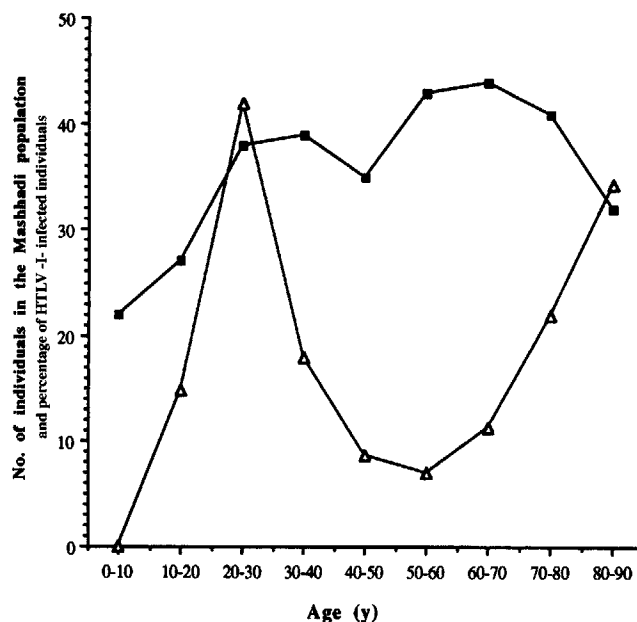


Figure 1. Age-related distribution of HTLV-I infectivity in the Mashhadi Jewish population. The number of individuals in the Mashhadi Jewish population is represented by ■. The percentage of HTLV-I infected individuals by age group is represented by ▲.

The age distribution among the various decades of the Mashhadi population being studied is presented in figure 1. The age distribution of HTLV-I-infected subjects was significantly different from that of the healthy Mashhadi population ($P < .01$); in addition, the incidence of infection was distributed in a bimodal pattern, with a peak in the incidence of infection in young adulthood (20-30 years old) and a gradual rise reaching a second peak in the incidence of infection in the very elderly (80-90 years old).

The HTLV-I infection rate (18%) in the Mashhadi population in the present study is similar to that found in our previous studies [1, 2]. The most striking finding in the present study was the high rate of infection among the elderly population (>60 years old). This finding is an extension of the reported clustering of HTLV-I infection within a nursing home for Mashhadi elderly [1]. HTLV-I is known to be transmitted by sexual intercourse [5], from mother to child in breast milk [6], via blood transfusion [7], and by sharing of needles by parenteral drug abusers [8]. These modes of transmission can account for the early peak of HTLV-I infection in the younger population. However, the increase in the incidence of HTLV-I infection in the elderly is poorly understood since trans-

Reprints or correspondence: Dr. A. Achiron, Multiple Sclerosis Center, Sheba Medical Center, Tel-Hashomer, 52621 Israel.