

Septal myectomy: cut, coil, or boil?

Mario Togni, Michael Billinger, Stephane Cook, and Otto M. Hess*

Swiss Cardiovascular Center, University Hospital Inselspital, Freiburgstrasse, CH-3010 Berne, Switzerland

This editorial refers to ‘Non-surgical septal myocardial reduction by coil embolization for hypertrophic obstructive cardiomyopathy: early and 6 months follow-up’ by E. Durand et al.,[†] on page 348

Hypertrophic cardiomyopathy (HOCM) is characterized by asymmetric septal hypertrophy with outflow tract obstruction in approximately one-third of patients. However, recent studies suggest that obstruction may be present in up to 70% of patients with enhanced sympathetic activation under exercise conditions.¹ Clinical features are dyspnoea on exertion, angina pectoris, and atrial and ventricular arrhythmias, which mainly are due to diastolic dysfunction, whereas syncope and presyncope often are due to outflow tract obstruction and represent an ominous sign of ventricular arrhythmias and sudden cardiac death.

The treatment strategy is 3-fold: (i) medical therapy for targeting diastolic dysfunction; (ii) myectomy (interventional or surgical) for relief of obstruction; and (iii) implantable defibrillators for prevention of sudden cardiac death.²

For decades, the gold standard for septal myectomy has been surgical treatment, with excellent short- and long-term results.³ In 1995, a new interventional technique (alcohol ablation of the septum) was put forward for percutaneous treatment of HOCM.⁴ In their study, Durand and co-workers⁵ propose a new technique for septal ablation of the myocardium, namely coiling of septal branches. One to five coils were deployed into the first or second septal branch of the left anterior descending artery in 20 patients with HOCM, thereby inducing septal ischaemia with myocardial necrosis and a consecutive creatine kinase (CK) rise of 386 U/L. As a result, the pressure gradient decreased significantly from 80 to 35 mmHg at the 6 months follow-up examination. Clinical symptoms and exercise capacity improved, as reflected by a significant increase in peak oxygen consumption (from 14.8 ± 4.5 to 18.5 ± 4.5 ml/kg/min) and a prolongation of exercise duration (from 7.1 ± 3.5 to 9.0 ± 3.8 min). The procedure was well tolerated, and no AV blocks were observed. However, in one patient, septal perforation occurred, which was surgically treated; however, the patient died postoperatively. Other complications were not reported, and the authors claim from this series that in contrast to alcohol ablation or surgical

myectomy, no AV blocks occur with coil embolization. Nevertheless, they suggest that larger studies, ideally employing a randomized comparison between coil embolization and alcohol septal ablation, are warranted.

The authors are to be congratulated for these results and this new technique. A major limitation of alcohol ablation is, indeed, an AV block, which occurs in 27% of all patients (transient); ~10% need pacemaker implantation (Table 1). However, previous data suggest that infarct size is larger with alcohol ablation (10–15 g) compared with 3 g with coil embolization. This finding is paralleled by a larger CK rise with alcohol ablation (1038 U/L) when compared with coil embolization (386 U/L). Alcohol appears to penetrate more deeply into the septal region and induces a larger area of necrosis, whereas coil embolization leads primarily to ischaemia and only secondarily to necrosis. However, in some rare cases, alcohol dissipation (spill over) to non-target myocardial areas (right ventricle or apex of the left ventricle) may occur.

In Durand et al.’s pilot study, a quarter of the patients had unsuccessful treatment with a resting gradient >50 mmHg at 6 months. This reflects the learning curve, as stated by the authors, or indicates the less aggressive nature of the technique. Alcohol ablation has been reported to be successful in 90–95% of all patients.

As an alternative, radiofrequency ablation has been recommended for reduction of septal hypertrophy in children with HOCM, because alcohol ablation in this patient group is strongly discouraged due to the induction of potential arrhythmias.⁶ From reviewing the literature and comparing alcohol ablation with coil embolization (Table 1), there are clear differences in the release of CK and the decrease in outflow tract gradient, suggesting a larger infarct with alcohol ablation than with coil embolization. The absence of AV block with coil embolization could be explained by the smaller infarct size and the modest decrease in pressure gradient.

Interestingly enough, a Polish group⁷ performing coil embolization in patients with HOCM reported a transient AV block in 43% of patients (Table 1). Thus, Durand’s study may represent a highly selected group that does not show AV block during coil embolization. Larger samples may answer this question.

Only a randomized trial will allow for a fair comparison of the two techniques. A contraindication for alcohol ablation (and an

The opinions expressed in this article are not necessarily those of the Editors of the *European Heart Journal* or of the European Society of Cardiology.

* Corresponding author. Tel: +41 31 632 9653, Fax: +41 31 632 4771. Email: otto.hess@insel.ch

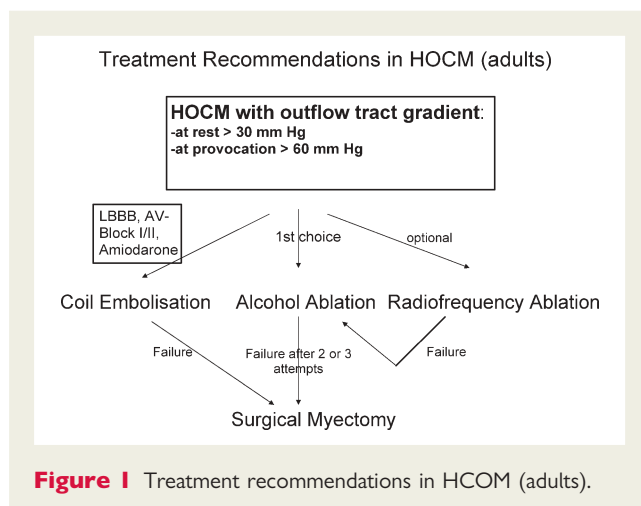
[†] doi:10.1093/eurheartj/ehm632

Published on behalf of the European Society of Cardiology. All rights reserved. © The Author 2008. For permissions please email: journals.permissions@oxfordjournals.org.

Table 1 A comparison of alcohol ablation and coil embolization

Author	Year	n	AV block		PM	Death (cardiac)	Peak CK (U/L)	LVOTG resting (mmHg)	
			Transient	Permanent				Before	After
Alcohol ablation									
Chang ⁸	2003	224	N/A	14%	–	–	1335	62	20
Osterne ⁹	2003	18	44%	11%	11%	5.5%	–	68	3.8
Chang ¹⁰	2004	173	16%	–	–	–	1387	58	19
Gietzen ¹¹	2004	146	N/A	11%	25%	2.5%	508	52	14
Talreja ¹²	2004	58	N/A	12%	12%	–	–	72	11
Faber ¹³	2005	242	N/A	10%	10%	1.2%	483	57	25
Fernandes ¹⁴	2005	130	N/A	13%	13%	1.5%	1676	74	4
Streit ¹⁵	2007	24	21%	13%	13%	0%	931	38	13
Total or mean		1015	27%	12%	14%	2%	1038	60	17
Coil embolization									
Iacob ⁷	2004	7	43%	0%	0%	0%	N/A	72	34
Durand ⁵	2007	28	0%	0%	0%	4%	386	80	35
Total or mean		35	9%	0%	0%	3%	386	78	35

N/A, not available; PM, pacemaker; CK, creatine kinase; LVOTG, left ventricular outflow tract gradient.

**Figure 1** Treatment recommendations in HOCM (adults).

indication for coil embolization) may represent pre-existing left bundle branch block (LBBB). A complete AV block may occur in these patients when alcohol ablation induces right bundle branch block (RBBB) in up to 50% of patients. Amiodarone treatment is another contraindication due to associated AV conduction prolongation. A third contraindication to alcohol ablation is the pre-existing AV block I or II (Figure 1).

In summary, coil embolization represents a new and promising method for reducing septal hypertrophy in patients with HOCM. The first results suggest a lower risk for the occurrence of AV block during septal ablation, but haemodynamic success may be limited, with less reduction in outflow tract gradient.

Conflict of interest: none declared.

References

1. Maron MS, Olivetto I, Zenovich AG, Link MS, Pandian NG, Kuvin JT, Nistri S, Cecchi F, Udelson JE, Maron BJ. Hypertrophic cardiomyopathy is predominantly a disease of left ventricular outflow tract obstruction. *Circulation* 2006;**114**:2232–2239.
2. Maron BJ, Spirito P, Shen WK, Haas TS, Formisano F, Link MS, Epstein AE, Almquist AK, Daubert JP, Lawrenz T, Boriani G, Estes NA 3rd, Favale S, Piccinino M, Winters SL, Santini M, Betocchi S, Arribas F, Sherrid MV, Buja G, Semsarian C, Bruzzi P. Implantable cardioverter–defibrillators and prevention of sudden cardiac death in hypertrophic cardiomyopathy. *JAMA* 2007;**298**:405–412.
3. Schoendube FA, Klues HG, Reith S, Flachskampf FA, Hanrath P, Messmer BJ. Long-term clinical and echocardiographic follow-up after surgical correction of hypertrophic obstructive cardiomyopathy with extended myectomy and reconstruction of the subvalvular mitral apparatus. *Circulation* 1995;**92**(Suppl):II122–127.
4. Sigwart U. Non-surgical myocardial reduction for hypertrophic obstructive cardiomyopathy. *Lancet* 1995;**346**:211–214.
5. Durand E, Mousseaux E, Coste P, Pillière R, Dubourg O, Trinquart L, Chatellier G, Hagège A, Desnos M, Lafont A. Non-surgical septal myocardial reduction by coil embolization for hypertrophic obstructive cardiomyopathy: early and 6 months follow-up. *Eur Heart J* 2008;**29**:348–355. doi:10.1093/eurheartj/ehm632.
6. Maron BJ, McKenna WJ, Danielson GK, Kappenberger LJ, Kuhn HJ, Seidman CE, Shah PM, Spencer WH 3rd, Spirito P, Ten Cate FJ, Wigle ED, Task Force on Clinical Expert Consensus Documents. American College of Cardiology; Committee for Practice Guidelines. European Society of Cardiology. American College of Cardiology/European Society of Cardiology clinical expert consensus document on hypertrophic cardiomyopathy. A report of the American College of Cardiology Foundation Task Force on Clinical Expert Consensus Documents and the European Society of

- Cardiology Committee for Practice Guidelines. *J Am Coll Cardiol* 2003;**42**:1687–1713.
7. Iacob M, Pinte F, Tintoiu I, Cotuna L, Caroescu M, Popa A, Cristian G, Goleanu V, Greere V, Moscaliuc I, Neagoie G, Crisan P, Garjeu A, Chiriac L, Bolohan R, Murgu V, Lobont B, Filip S, Roates J, Hila G, Postolea E. Microcoil embolisation for ablation of septal hypertrophy in hypertrophic obstructive cardiomyopathy. *Kardiol Pol* 2004;**61**:350–355.
 8. Chang SM, Nagueh SF, Spencer WH 3rd, Lakkis NM. Complete heart block: determinants and clinical impact in patients with hypertrophic obstructive cardiomyopathy undergoing non-surgical septal reduction therapy. *J Am Coll Cardiol* 2003;**42**: 296–300.
 9. Osterne EC, Seixas TN, Paulo Filho W, Osterne EM, Gomes OM. Percutaneous transluminal septal alcoholization for the treatment of refractory hypertrophic obstructive cardiomyopathy: initial experience in the Federal District. *Arq Bras Cardiol* 2003;**80**: 359–378.
 10. Chang SM, Lakkis NM, Franklin J, Spencer WH 3rd, Nagueh SF. Predictors of outcome after alcohol septal ablation therapy in patients with hypertrophic obstructive cardiomyopathy. *Circulation* 2004;**109**:824–827.
 11. Gietzen FH, Leuner CJ, Obergassel L, Strunk-Mueller C, Kuhn H. Transcoronary ablation of septal hypertrophy for hypertrophic obstructive cardiomyopathy: feasibility, clinical benefit, and short term results in elderly patients. *Heart* 2004;**90**: 638–644.
 12. Talreja DR, Nishimura RA, Edwards WD, Valeti US, Ommen SR, Tajik AJ, Dearani JA, Schaff HV, Holmes DR Jr. Alcohol septal ablation versus surgical septal myectomy: comparison of effects on atrio-ventricular conduction tissue. *J Am Coll Cardiol* 2004;**44**: 2329–2332.
 13. Faber L, Seggewiss H, Gietzen FH, Kuhn H, Boekstegers P, Neuhaus L, Seipel L, Horstkotte D. Catheter-based septal ablation for symptomatic hypertrophic obstructive cardiomyopathy: follow-up results of the TASH-registry of the German Cardiac Society. *Z Kardiol* 2005;**94**:516–523.
 14. Fernandes VL, Nagueh SF, Wang W, Roberts R, Spencer WH 3rd. A prospective follow-up of alcohol septal ablation for symptomatic hypertrophic obstructive cardiomyopathy—the Baylor experience (1996–2002). *Clin Cardiol* 2005;**28**:124–130.
 15. Streit S, Walpoth N, Windecker S, Meier B, Hess OM. Is alcohol ablation of the septum associated with recurrent tachyarrhythmias. *Swiss Med Wkly* 2007; in press.