

## Hypothesis

# Coxsackie B viruses and the kidney—a neglected topic

Andreas Pasch and Felix J. Frey

Department of Nephrology and Hypertension, Inselspital, University of Bern,  
Freiburgstrasse 10, CH-3010 Bern, Switzerland

### Abstract

Coxsackie B viruses types 1–6 (CVB1–6) occur worldwide and cause a broad spectrum of diseases, including myocarditis and aseptic meningitis. Although renal damage due to CVB has been suspected since the 1950s, these agents are only rarely searched for in today's clinical nephrological practice. Nevertheless, CVB can infect mesangial cells. Furthermore, infections with these viruses lead to a histological picture resembling mesangioproliferative glomerulonephritis and IgA-nephropathy in mice. In the present article, we provide an overview of this largely neglected topic, and of the slowly and steadily increasing evidence suggesting a link between coxsackieviral infections and kidney diseases.

**Keywords:** coxsackievirus; CVB; enterovirus; mesangial; renal

### Biology of coxsackieviruses

In 1948, while searching for 'parapoliomyelitis viruses', Dalldorf and Sickles [1] discovered a new virus in the stool of two children who lived in the little town of Coxsackie, New York. Later, coxsackieviruses were grouped into two categories—coxsackie A viruses (CVA, types 1–22 and 24) and coxsackie B viruses (CVB, types 1–6)—depending on their tissue tropism and the course of infection in suckling baby mice. Taxonomically, coxsackie-, polio- and echoviruses form the genus enteroviridae which belongs to the family of picornaviridae.

Coxsackieviruses are small ('pico') particles with a diameter of about 30 nm composed of a protein capsid and an RNA genome [2]. Like other enteroviruses, they are very resistant to acid and other environmental

influences. Coxsackieviruses are spread by faecal-oral transmission and enter the organism via the gastrointestinal tract. CVB replicate in enterocytes and secondarily enter the circulation to affect other organ systems. As an initial step of infection on the cellular level, the virus binds to specific receptors on the surface of eukaryotic cells. This interaction leads to the release of viral RNA into the cellular cytoplasm. Here, newly generated viral RNA-polymerases translate the viral positive strand (+) RNA into a complementary minus (–) RNA strand, which then serves as a matrix for the generation of multiple new viral (+) RNA molecules. Viral RNA and capsid proteins then assemble to form complete viruses which are released from the host cell.

Coxsackieviruses do occur worldwide. Most coxsackieviral infections manifest as a flu-like febrile disease or remain asymptomatic [2]. However, CVB in addition cause aseptic meningitis, acute and chronic myocarditis, paralytic diseases, rhabdomyolysis, pleurodynia (Bornholm's disease) and severe septic diseases in newborns.

Given the fact that the receptors for CVB and the cellular constituents for replication of CVB have been identified in renal tissue [3], it is reasonable to anticipate that CVB might, at least under certain circumstances, induce renal damage.

### Coxsackieviruses and the kidney

#### Human case reports

In 1958, 10 years after the discovery of the first coxsackievirus, Utz and Shelokov [4] reported a generalized CVB3 infection in a 40-year-old male. During the course of the disease which was characterized by biphasic fever, chills, myalgia and headache, CVB3 was repeatedly isolated from blood, cerebrospinal fluid and urine. Renal function, as assessed by the excretion of phenolsulfonphthalein, was impaired. On day 5 of the disease state, urinary samples were positive for CVB, while no virus was detected in the blood.

Correspondence and offprint requests to: Andreas Pasch, MD, Department of Nephrology and Hypertension, Inselspital, University of Bern, Freiburgstrasse 10, CH-3010 Bern, Switzerland. Email: andreas.pasch@insel.ch

During an endemic of aseptic meningitis in Japanese children, CVB5 antigen was also detected within exfoliated urinary cells by immunofluorescence staining [5].

Besides the detection of CVB in urine, the virus was identified in renal tissue exhibiting evidence for an inflammatory reaction. Burch and Colcolough [6] identified abundant CVB4 antigen in myocardial and renal tissue of a 45-year-old male who had died of pancarditis and nephritis. Interstitial inflammation and areas of focal chronic glomerulonephritis with increased cellularity of the glomerular tufts, crescent formation, and hyalinization of the glomeruli were encountered. Similarly, Benyesh-Melnick *et al.* [7] isolated CVB1 from kidney tissue of a child dying from myocarditis.

Later on, CVB4 glomerulonephritis characterized by viruria, proteinuria, haematuria, leukocyturia, high blood pressure and an elevated blood urea nitrogen in a 9-year-old boy was published by Bayatpour *et al.* [8]. Burch *et al.* found CVB4 by immunofluorescence in the kidney of a 19-year-old male who had died from acute dilated cardiomyopathy [9]. Furthermore, Aronson and Phillips [10] reported six adult patients with acute oliguric renal failure who concurrently showed a significant rise of CVB5 antibody titre levels. In a systematic autopsy study, CVB antigen was detected by immunofluorescence staining in the kidneys of 11 out of 104 unselected patients [11]. The specific viral antigen-antibody reaction displayed focal, bright intracytoplasmatic fluorescence scattered within the glomerulus, tubular epithelium and interstitial tissue.

In a study focusing viral infections in renal transplant recipients, CVB3 was isolated from two of 20 urine samples [12]. Unfortunately, no information was given about the clinical status and the kidney function of the affected patients. Furthermore, four patients with renal transplant rejection in the presence of sharply rising CVB4 antibody titres and clinical features of coxsackieviral infection and renal failure have been identified [13].

The restricted number of cases linking CVB infection with renal disease was reported before 1976. At that time, genetic identification of viruses by modern technology was not available. The analysis of the patients' histories does not allow a firm conclusion as to whether the CVB virus was directly responsible for the impaired renal function. Therefore, investigations in animals might possibly be more informative.

#### Animal studies

Sun *et al.* [14] described a consistent sequential pattern of the histologic renal lesions induced by CVB1 in mice. Two weeks after infection, glomeruli showed increased cellularity with proliferation and swelling of endothelial and mesangial cells. Later, fusion of capillary loops led to a picture similar to lobular glomerulonephritis. More advanced lesions showed sclerosing changes of the glomeruli and partial or complete hyalinization of the glomerular tuft.

Fluorescence microscopy exhibited deposition of gamma-globulin along capillaries in irregular clumping patterns. These observations corroborated publications from the 1950s and 1960s showing histological changes and excretion of CVB1 [15] and CVB5 [16] in the urine of infected mice.

Kamiyama [17] developed a more chronic model and inoculated mice with CVB4 administered once a month for 9 months. He reported mesangial cell proliferation, marked changes of the glomerular basement membrane, crescent formation, interstitial inflammation and equal amounts of IgA and IgG deposits in the glomeruli.

Yoshida *et al.* observed by *in-situ* hybridization strong CVB4-specific positive strand (+) RNA signals in mesangial cells [18]. In their model, CVB4 were inoculated monthly into mice for 5 months. Interestingly, predominant glomerular IgA depositions along with mesangial proliferation were detected for several months after infection (Figure 1), suggesting a kind of experimental IgA-nephropathy.

In order to establish whether mesangial cell function was disturbed by CVB4 infection, Kume [19] studied the clearing of colloidal carbon by mesangial cells in CVB4-infected mice and found a reduced clearance in infected when compared with non-infected animals.

The histological changes observed in mice were corroborated by findings in other species. Burch *et al.* [20] infected squirrel monkeys with CVB4, and observed a marked proliferation of mesangial and endothelial cells. The lesions were patchy in distribution. Virus could be isolated from renal tissue in two monkeys necropsied 3 and 7 days after inoculation.

Thus, contrary to human investigations, the studies in mice and monkeys definitely indicate a pathogenic potential, at least following inoculation of high amounts of CVB1 and CVB4. The lesions appear to be predominantly glomerular and reminiscent of human IgA nephropathy.

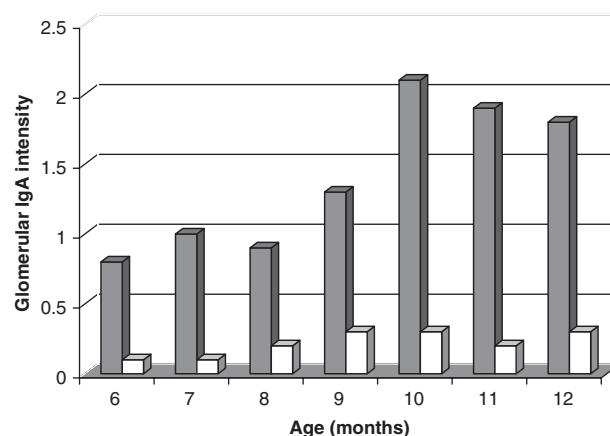


Fig. 1. Intensity of glomerular IgA by immunofluorescence in CVB4-infected mice. Bar height represents mean for infected mice (hatched) and control mice (open). Intensity was graded on a scale where negative = 0, slight = 0.5, mild = 1, moderate = 2 and marked = 3 (adapted from [18]).

### *In-vitro studies*

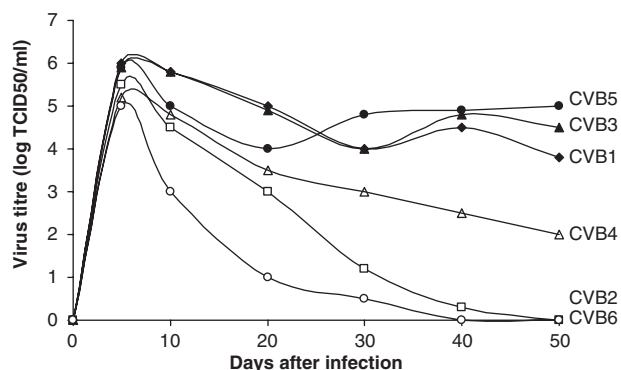
Conaldi *et al.* [3] generated primary kidney cell lines from the unaffected part of human kidneys resected because of a carcinoma. The resulting cell lines of proximal tubular epithelial cells, glomerular podocytes and glomerular mesangial cells were inoculated with reference strains of CVB1–6. Mesangial cells expressed smaller amounts of CVB receptors than proximal tubular epithelial cells. After infection, all cell lines produced viable viruses. A cytopathic effect was observed with glomerular epithelial cells and proximal tubular epithelial cells only. In contrast, mesangial cells survived and even established a state of persistent infection. This chronic carrier-state was most pronounced with CVB1, 3 and 5 which were produced in high and stable titres for at least 50 days (Figure 2). Phagocytic function of mesangial cells was tested by phagocytosis assays with IgG-coated latex beads and was dramatically reduced in infected cells. Also, contractility of mesangial cells was diminished significantly.

Based on these investigations one might predict that first, the renal lesions induced by CVB will be mixed glomerular and tubular, and second, the nephrotoxic potential depends on the strain of CVB virus causing the infection.

### Comments and outlook

From the data presented, it is likely that CVB can infect kidney cells *in vivo* and *in vitro*, and in doing so induce transient or chronic kidney diseases.

CVB leads to cytopathic effects in renal tissue. When primary cell cultures of human podocytes and proximal tubular epithelial cells are infected with CVB1–6, they show cytopathic effects and lysis of the infected cells [3]. *In vitro*, lytic infections lead to the release of high titres of CVB and to the shedding of adherent cells from the plastic material. Against this background, one is tempted to speculate that a similar



**Fig. 2.** Viral titres during infection of mesangial cells *in vitro*. CVB1, 3 and 5 induce a chronic and persistent infection in human primary mesangial cell culture. In contrast, CVB2 and 6 are cleared from the cells in 30–40 days. CVB4 produces a prolonged infection with slowly declining viral titres (adapted from [3]).

mechanism explains transient viruria and shedding of virus-bearing cells from the urinary tract during CVB infection.

The interaction between CVB and mesangial cells depends on the subtype of CVB. *In vitro*, human primary mesangial cell cultures are infectable with CVB1–6 [3]. CVB1, 3 and 5, cause a persistent and ongoing infection and a continuous production of virus. Interestingly, CVB1, 3 and 5, but not CVB2, 4 and 6, bind to decay accelerating factor (DAF/CD55) which is a glycosylphosphatidylinositol-anchored cell surface protein consisting of five extracellular short consensus repeats [21,22]. Whether differential binding to DAF/CD55 simply reflects coincidence or DAF plays a role in the induction of carrier-states of CVB-infected cells, remains to be established.

The presence of CVB in mesangial cells seems to be functionally relevant, since persistent *in vitro* infection of mesangial cells leads to impaired phagocytosis and thereby to an impaired clearing function of these cells [3]. Furthermore, cellular contractility, another important property in glomerular pathophysiology, is markedly reduced in chronically CVB-infected mesangial cells. In accordance with these findings, inoculation of CVB4 causes delayed mesangial clearance of colloidal carbon in mice [19].

When CVB4 are injected into mice, a mesangio-proliferative glomerulonephritis with histologically variable expression develops. In some studies, increased mesangial cellularity was only transiently found [17,23–25], whereas in others the effect lasted for many months [18,26]. These differences are best explained by different routes, frequencies and amounts of CVB applied, and by the different strains of viruses and mice used. Whether the experimental findings explain, at least in part, the heterogeneous clinical course of coxsackieviral infections encountered in humans awaits clarification. With respect to chronic infection of cells *in vivo*, viral antigen and viral positive strand (+) RNA have been detected by immunofluorescence and by *in-situ* hybridization in murine kidneys [3,25]. This indicates a replication of CVB in these cells.

The pathophysiologic mechanism by which kidney damage is induced in CVB infection is not known. It has been suggested that acute damage is caused by acute and lytic infection of cells. In contrast, chronic damage might be induced by chronic infection of cells followed by consecutive immune-complex-related mechanisms of glomerular injury [14,27]. The latter mechanism could explain the interesting observation of CVB4-induced IgA-nephropathy [18].

Tropism towards different tissues and organs has been a long known feature of different CVB strains. As an example, CVB3 strains inducing fulminant myocarditis in mice have been described as well as strains which do not affect the murine heart at all [28,29]. Although the reason for this phenomenon has not been elucidated in detail, in analogy to cardiotropism, different CVB strains might exhibit different degrees of nephrotropism. If this was the case, many wild type CVBs might cause simply transient or

no significant kidney damage at all. On the other hand, more nephrotropic strains might induce acute or chronic functional impairment of renal function. In this context, immunosuppression or previous kidney damage could be the factors rendering the kidney more vulnerable towards infections with coxsackieviruses. In accordance with this possibility, CVB-induced transplantation kidney failure has been described [13].

The causes of most of the glomerular and interstitial types of nephritis remain unknown. Given the human case reports, the acute and chronic experimental inflammatory kidney diseases induced by CVB and the observations in cell cultures derived from kidney cells, it is reasonable to assume that CVB are clinically relevant for renal disease and should be investigated accordingly in the future.

*Acknowledgements.* Erika Baer-Spycher Stiftung. SNF No. 3100-61505.

*Conflict of interest statement.* None declared.

## References

- Dalldorf G, Sickles GM. An unidentified, filterable agent isolated from the feces of children with paralysis. *Science* 1948; 108: 61-63
- Rueckert R. Picornaviridae: the viruses and their replication, In: Fields B, Knipe DM, eds. *Virology*, Raven Press, New York, 1996; 609-654
- Conaldi PG, Biancone L, Bottelli A, De Martino A, Camussi G, Toniolo A. Distinct pathogenic effects of group B coxsackieviruses on human glomerular and tubular kidney cells. *J Virol* 1997; 71: 9180-9187
- Utz JP, Shelokov AI. Coxsackie B virus infection; presence of virus in blood, urine, and cerebrospinal fluid. *J Am Med Assoc* 1958; 168: 264-267
- Hinuma Y, Miyamoto T, Murai Y, Ishida N. Detection of Coxsackie virus antigen in urinary cells by immunofluorescence. *Lancet* 1962; 2: 179-180
- Burch GE, Colcolough HL. Progressive Coxsackie viral pancarditis and nephritis. *Ann Intern Med* 1969; 71: 963-970
- Benyesh-Melnick M, Rosenberg HS, Watson B. Viruses in cell cultures of kidneys of children with congenital heart malformations and other diseases. *Proc Soc Exp Biol Med* 1964; 117: 452-459
- Bayatpour M, Zbitnew A, Dempster G, Miller KR. Role of coxsackievirus B4 in the pathogenesis of acute glomerulonephritis. *Can Med Assoc J* 1973; 109: 873 passim
- Burch G, Harb J, Hiramoto Y. Coxsackie B4 viral infection of the human kidney. *J Urol* 1974; 112: 714-722
- Aronson MD, Phillips CA. Coxsackievirus B5 infections in acute oliguric renal failure. *J Infect Dis* 1975; 132: 303-306
- Burch GE, Chu KC, Colcolough HL, Sohal RS. Immunofluorescent localization of coxsackievirus B antigen in the kidney observed at routine autopsy. *Am J Med* 1969; 47: 36-42
- Krech U, Jung M, Price PC, Thiel G, Sege D, Reutter F. Virus infections in renal transplant recipients. *Z Immunitätsforsch Exp Klin Immunol* 1975; 148: 341-355
- Page Y, Serrange C, Revillard JP, Traeger J, Denoyel J. Letter: Coxsackie B virus infections in kidney transplantation. *Nouv Presse Med* 1976; 5: 1587-1588
- Sun SC, Lai CH, Chen ST, Schaeffer BT. Evolution of chronic glomerulonephritis induced in mice by ECHO-9 and Coxsackie B 1 viruses. *J Pathol* 1971; 104: 53-57
- Jensen MM. Experimental viral infections of the urinary tract of mice. *J Infect Dis* 1965; 115: 370
- Pappenheimer AM, Kunz LJ, Richardson S. Excretion of coxsackie virus (Conn. No. 5 strain) in the urine of infected mice. *Proc Soc Exp Biol Med* 1951; 77: 405-407
- Kamiyama S. Experimental glomerulonephritis induced by Coxsackie B4 virus in mice-glomerular changes associated with intermittent viral inoculations. *Nippon Jinzo Gakkai Shi* 1990; 32: 939-948
- Yoshida K, Suzuki J, Suzuki S *et al.* Experimental IgA nephropathy induced by coxsackie B4 virus in mice. *Am J Nephrol* 1997; 17: 81-88
- Kume K. Influence of Coxsackie B4 virus on uptake and transport of colloidal carbon by glomerular mesangium. *Nippon Jinzo Gakkai Shi* 1990; 32: 777-789
- Burch GE, Chu KC, Soike KF. Coxsackievirus B4 nephritis in the squirrel monkey. *Br J Exp Pathol* 1982; 63: 680-685
- Shafren DR, Bates RC, Agrez MV, Herd RL, Burns GF, Barry RD. Coxsackieviruses B1, B3, and B5 use decay accelerating factor as a receptor for cell attachment. *J Virol* 1995; 69: 3873-3877
- Pasch A, Kupper JH, Wolde A, Kandolf R, Selinka HC. Comparative analysis of virus-host cell interactions of haemagglutinating and non-haemagglutinating strains of coxsackievirus B3. *J Gen Virol* 1999; 80 (Pt 12): 3153-3158
- Kato K. Experimental nephritis induced by Cox. B4 virus in mice (author's transl). *Nippon Jinzo Gakkai Shi* 1980; 22: 233-247
- Oohara N. Experimental nephritis induced by Coxsackie B4 virus in mice-transient mesangial proliferation associated with acute viremia. *Nippon Jinzo Gakkai Shi* 1986; 28: 351-364
- Mutoh S, Kumada K, Kume K, Suzuki J, Yokota T, Suzuki H. Detection of coxsackie B4 virus RNA in infected mouse kidneys by *in situ* hybridization. *Nephron* 1994; 67: 340-345
- Isome M, Yoshida K, Suzuki S *et al.* Experimental glomerulonephritis following successive inoculation of five different serotypes of group B coxsackieviruses in mice. *Nephron* 1997; 77: 93-99
- Sun S, Burch GE, Sohal RS, Chu KC. Coxsackie B4 viral nephritis in mice and its autoimmune-like phenomena. *Proc Soc Exp Biol Med* 1967; 126: 882-885
- Selinka HC, Wolde A, Pasch A *et al.* Comparative analysis of two coxsackievirus B3 strains: putative influence of virus-receptor interactions on pathogenesis. *J Med Virol* 2002; 67: 224-233
- Selinka HC, Wolde A, Sauter M, Kandolf R, Klingel K. Virus-receptor interactions of coxsackie B viruses and their putative influence on cardiotropism. *Med Microbiol Immunol (Berl)* 2004; 193: 127-131

*Received for publication: 31.10.05*

*Accepted in revised form: 12.1.06*