

Intermediate hepatocellular carcinoma: current treatments and future perspectives

J.-F. Dufour^{1,2*}, I. Bargellini³, N. De Maria⁴, P. De Simone⁴, I. Goulis⁵ & R. T. Marinho⁶

¹Hepatology, Department of Clinical Research, University of Berne, Berne; ²University Clinic for Visceral Surgery and Medicine, Inselspital, University of Berne, Berne, Switzerland; ³Department of Diagnostic and Interventional Radiology, University of Pisa, Pisa; ⁴Gastroenterology, Department of Internal Medicine, University Hospital of Modena, Modena, Italy; ⁵4th Department of Internal Medicine, Aristotelian University of Thessaloniki, Greece; ⁶Liver Unit, Department of Gastroenterology and Hepatology, Hospital de Santa Maria, Medical School of Lisbon, Lisboa, Portugal

Current guidelines recommend transarterial chemoembolization (TACE) as the standard treatment of Barcelona-Clinic Liver Cancer (BCLC)-B patients. However, the long-term survival outcomes of patients managed with this technique do not appear fully satisfactory; in addition, intermediate-stage hepatocellular carcinoma (HCC) includes a heterogeneous population of patients with varying tumour burdens, liver function and disease aetiology. Therefore, not all patients with intermediate-stage HCC may derive similar benefit from TACE, and some patients may benefit from other treatment options, which are currently approved or being explored. These include different TACE modalities, such as selective TACE or drug-eluting beads TACE and radioembolization. The introduction of sorafenib in the therapeutic armamentarium for HCC has provided a new therapeutic option for the treatment of BCLC-B patients who are unsuitable to TACE or in whom TACE resulted in unacceptable toxicity. In addition, clinical trials aimed at investigating the potential role of this molecule in the treatment of patients with intermediate-stage HCC within combination therapeutic regimens are ongoing. This narrative review will present and discuss the most recent evidence on the locoregional or medical treatment with sorafenib in patients with intermediate-stage HCC.

Key words: adverse events, chemoembolization, locoregional, SIRT, sorafenib, systemic targeted therapy, TACE

introduction

The recent guidelines issued by the European Association for the Study of Liver (EASL) endorse the Barcelona-Clinic Liver Cancer (BCLC) classification for the staging of hepatocellular carcinoma (HCC) [1,2]. This classification divides HCC patients into five stages (0, A, B, C and D) according to different prognostic variables and allocates therapies according to treatment-related status [1].

About 20% of HCC patients are classified as affected by BCLC-B, or intermediate-stage HCC, and present a 2-year survival of ~50% [1]. The management of these patients, like that of other HCC subjects, should be based on the multidisciplinary interaction among different specialists [1].

Current guidelines recommend transarterial chemoembolization (TACE) as the standard treatment of BCLC-B patients [1,3,4]. However, despite several recent advances and technical refinements, the long-term survival outcomes of patients managed with this technique do not appear fully satisfactory [3]; in addition, intermediate-stage HCC includes a heterogeneous population of patients with varying tumour burdens, liver function and disease aetiology [3–5]. As reported by Piscaglia and Bolondi [5], both a patient

with still well-preserved liver function (Child-Pugh A5 due to albumin 4.8 g/dl, total bilirubin 0.9 mg/dl, INR 0.99) and only two nodules <3 cm and a patient with persistent ascites and jaundice (Child-Pugh B) with multifocal large tumours will be classified as affected by intermediate-stage HCC.

Therefore, not all patients with intermediate-stage HCC will derive similar benefit from TACE, and some patients may benefit from other treatment options, which are currently approved or being explored (Figure 1) [3–6]. These include different TACE modalities, such as selective TACE or drug-eluting beads (DB)-TACE, and radioembolization or combination approaches [3–6]. For instance, the combination of TACE and radiofrequency ablation gave promising results in a recent study [6].

The introduction of sorafenib in the therapeutic armamentarium for HCC has provided a new therapeutic option for the treatment of BCLC-B patients who are unsuitable to TACE or in whom TACE resulted in unacceptable toxicity. In addition, clinical trials aimed at investigating the potential role of this molecule in the treatment of patients with intermediate-stage HCC within combination therapeutic regimens are ongoing.

This review will present and discuss the most recent evidence on the locoregional or medical treatment with sorafenib in patients with intermediate-stage HCC. Surgical procedures, including resection or transplantation, can be considered in selected patients, as reviewed in Zhang *et al.* [7].

*Correspondence to: Prof. Jean-Francois Dufour, Hepatology, Department of Clinical Research, University of Berne, Murtenstrasse 35, 3010 Bern, Switzerland; Tel: +41-31-632-31-91; Fax: +41-31-632-49-97; E-mail: jf.dufour@ikp.unibe.ch

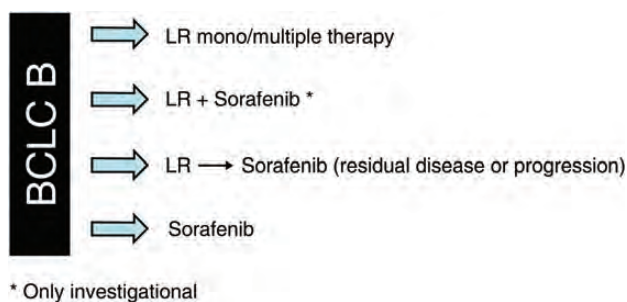


Figure 1. Locoregional (LR) or medical treatment of patients with intermediate-stage HCC, either approved or under investigation. Asterisk denotes only investigational.

Resection may be a valid option in selected patients [7]. More in detail, radical resection can be considered in: (i) patients with single HCC and large tumour nodule, swelling outward, clear border or pseudocapsule and <30% hepatic tissue destroyed or >50% compensatory hepatic hypertrophy and (ii) patients with multiple HCC with ≤ 3 nodules localized in one lobe or segment of the liver [7]. Other patients may be eligible for palliative resection (see Zhang *et al.* [7] for a deeper discussion on indication for palliative resection). Due to the shortage of available organs, it is currently recommended that only those HCC patients with an estimated high probability of post-transplant survival benefit may be selected for liver transplantation. The Milan criteria (1 lesion ≤ 5 cm or 2–3 lesions ≤ 3 cm), proposed in 1996, still represent the basis for the selection of the best candidates for liver transplant [7–10]. However, the adoption of expanded and/or down-staging criteria for liver transplant has been proposed and is currently under clinical investigation [7–10]. For instance, a study by Mazzaferro—the leading investigator of the team who identified the same Milan criteria—conducted on 1556 patients has suggested that more HCC patients could be eligible for transplantation if the Milan criteria were replaced by a more precise estimation of survival based on individual tumour characteristics and up-to-seven criteria [8].

These findings are confirmed by a study on more than 6000 patients included in the US Scientific Registry of Transplant Recipients database: this analysis shows that the Milan criteria are too restrictive, and patients with larger total tumour volume can enjoy satisfactory post-transplant survivals [11]. Moreover, a composite patient selection score combining total tumour volume and alpha fetoprotein can be considered the most effective of all tested staging criteria for the prediction of the survival of transplanted patients [11].

Locoregional options for the intermediate patient

The most widely used locoregional therapies for the treatment of intermediate-stage HCC are TACE, selective TACE, DB-TACE and radioembolization [3,4,7,12–14]. These interventions are image-guided and therefore a careful imaging, also before and after treatment, represents an essential prerequisite for their success [12,13]. A detailed description of

the imaging modalities for locoregional treatments is beyond the scopes of this review.

transarterial chemoembolization

TACE is considered as the standard treatment of patients with compensated liver function (Child B up to 8 points), with large single nodule or multifocal HCC (<5 cm) not occluding the portal venous vessels and without extrahepatic spread [3,14,15]. Survival benefits determined by TACE were reported in two randomized, controlled trials (RCTs): Llovet *et al.* [16] showed a significant survival advantage in favour of TACE over transarterial embolization [hazard ratio (HR) for death: 0.47; 95% confidence interval (CI), 0.25–0.91; $P = 0.025$], and Lo *et al.* [17] showed a 50% reduction in the relative risk of death with TACE versus symptomatic treatment (95% CI, 0.31–0.81; $P = 0.005$). In addition, the efficacy of TACE has been evaluated in other RCTs, and two of these did not show a prolonged survival time with respect to controls [18,19]. Despite this, the results of a meta-analysis published in 2003 indicated that treatment with transarterial embolization/TACE is associated with a significantly higher 2-year survival rate than in the control group (odds ratio, 0.53; 95% CI, 0.32–0.89; $P = 0.017$) [20]. These findings are in agreement with those reported in another meta-analysis of 18 RCTs, which shows that TACE improves the overall survival (OS) at 2 years compared with non-active treatment; however, the magnitude of this benefit is relatively small [21].

TACE-associated adverse events (AEs), although usually transient and manageable, occur in a significant proportion (35–100%) of patients: they include post-embolization syndrome (comprising fever, abdominal pain and a moderate degree of ileus), relevant liver function deterioration, ascites and gastrointestinal bleeding [22]. In addition, TACE does have some contra-indications, both absolute and relative (Table 1) [22].

Collectively, these findings indicated that treatment with TACE may be associated with some benefits in terms of OS, although the level of benefit varies and considerable AEs may occur: therefore, a careful selection of patients appears crucial before the initiation of TACE therapy [3].

In the future, additional trials should be conducted to investigate some ‘grey areas’ still present in the current knowledge of TACE, such as the use and type of the chemotherapeutic agent, as well as the best type of embolizing medium [3]. Of note, recent evidence supports the use of the EASL criteria or the mRECIST criteria, rather than the standard RECIST criteria, in the evaluation of clinical response after TACE [23]. Gilmore *et al.* reported a significant association between survival and overall EASL and mRECIST responses: response was associated with a 44% risk reduction and mRECIST with a 42% reduction. Conversely, there was no significant association between survival and RECIST 1.1 responses [23]. These data are corroborated by those reported by Shim *et al.* [24], who show that the HRs for time to progression (TTP) and OS in responders were 0.15 (95% CI: 0.10–0.21) and 0.18 (95% CI: 0.13–0.26), respectively, when the mRECIST definition of an objective response was used and 0.16 (95% CI: 0.11–0.22) and 0.23 (95% CI: 0.16–0.33),

Table 1. Absolute and relative contraindications for TACE (reproduced from Raoul *et al.* [22], with permission)

Absolute contraindications	
•	Decompensated cirrhosis (Child-Pugh B ≥8) including: <ul style="list-style-type: none"> – Jaundice – Clinical encephalopathy – Refractory ascites – Hepatorenal syndrome
•	Extensive tumour with massive replacement of both entire lobes
•	Severely reduced portal vein flow (e.g. non-tumoural portal vein occlusion or hepatofugal blood flow)
•	Technical contraindications to hepatic intra-arterial treatment, e.g. untreatable arteriovenous fistula
•	Renal insufficiency (creatinine ≥2 mg/dl or creatinine clearance <30 ml/min)
Relative contraindications	
•	Tumour size ≥10 cm
•	Co-morbidities involving compromised organ function: <ul style="list-style-type: none"> – Active cardiovascular disease – Active lung disease
•	Untreated varices at high risk of bleeding
•	Bile-duct occlusion or incompetent papilla due to stent or surgery

respectively, with the EASL response criteria. In a recent paper, Kim *et al.* reached the same conclusions, further supporting the significant association between TACE response and OS [25].

Selectivity in positioning the catheter may enhance the efficacy of TACE. Selective TACE indeed comprises the injection of chemotherapeutic agents into the segmental or subsegmental branches feeding the tumours [26]. Golfieri *et al.* [26] compared the effectiveness of selective/superselective TACE versus standard TACE in determining tumour necrosis, in a prospective database of 67 consecutive patients (122 nodules, all <5 cm). The mean histological necrosis level was 64.7%; complete tumour necrosis was obtained in 42.6% of the nodules. When compared with the standard TACE, selective/superselective TACE was associated with higher mean levels of necrosis (75.1 versus 52.8%; $P = 0.002$) and a higher rate of complete necrosis (53.8 versus 29.8%, $P = 0.013$). A direct relationship was reported between the tumour diameter and the mean tumour necrosis level (59.6% for lesions <2 cm, 68.4% for lesions 2.1–3 cm and 76.2% for lesions >3 cm). These findings suggest that selective/superselective TACE may determine a higher rate of tumour necrosis than the standard TACE; however, very small nodules (<2 cm) may not respond as 3–4 cm nodules [26].

drug-eluting beads TACE

DB-TACE uses doxorubicin-loaded beads rather than the conventional doxorubicin Lipiodol® (Guerbet, Genoa, Italy) emulsion [3]. It has been suggested that this approach could result in an overall favourable toxicity profile and antitumor activity (response rates ranging from 13.3 to 80.7%) [3].

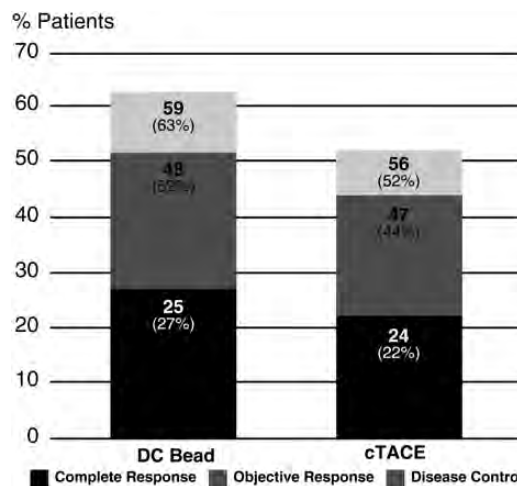


Figure 2. Complete response, objective response and disease control rate [cumulative number (%) of patients] at 6 months in the PRECISION V trial (reproduced from Lammer *et al.* [27], with permission).

The randomized, controlled PRECISION V trial has compared DB-TACE with the standard TACE for the treatment of 212 cirrhotic patients with HCC [27]. At 6 months, the DB-TACE group showed higher rates of complete response, objective response and disease control compared with the cTACE group (Figure 2) [27]. Although the predefined hypothesis of superiority was not met in the overall population, patients with Child-Pugh B, Eastern Cooperative Oncology Group 1, bilobar disease and recurrent disease presented a significant increase in objective response ($P = 0.038$). In addition, DB-TACE was associated with a reduction in serious liver toxicity and a lower rate of doxorubicin-related side-effects when compared with the standard TACE.

These findings are overall in line with those reported in another RCT by Malagari *et al.* [28], which compared DB-TACE with doxorubicin ($n = 41$) and bland embolization ($n = 43$). At 6 months, a complete response, assessed with the EASL criteria, was seen in 11 patients (26.8%) in the DB-TACE group versus 6 patients (14%) in the bland embolization group, whereas a partial response was achieved in 19 patients (46.3%) and 18 (41.9%) patients, respectively. An advantage for DB-TACE has been also reported in terms of rate of recurrences and TTP (42.4 ± 9.5 versus 36.2 ± 9.0 weeks; $P = 0.008$).

The overall favourable efficacy of DB-TACE is further corroborated by a recent international, long-term (5 years of follow-up) study [29]. In total, 173 HCC patients not suitable for curative treatments were enrolled; 41% were classified as Child-Pugh B. The OS at 5 years was 22.5%, with higher rates achieved in Child-Pugh class A compared with Child-Pugh class B patients (29.4 versus 12.8%). The mean OS was 43.8 months. Multivariate analysis identified some significant and independent determinants of 5-year survival: these were the number of lesions, lesion vascularity, initially achieved complete response and objective response.

In a recent observational study by Burrel *et al.* [30] ($n = 104$; 63 patients were BCLC-B), DB-TACE was associated with the median survival of 48.6 months, and only 10 patients reported major complications associated with this intervention. This study confirmed the safety of DB-TACE in patients with HCC

and defined the survival gain that can be obtained, providing key evidence to decide among controversial indications and TACE [30]. However, these data might not be directly extended to clinical practice, since they were collected in a single, highly specialized centre. In addition, included patients had to meet very stringent selection criteria (preserved liver function, absence of symptoms, extrahepatic spread or vascular invasion).

radioembolization

Radioembolization is an investigational technique which has given some promising results in preliminary experiences [31–33]. It is defined as the infusion of radioactive substances (such as Iodine-131-labelled lipiodol or microspheres containing Yttrium-90) into the hepatic artery [1]. Given the hypervascularity of HCC, microspheres will be preferentially delivered to the tumour area and selectively emit high-energy, low-penetration radiation to the tumour [1]. Salem *et al.* [31] have reported the results of a feasibility study which included 291 patients with HCC, who received a total of 526 treatments with radioembolization. The response rate according to the EASL criteria was 57%; the overall TTP was 7.9 months. Survival times were longer in patients with Child-Pugh A (17.2 months) than in those with Child-Pugh B disease (7.7 months; $P = 0.002$). Reported toxic effects included fatigue (57%), pain (23%) and nausea/vomiting (20%); 19% exhibited grade 3/4 bilirubin toxicity. The 30-day mortality rate was 3%.

However, the relevant costs associated with radioembolization may limit a wide use of this technique [12]. Moreover, the recent EASL Guidelines stressed that, due to the lack of RCTs comparing radioembolization with chemoembolization or sorafenib in patients with intermediate- or advanced-stage HCC, further research is needed to establish a competitive efficacy role in these populations [1].

sorafenib in the treatment of the intermediate patient

Sorafenib is currently the only drug approved for the treatment of patients with advanced HCC (BCLC-C stage); however, the use of this molecule in the treatment of intermediate patients is approved in patients with BCLC-B HCC who are unsuitable to TACE or in whom TACE resulted in unacceptable toxicity [1,22,34–36]. According to available evidence, sorafenib has a role in patients who fail or are not eligible to TACE, as recently suggested by a Panel of Experts [22]. We propose here a slightly modified version of the same algorithm (Figure 3).

Bruix *et al.* [37] carried out a subanalysis of the landmark SHARP study to compare the efficacy and safety of sorafenib alone in patients with BCLC-B (sorafenib, $n = 54$; placebo, $n = 51$) versus BCLC-C (sorafenib, $n = 245$; placebo, $n = 252$) stage of HCC. Overall, the benefit determined by sorafenib, expressed in terms of OS and TTP, was similar in BCLC-B (median OS: 14.5 months, +39% versus placebo; median TTP: 6.9 months, +113% versus placebo, $P = 0.0016$) and BCLC-C (median OS: 9.7 months, +43% versus placebo, $P = 0.018$; median TTP: 4.9 months, +69% versus placebo, $P = 0.00003$) subgroups and was consistent with that reported in the overall population [37]. The incidence of grade 3/4 drug-related AEs was not different in the two subgroups and was similar to that reported for the overall SHARP study population. The authors concluded that these findings confirm a retained efficacy of sorafenib even in the intermediate-stage HCC [37].

In an observational setting, a subanalysis of the global phase IV GIDEON study documented an OS of 12.6 months for BCLC-B patients, as assessed in a cohort of 311 Child-Pugh A and B patients [38]. In the smaller Italian SOFIA study, the OS of the 74 BCLC-B patients treated with sorafenib was longer than that reported in the 222 BCLC-C patients evaluated (20.6 versus 8.4 months; $P < 0.0001$) [39]. Taken together, these

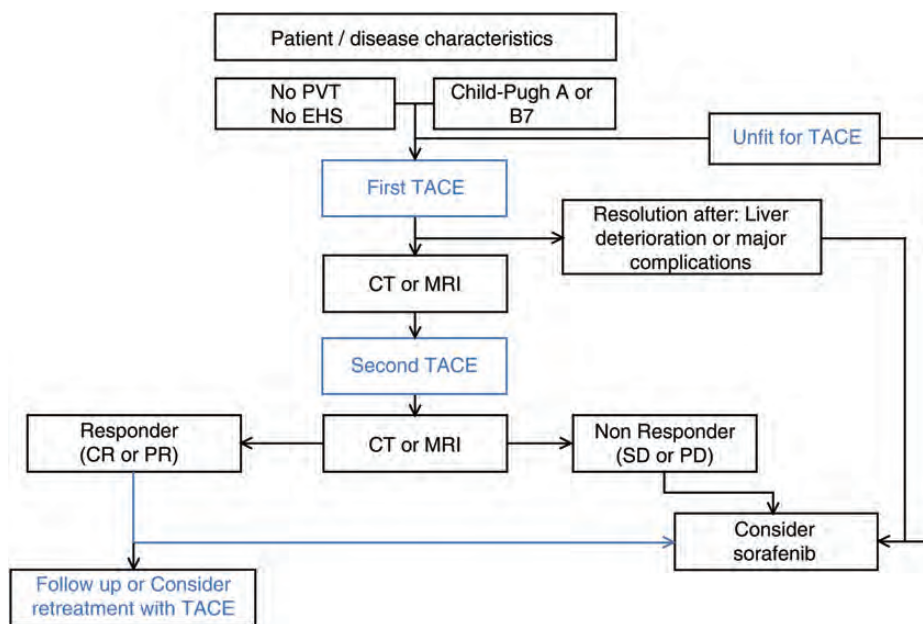


Figure 3. Proposed algorithm for the treatment of patients with intermediate-stage HCC. Response is defined according to mRECIST criteria.

preliminary results lend some support to the potential use of sorafenib monotherapy in patients with BCLC-B stage of HCC.

It is widely accepted that TACE promotes the synthesis of proangiogenic factors via a hypoxia-driven mechanism [35,40]. Therefore, there may be a rationale for the combination of sorafenib with TACE, since sorafenib inhibits the action of proangiogenic factors promoted by TACE [35,40,41]. Preliminary evidence, collected in a phase I trial, shows that the combination of sorafenib and TACE is not associated with major AEs and, therefore, could deserve further investigations [42]. Moreover, given the overall more favourable efficacy/safety profile of DB-TACE compared with the standard TACE, the combination of sorafenib with DB-TACE appears promising. Clinical trials investigating this therapeutic approach (namely the START, SOCRATES and TACTIS) are ongoing and will likely provide new evidence on the efficacy and safety of a combination of TACE and sorafenib in the treatment of intermediate-stage HCC patients. The results of the global phase II SPACE trial have been recently published in an abstract form [43]. In total, 307 patients with BCLC-B stage of HCC were randomized to sorafenib ($n = 154$) or placebo ($n = 153$) in combination with TACE with doxorubicin-eluting beads (DEBDOX). Even if this study met its primary end point from a statistical point of view ($P = 0.072$ for TTP), the actual improvement of the median TTP was not clinically relevant (from 166 to 169 days). The results of other ongoing studies appear eagerly awaited.

conclusions

Patients with intermediate-stage HCC represent a heterogeneous population, characterized by varying tumour burdens, liver function and disease aetiology. Therefore, a 'one size fits all' approach may not be entirely feasible in these subjects. We believe, in line with current guidelines, that a multidisciplinary management by specialists with different expertise may represent the optimal approach for the diagnosis and treatment of patients classified as affected from intermediate-stage HCC.

TACE represents the standard treatment approach in this population. This therapy is associated with some OS benefits, although the level of benefit reported varies—according to patient's and tumour characteristics as well as the methodology used. In addition, TACE is not suitable for all patients and can be associated with the onset of some AEs, although transitory. Variants of TACE or other locoregional treatments have been tested, and DB-TACE in particular showed promising results, but further evidence is necessary to fully support these approaches. In addition, a very recent paper has documented the potential benefits of a 'repeated-TACE' approach [44], and research aimed at investigating the factors who can predict a failure of response with this treatment is active [45].

In our opinion, the potential role of radioembolization, or a combination of locoregional approaches (see for instance, the combination of activated liposomal encapsulation of doxorubicin in combination with radiofrequency ablation, currently being explored in the HEAT trial NCT00617981), for the intermediate patients definitely deserves further investigations and should be considered from a

multidisciplinary perspective. Lastly, sorafenib, the only systemic treatment currently approved for the treatment of HCC, has a role in the treatment of patients with BCLC-B stage of HCC who are unsuitable to TACE or in whom TACE resulted in unacceptable toxicity.

Another intriguing arena is represented by the combination or the sequential use of locoregional approaches and sorafenib. Moreover, preliminary evidence suggests that sorafenib may be used in patients who fail or are not eligible to TACE, in a sequential manner. The potential combination of TACE (either standard TACE or DB-TACE) and systemic targeted therapy also represents a promising treatment strategy, currently being explored in different phase III trials.

funding

Editorial assistance was provided by Luca Giacomelli, PhD, on behalf of *inScience* Communication, Springer Healthcare; this assistance was funded by Bayer Italy.

disclosure

JFD participated in advisory boards for BMS, Bayer, Gilead, Novartis, Roche. IG participated in advisory boards for BMS, Gilead, Novartis, Roche, MSD. Other authors declare no conflict of interest directly relevant to this study.

references

1. European Association for the Study of the Liver, European Organisation for Research and Treatment of Cancer. EASL-EORTC Clinical Practice Guidelines: management of hepatocellular carcinoma. *J Hepatol* 2012; 56(4): 908–943.
2. Llovet JM, Brú C, Bruix J. Prognosis of hepatocellular carcinoma: the BCLC staging classification. *Semin Liver Dis* 1999; 19: 329–338.
3. Lencioni R. Loco-regional treatment of hepatocellular carcinoma. *Hepatology* 2010; 52(2): 762–773.
4. Lencioni R, Chen XP, Dagher L et al. Treatment of intermediate/advanced hepatocellular carcinoma in the clinic: how can outcomes be improved? *Oncologist* 2010; 15(Suppl 4): 42–52.
5. Piscaglia F, Bolondi L. The intermediate hepatocellular carcinoma stage: should treatment be expanded? *Dig Liver Dis* 2010; 42(Suppl 3): S258–S263.
6. Kim JH, Won HJ, Shin YM et al. Medium-sized (3.1–5.0 cm) hepatocellular carcinoma: transarterial chemoembolization plus radiofrequency ablation versus radiofrequency ablation alone. *Ann Surg Oncol* 2011; 18(6): 1624–1629.
7. Zhang ZM, Guo JX, Zhang ZC et al. Therapeutic options for intermediate-advanced hepatocellular carcinoma. *World J Gastroenterol* 2011; 17(13): 1685–1689.
8. Mazzaferro V, Llovet JM, Miceli R et al. Metroticket Investigator Study Group. Predicting survival after liver transplantation in patients with hepatocellular carcinoma beyond the Milan criteria: a retrospective, exploratory analysis. *Lancet Oncol* 2009; 10(1): 35–43.
9. Ravioli M, Grazi GL, Piscaglia F et al. Liver transplantation for hepatocellular carcinoma: results of down-staging in patients initially outside the Milan selection criteria. *Am J Transplant* 2008; 8(12): 2547–2557.
10. Yao FY, Kerlan RK, Jr, Hirose R et al. Excellent outcome following down-staging of hepatocellular carcinoma prior to liver transplantation: an intention-to-treat analysis. *Hepatology* 2008; 48(3): 819–827.
11. Toso C, Asthana S, Bigam DL et al. Reassessing selection criteria prior to liver transplantation for hepatocellular carcinoma utilizing the Scientific Registry of Transplant Recipients database. *Hepatology* 2009; 49(3): 832–838.
12. Meza-Junco J, Montano-Loza AJ, Liu DM et al. Locoregional radiological treatment for hepatocellular carcinoma; which, when and how? *Cancer Treat Rev* 2012; 38(1): 54–62.

13. Gervais DA, Kalva S, Thabet A. Percutaneous image-guided therapy of intra-abdominal malignancy: imaging evaluation of treatment response. *Abdom Imaging* 2009; 34(5): 593–609.
14. Davis CR. Interventional radiological treatment of hepatocellular carcinoma. *Cancer Control* 2010; 17(2): 87–99.
15. O'Neil BH, Venook AP. Hepatocellular carcinoma: the role of the North American GI Steering Committee Hepatobiliary Task Force and the advent of effective drug therapy. *Oncologist* 2007; 12: 1425–1432.
16. Llovet JM, Real MI, Montaña X et al. Arterial embolisation or chemoembolisation versus symptomatic treatment in patients with unresectable hepatocellular carcinoma: a randomised controlled trial. *Lancet* 2002; 359: 1734–1739.
17. Lo CM, Ngan H, Tso WK et al. Randomized controlled trial of transarterial lipiodol chemoembolization for unresectable hepatocellular carcinoma. *Hepatology* 2002; 35: 1164–1171.
18. Doffoël M, Bonnetain F, Bouché O et al. Multicentre randomised phase III trial comparing tamoxifen alone or with transarterial lipiodol chemoembolization for unresectable hepatocellular carcinoma in cirrhotic patients (Fédération Francophone de Cancérologie Digestive 9402). *Eur J Cancer* 2008; 44: 528–538.
19. Groupe d'Etude de Traitement du Carcinome Hépatocellulaire. A comparison of lipiodol chemoembolization and conservative treatment for unresectable hepatocellular carcinoma. *N Engl J Med* 1995; 332: 1256–1261.
20. Llovet JM, Bruix J. Barcelona Clinic Liver Cancer Group. Systematic review of randomized trials for unresectable hepatocellular carcinoma: chemoembolization improves survival. *Hepatology* 2003; 37: 429–442.
21. Cammà C, Schepis F, Orlando A et al. Transarterial chemoembolization for unresectable hepatocellular carcinoma: meta-analysis of randomized controlled trials. *Radiology* 2002; 224(1): 47–54.
22. Raoul JL, Sangro B, Forner A et al. Evolving strategies for the management of intermediate-stage hepatocellular carcinoma: available evidence and expert opinion on the use of transarterial chemoembolization. *Cancer Treat Rev* 2011; 37(3): 212–220.
23. Gillmore R, Stuart S, Kirkwood A et al. EASL and mRECIST responses are independent prognostic factors for survival in hepatocellular cancer patients treated with transarterial embolization. *J Hepatol* 2011; 55(6): 1309–1316.
24. Shim JH, Lee HC, Kim SO et al. Which response criteria best help predict survival of patients with hepatocellular carcinoma following chemoembolization? A validation study of old and new models. *Radiology* 2012; 262(2): 708–718.
25. Kim BK, Kim KA, Park JY et al. Prospective comparison of prognostic values of modified response evaluation criteria in solid tumours with European Association for the Study of the Liver criteria in hepatocellular carcinoma following chemoembolisation. *Eur J Cancer* 2013; 49(4): 826–834.
26. Golfieri R, Cappelli A, Cucchetti A et al. Efficacy of selective transarterial chemoembolization in inducing tumor necrosis in small (<5 cm) hepatocellular carcinomas. *Hepatology* 2011; 53(5): 1580–1589.
27. Lammer J, Malagari K, Vogl T et al.; PRECISION V Investigators. Prospective randomized study of doxorubicin-eluting-bead embolization in the treatment of hepatocellular carcinoma: results of the PRECISION V study. *Cardiovasc Intervent Radiol* 2010; 33(1): 41–52.
28. Malagari K, Pomoni M, Kelekis A et al. Prospective randomized comparison of chemoembolization with doxorubicin-eluting beads and bland embolization with BeadBlock for hepatocellular carcinoma. *Cardiovasc Intervent Radiol* 2010; 33(3): 541–551.
29. Malagari K, Pomoni M, Moschouris H et al. Chemoembolization with doxorubicin-eluting beads for unresectable hepatocellular carcinoma: five-year survival analysis. *Cardiovasc Intervent Radiol* 2012; 35(5): 1119–1128.
30. Burrel M, Reig M, Forner A et al. Survival of patients with hepatocellular carcinoma treated by transarterial chemoembolization (TACE) using DCBeads. Implications for clinical practice and trial design. *J Hepatol* 2012; 56(6): 1330–1335.
31. Salem R, Lewandowski RJ, Mulcahy MF et al. Radioembolization for hepatocellular carcinoma using Yttrium-90 microspheres: a comprehensive report of long-term outcomes. *Gastroenterology* 2010; 138: 52–64.
32. Ibrahim SM, Lewandowski RJ, Sato KT et al. Radioembolization for the treatment of unresectable hepatocellular carcinoma: a clinical review. *World J Gastroenterol* 2008; 14: 1664–1669.
33. Woodall CE, Scoggins CR, Ellis SF et al. Is selective internal radioembolization safe and effective for patients with inoperable hepatocellular carcinoma and venous thrombosis? *J Am Coll Surg* 2009; 208: 375–382.
34. Park JW, Koh YH, Kim HB et al. Phase II study of concurrent transarterial chemoembolization and sorafenib in patients with unresectable hepatocellular carcinoma. *J Hepatol* 2012; 56(6): 1336–1342.
35. Dufour JF. TACE with or without systemic therapy? *J Hepatol* 2012; 56(6): 1224–1225.
36. Farinati F, Giacomin A, Vanin V et al. TACE treatment in hepatocellular carcinoma: what should we do now? *J Hepatol* 2012; 57(1): 221–222.
37. Bruix J, Raoul JL, Sherman M et al. Efficacy and safety of sorafenib in patients with hepatocellular carcinoma (HCC): subanalysis of sharp trial based on Barcelona Clinic Liver Cancer (BCLC) stage. *J Hepatol* 2009; 50: S28–S29.
38. Lencioni R. Second interim results of the GIDEON (Global Investigation of Therapeutic DEcisions in HCC and of its treatment with sorafenib) study: Barcelona Clinic Liver Cancer (BCLC) Stage Subgroup Analysis (abstract #6500). In: ESMO-ECCO oncology meeting Stockholm; 2011.
39. Iavarone M, Cabibbo G, Piscaglia F et al.; SOFIA (SORafenib Italian Assessment) study group. Field-practice study of sorafenib therapy for hepatocellular carcinoma: a prospective multicenter study in Italy. *Hepatology* 2011; 54(6): 2055–2063.
40. Dufour JF, Johnson P. Liver cancer: from molecular pathogenesis to new therapies: summary of the EASL single topic conference. *J Hepatol* 2010; 52: 296–304.
41. Lencioni R. Chemoembolization for hepatocellular carcinoma. *Semin Oncol* 2012; 39(4): 503–509.
42. Dufour JF, Hoppe H, Heim MH et al. Continuous administration of sorafenib in combination with transarterial chemoembolization in patients with hepatocellular carcinoma: results of a phase I study. *Oncologist* 2010; 15(11): 1198–1204.
43. Lencioni R, Llovet JM, Han G et al. Sorafenib or placebo in combination with transarterial chemoembolization (TACE) with doxorubicin-eluting beads (DEBDOX) for intermediate-stage hepatocellular carcinoma (HCC): Phase II, randomized, double-blind SPACE trial. *J Clin Oncol* 2012; 30(Suppl. 4): abstr LBA154.
44. Terzi E, Golfieri R, Piscaglia F et al. Response rate and clinical outcome of HCC after first and repeated cTACE performed 'on demand'. *J Hepatol* 2012; 57(6): 1258–1267.
45. Georgiades C, Geschwind JF, Harrison N et al. Lack of response after initial chemoembolization for hepatocellular carcinoma: does it predict failure of subsequent treatment? *Radiology* 2012; 265(1): 115–123.