

### ***Waddlia chondrophila*: From Bovine Abortion to Human Miscarriage**

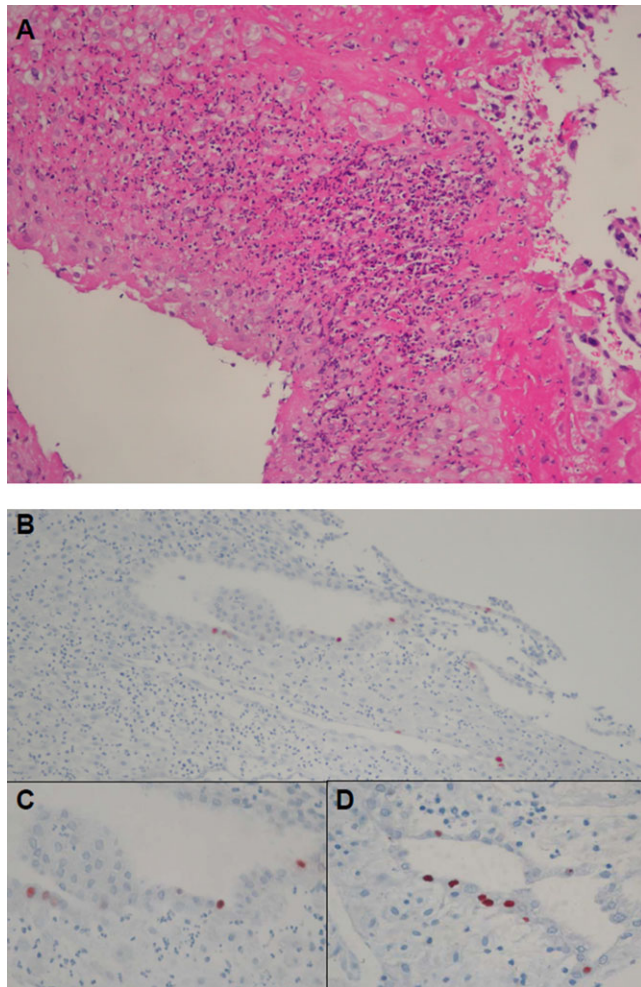
TO THE EDITOR—Miscarriage is the most common complication of pregnancy, affecting every fourth woman during her life [1]. Despite thorough investigations, an etiology is elucidated in only 50% of cases. A recent serological study has suggested a role of *Waddlia chondrophila*, a strict intracellular bacteria belonging to the Chlamydiales order, in human miscarriage [2]. Thus, 96 out of 438 women exhibited an anti-*Waddlia* immunoglobulin G (IgG) titer  $\geq 1:64$ . This seroprevalence was significantly higher in patients with miscarriage (32%) compared with control women with an uneventful pregnancy (7%,  $P < .001$ ). Anti-*Waddlia* antibodies were specific, as they did not cross-react with antibodies directed against other Chlamydiaceae (ie, *Chlamydia trachomatis*, *Chlamydia pneumoniae*, or *Chlamydia psittaci*) or other intracellular bacteria such as *Rickettsia*, *Coxiella*, *Wolbachia*, and *Anaplasma* [2–4]. Moreover, the strong statistical

association between miscarriage and IgG reactivity against *Waddlia* remained when adjusted for possible confounding factors in various multivariate logistic regression models [2]. However, direct demonstration of *Waddlia* in human placenta has not yet been reported. We thus investigated the role of *Waddlia* in human miscarriage prospectively as part of an ongoing study. This study has been approved by the local ethical committee (reference number 138/06). We herein document the first case of *Waddlia*-associated miscarriage by demonstrating the direct presence of *Waddlia* in the cervicovaginal secretion and in the placenta by polymerase chain reaction (PCR) and immunohistochemistry.

After a normal pregnancy and a first early miscarriage, a 34-year-old white woman presented with a second miscarriage at week 10 of gestation. The patient did not report any prior medical or surgical history. She neither had pets nor contact with animals, and she did not live in a rural area. The patient underwent a dilatation and curettage, during which retained products of conception, serum, and cervicovaginal swab were collected. Postoperative follow-up was uneventful.

Immunofluorescence was performed as previously described [2] and showed a positive anti-*Waddlia* antibody serology (titer 1:64). In addition, DNA of *Waddlia* was amplified from the cervicovaginal swab using a *Waddlia* specific real-time PCR [5]. The patient had neither *Chlamydia trachomatis*-positive serology nor DNA in the cervicovaginal swab. Placental histology showed the presence of numerous polymorphonuclear cells in the fibrin of the decidua, compatible with an early infection (Figure 1A). Moreover, *Waddlia* immunohistochemistry showed the presence of *Waddlia* infected cells localised in the glandular epithelium (Figures 1B, C, and D).

We thus show here strong evidence of human infection with *Waddlia*



**Figure 1.** Histological Pictures and Immunohistochemistry to Detect *Waddlia chondrophila*. (A), Hematoxylineosin–stained histological sections of the placenta (magnification  $\times 200$ ). (B, C, and D) Immunohistochemistry (magnification  $\times 200$  for B,  $\times 400$  for C and D) using a specific rabbit polyclonal antibody (dilution of 1:12,000) to investigate for the presence of *Waddlia* in the placenta. Detection was performed with the Dako ChemMate Detection Kit according to the manufacturer's instructions. The histological picture (A) shows infiltration of the placenta with numerous polymorphonuclear cells compatible with early infection. Immunohistochemistry (B, C, and D) demonstrated the presence of *Waddlia* in epithelial cells of the endometrial glands.

*chondrophila*. Indeed, *Waddlia* infection was documented by serology, by PCR, and by immunohistochemistry. The latter test confirmed the presence of *Waddlia* in the placenta, in an area exhibiting signs of recent infection.

Animals are an important infection source and reservoir of emerging human pathogens. *Waddlia* was first identified in bovine abortion [1, 3, 4]. Other zoonotic pathogens, such as *Toxoplasma gondii*, *Chlamydophila abortus*, and *Coxiella burnetii* are well-known agents of adverse human pregnancy outcomes. Whether

human infection with *Waddlia* occurs through contact with animals is still questionable. In this case, the patient did not have any contact with animals. But transmission might also occur through ingestion of contaminated milk or meat. Since *Waddlia* has also been recovered in the vaginal and respiratory tract area of humans [5], human-to-human transmission is also possible. The high *Waddlia* seroprevalence in women suffering from miscarriage [2] makes further investigations urgently necessary to explore the role of *Waddlia* in this setting.

This first report of *Waddlia* in miscarriage might give new insight in the prevention and investigation of miscarriage, the most frequent complication of human pregnancy.

### Acknowledgments

We thank all midwives and doctors who participated in the sampling for this study. Their involvement was essential to the whole process, and they enthusiastically gave their time to provide information and samples. We thank Sebastien Aeby for technical help, and Francoise Damnon and Andre Baud for computer assistance.

**Financial support.** This work was supported by the University of Lausanne (interdisciplinary grant); the Swiss National Science Foundation (FN3200B0-116445 and FN310030-130466); the Institute of Microbiology; the Department of Obstetrics and Gynecology; the Société Académique Vaudoise (“Paul Blanc” grant to D. B.); the SICPA Foundation (D. B.); and the Leenards Foundation (Bourse Leenards pour la relève académique en médecine clinique à Lausanne [career award] to G. G.).

**Potential conflicts of interest.** All authors: No reported conflicts.

All authors have submitted the ICMJE Form for Disclosure of Potential Conflicts of Interest. Conflicts that the editors consider relevant to the content of the manuscript have been disclosed in the Acknowledgements section.

**David Baud,<sup>1,2</sup> Genevieve Goy,<sup>1</sup> Maria-Chiara Osterheld,<sup>3</sup> Nicole Borel,<sup>4</sup> Yvan Vial,<sup>2</sup> Andreas Pospischil,<sup>4</sup> and Gilbert Greub<sup>1,5</sup>**

<sup>1</sup>Department of Laboratory, Institute of Microbiology, University Hospital Centre and University of Lausanne, <sup>2</sup>Department of Obstetrics and Gynaecology, Maternity, University Hospital Centre, and, <sup>3</sup>Vetsuisse Faculty, Institute of Pathology, University Hospital Centre, Lausanne, Switzerland; <sup>4</sup>Department of Laboratory Medicine, Institute of Veterinary Pathology, University of Zürich, Zürich, Switzerland; and <sup>5</sup>Infectious Disease Service, Department of Internal Medicine, University Hospital Centre, Lausanne, Switzerland

### References

1. Baud D, Regan L, Greub G. Emerging role of *Chlamydia* and *Chlamydia*-like organisms in adverse pregnancy outcomes. *Curr Opin Infect Dis* 2008; 21:70–6.
2. Baud D, Thomas V, Arafa A, Regan L, Greub G. *Waddlia chondrophila*, a potential agent of human fetal death. *Emerg Infect Dis* 2007; 13:1239–43.
3. Rurangirwa FR, Dilbeck PM, Crawford TB, McGuire TC, McElwain TF. Analysis of the 16S rRNA gene of micro-organism WSU 86-1044 from an aborted bovine foetus reveals that it is a member of the order Chla-

- mydiales: Proposal of Waddliaceae fam. nov., *Waddlia chondrophila* gen. nov., sp. nov. Int J Syst Bacteriol **1999**; 49(Pt 2):577–81.
4. Henning K, Schares G, Granzow H, et al. *Neospora caninum* and *Waddlia chondrophila* strain 2032/99 in a septic stillborn calf. Vet Microbiol **2002**; 85:285–92.
  5. Goy G, Croxatto A, Posfay-Barbe KM, Gervais A, Greub G. Development of a real-time PCR for the specific detection of *Waddlia chondrophila* in clinical samples. Eur J Clin Microbiol Infect Dis **2009**; 28:1483–6.

Correspondence: Gilbert Greub, MD, PhD, Center for Research on Intracellular Bacteria (CRIB), Institute of Microbiology, University Hospital Center and University of Lausanne, Bugnon 48, 1011 Lausanne, Switzerland (gilbert.greub@chuv.ch).

**Clinical Infectious Diseases 2011;52(12):1469–1471**

© The Author 2011. Published by Oxford University Press on behalf of the Infectious Diseases Society of America. All rights reserved. For Permissions, please e-mail: journals.permissions@oup.com.  
1058-4838/2011/5212-0013\$14.00  
DOI: 10.1093/cid/cir205