



ELSEVIER

European Journal of Cardio-thoracic Surgery 36 (2009) 210–211

EUROPEAN JOURNAL OF
CARDIO-THORACIC
SURGERY

www.elsevier.com/locate/ejcts

Case report

Septal myectomy for hypertrophic obstructive cardiomyopathy: coil, boil and the role of rescue surgery

Thierry Carrel^{*}, Jürg Schmidli

Department of Cardiovascular Surgery, University Hospital Berne, CH-3010 Berne, Switzerland

Received 28 October 2008; received in revised form 16 March 2009; accepted 17 March 2009; Available online 1 May 2009

Abstract

Interventional treatment of hypertrophic obstructive cardiomyopathy has considerably developed and primary surgical approach is nowadays considered for a minority of patients with insufficient relief of obstruction following catheter intervention. We present the history of a patient who underwent alcohol ablation and developed a life-threatening ventricular septal defect consecutively to a large myocardial infarction because of alcohol injection into the LAD.

© 2009 European Association for Cardio-Thoracic Surgery. Published by Elsevier B.V. All rights reserved.

Keywords: Hypertrophic cardiomyopathy; Coil embolisation; Alcohol ablation; Surgery; Complications

1. Introduction

Treatment of hypertrophic obstructive cardiomyopathy (HOCM) was exclusively a surgical topic until new transcatheter intervention methods were demonstrated to be successful as well. Recently, Durand and co-authors described the feasibility of coil embolisation for the treatment of HOCM. Twenty patients with drug-refractory symptoms underwent septal reduction using embolisation of detachable coils [1]. Occlusion of septal branches was 'successfully' performed in all patients. No patient developed heart block or ventricular tachycardia. However, one patient developed post-interventional ventricular septal defect (VSD) and died 19 days following the procedure. At 6-month follow-up, functional class and peak oxygen consumption significantly improved compared to baseline. Echocardiography showed a significant ($p < 0.001$) reduction of the septum thickness (21 ± 3 to 17 ± 4 mm) and LVOT pressure gradient (80 ± 29 to 35 ± 29 mmHg).

In the same journal, Togni and co-authors emphasised the successful results [2]. As usual for the evaluation of an interventional procedure, the follow-up was very short. In this context, one should not forget that surgical myectomy has been shown to provide excellent durable results, with survival rates similar to those of a normal population [3].

The post-infarction VSD, a life-threatening complication, is described with a few words only [1]. Unfortunately, papers dealing with the transcatheter options for HOCM do not

address this disastrous complication for the simple reason that once it has occurred, it turns out to be a surgical problem. Interestingly, the most comprehensive paper on that issue has not been published by cardiologists but by pathologists [4]!

In a recent comment on alcohol ablation, Sigwart claimed that alcohol ablation can be guided very precisely by 2D-echocardiography [5]. The following observation emphasises the fact that this affirmation remains speculative, even in the hands of very experienced interventional cardiologists.

2. Case report

A 60-year-old female patient was referred because of shortness of breath functional class NYHA II, dizziness and uncharacteristic thoracic pains. Echocardiography showed a classical HOCM with systolic anterior motion of the mitral valve and consecutive mild mitral regurgitation. LVOT mean/maximal pressure gradients were 102/207 mmHg at rest and 150/250 mmHg following amyl nitrite testing. There was a significant LV-hypertrophy but systolic function was normal (EF 65%). Treatment consisted of nifedipin 2×80 mg daily and magnesium.

Indication for alcohol ablation was confirmed. During coronary angiography, 2.5 ml of alcohol 95% were injected during 11 min in the 1st septal branch. Some alcohol came back in the LAD which resulted in immediate LAD occlusion. A TITAN-stent was implanted but there was a no-reflow phenomenon. Mean, resp. maximal pressure gradient was described to have decreased from 68/112 to 12 mmHg immediately after the procedure. One day following the procedure, the mean/max

^{*} Corresponding author. Tel.: +41 31 632 23 75; fax: +41 31 632 44 43.
E-mail address: thierry.carrel@insel.ch (T. Carrel).

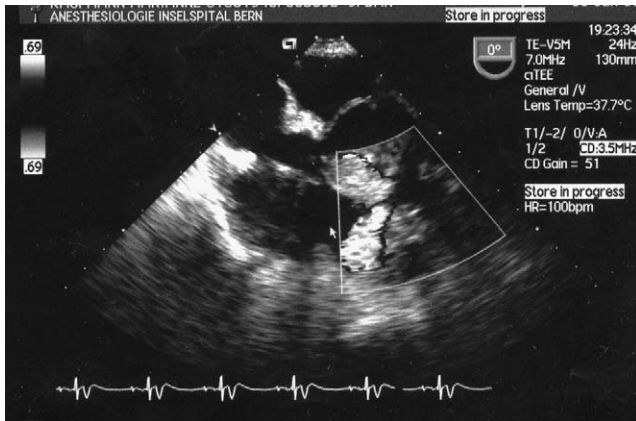


Fig. 1. TEE with four chamber view showing the large VSD at the mid-ventricular septum.

pressure gradient at rest was still significant 48/95 mmHg, despite the fact that the LV-function had considerably deteriorated (EF 45%) due to a large antero-septal myocardial infarction (maximal CK 4000 micromol/ml). Post-interventional bleeding at the femoral artery puncture site required transfusion of 2 packs of erythrocytes. On post-procedural day 2, the patient complained about retrosternal pains and developed haemodynamic instability. Echocardiography showed a non-restrictive ventricular septal defect, a mild to moderate mitral regurgitation and a circular pericardial effusion (Fig. 1).

Because of increasing haemodynamic instability, immediate surgery was performed under moderate hypothermic cardiopulmonary bypass. The VSD was approached through a left ventriculotomy parallel to the LAD and closed with a pericardial patch using interrupted sutures. The hypertrophic septum was resected from below the aortic valve until deep into the left ventricle and the papillary muscles were mobilised. The mitral valve was repaired with an annuloplasty ring.

Unfortunately, the LAD could not be revascularised since it was completely thrombosed. Weaning from cardiopulmonary bypass required substantial inotropic support. Pacemaker was necessary because of av block III. Recovery was prolonged. Postoperative echocardiography on the ICU and before discharge (on p.o. day 25) showed trivial residual VSD, no residual gradient across the LVOT, a trivial mitral regurgitation. LV-EF was 45%.

3. Comment

This case illustrates that surgical myectomy for HOCM treatment is considered less and less frequently due to increasing enthusiasm for catheter-based interventions. During decades, the gold standard for treatment of HOCM has been surgical resection with excellent short- and long-term results [3,6]. In the last 15 years, alcohol ablation and most recently coil embolisation were found to be attractive options to release the LVOT pressure gradient. Increasing experience showed that alcohol ablation penetrates more deeply into the septal region and induces a corresponding area of necrosis, whereas coil embolisation leads primarily to ischaemia and only secondarily to necrosis.

The short comment by Togni and co-authors entitled ‘Septal myectomy: cut, coil or boil?’ does unfortunately not address the advantages of the surgical approach which allows the most precise and complete resection under view and the mobilisation of the papillary muscles from the hypertrophied septum and the free left-ventricular wall. In addition, it does not address the problem of iatrogenic VSD and its obligatory treatment [7].

Working closely with the cardiologists (which has been done extremely successfully during the last 10 years in our institution) may attenuate the fact that surgery is considered only to rescue patients from life-threatening complications following catheter interventions. However, it will be necessary to re-assess some of the very long-term results of standard surgical procedures to ensure objective comparison with the new, less invasive techniques.

In the case described above, the surgical approach allowed precise and complete resection of the hypertrophic septum and was able to abolish (and not only to reduce) the LVOT pressure gradient, which was still significant following alcohol ablation. In addition, surgery allowed for additional repair of the mitral valve but due to complete occlusion of the LAD, no revascularisation was performed. Since alcohol induces a chemical lesion, the reason for stent insertion (additional foreign material) was not clear: it might have been a typical cardiologist’s ‘reflex’ to treat acute coronary occlusion.

We conclude that surgical treatment has still a role to play in HOCM disease and should not be limited to the treatment of life-threatening complications [8,9].

References

- [1] Durand E, Mousseaux E, Coste P, Pilière R, Dubourg O, Trinquart L, Chatellier G, Hagege A, Desnos M, Lafont A. Non-surgical septal myocardial reduction by coil embolization for hypertrophic obstructive cardiomyopathy: early and 6 months follow-up. *Eur Heart J* 2008;29:348–55.
- [2] Togni M, Billinger M, Cook S, Hess O. Septal myectomy: cut, coil or boil? *Eur Heart J* 2008;29:296–8.
- [3] Schoendube FA, Klues HG, Reith S, Flachskampf FA, Hanrath P, Messmer BJ. Long-term clinical and echocardiographic follow-up after surgical correction of hypertrophic obstructive cardiomyopathy with extended myectomy and reconstruction of the subvalvular mitral apparatus. *Circulation* 1995;92(Suppl. II):II122–7.
- [4] Batalis NI, Harley RA, Collins KA. Iatrogenic deaths following treatment for hypertrophic obstructive cardiomyopathy: case reports and approach to the autopsy and death certification. *Am J Forensic Med Pathol* 2005;26:343–8.
- [5] Sigwart U. Non surgical myocardial reduction for hypertrophic obstructive cardiomyopathy. *Lancet* 1995;346:211–4.
- [6] Schulte HD, Bircks W, Lösse B. Techniques and complications of transaortic subvalvular myectomy in patients with hypertrophic obstructive cardiomyopathy. *Z Kardiol* 1987;76(Suppl. 3):145–51.
- [7] Aroney CN, Goh TH, Hourigan LA, Dyer W. Ventricular septal rupture following nonsurgical septal reduction for hypertrophic cardiomyopathy: treatment with percutaneous closure. *Catheter Cardiovasc Interv* 2004;61:411–4.
- [8] Maron BJ, McKenna WJ, Danielson GK, Kappenberger LJ, Kuhn HJ, Seidman CE, Shah PM, Spender WH, Spirito P, Ten Cate FJ, Wigle ED. Task Force on Clinical Expert Consensus Documents. American College of Cardiology/European Society of Cardiology clinical expert consensus document on hypertrophic cardiomyopathy. *J Am Coll Cardiol* 2003;42:1687–713.
- [9] Talreja DR, Nishimura RA, Edwards WD, Valeti US, Ommen SR, Tajik AJ, Dearani JA, Schaff HV, Holmes DR. Alcohol septal ablation versus surgical septal myectomy: comparison of effects on atrioventricular conduction tissue. *J Am Coll Cardiol* 2004;44:2329–32.