

PAEDIATRICS

**Clinical evaluation of cuff and tube tip position
in a newly designed paediatric preformed
oral cuffed tracheal tube**

M. Weiss¹*, A. Dullenkopf¹, S. Böttcher², A. Schmitz¹, K. Stutz¹, C. Gysin³
and A. C. Gerber¹

¹Department of Anaesthesia, ²Department of Paediatric Surgery and ³Department of Otolaryngology,
University Children's Hospital, Zurich, Switzerland

*Corresponding author: Department of Anaesthesia, University Children's Hospital, Steinwiesstrasse
75, 8032 Zurich, Switzerland. E-mail: markus.weiss@kispi.unizh.ch

Background. To assess the adequacy of the position of the tracheal tube cuff and tracheal tube tip in the recently introduced preformed oral Microcuff paediatric endotracheal tube (PET) using the manufacturers recommendations for Microcuff tracheal tube size selection.

Methods. With Hospital Ethics Committee approval and informed parental consent, the tracheas of children from birth to adolescence were orally intubated with the preformed oral Microcuff PET. First, the position of the tracheal tube's intubation depth mark in relation to the vocal cords was assessed. Second, the distance 'tracheal tube tip-to-carina' was endoscopically measured with the patient supine and the head in a neutral position and the tube placed with the centre mark at the lower incisors or alveolar ridge.

Results. A total of 166 children aged from 0.1 to 16.4 yr (median 5.9 yr) were studied. In five patients the intubation depth mark was above (5 mm each), in 22 patients at the level of and in the remaining 139 patients below the vocal cords. No endobronchial intubation occurred. In four patients the distance 'tracheal tube tip-to-carina' was smaller than the safety margin to prevent endobronchial intubation during head-neck flexion.

Conclusion. The new oral preformed cuffed tracheal tubes allow safe placement in almost all patients when inserted according to the tube bend. The critically low tube tip and the high cuff positions in a few tubes when placed according to the tube bend requires clinical alertness.

Br J Anaesth 2006; **97**: 695–700

Keywords: equipment, tubes tracheal, cuff; equipment, tubes tracheal, oral; equipment, tubes tracheal, preformed

Accepted for publication: July 23, 2006

Introduction

The use of cuffed tracheal tubes in children below the age of 8 yr has become popular for several reasons.^{1–6} The suggested benefits are a low tracheal tube exchange rate and a sealed airway without the use of over-sized uncuffed tracheal tubes.⁷ Preformed cuffed tracheal tubes are of particular interest for ear-nose-throat (ENT) and cleft surgery as the tube cuff allows compensation for an excessive air leak and protection against pulmonary aspiration of blood. In addition, discharge of anaesthetic gases is reduced, which is helpful to the surgeon operating at the patient's head.

As poorly designed cuffed tracheal tubes can cause airway damage, the cuff position of paediatric tracheal tubes has become of interest.^{8–12} In Magill shaped cuffed tracheal tubes, an appropriate depth mark is placed at the level of the vocal cords to ensure that the cuff truly is below the vocal cords and on the other hand the tube is not advanced too far into the trachea.^{13 14} However, in preformed cuffed tracheal tubes, the final position of the cuff and of the tube tip within the trachea is predetermined, because the tube's bend is intended to be placed with the centre of its concave curvature facing the lower incisors or alveolar ridge. So far there are no clinical studies investigating cuff and tube tip

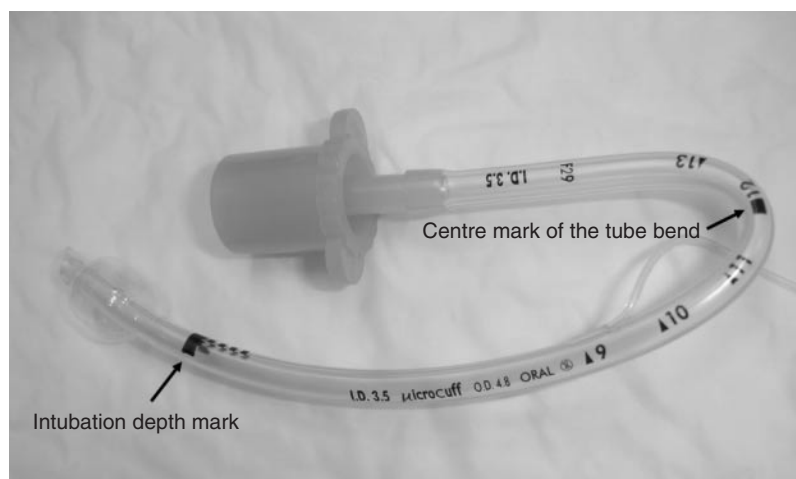


Fig 1 Oral preformed Microcuff PET with distally placed high-volume low-pressure polyurethane cuff (thickness of cuff membrane 10 μm), intubation depth mark, and centre mark at the tube bend.

position in preformed oral cuffed paediatric tracheal tubes, when the tracheal tube is placed according to its tube bend.

The aim of the present study was to evaluate the appropriateness of the tracheal tube cuff and tube tip position in the recently introduced preformed oral Microcuff paediatric tracheal tube (PET).

Methods

The study was approved by the Hospital Ethical Review Board and informed parental consent was required for inclusion into the study. Children from birth up to 16 yr undergoing elective surgery requiring endotracheal intubation with a preformed oral tracheal tube were studied. The tracheas were intubated with preformed oral Microcuff PETs (Microcuff GmbH, Weinheim, Germany) with high-volume, low-pressure cuffs made from polyurethane (Fig. 1). The Microcuff recommendations for Magill type tracheal tube size selection were used.^{7,12} These are based on Motoyama's formula for selection of cuffed tracheal tubes in children aged 2 yr or older and on Khine's recommendations for patients below 2 yr of age (Table 1).^{4,15}

After induction of anaesthesia and neuromuscular block, the patients' tracheas were intubated with an appropriately sized oral preformed Microcuff PET under direct laryngoscopy. First, the tracheal tube was placed with its intubation depth mark at the level of the vocal cords and initial oral tube insertion depth was read at the lower alveolar ridge or lower incisors (Fig. 2—Step A). Next, the tube was inserted further or drawn back until the centre mark of the bend was at the lower incisors or alveolar ridge (Fig. 2—Step B). In this position, the tube was taped to the patient's chin. In those patients in whom the intubation depth mark was above the vocal cords after Step B the tracheal tube was inserted further into the trachea and taped to the chin, so that the intubation depth mark was at the level of the vocal cords (Step C). Afterwards, the lungs were checked for bilateral breath sounds.

Tracheal tube size was judged as adequate if the leak pressure (airway pressure needed to establish an air leak around the tracheal tube with the cuff not inflated) was 20 cm H₂O or less and if the sealing pressure (cuff pressured to seal the trachea) was 20 cm H₂O or less. The tube was exchanged to the next smaller size if the leak pressure was too high and was changed to the next larger size if a cuff pressure more than 20 cm H₂O was necessary to prevent a leak.

With the tracheal tube in position after Step B or if further adjustment was required, after Step C, the distance from the tracheal tube tip to the carina was endoscopically assessed with the patient supine and the head in a neutral position. The head was said to be in a neutral position if the external auditory meatus and the superior orbital margin were vertically aligned. Endoscopic assessment was performed using a flexible fibroscope attached to a video-monitor system (Flexible Airway Endoscopes, OD 1.9, 2.9 and 3.9 mm, Acutronic Medical Systems, Baar, Switzerland). A drawback technique was used. The fibroscope was advanced into the left main bronchus and was drawn back until the crest of the tracheal carina was seen. A clip was placed on the fibroscope at the level of the tube adaptor. Then, the endoscope was further drawn back until the tube tip became visible. The distance between the clip and the level of the tube adaptor was then measured.¹³ The distance from tracheal tube tip-to-carina was compared with the distance needed (margin of safety) to prevent endobronchial intubation during head-neck flexion. This margin of safety was obtained from a previous study by our group and ranges from 1 cm in newborns to about 2 cm at 16 yr of age.¹⁶

Results

A total of 166 children aged from 0.1 to 16.4 yr (median 5.9 yr) were studied. In all patients the leak pressure was 20 cm H₂O or less (median 4 cm H₂O) with the cuff not

Table 1 Age-related tracheal tube size selection,^{7,14} technical data for the preformed Microcuff® PET¹²⁻¹⁴ and oral intubation depths for straight paediatric tracheal tubes.^{26,27} Tube size selection in children aged under 2 yr was based on Khine's recommendations.⁴ Tube size selection in children aged 2 yr or more was based on Motoyama's formula [internal diameter in millimetres=(age in years/4)+3.5].¹⁵ ID, internal diameter

| Internal diameter (mm) | Age group (yr) | Distance from depth mark to tube tip (mm) | Distance from the centre of the bend to tube tip (mm) | Distance from the depth mark to upper border to the cuff (mm) | Oral tube insertion depth for straight tracheal tubes (mm) |
|------------------------|------------------------|---|---|---|--|
| ID 3.0 | Newborns (≥3 kg) to <1 | 24 | 105 | 9 | 90–120 |
| ID 3.5 | 1 to <2 | 27 | 120 | 10 | 120–130 |
| ID 4.0 | 2 to <4 | 30 | 130 | 12 | 130–140 |
| ID 4.5 | 4 to <6 | 34 | 150 | 12 | 140–150 |
| ID 5.0 | 6 to <8 | 39 | 155 | 16 | 150–160 |
| ID 5.5 | 8 to <10 | 45 | 165 | 16 | 160–170 |
| ID 6.0 | 10 to <12 | 50 | 180 | 18 | 170–180 |
| ID 6.5 | 12 to <14 | 54 | 190 | 19 | 180–190 |
| ID 7.0 | 14 to <16 | 58 | 200 | 22 | 190–200 |

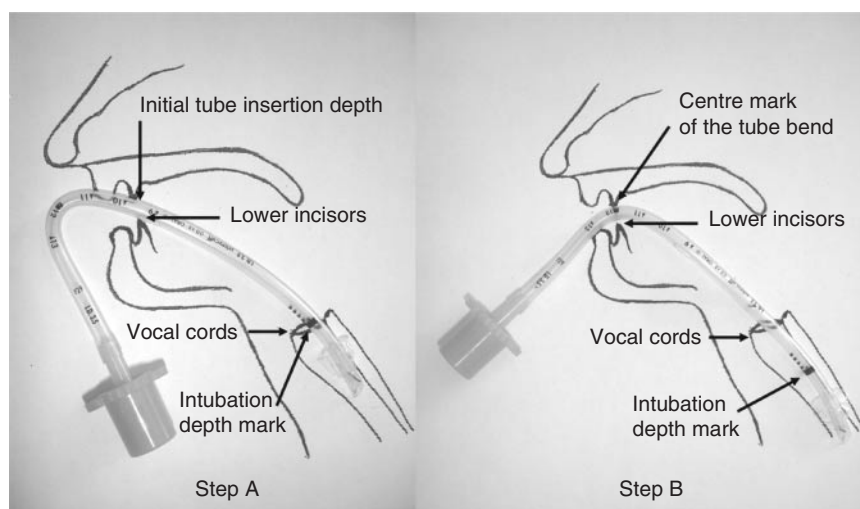


Fig 2 Step A: The oral preformed tracheal tube inserted with intubation depth mark at the level of the cords. Initial tube insertion depth is read at the lower incisors or alveolar ridge. Step B: The oral preformed tracheal tube is advanced until the centre mark of the tube bend is at the lower incisors or alveolar ridge.

inflated. A complete seal was achieved in all patients with cuff pressures ranging from 0 to 20 cm H₂O (median 10 cm H₂O) (Table 2). No tube exchange was required because of an ill-fitting tube.

After step B the intubation depth mark position was above the vocal cords (5 mm each case) in five patients, necessitating further advancement of the tube, at the level of the vocal cords in 22 patients, and in the remaining 139 patients below the vocal cords (range 5–40 mm).

The intubation depth mark was above the vocal cords in four children intubated with a 3.0 mm ID tracheal tube (0.71, 0.75, 0.57 and 0.8 yr old infants), and in one child with a 4.0 mm ID tracheal tube inserted (3.3 yr old child).

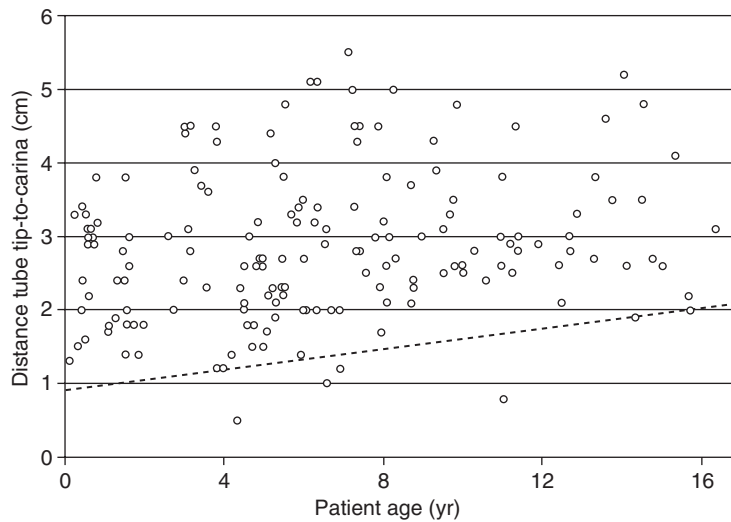
No endobronchial intubation occurred after Step B, or after Step C in the case of tubes that needed further adjustment. The distance from the tracheal tube tip to the carina ranged from 5 to 55 mm (Table 2). In 4 patients the distance from the tracheal tube tip to the carina was smaller than the required safety margin to prevent endobronchial intubation during head-neck flexion (Fig. 3).

Discussion

Preformed oral tracheal tubes were first described by Ring, Adair and Elwyn (therefore called RAE tubes) and were introduced in the late 1970s.¹⁷ They are prebent to reduce the likelihood of kinking and to make them suitable for surgery of the mouth and face. Preformed tracheal tubes fit better into an oral gag, are easier to secure to the chin and may reduce the risk of unintended extubation. A major limitation is that their flexion point is fixed and that, for a given internal diameter, the tracheal tube is available in only one length. Therefore, if a patient with a narrow cricoid ring requires a preformed tracheal tube that is smaller than usual for its age, the tracheal tube may be too short and may become dislodged accidentally during surgery. If a larger uncuffed tube is used for a patient with an unusually wide trachea, the tracheal tube may be too long and its tip could enter a main bronchus.¹⁸ Consequently, the bend often has to be placed within or outside the oral cavity, making kinking and tube

Table 2 Patient characteristics, leak and sealing pressures, position of the intubation depth mark related to the vocal cords and measured distance from the tube tip-to-carina. Data are median (range), $n=166$. ID, internal diameter

| Age (yr) | ID (mm) | Number of patients | Age (yr) | Weight (kg) | Height (cm) | Leak pressure (cm H ₂ O) | Sealing pressure (cm H ₂ O) | Intubation depth mark position in relation to the vocal cords (cm) | Distance tube tip to carina (cm) |
|--------------|---------|--------------------|------------------|----------------|---------------|-------------------------------------|--|--|----------------------------------|
| All patients | 3.0–7.0 | 166 | 5.9 (0.1–16.4) | 21 (4.5–75.0) | 115 (57–173) | 4 (2–20) | 10 (0–20) | 1.0 (–0.5 to 4.0) | 2.8 (0.8–5.5) |
| <1 | 3.0 | 18 | 0.6 (0.1–0.8) | 8.0 (4.5–10.6) | 67 (57–79) | 7 (4–16) | 12 (0–16) | 0 (–0.5 to 1.5) | 3.0 (1.3–3.8) |
| 1 | 3.5 | 14 | 1.5 (1.1–1.9) | 9.5 (7.0–13.4) | 77 (71–84) | 7 (4–10) | 9 (8–14) | 1.0 (0–2.0) | 2.0 (1.4–3.8) |
| 2–3 | 4.0 | 17 | 3.2 (2.0–3.9) | 15.5 (10–20) | 100 (87–111) | 6 (2–16) | 10 (0–16) | 0.5 (–0.5 to 1.0) | 3.6 (1.2–4.5) |
| 4–5 | 4.5 | 36 | 5.0 (4.0–5.9) | 19 (13–28) | 111 (99–124) | 4 (2–18) | 10 (0–20) | 1.5 (0.5–3.5) | 2.3 (0.5–4.8) |
| 6–7 | 5.0 | 26 | 6.9 (6.0–7.9) | 24 (19–38) | 121 (112–135) | 4 (2–20) | 10 (4–16) | 1.0 (0–1.5) | 3.1 (1.0–5.5) |
| 8–9 | 5.5 | 21 | 8.8 (8.0–9.9) | 30 (21–44) | 134 (120–140) | 4 (2–10) | 10 (6–14) | 1.5 (0–3.5) | 3.0 (1.7–5.0) |
| 10–11 | 6.0 | 14 | 11.0 (10.0–11.9) | 36 (28–75) | 146 (133–159) | 5 (2–14) | 11 (6–14) | 1.5 (0–3.0) | 2.8 (0.8–4.5) |
| 12–13 | 6.5 | 10 | 13.1 (12.4–14.0) | 49 (35–55) | 155 (145–173) | 2 (2–8) | 11 (8–14) | 1.5 (0.5–3.0) | 3.2 (2.1–5.2) |
| 14–15 | 7.0 | 10 | 14.9 (14.4–16.4) | 55 (42–62) | 165 (150–173) | 4 (2–8) | 11 (8–16) | 2.0 (0–4.0) | 2.7 (1.9–4.8) |

**Fig 3** The distance ‘tube tip-to-carina’ is plotted against patient age. Tracheal tube tip position was endoscopically assessed with the preformed tube bend placed at the lower teeth or alveolar ridge ($n=166$). The dotted line shows data from a previous study and indicates maximal caudal displacement of the tube tip with 30° neck flexion (neonate 10 mm; adult patient 20 mm).¹⁶ Endobronchial intubation is predicted during neck flexion if the tube tip is below this line in the neutral position.

compression more likely and removing the benefit of the preformed bend.

As demonstrated in our study, these problems can be effectively overcome in most patients by the use of a cuffed preformed tracheal tube. Their reduced outer diameter compared with traditional uncuffed tracheal tubes provided a good fit (air leak at airway pressures of less than 20 cm H₂O with the cuff deflated) at the first intubation attempt and the cuff allowed the airway to be sealed at a low cuff pressure in all patients (median 10 cm H₂O). Furthermore, the preformed oral Microcuff PET allowed safe positioning of the tube cuff and tube tip in almost all children investigated when placed with the tracheal tube bend at the lower incisors or alveolar ridge.

Because the distance from the lower incisors or alveolar ridge to the vocal cords at any given age is variable it is not possible to design a tube that gives an optimal cuff and

tracheal tube tip position in all children. Using the oral preformed Microcuff tube the intubation depth mark was placed below the vocal cords in most of our patients. This is because the Microcuff intubation depth mark in straight tracheal tubes was designed to avoid endobronchial intubation in the shortest trachea of the related age group.^{12–14 16} Thus, when the preformed tracheal tube is placed according to the bend the intubation depth mark will become advanced further in the trachea in most of the patients. To prevent kinking the tube should be placed according to the bend. This should guarantee that the intubation depth mark will be at least at the vocal cords or below and that the tracheal tube tip will not be too deep.

As cuffed tracheal tubes are selected with internal diameter 0.5–1.0 mm less than uncuffed tracheal tubes, the bend and shape of a given cuffed preformed tracheal tube should be manufactured according to the 0.5–1.0 mm

larger sized uncuffed preformed tracheal tube. The bend and shape of the new oral preformed Microcuff PET is identical to that of an uncuffed preformed tracheal tube with identical ID. This would imply that the tubes are too short and the cuffs too high within the trachea. However, the intubation depth mark was placed above the vocal cords in only five children, with the cuff still being placed below the glottic region. In these patients the tube was inserted further into the trachea, so that the intubation depth mark was placed at least at the level of the vocal cords. On the other hand, although no endobronchial intubation occurred, in four patients the preformed cuffed tracheal tube carried a risk of endobronchial intubation during head-neck flexion, despite being shorter than their corresponding age-related uncuffed oral preformed tube. This is not surprising as uncuffed preformed tracheal tubes often are too long, especially in smaller children.^{19–21} This is because the first preformed tracheal tubes were designed by defining the maximal insertion depth that did not result in endobronchial intubation.¹⁷ This approach increased the risk of endobronchial intubation in many children. To overcome this problem most uncuffed oral preformed tracheal tubes are provided with two Murphy eyes near the bevel, one on the long side of the bevel and the other on the opposite short side. Mallinckrodt reduced the length of their oral preformed RAE paediatric tracheal tubes of ID 5.5 mm size and less by 5–15 mm (depending on the ID) for the European market in 1986.^{22–24} Nevertheless, in 1991 endobronchial intubation was still reported as a frequent event by Black and Mackersie, when using uncuffed oral preformed tracheal tubes in children.¹⁹ They studied 42 children aged between 3 months and 16 yr and reported that uncuffed oral preformed tracheal tubes were placed endobronchially in 20% of the children and were too long in 32%. In our study the oral preformed Microcuff PET without a Murphy's eye and with a short distally placed high-volume low-pressure polyurethane cuff allowed safe tracheal tube positioning when placed with the bend at the lower incisors or alveolar ridge in a large population of children of various ages.

However, as the tube bend determines cuff and tube tip position within the trachea, it is mandatory that an intubation depth mark is printed on the tracheal tube shaft and that this is placed at least at the level of the vocal cords during tracheal intubation in order to guarantee that the cuff is positioned below the vocal cords.

This is the first clinical investigation dealing with cuff position and tube tip position in oral preformed tracheal paediatric tubes. Our data will help to improve the design and the selection of oral cuffed preformed tracheal tubes. For example, our findings suggest that the ID 3.5 mm tracheal tube should be used in patients from 6 months of age up to 2 yr to obtain a lower tracheal tube cuff position. The use of a 3.5 mm ID Microcuff PET in children from 6 months onward has been shown not to result in an increased incidence of tube exchange or stridor.²⁵

This study evaluated tube placement with the head-neck in neutral position. During ENT and cleft palate surgery, the head-neck is often extended leading to various degree of upward movement of the tube.¹⁶ However, it must also be kept in mind that in ENT and cleft surgery an oral gag with tongue depressor is often inserted leading to downward movement of the tracheal tube.

In conclusion, the new oral preformed cuffed tracheal tubes used according to the manufacturer's recommendation for tube size selection allow safe placement of the tube tip in the trachea and tube cuff placement below the vocal cords in almost all patients when inserted according to the tube bend. The low tracheal tube tip position or overly high cuff position seen in a few patients requires clinical alertness.

Acknowledgements

Financial Disclosure Statement: The tracheal tubes were ordered from local distributors and paid for from departmental resources. M.W. and A.C.G. are involved in re-designing and improving cuffed paediatric tracheal tubes in co-operation with Microcuff GmbH, Weinheim, Germany, and Tyco Healthcare, Athlone, Ireland. No agreements or financial benefits was obtained from these co-operations.

References

- 1 American Heart Association. Part 12. Pediatric advanced life support. *Circulation* 2005; **112**: 167–87
- 2 The International Liaison Committee on Resuscitation (ILCOR) Consensus science with treatment recommendations for pediatric and neonatal patients: Pediatric Basic and Advanced Life Support. *Pediatrics* 2005; **117**: e955–77
- 3 Golden S. Cuffed versus uncuffed endotracheal tubes in children: a review. *News Letter of the American Society for Pediatric Anesthesia* 2006; **19**: 10–2
- 4 Khine HH, Corddry DH, Ketrwick RG *et al.* Comparison of cuffed and uncuffed endotracheal tubes in young children during general anesthesia. *Anesthesiology* 1997; **86**: 627–31
- 5 Murat I. Cuffed tubes in children: a 3-year experience in a single institution. *Paediatr Anaesth* 2001; **11**: 748–9 (Letter)
- 6 Newth CJ, Rachmann B, Patel N, Hammer J. The use of cuffed versus uncuffed endotracheal tubes in pediatric intensive care. *J Pediatr* 2004; **144**: 333–7
- 7 Dullenkopf A, Gerber AC, Weiss M. Fit and seal characteristics of a new paediatric tracheal tube with high volume—low pressure polyurethane cuff. *Acta Anaesthesiol Scand* 2005; **49**: 232–7
- 8 Ho AM, Aun CST, Karmakar MK. The margin of safety associated with the use of cuffed paediatric tracheal tubes. *Anaesthesia* 2002; **57**: 173–5
- 9 Holzki J. Tubes with cuffs in newborn and young children are a risk!. *Anaesthesist* 2002; **51**: 321–3 (in German)
- 10 Weiss M, Dullenkopf A, Gysin C, Dillier CM, Gerber AC. Shortcomings of cuffed paediatric tracheal tubes. *Br J Anaesth* 2004; **92**: 78–88
- 11 Dillier CM, Trachsel D, Baulig W, Gysin C, Gerber AC, Weiss M. Laryngeal damage due to an unexpectedly large and inappropriately designed cuffed pediatric tracheal tube in a 13-month-old child. *Can J Anaesth* 2004; **51**: 72–5
- 12 Weiss M, Dullenkopf A, Gerber AC. Microcuff pediatric tracheal tube. A new tracheal tube with a high volume-low pressure cuff for children. *Anaesthetist* 2004; **53**: 73–9 (German)

- 13 Weiss M, Balmer C, Dullenkopf A, *et al.* Intubation depth markings allow an improved positioning of endotracheal tubes in children. *Can J Anesth* 2005; **52**: 721–6
- 14 Weiss M, Gerber AC, Dullenkopf A. Appropriate placement of intubation depth marks in a new cuffed paediatric tracheal tube. *Br J Anaesth* 2005; **94**: 80–7
- 15 Motoyama EK. Endotracheal intubation. In: Motoyama EK. *Smith's Anesthesia for Infants and Children*. St. Louis: Mosby, 1990; 269–75
- 16 Weiss M, Knirsch W, Kretschmar O, *et al.* Tracheal tube-tip displacement in children during head-neck movement—a radiological assessment. *Br J Anaesth* 2006; **96**: 486–91
- 17 Ring WH, Adair JC, Elwyn RA. A new pediatric endotracheal tube. *Anesth Analg* 1975; **54**: 273–4
- 18 Fisher DM. Anesthesia equipment for pediatrics. In: Gregory GA, ed. *Pediatric Anesthesia*. New York: Churchill Livingstone, 2001; 207–8
- 19 Black AE, Mackersie AM. Accidental bronchial intubation with RAE tubes. *Anaesthesia* 1991; **46**: 42–3
- 20 McDonald DS, McCormick A, Mackersie AM. Difficulty with a preformed tube in neonate. *Paediatr Anaesth* 1997; **7**: 87–8
- 21 Edsell MEG, McDonald P. Length of preformed tracheal tubes. *Anaesthesia* 2005; **60**: 940–1
- 22 Schaefer HG, Marsch SCU, Flatt T. The length of RAE preformed tubes. *Anaesthesia* 1991; **46**: 791
- 23 Hannington-Kiff JG. The length of RAE preformed tubes. *Anaesthesia* 1991; **46**: 791
- 24 Mackersie AM. The length of RAE preformed tubes. *Anaesthesia* 1991; **46**: 792
- 25 Salgo B, Schmitz A, Stutz K, *et al.* Evaluation of a new recommendation for improved cuffed tracheal tube size selection in infants and small children. *Acta Anaesthesiol Scand* 2006; **50**: 557–61
- 26 Hatch DJ. Paediatric anaesthetic equipment. *Br J Anaesth* 1985; **57**: 672–84
- 27 Stuart R, Steward DJ, Lerman J. Techniques and procedures of pediatric anesthesia. In: Steward DJ, Lerman J, eds. *Manual of Pediatric Anesthesia*. New York: Churchill Livingstone, 2001; 69–127